

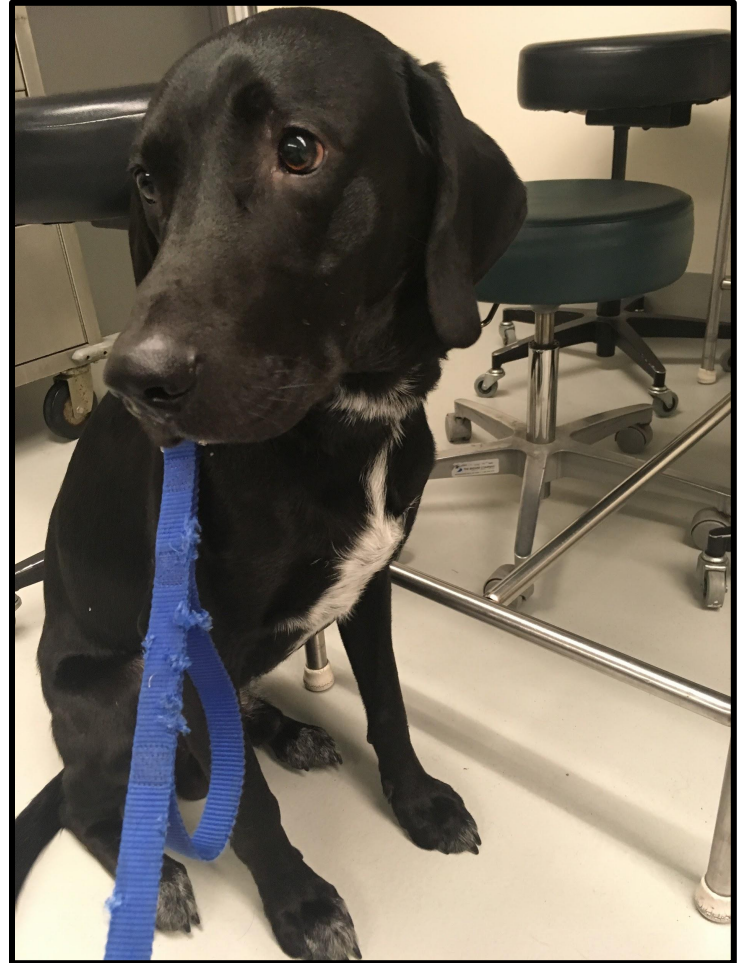
**Idiopathic  
megaesophagus in  
a 9-month-old  
Labrador Mix**

Ellie Matheny  
Class of 2018



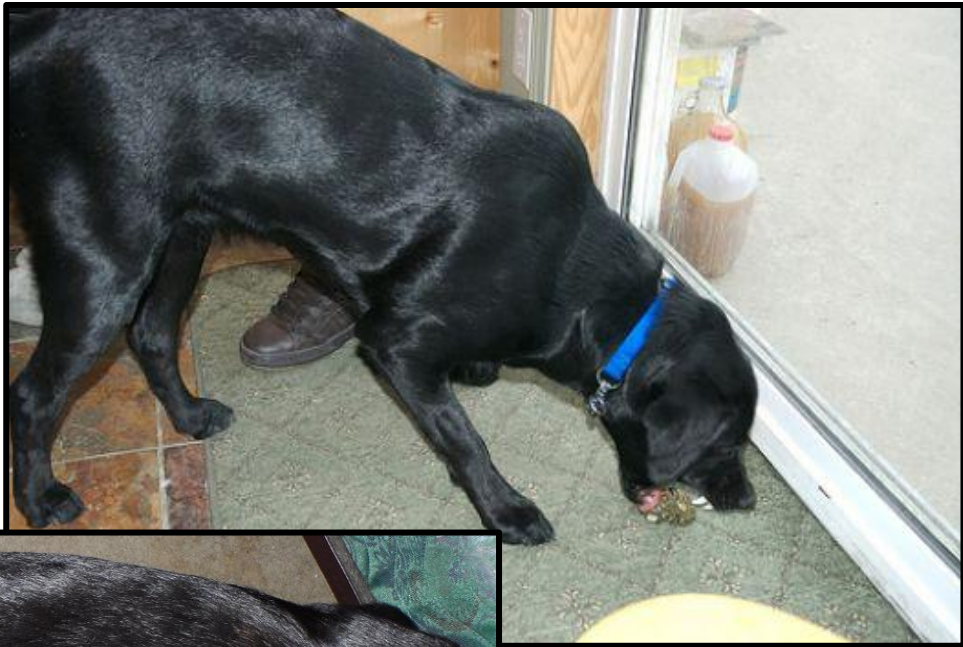# Signalment and History

- 9-month-old male intact Labrador mix
- Regurgitation since adoption at 9 weeks old
- Lack of appropriate weight gain over 6 months, weight loss preceding 2 months
- Sitting up for 5-6 minutes after meals helps keep food down at least an hour
- Not monitored closely throughout the day--free to roam outside
- Physical exam: within normal limits



# Problem list

1. Regurgitation
  - Structural vs. functional problem in the esophagus
2. Weight loss



<http://www.dogscatspets.org/wp-content/uploads/2015/08/dog-vomiting-food-and-water.jpg>



[http://vet.tufts.edu/wp-content/uploads/weight\\_loss.png](http://vet.tufts.edu/wp-content/uploads/weight_loss.png)

# Differential diagnoses for regurgitation



<http://www.speakingforspot.com/Images/regurgitation.jpg>

## **Structural:**

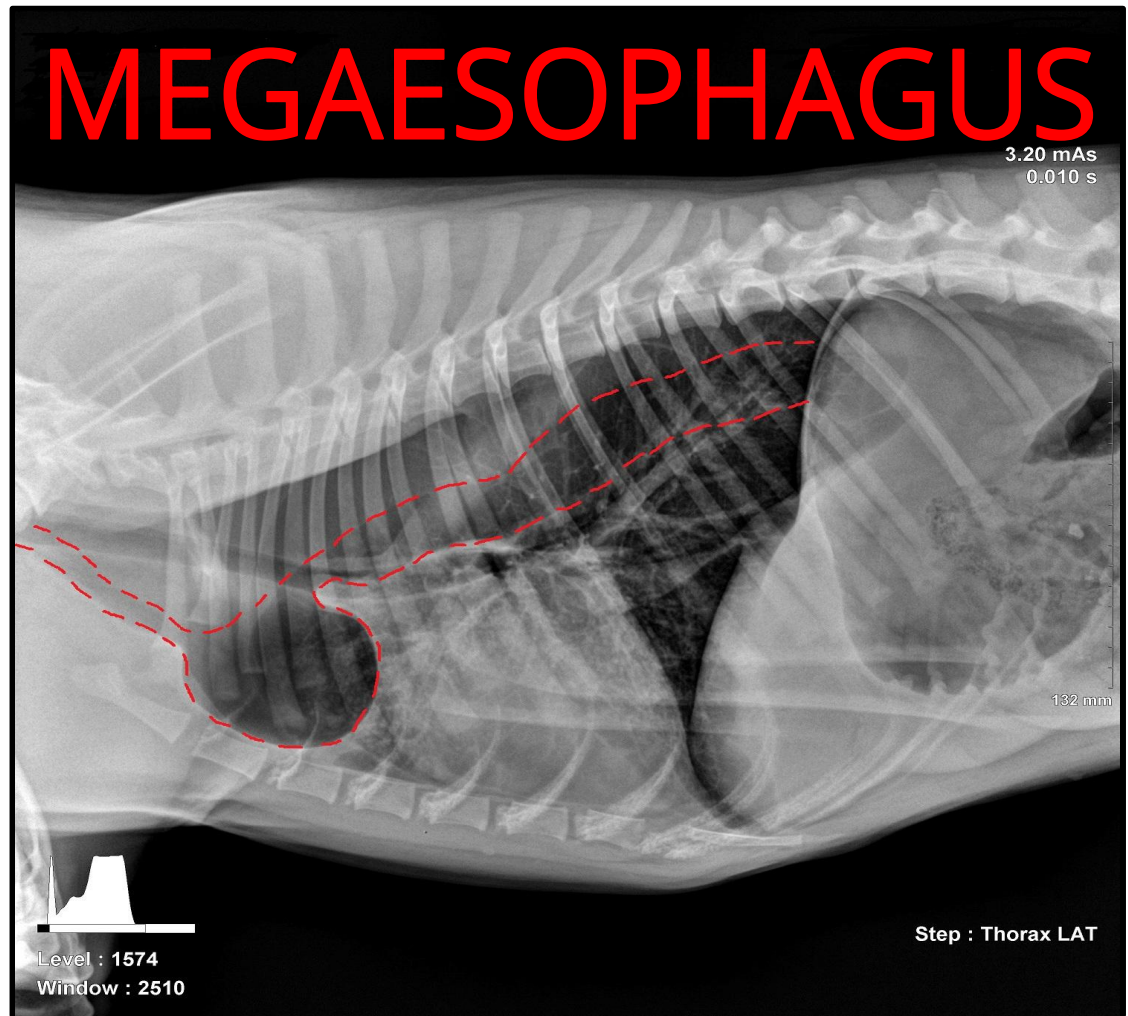
- Megaesophagus
- Neoplasia
- Mechanical obstruction
- Trauma

## **Functional:**

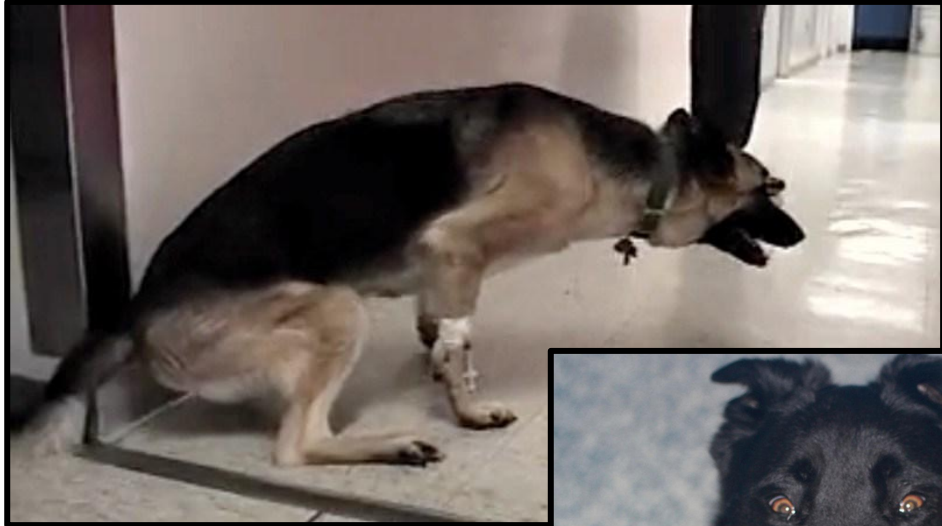- Megaesophagus
- Myasthenia gravis (focal or generalized)
- Hypoadrenocorticism
- Hypothyroidism
- Tetanus
- Botulism
- Esophagitis
- Peripheral neuropathy

# Diagnostic imaging


- Distended diverticulum in esophagus cranial to the base of the heart
- Dilated esophagus throughout the thorax
- Possible evidence of previous or subclinical pneumonia in cranio-ventral lungs



# Causes of megaesophagus



<https://neuropetvet.com/quiz/2015113myasthenia-gravis-thoracic-rads/>



[http://speakingforspot.com/blog/wp-content/uploads/2016/06/SF\\_SBlog\\_tetanus.jpg](http://speakingforspot.com/blog/wp-content/uploads/2016/06/SF_SBlog_tetanus.jpg)


- **Congenital** (a.k.a. Primary)
  - Vascular ring anomalies
  - Myasthenia gravis
  - Idiopathic
- **Acquired** (a.k.a. Secondary, potentially reversible)
  - Myasthenia gravis
  - Hypothyroidism
  - Hypoadrenocorticism
  - Polyneuropathy
  - Tick paralysis
  - Lead toxicity
  - Tetanus
  - Botulism

# Diagnostics

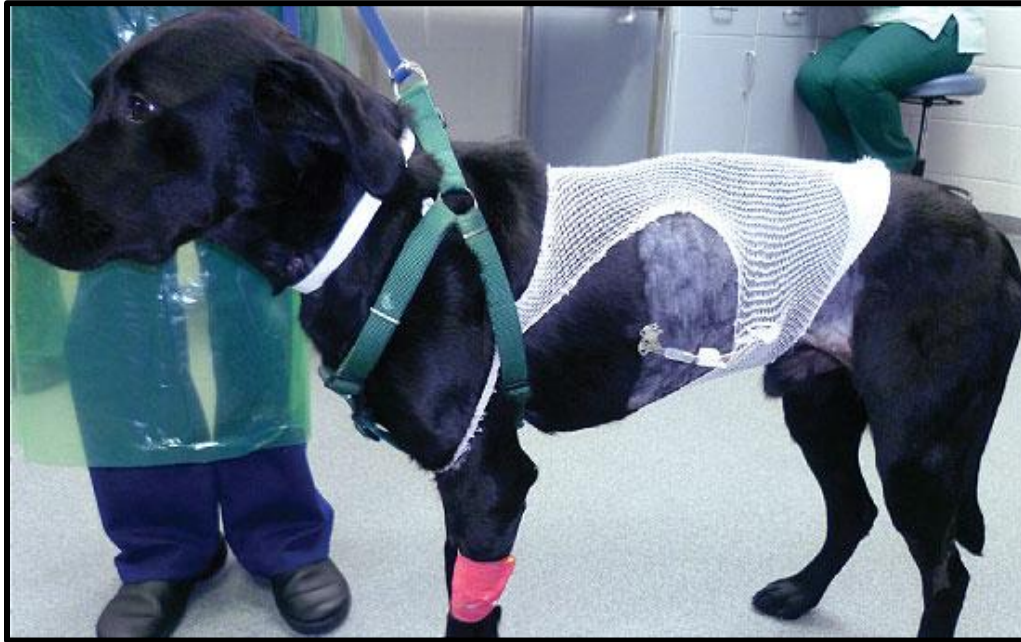- Rule out most structural esophageal problems with thoracic radiographs +/- contrast
- Rule out a functional problem with a swallow study
- Rule out some acquired causes with bloodwork:
  - Hypoadrenocorticism: baseline cortisol +/- ACTH stim test
  - Hypothyroidism: thyroid panel + free T4
  - Lead poisoning: measured in whole blood
  - Myasthenia gravis: acetylcholine receptor antibodies

# Feeding Management

- Feed small meals often
- Owners must experiment with what consistency and kibble size works best for their pet
  - Canned food in meatballs or a slurry are common options
- Feed sitting upright for AT LEAST 20 minutes (Bailey chair)



# Conservative Management

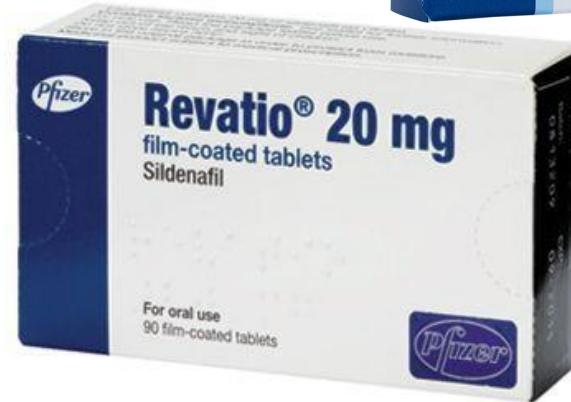
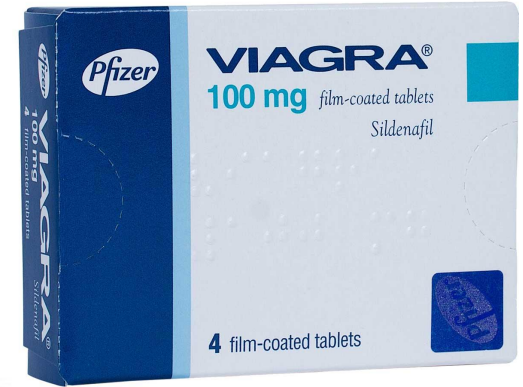
<https://www.willows.uk.net/library/img/www/Specialist%20Services/internal-medicine/dog-with-a-gastrostomy-tube.jpg>

- Gastrostomy tube
  - Still risk of aspirating saliva
- Strict monitoring for eating other things
- Regular check-ups for aspiration pneumonia
- +/- Prokinetics such as metoclopramide and cisapride
- Vasodilators: sildenafil

# Sildenafil: potential medical management

- Vasodilator
- Relaxes lower esophageal sphincter--encouraging emptying into stomach
- Significantly reduced number of regurgitation episodes and increased weight gain in treatment group vs. control
- 30 day supply--20mg tab BID is approximately \$40.00
  - Name-brand Viagra: \$70.00 per 100mg tablet



<https://www.assuredpharmacy.co.uk/blog/wp-content/uploads/2014/11/viagra-100-4.jpg>

# Cost

- Internal Medicine Specialty Exam **\$200.00**
- Three-view thoracic radiographs **\$175.00**
- Barium swallow study \$260.00
- Diagnostic blood work
  - Lead levels \$35.00
  - Thyroid panel \$67.00
  - Baseline cortisol \$16.00
  - Acetylcholine-receptor antibodies \$167.00
- Gastrostomy tube placement (plus castration) \$2000.00
- Bailey chair \$200.00

# Prognosis

- Poor -- median survival time 90 days
- No “cure” -- very small chance for spontaneous resolution
- Time and financial commitment of management
- Difficult to watch the dog slowly starve
- On-going risk of aspiration pneumonia
- Quality of life (for pet and owner)

# Discussion with owners

Communication tips for talking about difficult medical decisions:

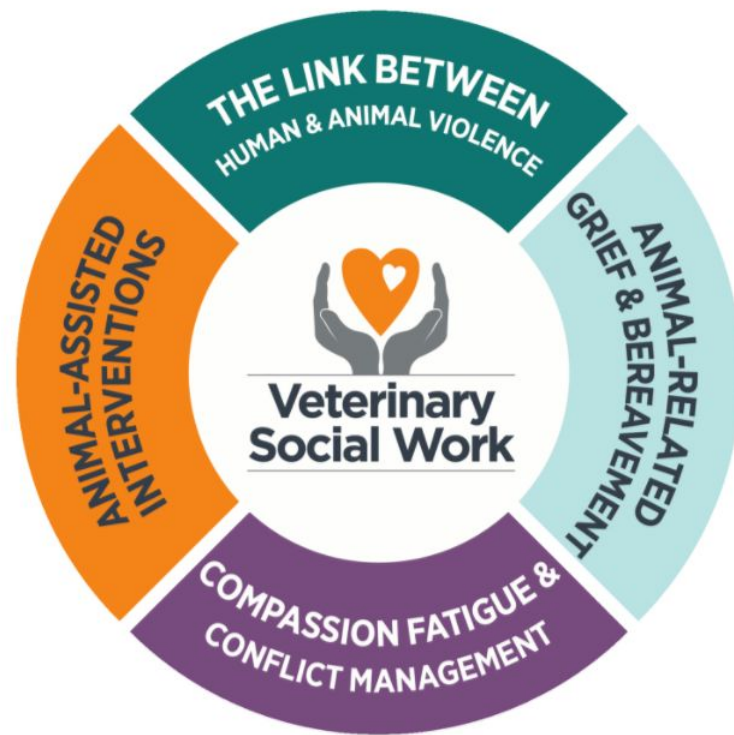- ★ Don't pressure them into the full work-up and treatment
  - Pay special attention to your non-verbals
- ★ Validate their conflicted feelings
  - If they have them, if they don't--refrain from judging
- ★ Empathy, empathy, empathy!
  - Imagine yourself in their position
- ★ Offer grief support, either through your practice if available or refer to an outside resource

# Grief support

The screenshot shows the Cornell University College of Veterinary Medicine website. The navigation bar includes links for ABOUT US, EDUCATION, HOSPITAL CARE, HEALTH TOPICS, DIAGNOSTIC CENTER, RESEARCH, DEPARTMENTS, and ALUMNI. The main header features the Cornell University logo and the text "Cornell University College of Veterinary Medicine". Below the header, there are icons for People, Giving, and Emergencies. The page title is "Pet Loss Support Hotline". The content area includes three images: a black and white cat being held, a man with a beard and a white cap touching a horse's face, and a woman holding a white puppy. On the right side, there is an "OUTREACH" section with a "Pet Loss Support Hotline" link, and sub-links for "About Us", "Donate", "Other Hotlines", and "Resources for Grieving". Below this, the "Pet Loss Support Hotline" details are listed: 607.253.3932, 6:00 pm - 9:00 pm Eastern Time, Tuesdays and Thursdays.

607.253.3932 [cornellplsh@gmail.com](mailto:cornellplsh@gmail.com)

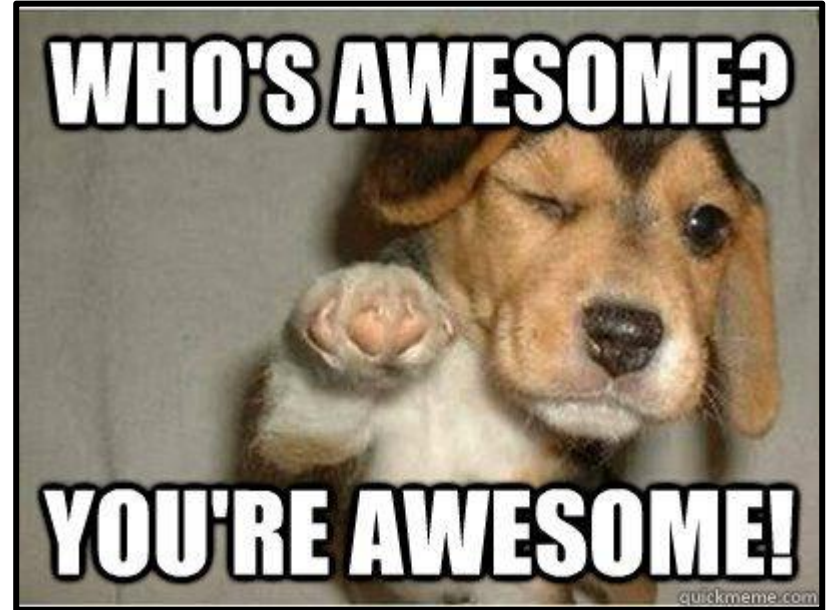Attending to human needs at the intersection of veterinary and social work practice



Helpline: 865.755.8839  
[vetsocialwork@utk.edu](mailto:vetsocialwork@utk.edu)

# Acknowledgments

A huge thanks to  
**Dr. Meredith Miller**  
and  
**Dr. Patrick Carney**  
for your guidance  
and support!



<http://www.quickmeme.com/meme/35cvri>

# References

- Bartges, J.W. and Nielson, D.L. Reversible megaesophagus associated with atypical primary hypoadrenocorticism in a dog. *Journal of American Veterinary Medical Association*. 1992, September; 201(6): 889-891.
- Gaynor, A.R., Shofer, F.S. and R.J. Washabau. Risk factors for acquired megaesophagus in dogs. *Journal of American Veterinary Medical Association*. 1997, December 1; 211(11): 1406-1412.
- Kanemoto, Y., Fukushima, K., Kanemoto, H., Ohno, K., and Hsujimoto, H. Long-term management of a dog with idiopathic megaesophagus and recurrent aspiration pneumonia by use of an indwelling esophagostomy tube for suction of esophageal content and esophagogastric tube feeding. *Journal of Veterinary Medical Sciences*. 2017, January; 79(1): 188-19.
- Mace, S., Shelton, G.D., and Eddlestone, S. Megaesophagus. *Compendium: Continuing Education for Veterinarians*. 2012, February; 34 (2): E1-E8.
- Manning, K., Birkenheuer, A.J., Briley, J., Montgomery, S.A., Harris, J., Vanone, S.L., and Gookin, J.L. Intermittent At-Home Suctioning of Esophageal Content for Prevention of Recurrent Aspiration Pneumonia in 4 Dogs with Megaesophagus. *Journal of Veterinary Internal Medicine*. 2016, September; 30: 1715-1719.
- McBrearty, A. R., Ramsey, I.K., Courcier, E.A., Mellor, D.J., and Bell, R. Clinical factors associated with death before discharge and overall survival time in dogs with generalized megaesophagus. *Journey of American Veterinary Medical Association*. 2011, June 15; 238(12): 1622-1628.
- Quintavalla, F., Menozzi, A., Pozzoli, C., Poli, E., Donati, P., Wyler, D.K., Serventi, P., and Bertini, S. Sildenafil improves clinical signs and radiographic features in dogs with congenital idiopathic megaesophagus: a randomised controlled trial. *Veterinary Record*. 2017, April 22; 180 (16): 404.



Questions?

