

# Coronaviruses as a cause of vascular disease: a comparative medicine approach

Alison E. Stout DVM <sup>1</sup>, Nicole André LVT <sup>1</sup>, Joshua Zimmerberg MD PhD <sup>4</sup>, Susan C. Baker PhD <sup>5</sup> and Gary R. Whittaker PhD <sup>1,2,3,\*</sup>

<sup>1</sup>Department of Microbiology and Immunology, <sup>2</sup>Feline Health Center, College of Veterinary Medicine, <sup>3</sup>Master of Public Health Program, Cornell University, Ithaca NY; <sup>4</sup>Division of Basic and Translational Biophysics, National Institute for Child Health and Development, National Institutes of Health, Bethesda, MD; <sup>5</sup>Department of Microbiology and Immunology, Loyola University Chicago, Stritch School of Medicine, Maywood, IL.

\*Corresponding author. Email: [grw7@cornell.edu](mailto:grw7@cornell.edu).  
618 Tower Rd., Ithaca NY 14853 USA.

## Running title:

Coronaviruses as a cause of vascular disease

## Abstract

COVID-19, caused by SARS-CoV-2, frequently manifests as a respiratory disease, including coughing, shortness of breath, fever, and loss of smell. However, additional disease manifestations occur across numerous organ systems, due at least in part to vasculitis and endotheliitis. COVID-19-associated multisystem inflammatory syndrome in children (MIS-C) was recently identified as a component of SARS-CoV-2 infection. In feline medicine, feline coronavirus is a common pathogen of cats that can lead to a fatal disease called feline infectious peritonitis (FIP). Like COVID-19 in humans, clinical manifestations of FIP are due, in part, to coronavirus-induced vasculitis that can also result in a fatal multisystem inflammatory syndrome in cats. As such, studies investigating how feline coronavirus infection can cause disseminated vasculitis in FIP cats will provide new information that can translate to understanding COVID-19 in humans. We argue for a comparative medicine approach for tackling coronavirus diseases.

## Introduction

The 2019-2020 pandemic of COVID-19 is caused by a recently emerged zoonotic betacoronavirus, classified as SARS-CoV-2. COVID-19 frequently presents as a respiratory disease, manifested as fever, cough, shortness of breath, loss of smell, headaches, and malaise. More severe disease can include acute respiratory distress

syndrome (ARDS); however, it is now appreciated that other organ systems are involved, including the gastrointestinal, central nervous system (CNS), cardiovascular, renal, hepatic, endocrine, dermatological, hematologic, and ophthalmic systems.<sup>17</sup> It has been suggested that these systemic signs are due to virus infection of endothelial cells and endotheliitis,<sup>49</sup> leading to vasculitis.<sup>5</sup> As such COVID-19 can be thought of as both a respiratory disease and a vascular disease, with expanded viral tropism and high transmissibility contributing to the current public health crisis and discriminating SARS-CoV-2 from SARS-CoV, despite a shared receptor (ACE2) for both viruses.

By reviewing the history and pathogenesis of a feline coronavirus, we see parallels between COVID-19 and feline infectious peritonitis (FIP), with broad diversity across human and feline coronavirus infections as originally noted for SARS.<sup>41</sup> Feline coronavirus (FCoV) infection in cats is usually considered to be an initial gastrointestinal, or rarely respiratory infection, expanding in some animals to FIP, a systemic, vascular disease with high morbidity and mortality.<sup>46</sup> This disease of cats, initially called chronic fibrinous peritonitis, was first described in 1963<sup>22</sup>; shortly thereafter the etiologic agent was recognized as a coronavirus. The disease, now called feline infectious peritonitis (FIP), occurs worldwide and remains nearly always fatal with a preponderance of disease occurring in young cats (< 2yr of age).<sup>28,38</sup> The etiological agent responsible for most cases of FIP is the type I feline coronavirus (FCoV), an alphacoronavirus.<sup>25</sup> While transmission and infection of FCoV is widespread across domestic cats, only a small subset of animals develop the systemic disease (Figure 1). Common across these various disease presentations, is the identification of a viral-induced vasculitis.<sup>27</sup> This review highlights the similarities across COVID-19 and FIP, drawing an opportunity for collaboration between the medical and veterinary communities in battling both of these devastating diseases.

## ***Clinical and pathological profile of feline coronavirus infection: parallels with COVID-19***

Like COVID-19 in humans, FIP has been implicated in a number of disease manifestations in cats (Figure 2), being described as “presenting variably with multiple organ failure, seizures, generalized effusion or shock”.<sup>14</sup> Disease is commonly classified in one of two clinical forms, effusive or “wet” (characterized by proteinaceous effusion accumulation in primarily the peritoneal or pleural spaces) and non-effusive, or “dry” (characterized by granulomatous lesions across numerous organs, especially the brain).<sup>19</sup> A “mixed form” is also considered, and across the clinical spectrum, granulomatous to pyogranulomatous lesions are common, presenting on

the serosal side of the liver, kidneys, and intestines.<sup>19</sup> The spectrum of pathology observed with FIP is wide-reaching and has previously been noted to include serositis, hepatitis, nephritis, uveitis, and corioretinitis.<sup>38,55</sup> Neuropathologic manifestations of FIPV in cats includes meningitis, meningoencephalitis, ependymitis and choroid plexitis with inflammation varying from lymphoplasmacytic to pyogranulomatous and often including vasculitis and perivasculitis.<sup>31</sup> Ophthalmic conditions, including uveitis and chorioretinitis have additionally been described. Case reports have highlighted associated cardiac lesions, including myocarditis and fibrinous epicarditis.<sup>12,34</sup> Dermatological lesions, which have been less frequently described in FIP, include erythema, nodules, and papules.<sup>4,8,10</sup> Early respiratory signs have also been reported in some cases<sup>8,54</sup> and immunostaining has identified virus in lung parenchyma in some cats.<sup>27</sup> Most recently, our lab has confirmed viral presence in the upper respiratory tract via immunostaining.<sup>1</sup>

The similar feature across both development of FIP and patients with COVID-19 is the overwhelming vascular involvement.<sup>3,5,20</sup> In one of the first reports recognizing the vascular involvement in cases of FIP, four lesion types were described, including: “perivascular edema,” “degeneration of vascular wall,” “endothelial proliferation,” and “adventitial and/or perivascular infiltration”.<sup>20</sup> In 1989, Boudreaux and colleagues described FIP lesions in several cats as an “obliteration” of the vessel walls.<sup>7</sup> Likewise, a 1984 review by August, concluded “FIPV might more accurately be named feline coronaviral vasculitis”.<sup>3</sup> As a naturally occurring disease of cats, FIP and FCoV infection provide insight into SARS-CoV-2 pathogenesis, especially considering the shared development of vascular manifestations.

Though rare, observations of myocarditis, rhinitis or cutaneous lesions in FIP may provide a comparison for COVID-19.<sup>1,8,12,42</sup> In several COVID-19 patients, chilblain-like lesions a condition colloquially termed “COVID-toes” has been described, though the full relationship as a manifestation of COVID-19 remains open.<sup>30,33</sup> In cats a similar condition known as plasma cell pododermatitis may equally be linked to FCoV. Plasma cell pododermatitis, manifests as inflammation of the paw pad, along with the potential for color changes, ulcerations, and fissures.<sup>40</sup> An associated infectious disease has been suggested in cases of feline pododermatitis.<sup>11</sup> Our lab has previously identified pododermatitis in a cat submitted because of FIP in addition to observing similar footpad lesions in a cat shedding FCoV. Though “COVID-toes” and feline pododermatitis are rare outcomes of infection, they

further highlight the spectrum of similarities across COVID-19 and FIP.

One distinguishing feature of COVID-19 is anosmia. Likewise, common across most cases of FIP is the onset of anorexia.<sup>38,53</sup> While this is a non-specific clinical sign that can be attributed to a number of different causes, anorexia can be attributed to a loss of odor perception—a particularly important sensation that controls appetite in cats. While anosmia is hard to measure in cats, the connections between infection of the olfactory bulb and possible spread to the brain by human and feline coronaviruses deserve further evaluation, especially in light of the neurologic manifestations across both diseases.<sup>14,29</sup>

### *The immune component of FIP disease*

FIP is classically characterized as immune mediated, based on early observations of the circulation of complement and immunoglobulins, including as immune complexes.<sup>24,39</sup> Specifically, type III hypersensitivity and Arthus-like reactions lead to the development of immune complexes, which can be deposited in the walls of blood vessels, resulting in vasculitis. Despite early attempts to classify FIP as a type III hypersensitivity reaction, further work by Kipar and colleagues has shown numerous disparities.<sup>26,27</sup> Type III hypersensitivity has also been investigated in COVID-19 patients.<sup>43</sup> The relevance of FIP as a type IV hypersensitivity reaction has also been evaluated, with obvious perivascular lesions comprised of T-lymphocytes, granulocytes and a hallmark feature of FIP, macrophage infiltrates.<sup>36</sup> In cats inoculated intradermally with FCoV, delayed type hypersensitivity is observed, resulting in perivascular cellular infiltrates of macrophages, neutrophils, and lymphocytes, in the absence of immune complexes.<sup>52</sup> However, the cellular extravasation associated with FIP lesions contributes to endothelial disruption and the inflammatory reaction underlying FIP.<sup>27</sup> Specifically, the adhesion molecules  $\beta_2$  integrin lymphocyte function associated antigen (LFA)-1,  $\beta_1$  integrin very late antigen (VLA)-4 and  $\beta_2$  macrophage-1 antigen (Mac-1) have been demonstrated to be increased in peripheral blood leukocytes isolated from cats with FIP.<sup>35</sup> The integrins (LFA)-1 and (VLA)-4 play an important role in neutrophil and monocyte migration across the endothelium and have been implicated in causing vasculitis in other disease processes,<sup>9,47</sup> whereas (Mac-1) may play an additional role in thrombosis development.<sup>51</sup> The hypothesized role of endotheliitis underlying COVID-19<sup>49</sup> disease parallels with the previous reports in FIP and the resulting acute vasculitis.

The interplay between vascular pathogenesis and hemodynamics has long been recognized in FIP.<sup>53</sup> In cats experimentally infected with FCoV, classic FIP disease,

including perivenous pyogranulomatous lesion in addition to phlebitis, thrombophlebitis and thrombosis have been observed in addition to endothelial swelling with inflammatory infiltrates of the tunica media.<sup>53</sup> Thrombocytopenia, anemia, icterus, decreases in clotting factors VII-XII, elevations in antithrombin III, and prolonged activated partial thromboplastin time, prothrombin time, and thrombin time, following experimental infection are additionally observed.<sup>7,53</sup> Thus, the end stage result for a portion of cats with FIP is the development of disseminated intravascular coagulation.<sup>7,53</sup> This is in contradistinction to the ICU course of human patients, who are often anti-coagulated at some point in their hospital stay, yet the rare development of DIC in humans is associated with worse outcomes of COVID-19.<sup>48</sup> The fibrin breakdown product D-dimer, a marker of DIC, has been infrequently studied in FIP cats, but in two cases has been elevated—as might be expected and paralleling observations in COVID-19 patients.

The development of FIP in a subset of cats, despite a majority of cats being sub-clinically infected with FCoV has been proposed to be a result of the initial immune response.<sup>37</sup> In particular, it is commonly considered that strong cell mediated immunity (CMI) in addition to humoral immunity results in inapparent disease, while a lack of CMI results in effusive disease and partial CMI results in non-effusive disease.<sup>37</sup> In a similar consideration of the immune response, the recently described multisystem inflammatory syndrome in children (MIS-C), which may be a manifestation of SARS-CoV-2,<sup>16</sup> has been proposed to develop when the interferon response is delayed or as a result of an aberrant IgG response enhancing disease development.<sup>44</sup> In addition to MIS-C, multisystem inflammatory syndrome in adults (MIS-A) has also been described as an outcome of those exposed to SARS-CoV-2.<sup>32</sup>

#### ***Antibody-dependent enhancement of infection***

For SARS-CoV-2, concerns about antibody-dependent enhancement (ADE) of infection have been raised,<sup>13</sup> in large part based on experiences with other human viruses such as respiratory syncytial virus, influenza and dengue; despite the need for caution, formal evidence associating ADE with clinical outcomes of COVID-19 remains insufficient.<sup>2</sup> In cats, is it noteworthy that a role for ADE has long been considered to be involved in FCoV infection and the development of FIP, with antibodies providing a means for FCoV to gain entry into the macrophage.<sup>21</sup> To this end, despite several attempts, a viable FCoV/FIP vaccine is still not available.<sup>45,50</sup> In contrast to these early studies of vaccines for FIP, preliminary results of immunization for COVID-19, such

as with stabilized spike immunogens have documented neutralizing, not enhancing, antibody responses.<sup>23</sup>

#### ***Perspectives***

COVID-19 is a complex and challenging disease in humans, and similarly FIP is a complex disease in cats, with numerous factors contributing to the disease outcome. In analogy with a perennial question in metastatic cancer research, “seed and soil”, the availability of immunologic, pathologic, and physiologic specimen and data on these similarly fatal inflammatory syndromes from two different coronaviruses in their own host species can allow testing of hypotheses on structure/function relationships in the venous vasculitides. Moreover, given the lack of enthusiasm for clinical biopsy of human patients with fulminant COVID-19 and the severe difficulties in obtaining good preservation of pathological specimens, it will take a very long time to learn what is discussed above: the presence or absence of coronavirus in human patients at the onset and during progression of their inflammatory phase of COVID-19.

As a naturally occurring disease with many parallels to COVID-19, we suggest that FIP may help provide guidance for future research on COVID-19. The underlying vasculopathy across both FIP and COVID-19 highlight the need to think of these diseases as multi-system, rather than as organ-specific diseases. While FCoV is often considered as having an enteric route of transmission, it is clear that the oro-pharynx is a robust portal of entry into host. An additional factor that needs to be considered is that SARS-CoV-2 infects cats.<sup>15,18</sup> While not currently considered to be a significant disease concern for cats, and as such not a robust animal model for COVID-19 disease, increased infection rates of SARS-CoV-2 in cats and possible co-infections with FCoV do raise the concern of overlapping pathology and clinical presentation of human and feline coronaviruses with surprisingly similar vascular disease profiles, in addition to the potential for viral recombination. However, the fact that SARS-CoV-2 naturally infects cats may offer a model for pre-clinical evaluation of SARS-CoV-2 vaccines. We suggest that further studies investigating how coronaviruses may cause vascular disease are needed so that we can eliminate these devastating illnesses, with FIP providing a platform for shared clinical trials bridging feline and human medicine.

***Funding:*** AES is supported by NIH Comparative Medicine Training Program T32OD011000. GRW is funded by NIH grants R01AI135270 and R21AI135373, SCB is funded by NIH grant R01 AI085089. Research on FIP in the author’s labs is funded in part by the Winn Feline Foundation and the Cornell Feline Health Center.

**Acknowledgments:** We thank Andrew Miller, Robert Goggs, Natalie Zatz and Beth Licitra for critical reading of the manuscript and helpful discussions.

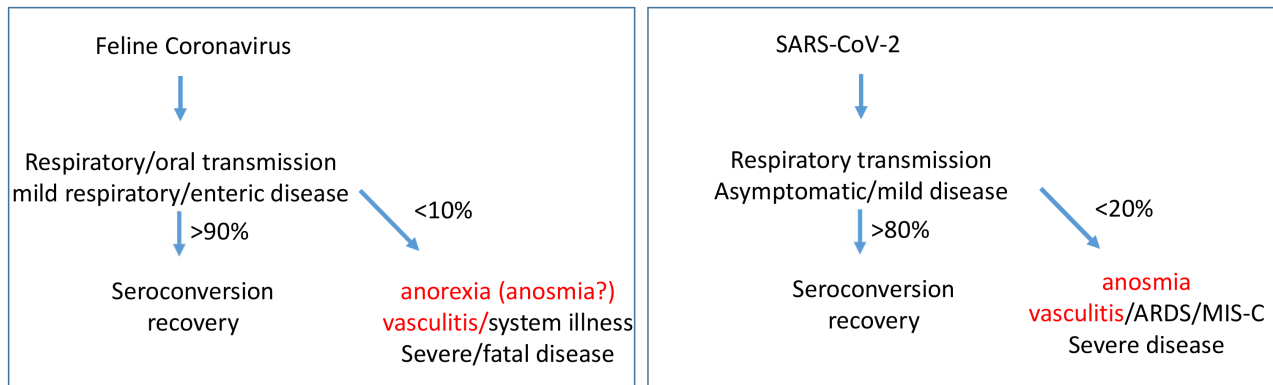
**Conflicts of Interest:** The authors declare no conflict of interest.

## References

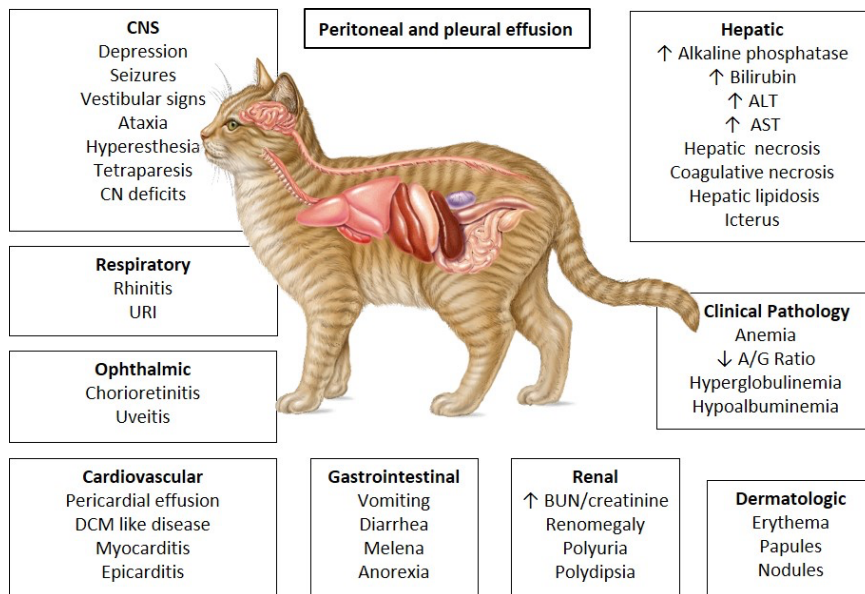
1. **André NM, Miller AD, Whittaker GR.** 2020. Feline infectious peritonitis virus-associated rhinitis in a cat. *Journal of Feline Medicine and Surgery Open Reports* **6**:1–6.
2. **Arvin AM, Fink K, Schmid MA, Cathcart A, Spreafico R, Havenar-Daughton C, Lanzavecchia A, Corti D, Virgin HW.** 2020. A perspective on potential antibody-dependent enhancement of SARS-CoV-2. *Nature* **584**: 353–363.
3. **August JR.** 1984. Feline Infectious Peritonitis: An Immune-Mediated Coronaviral Vasculitis. *Veterinary Clinics of North America: Small Animal Practice* **14**:971–984.
4. **Bauer BS, Kerr ME, Sandmeyer LS, Grahn BH.** 2013. Positive immunostaining for feline infectious peritonitis (FIP) in a Sphinx cat with cutaneous lesions and bilateral panuveitis. *Veterinary Ophthalmology* **16**:160–163.
5. **Becker RC.** 2020. COVID-19-associated vasculitis and vasculopathy. *Journal of Thrombosis and Thrombolysis* **50**: 499–511.
6. **Biezus G, Cristo TG de, Schade MF da S, Ferian PE, Carniel F, Miletti LC, Maciel A da R, Casagrande RA.** 2020. Plasma cell pododermatitis associated with feline leukemia virus (FeLV) and concomitant feline immunodeficiency virus (FIV) infection in a cat. *Topics in Companion Animal Medicine* **41**: 100475. <https://doi.org/10.1016/j.tcam.2020.100475>.
7. **Boudreaux MK, Weiss RC, Cox N, Spano JS.** 1989. Evaluation of antithrombin-III activity as a coindicator of disseminated intravascular coagulation in cats with induced feline infectious peritonitis virus infection. *American Journal of Veterinary Research* **50**:1910–1913.
8. **Cannon MJ, Silkstone MA, Kipar AM.** 2005. Cutaneous lesions associated with coronavirus-induced vasculitis in a cat with feline infectious peritonitis and concurrent feline immunodeficiency virus infection. *Journal of Feline Medicine and Surgery* **7**:233–236.
9. **Coll-Vinent B, Cebrián M, Cid MC, Font C, Esparza J, Juan M, Yagüe J, Urbano-Márquez Á, Grau JM.** 1998. Dynamic pattern of endothelial cell adhesion molecule expression in muscle and perineural vessels from patients with classic polyarteritis nodosa. *Arthritis & Rheumatism* **41**:435–444.
10. **Declercq J, De Bosschere H, Schwarzkopf I, Declercq L.** 2008. Papular cutaneous lesions in a cat associated with feline infectious peritonitis. *Veterinary Dermatology* **19**:255–258.
11. **Diesel A.** Image Gallery: Immune-Mediated Skin Diseases. *Clinician's Brief* [Internet]. 2020 [cited 2020 September 28]. Available from: <http://www.cliniciansbrief.com/article/image-gallery-immune-mediated-skin-diseases>
12. **Ernandes MA, Cantoni AM, Armando F, Corradi A, Ressel L, Tamborini A.** 2019. Feline coronavirus-associated myocarditis in a domestic longhair cat. *Journal of Feline Medicine and Surgery Open Reports* **5**:1–5.
13. **Eroshenko N, Gill T, Keaveney MK, Church GM, Trevejo JM, Rajaniemi H.** 2020. Implications of antibody-dependent enhancement of infection for SARS-CoV-2 countermeasures. *Nature Biotechnology* **38**:789–791.
14. **Foley JE, Rand C, Leutenegger C.** 2003. Inflammation and changes in cytokine levels in neurological feline infectious peritonitis. *Journal of Feline Medicine and Surgery* **5**:313–322.
15. **Gaudreault NN, Trujillo JD, Carossino M, Meekins DA, Morozov I, Madden DW, Indran SV, Bold D, Balaraman V, Kwon T, et al.** 2020. SARS-CoV-2 infection, disease and transmission in domestic cats. *Emerging Microbes and Infections*. <https://doi.org/10.1080/22221751.2020.1833687>.
16. **Godfred-Cato S, Bryant B, Leung J, Oster ME, Conklin L, Abrams J, Roguski K, Wallace B, Prezzato E, Koumans EH, et al.** 2020. COVID-19-Associated Multisystem Inflammatory Syndrome in Children - United States, March-July 2020. *Morbidity and Mortality Weekly Report* **69**:1074–1080.
17. **Gupta A, Madhavan MV, Sehgal K, Nair N, Mahajan S, Sehrawat TS, Bikdeli B, Ahluwalia N, Ausiello JC, Wan EY, et al.** 2020.

- Extrapulmonary manifestations of COVID-19. *Nature Medicine* **26**:1017–1032.
18. **Halfmann PJ, Hatta M, Chiba S, Maemura T, Fan S, Takeda M, Kinoshita N, Hattori S, Sakai-Tagawa Y, Iwatsuki-Horimoto K, et al.** 2020. Transmission of SARS-CoV-2 in Domestic Cats. *New England Journal of Medicine* **383**: 592-594.
  19. **Hartmann K.** 2005. Feline infectious peritonitis. *Veterinary Clinics of North America: Small Animal Practice* **35**:39–79.
  20. **Hayashi T, Goto N, Takahashi R, Fujiwara K.** 1977. Systemic vascular lesions in feline infectious peritonitis. *The Japanese Journal of Veterinary Science* **39**:365–377.
  21. **Hohdatsu T, Yamada M, Tominaga R, Makino K, Kida K, Koyama H.** 1998. Antibody-dependent enhancement of feline infectious peritonitis virus infection in feline alveolar macrophages and human monocyte cell line U937 by serum of cats experimentally or naturally infected with feline coronavirus. *The Journal of Veterinary Medical Science* **60**:49–55.
  22. **Holzworth J.** 1963. Some important disorders of cats. *The Cornell Veterinarian* **53**:157–160.
  23. **Jackson LA, Anderson EJ, Roupheal NG, Roberts PC, Makhene M, Coler RN, McCullough MP, Chappell JD, Denison MR, Stevens LJ, et al.** 2020. An mRNA Vaccine against SARS-CoV-2 — Preliminary Report. *New England Journal of Medicine*. <https://www.nejm.org/doi/full/10.1056/nejmoa2022483>.
  24. **Jacobse-Geels HEL, Horzinek MC.** 1983. Expression of Feline Infectious Peritonitis coronavirus antigens on the surface of feline macrophage-like cells. *J. gen Virol* **64**:1859–1866.
  25. **Jaimes JA, Millet JK, Stout AE, André NM, Whittaker GR.** 2020. A Tale of Two Viruses: The Distinct Spike Glycoproteins of Feline Coronaviruses. *Viruses* **12**: 83. <https://doi.org/10.3390/v12010083>.
  26. **Kipar A, Bellmann S, Kremendahl J, Köhler K, Reinacher M.** 1998. Cellular composition, coronavirus antigen expression and production of specific antibodies in lesions in feline infectious peritonitis. *Veterinary Immunology and Immunopathology* **65**:243–257.
  27. **Kipar A, May H, Menger S, Weber M, Leukert W, Reinacher M.** 2005. Morphologic features and the development of granulomatous vasculitis in feline infectious peritonitis. *Vet Pathol* **42**:321–330.
  28. **Kipar A, Meli ML.** 2014. Feline Infectious Peritonitis: Still an Enigma? *Veterinary Pathology* **51**:505–526.
  29. **Mao L, Jin H, Wang M, Hu Y, Chen S, He Q, Chang J, Hong C, Zhou Y, Wang D, et al.** Neurologic Manifestations of Hospitalized Patients with Coronavirus Disease 2019 in Wuhan, China. *JAMA Neurology*. 2020 June 1;**77**:683–690.
  30. **Mazzotta F, Troccoli T, Bonifazi E.** 2020. A new vasculitis at the time of COVID-19. *European Journal of Pediatric Dermatology* **30**: 75–78.
  31. **Mesquita LP, Hora AS, Siqueira A de, Salvagni FA, Brandão PE, Maiorka PC.** 2016. Glial response in the central nervous system of cats with feline infectious peritonitis. *Journal of Feline Medicine and Surgery* **18**:1023–1030.
  32. **Morris SB, Schwartz NG, Patel P, Abbo L, Beauchamps L, Balan S, Lee EH, Paneth-Pollak R, Geevarughese A, Lash MK, et al.** 2020. Case Series of Multisystem Inflammatory Syndrome in Adults Associated with SARS-CoV-2 Infection — United Kingdom and United States, March–August 2020. *Morbidity and Mortality Weekly Report* **69**:1450–1456.
  33. **Noakes A, Majoe S.** 2020. Understanding the role that ‘COVID toe’ has in recognizing the potential extent of COVID-19 infections: a case study. *Pathogens and Global Health* **114**: 283-284.
  34. **Oliveira LB, Susta L, Rech RR, Howerth EW.** 2014. Pathology in practice: Effusive FIP with fibrinous epicarditis in a cat **245**:899–901.
  35. **Olyslaegers DAJ, Dedeurwaerder A, Desmarests LMB, Vermeulen BL, Dewerchin HL, Nauwynck HJ.** 2013. Altered expression of adhesion molecules on peripheral blood leukocytes in feline infectious peritonitis. *Veterinary Microbiology* **166**:438–449.
  36. **Paltrinieri S, Parodi MC, Cammarata G, Mambretti M.** 1998. Type IV hypersensitivity in the pathogenesis of FIPV-induced lesions. *Journal of Veterinary Medicine, Series B* **45**:151–159.

37. **Pedersen, N.** 1983. Feline infectious peritonitis and feline enteric coronavirus infections. *Feline Practice* **13**:5–20.
38. **Pedersen NC.** 2009. A review of feline infectious peritonitis virus infection: 1963-2008. *Journal of Feline Medicine and Surgery* **11**:225–258.
39. **Pedersen NC, Boyle JF.** 1980. Immunologic phenomena in the effusive form of feline infectious peritonitis. *American Journal of Veterinary Research* **41**:868–876.
40. **Pereira PD, Faustino AMR.** 2003. Feline plasma cell pododermatitis: a study of 8 cases. *Veterinary Dermatology* **14**:333–337.
41. **Perlman S, Netland J.** 2009. Coronaviruses post-SARS: update on replication and pathogenesis. *Nature Reviews Microbiology* **7**:439–450.
42. **Redford T, Al-Dissi AN.** 2019. Feline infectious peritonitis in a cat presented because of papular skin lesions. *The Canadian Veterinary Journal* **60**:183–185.
43. **Roncati L, Ligabue G, Fabbiani L, Malagoli C, Gallo G, Lusenti B, Nasillo V, Manenti A, Maiorana A.** 2020. Type 3 hypersensitivity in COVID-19 vasculitis. *Clinical Immunology* **217**:108487. <https://doi.org/10.1016/j.clim.2020.108487>.
44. **Rowley AH.** 2020. Understanding SARS-CoV-2-related multisystem inflammatory syndrome in children. *Nature Reviews Immunology* **20**:453–454.
45. **Scott FW, Corapi WV, Olsen CW.** 1992. Evaluation of the safety and efficacy of Primucell-FIP vaccine. *Feline Health Topics* **7**:6–8.
46. **Sykes JE.** Feline Coronavirus Infection. In: *Canine and Feline Infectious Diseases*. Elsevier; 2014. pp. 195–208. Available from: <https://linkinghub.elsevier.com/retrieve/pii/B978143770795300020X>
47. **Takeuchi T, Amano K, Sekine H, Koide J, Abe T.** 1993. Upregulated expression and function of integrin adhesive receptors in systemic lupus erythematosus patients with vasculitis. *The Journal of Clinical Investigation* **92**:3008–3016.
48. **Tang N, Li D, Wang X, Sun Z.** 2020. Abnormal coagulation parameters are associated with poor prognosis in patients with novel coronavirus pneumonia. *Journal of Thrombosis and Haemostasis* **18**:844–847.
49. **Varga Z, Flammer AJ, Steiger P, Haberecker M, Andermatt R, Zinkernagel AS, Mehra MR, Schuepbach RA, Ruschitzka F, Moch H.** 2020. Endothelial cell infection and endotheliitis in COVID-19. *The Lancet* **395**:1417–1418.
50. **Vennema H, Groot RJ de, Harbour DA, Dalderup M, Gruffydd-Jones T, Horzinek MC, Spaan WJ.** 1990. Early death after feline infectious peritonitis virus challenge due to recombinant vaccinia virus immunization. *Journal of Virology* **64**:1407–1409.
51. **Wang Y, Gao H, Shi C, Erhardt PW, Pavlovsky A, A. Soloviev D, Bledzka K, Ustinov V, Zhu L, Qin J, et al.** 2017. Leukocyte integrin Mac-1 regulates thrombosis via interaction with platelet GPIIb/IIIa. *Nature Communications* **8**:15559. <https://doi.org/10.1038/ncomms15559>.
52. **Weiss RC, Cox NR.** 1989. Evaluation of immunity to feline infectious peritonitis in cats with cutaneous viral-induced delayed hypersensitivity. *Veterinary Immunology and Immunopathology* **21**:293–309.
53. **Weiss RC, Dodds WJ, Scott FW.** 1980. Disseminated intravascular coagulation in experimentally induced feline infectious peritonitis. *American Journal of Veterinary Research* **41**:663–671.
54. **Wolfe LG, Griesemer RA.** 1966. Feline infectious peritonitis. *Path Vet* **3**:255–270.
55. **Ziółkowska N, Paździor-Czapula K, Lewczuk B, Mikulska-Skupień E, Przybylska-Gornowicz B, Kwiecińska K, Ziółkowski H.** 2017. Feline Infectious Peritonitis: Immunohistochemical features of ocular inflammation and the distribution of viral antigens in structures of the eye. *Veterinary Pathology* **54**:933–944.



**Figure 1:** FIP only develops in a subset of cats who are infected with FCoV, despite FCoV infection being widespread. Similarly, current evidence has demonstrated that many cases of SARS-CoV-2 infection are mild or inapparent disease.



**Figure 2:** The underlying vasculitis caused by FCoV infection can result in numerous body systems being affected. Since being first described in the 1960's, numerous reports have highlighted various disease presentations, as demonstrated here.