

AN ATLAS OF GENERAL PATHOLOGY

VOLUME II

by

J.M. King, D.V.M., Ph.D.

R.C.T. Lee, D.V.M., Ph.D.

PROFESSORIAL POST SCRIPTS

Cornell faculty often have manuscripts in various states of completion when they reach emeritus status. This archival repository is a place where these manuscripts, some previously published but out of print, and some that have not been subjected to peer review, may be valuable for their content, but sometimes also for their historical value. This collection is a place for these legacy works to become accessible online.

Cornell University
Released: October 2014

This book – <http://hdl.handle.net/1813/37946>
Professorial Post Scripts Collection – <http://ecommons.library.cornell.edu/handle/1813/37929>
The Internet-First University Press – <http://ecommons.library.cornell.edu/handle/1813/62>

AN ATLAS OF GENERAL PATHOLOGY

VOLUME II



AN ATLAS OF GENERAL PATHOLOGY
VOLUME II

AN ATLAS OF GENERAL PATHOLOGY

VOLUME II

BY

J.M. King, D.V.M., Ph.D.

R.C.T. Lee, D.V.M., Ph.D.

A Special Publication of the
Council for Agricultural Planning and Development Executive Yuan
and the
Pig Research Institute of Taiwan
Republic of China
and
Cornell University, Ithaca, N.Y. USA
March, 1983

Copyright © 1983 by the
Council for Agricultural
Planning and Development
Executive Yuan
37 Nankai Road, Taipei, 107
Taiwan, Republic of China

First Printing, March 1983
Printed by
Sheng An Printing Inc.
Taipei, Taiwan, Republic of China

AN ATLAS OF GENERAL PATHOLOGY
VOLUME II

BY




Copyright © 1983 by the
Council for Agricultural
Planning and Development,
Executive Yuan
37 Nanhai Road, Taipei, 107
Taiwan, Republic of China


First Printing, March 1983
Printed by
Shen's Art Printing Inc.
Taipei, Taiwan, Republic of China

Preface

**In Dedication To
Peter Olafson**



Medicine



Copyright © 1964
Council for the Advancement
of Planning Education
Executive Office
17 North
Tulane, N.

First Edition
Revised Edition
Sloan's
Tape, T.

Preface

The present work is intended as the second volume of an Atlas of General Pathology, of which the first was published in May 1976; it includes a large number of common lesions not found in the previous book, though a few are reprinted here for various reasons. The first volume focuses on pig lesions, but the second deals mostly with lesions seen in other species and includes swine specimens as well. Both diagnostic and incidental lesions and findings are covered. It is indeed quite frustrating for a pathologist to record a lesion without being able to interpret it because no such picture of it has been ever seen before. Nevertheless, this volume together with its forerunner should greatly enhance pathological studies.

The same general format has been followed in presenting the cause of the findings in the order of congenital defects, normal structures and findings commonly misinterpreted, artefacts, functional and physical changes, bacterial diseases, viral diseases, protozoal, fungal and parasitic diseases, and neoplastic problems. Exceptions to the aforementioned order occur, however, as when efforts are made to emphasize the value of some special lesions.

All pictures except those which carry the names and locations of the individuals who either supplied the pictures or had a part in their interpretation are ours, good or bad, and all captions for the pictures are also written by us.

It is our hope that no major errors have been made but we also expect that there will be discrepancies in the interpretation of some lesions. Part of the idea of this atlas is to stimulate pathologists to think of alternative possibilities in interpretation.

We are deeply indebted to many for helping with this book; they include Drs. F.M. Wu, C.I. Liu of the National Chung Hsing University, and Redmen Chu, S.J. Du of Pig Research Institute Taiwan, Republic of China. Our thanks also go to the Council for Agricultural Planning and Development, the Pig Research Institute of Taiwan, and the New York State College of Veterinary Medicine of Cornell University for their support, without which this publication will not be made possible. A special kind of thanks goes to Dr. Lois Roth who did the major amount of final proofreading under some duress of speed as well as to Mrs. John M. King who did the initial proofreading and the typing of the manuscript.

John M. King, D.V.M., Ph. D.
Professor
New York State College of Veterinary Medicine
Cornell University
Ithaca, New York, U.S.A.

Robert C.T. Lee, D.V.M., Ph. D.
President
National Chung-Hsing University
Taichung, Taiwan
Republic of China

Contents

			Plate number	Page number
Chapter	I	Skin.	1	1
Chapter	II	Musculoskeletal System.		31
		Bones	62	31
		Joints	83	42
		Muscles	101	51
Chapter	III	Peritoneum	119	60
Chapter	IV	Liver	141	71
		Gallbladder	196	98
Chapter	V	Pancreas	200	100
Chapter	VI	Urinary System		105
		Kidneys.	209	105
		Bladder	267	134
Chapter	VII	Female Genitalia	281	141
		Mammary Gland	296	148
Chapter	VIII	Male Genitalia	306	153
Chapter	IX	Respiratory System.		157
		Upper Respiratory Tract	313	157
		Pleura	344	172
		Lungs	349	175
Chapter	X	Cardiovascular System.		218
		Pericardium.	436	218
		Heart.	441	221
		Blood and Blood Vessels.	493	247
Chapter	XI	Lymphoid System.		261
		Spleen	521	261
		Thymus.	530	265
		Lymph Nodes	531	266
Chapter	XII	Alimentary Tract.		270
		Mouth and Esophagus.	539	270
		Stomach	562	281
		Small Intestine	617	309
		Large Intestine	674	337
Chapter	XIII	Nervous System.		347
		Brain	693	347
		Spinal Cord	709	355
		Eyes	717	359
Chapter	XIV	Endocrine System		360
		Thyroid and Parathyroid.	719	360
		Adrenal	722	361
		Pituitary	728	364
Index.				369

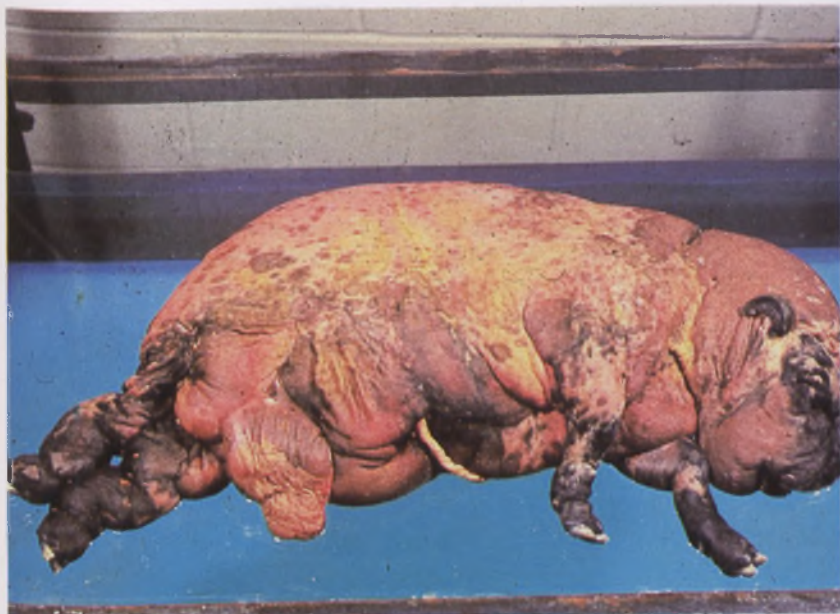

PLATE 1: GENERALIZED ANASARCA

This lamb fetus weighs about 20 kilograms but should weigh only 3 or 4 kilograms. The cause of the excess weight can be seen to be the marked edema that was present throughout the body. The cause of this Anasarca is not really known but some consider it due to malformation of lymphatic vessel drainage of the skin.

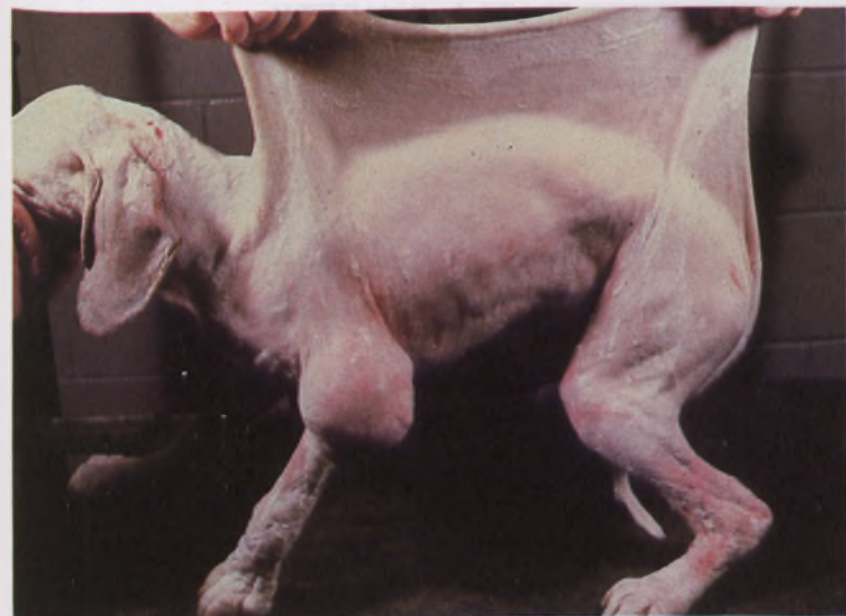

PLATE 2: CUTANEOUS ASTHENIA (DERMATOSPARAXIS)

The marked Asthenia shown by this dog's skin is a congenital disease caused by a defect in the formation of collagen. Several different species have similar skin lesions but they are not all necessarily due to the same defect in the collagen. Asthenia (meaning weakness) is also to be noted by the large rounded mass which is filled with fluid over the dog's elbow. This, a greatly distended bursa, is the result of trauma to the skin and underlying soft tissue over the bones in this area. The term Dermatosparaxis has been used for the condition in cattle but some think it is a better term for the entire group of similar diseases in all species. Collagen in other tissues may also be affected.



PLATE 3: DWARFISM

These two Hereford cattle are several years old but only about 4 feet tall. Their bloated condition along with their short stature and relatively normal conformation suggests what they are, Dwarfs. The wings of the orbitosphenoid or orbitopalatine bones would be seen bulging into the calvarium if the skulls were opened and the brains removed. The cause is probably genetic. The cause of the bloat is not known but it is a quite consistent feature in dwarfism.

Mr. R. Lindamood, Oklahoma, USA



PLATE 4: DWARFISM

This preserved cat head is from a five year old cat. It has the facial appearance of a kitten. This is considered to be a Pituitary Dwarf.

Dr. R. Minor, Cornell, USA



PLATE 5: DYSPLASTIC ANTLER DEVELOPMENT

One branch of this Sika deer's antler is shorter and more crooked than the other. The pathologist on duty told the students to make sure they examined the opposite hind leg for bone fractures. This caused much disbelief but the necropsy showed a deformed healed fracture of the tibia in the opposite hind leg. Dr. Robinson of Texas A & M has been studying this problem for years. It apparently is not a hormonal problem but rather a purely mechanical one from the lack of proper shaping of the antler by the animal on the inside of the opposite thigh when the leg is broken. It is well described in the lay press.

Dr. L. Roth, Oklahoma, USA

PLATE 10: FITTING EDEMA

Several decubital sores are present on the legs of this dog but the primary reason for showing the picture is to demonstrate the pitted depressions in the medial limb just above the hock. The entire leg is edematous as the result of generalized lymphatic

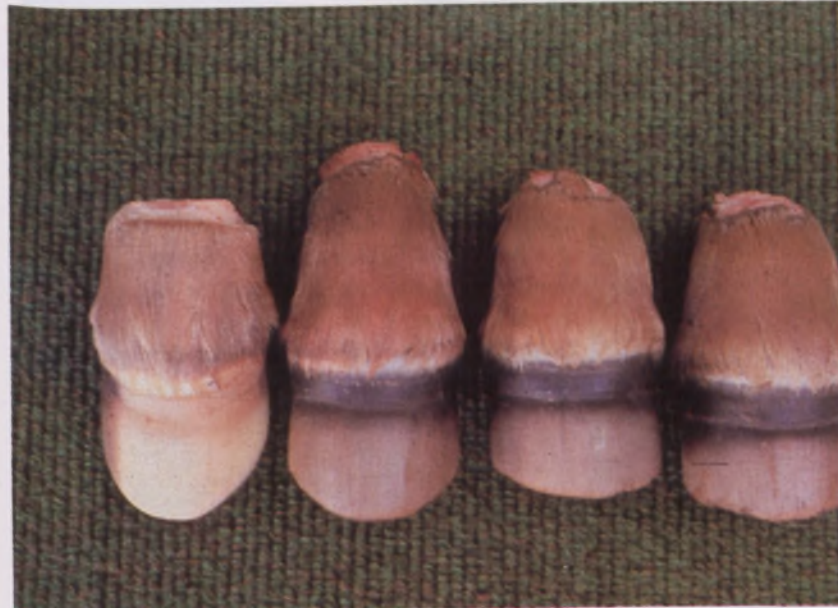

PLATE 6: HOOF WALL DYSPLASIA

The four horses feet shown here all show an approximately 1cm line of Hoof Wall Dysplasia, the result of a chronic infection elsewhere in the body that has been present for sometime. Dr. Mark Walter, Cornell, states that a normal horse's hoof wall grows about 0.54mm. per day. Using this as a rough approximation this foal has been ill about six months. Chronic malnutrition can also cause this lesion.

Dr. L. Roth, Oklahoma, USA

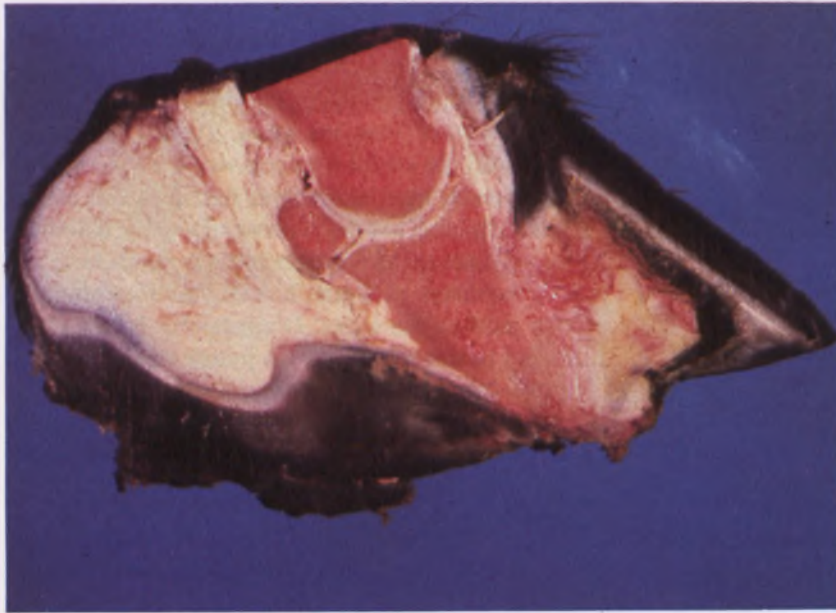

PLATE 7: CHRONIC PODODERMATITIS (FOUNDER)

The hemisectioned hoof shown here demonstrates the ventral rotation of the third phalanx (Coffin bone) away from the hoof wall. This case is an extremely chronic one as the triangular space between the wall and the coffin bone is filled with a large amount of necrotic debris and granulation tissue. At the proximal edge of the hoof wall, the dark hoof wall material itself is proliferating and making an attempt to grow down along the coffin bone to make a new wall. Sudden grain overload or cold water intake as well as other stresses may cause this, but its exact pathogenesis is still to be elucidated. A recent outbreak affected 16 of 17 horses treated with an oral vermifuge and three or four died. One had lesions like this in the fore feet and the rest had foundered with less severe lesions but recovered with treatment. Ponies get a similar lesion from pounding pavement and it is called Road Founder.

Dr. I. Lowe, Cornell, USA



PLATE 8: EMACIATION

The extreme wasted condition of this little pig is called Emaciation. It can be due to anything that causes an animal not to eat over a long period of time so that it utilizes its own muscle for vital nutrition. Marasmus and Cachexia could also be used to signify this severe debilitated condition. If it is due to a lack of food, thus a lack of calories, it is Starvation. If it is due to an imbalance of nutrients it should be called Malnutrition. A strict line of demarcation is not always possible. Chronic disease or malformations may also be causative.

37 猪
5910 C组
(饲料)40天+23天(正饲料)
120日龄
66年5月18日

Dr. F. M. Wu, Taiwan, R.O.C.



PLATE 9: EMACIATION FROM MALABSORPTION

This very thin dog is emaciated as the result of an intestinal problem that did not allow the dog to absorb its food properly. Many things including parasites, partial intestinal obstructions, metabolic diseases of the bowel and even allergic bowel diseases can cause this state of emaciation. In cattle, a common cause is Johne's Disease. One of the authors has a female of the same breed as in the picture which has severe diarrhea whenever she eats bread, pastry, dry dog foods or canned mixed dog food containing any of the common cereal grains. She can only eat pure meats or soybean derived dog foods to keep her from having diarrhea. This disease in the author's dog is thought to be Celiac Disease caused by a sensitivity to gluten but this has not been proven as yet.

any disease having a high fever including the use of
 Vegetarian Diets.

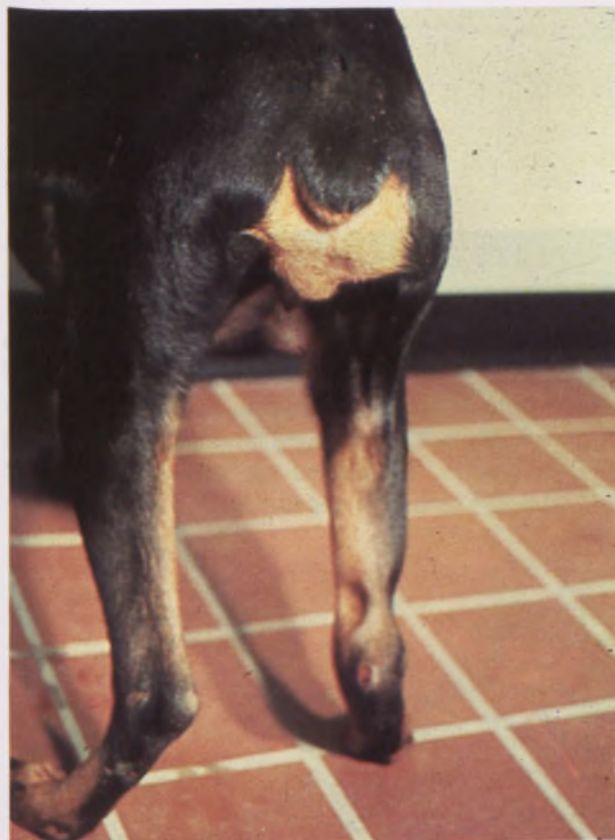

PLATE 10: PITTING EDEMA

Several decubital sores are present on the legs of this dog but the primary reason for showing the picture is to demonstrate the pinched depressions in the swollen limb just above the hock. The entire leg is edematous as the result of generalized lymphosarcoma which had infiltrated the sublumbar nodes and blocked lymphatic drainage from this limb causing edema of the limb. By thumb and finger pressure the fluid was forced out of the immediate area as shown. This is called Pitting Edema. It will suffuse back in with time.

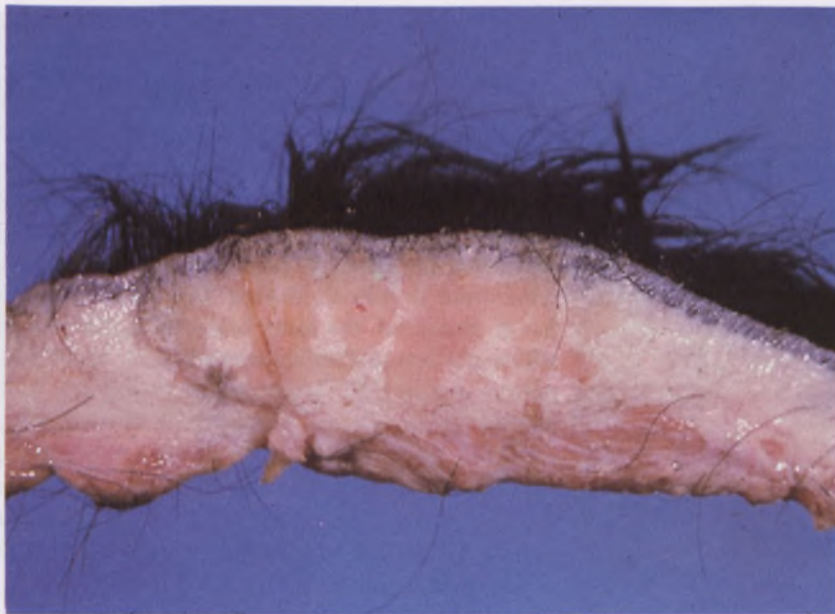

PLATE 11: METAPLASTIC BONE

This is the forehead skin from a 2-year-old bull. The more flesh colored material in the more opaque white subcutaneous tissue is dense bone and when boiled out, looked very much like white coral. It is an example of Metaplastic Bone which developed as a result of the bull apparently butting his head against hard structures. It was in no way intimately attached or contiguous with the skull proper. Metaplastic bone can be seen in almost any tissue wherever previous damage has occurred and the metabolic conditions are right for its development.

Dr. J. Lowe, Cornell, USA

PLATE 10: PITTING EDEMA

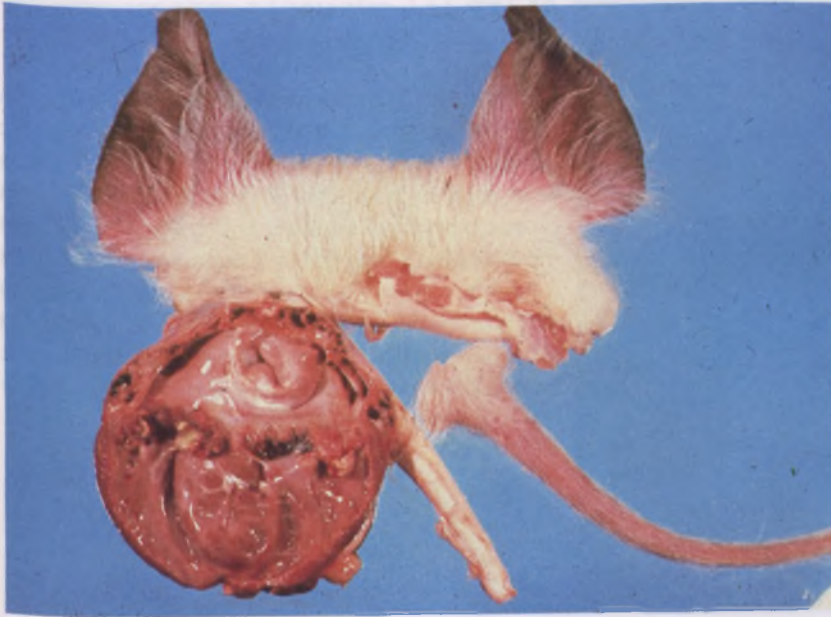Several decubital sores are present on the legs of this dog but the primary reason for showing the picture is to demonstrate the pitted depressions in the swollen limb just above the hock. The entire leg is swollen and the result of generalized lymphatic obstruction which indicated the underlying cause.



PLATE 12: ALLERGIC (PENICILLIN) DERMATITIS

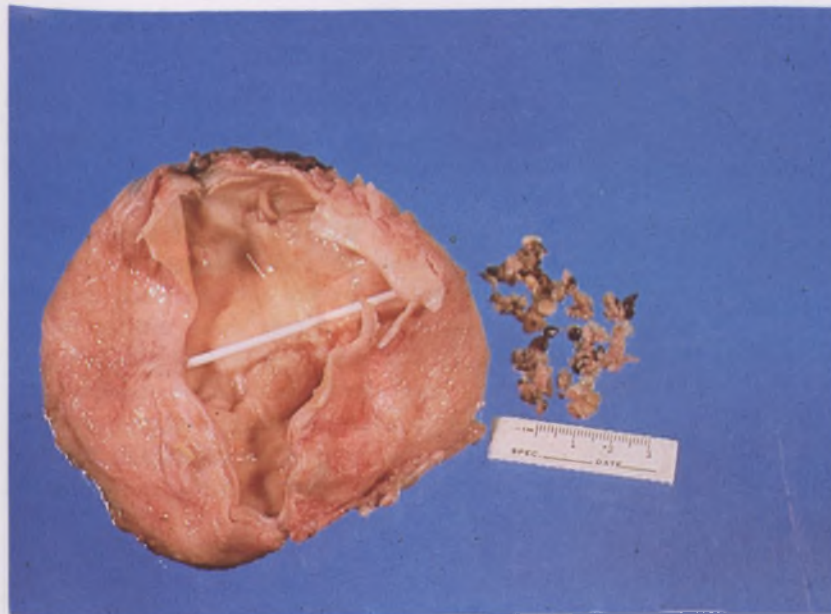
This cow with the still acute, raw appearing lesions and the more chronic, healed lesions is suspected of showing a severe skin hypersensitivity reaction to penicillin used in prolonged intramammary infusions for mastitis. She cleared up fairly well soon after penicillin treatment was stopped.

Dr. P. W. Wu, Taiwan, R.O.C.



**PLATE 13: EAR AND TAIL
INFARCTION**

The dark purple tips of the pig's ears and its purple tail are probably the result of a neurogenic vasoconstriction associated with fever and not the direct result of emboli from the Vegetative Endocarditis shown. Several reasons suggest this, and one is that these ear and tail lesions are commonly associated with the heart lesion, however emboli to other areas in the central nervous system are not common but should be if such were the case. Secondly, the tail and ear lesions are often associated with any high fever disease, even without Vegetative Endocarditis. It is also known that baby rats which are cold and wet get sloughing of the tail, digits, feet and even entire legs in an apparent attempt to maintain core temperature; a disease called Ringtail. This, the maintenance of core temperature, is the suspected mechanism in pigs with any disease having a high fever including this one of Vegetative Endocarditis.



**PLATE 14: CHRONIC TRAUMATIC
CARPAL BURSITIS
(HYGROMA)**

The large, thick walled cystic mass with smaller pieces of amorphous debris lying beside it is a Hygroma, the dilated serum filled bursa over the carpus of a cow caused by trauma to the area. The small pieces of debris are clumps of fibrin and blood which were part of the initial inflammatory process and now can be called Bursal Sand.



Dr. R. Boggs, Pennsylvania, USA

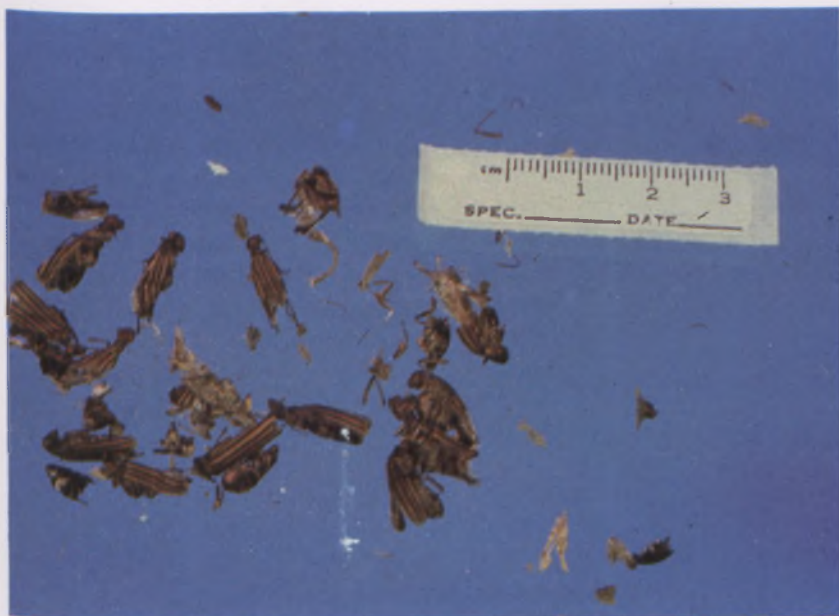PLATE 15: CHEMICAL (FERTILIZER) DERMATITIS

The skin lesions scattered on the back of this Holstein bull were treated for a long period as a mycotic dermatitis even though both molds and bacteria were seen in scrapings. It finally proved to be a caustic burn from fertilizer which was stored above the stanchion where the bull was actually kept while it grew up. A hole in the roof allowed rain water to soak down through the fertilizer. It is not always easy to be definitive clinically and many things must be considered with such skin cases before a definitive diagnosis can be made.



PLATE 16: EPICAUTA SPP. (BLISTER BEETLES)

Scattered throughout this handful of baled alfalfa hay are numerous 1-2cm squashed carcasses of *Epicauta* spp., one member of a genus of Blister Beetles that produce Cantharidin, a severe surface blistering agent. It is a Disease of Progress as cattle, sheep and horses eat these squashed beetles with the hay processed by the new machines. The new crimping machines squash these beetles in the hay just as it is being cut so that the hay dries faster. In the older times before crimpers the beetles would all leave the hay after it was cut and while it was drying. Their caustic effect in fatal cases is seen as ulcerative gingivitis, gastroenteritis, and toxic renal tubular injury.



**PLATE 17: BLISTER BEETLES
(*EPICAUTA* SPP.)**

The many carcasses and pieces of insects shown are Blister Beetles, *Epicauta* spp. These, along with Spanish Flies and Russian Flies, all produce a severe blistering agent called Cantharidin. These insects often swarm on alfalfa and if the alfalfa is cut and crimped, these insects are often crushed along with the plant stems. Cattle, horses or other species that eat these often die as a result of the blistering effect in the gastrointestinal tract and urinary tract.



PLATE 18: CHRONIC ERGOT POISONING WITH EXTREMITY GANGRENE

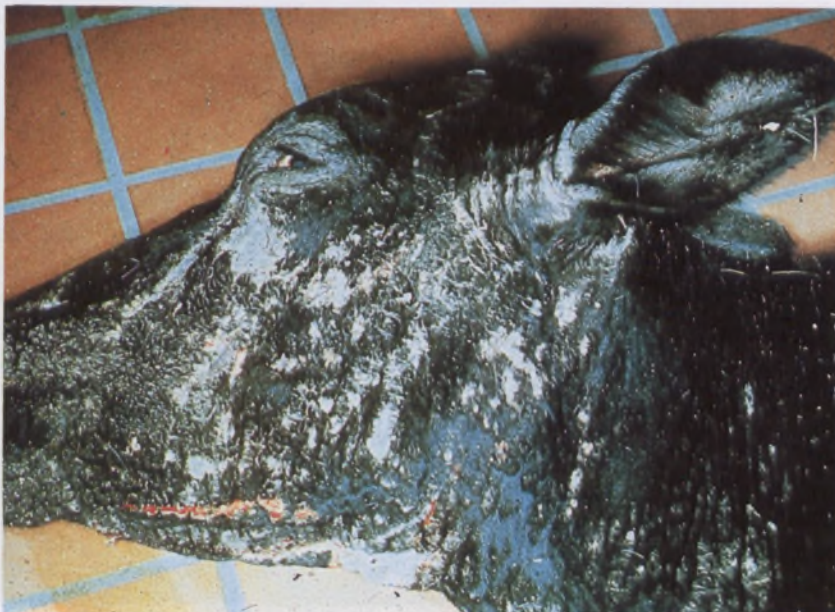The tips of the ears, the end of the tail and the both hind feet have been sloughed off or are in the process of being sloughed. This is the result of Chronic Ergot Poisoning. Ergot is from the fungus *Claviceps* spp. which grows on rye grass as a black elongated mass (sclerotium) in place of one of the seeds or grains of the plant. Alkaloids in the ergot apparently act on the smooth muscle of the blood vessels causing vasoconstriction to the point of ischemic necrosis with resulting dry gangrene to the affected parts. Chronic Fescue Poisoning (Fescue Foot), Chronic Seleninosis, and Frostbite must also be considered in such cases.



Dr. C. Pinello, Cornell, USA

**PLATE 19: *CLAVICEPS PURPUREA*
(ERGOT) ON RYE GRASS**

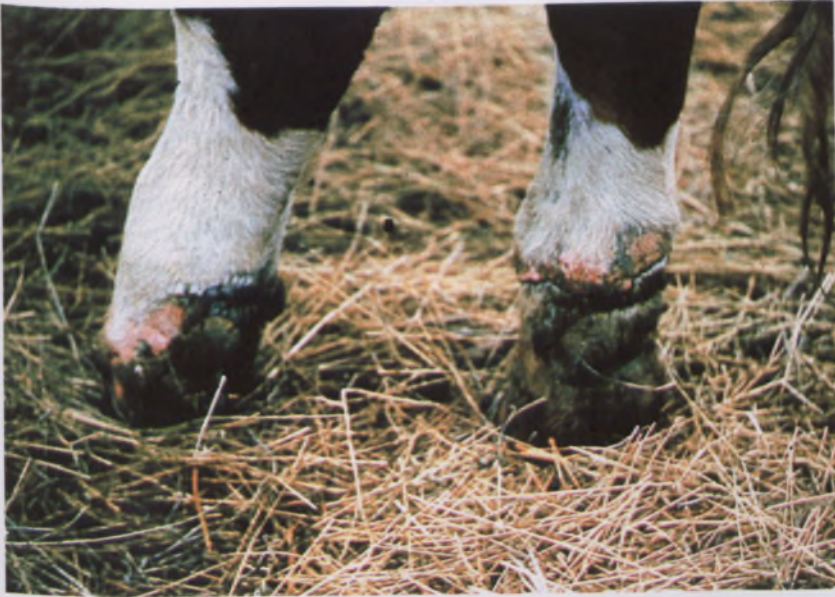The dark, elongated bodies replacing some of the seeds and lying free are the sclerotiae of *Claviceps purpurea*, a fungus on the rye plant. Each or all sclerotium when ground up can be called Ergot and contain the active alkaloids that in animals can cause abortions but more likely will cause distal extremity gangrene with loss of the ears, tail and feet by chemical constriction of the local blood vessels.



Dr. L. Kintner, Missouri, USA

**PLATE 20: *CHEMICAL (VICIA SPP.)*
DERMATITIS (VETCH
*POISONING)***

The cow with this severe skin lesion of the head and neck is suffering from Vetch Poisoning, caused by *Vicia* spp. Similar lesions can be seen elsewhere on the body but other diagnostic features may include markedly enlarged, firm adrenal glands (adrenomegaly) and pale spotted kidneys. The renal lesion is an interstitial nephritis while the adrenal is a marked adrenalitis. In our opinion, the adrenal gland is more consistent than the skin lesion in Vetch Poisoning. The toxic principle has not been identified and not all vetch is toxic.



**PLATE 21: DIGITAL GANGRENE
(FESCUE FOOT)**

The distal portions of both hind legs in this cow are necrotic and have no sensation which allows such cattle to walk almost without pain. They are sensitive at first however. In time, the feet may slough off completely and the cow could walk just on protruding bones. This case of Chronic Fescue Poisoning cannot be differentiated from Chronic Ergot Poisoning or Chronic Selenium Poisoning without good histories and clinical workups. Even Frostbite in certain areas can be suspect.

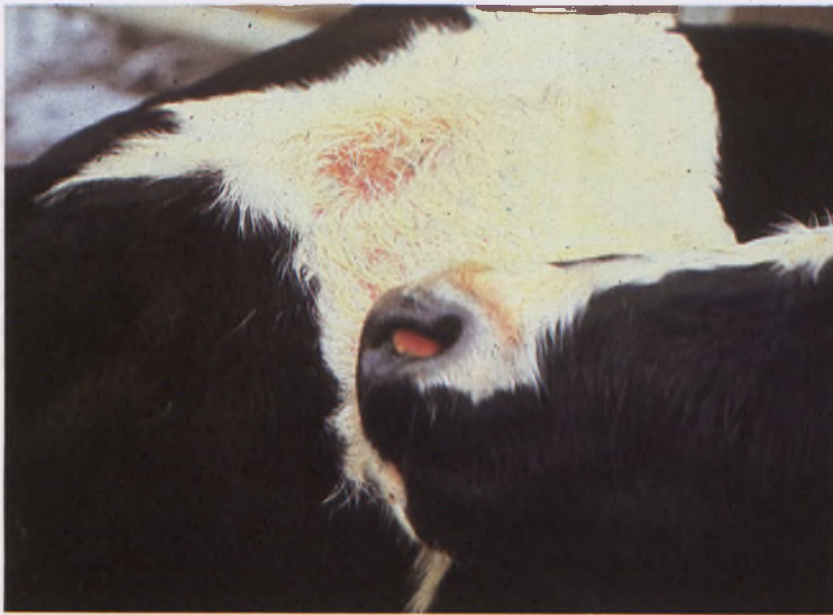Dr. S. Nelson, Missouri, USA



**PLATE 22: TOXIC (*CROTALARIA* spp.)
ALOPECIA**

The extreme condition of Alopecia (hair loss) in this pig is the result of *Crotalaria* spp. poisoning. This is one of the several manifestations of this plant poisoning which also includes central nervous disease, hepatic injury and a lung problems in several animal species. Thallium poisoning could also be suspected.

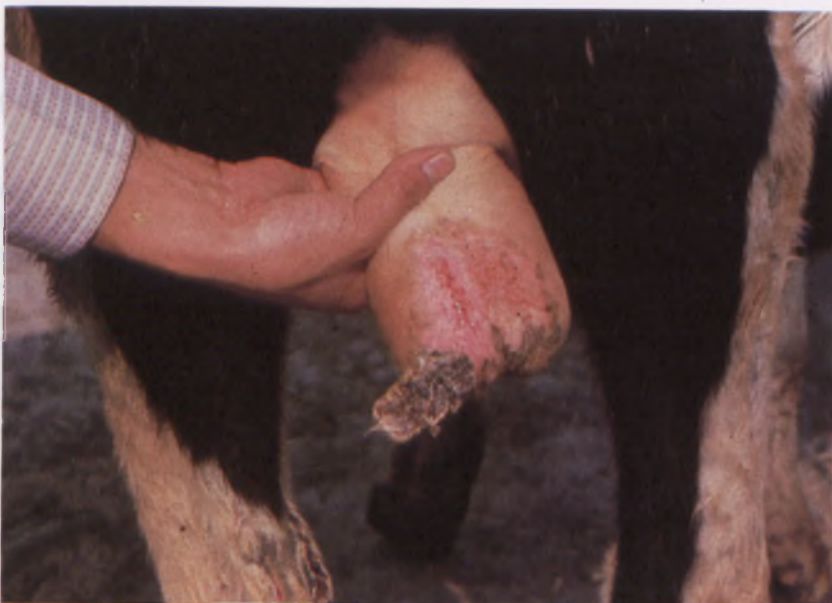Dr. H. Seibold, Georgia, USA



Dr. C.I. Liu, Taiwan, ROC

PLATE 23: LANTANA CAMARA PHOTOSENSITIZATION

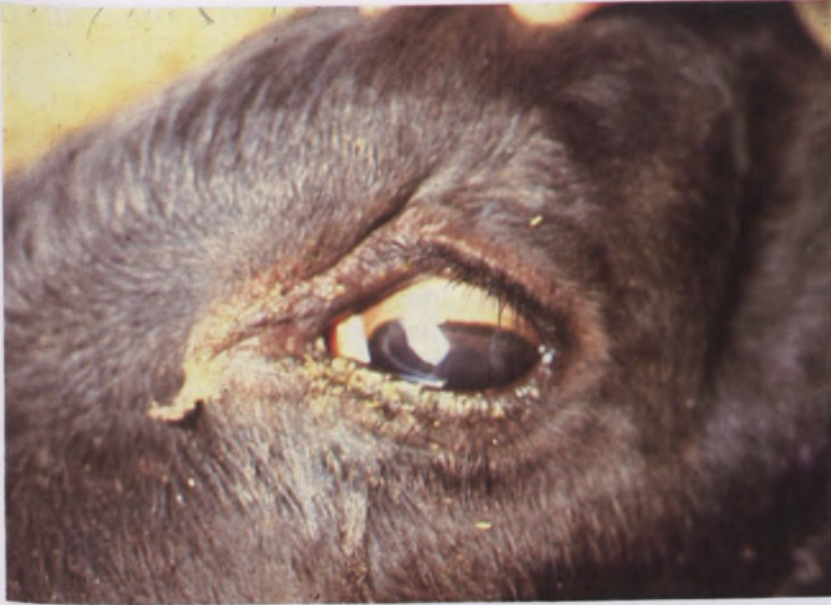The red yellow moist areas of the white haired skin and inside the nose of these cattle are inflamed as a result of Photosensitization caused by *Lantana camara* poisoning. A liver lesion was present to account for this Secondary Photosensitization. The inflammatory dermatitis being in these areas of white, unpigmented skin should make one suspect a photosensitization as these areas are not as well protected from the sun or strong light as are those areas with melanin.



Dr. C.I. Liu, Taiwan, ROC

PLATE 24: HEPATOTOXIC (LANTANA CAMARA) PHOTOSENSITIZATION

The white skin of the scrotum and of this bull's hock shows a marked dermatitis as the result of liver damage caused by *Lantana camara*. The actual cause of the skin lesion in photosensitization is due to the light activating certain fluorescent pigments in the cells of the skin. Most of these fluorescent pigments are breakdown products of hemoglobin or chlorophyll. A congenital defect in porphyrin metabolism can result in photosensitization as can liver disease as in this case of *Lantana camara* Poisoning and finally the ingestion or some other method of obtaining preformed photosensitizing pigments such as with blood transfusion. Again the white skin, that which isn't protected by melanin, is the most severely affected. In some cases the ventral part of the body appears more affected than the dorsal areas and this is explained by the reflection off shiny ground surfaces or even wet grass.



**PLATE 25: TOXIC (LANTANA CAMARA)
JAUNDICE**

The yellowish discoloration of the conjunctiva, Icterus, and the yellowish dried tears around the eye of this cow are the result of *Lantana camara* poisoning. This plant has caused liver necrosis which resulted in this Icterus or Jaundice.


Dr. C.I. Liu, Taiwan, ROC



PLATE 26: LANTANA CAMARA

This plant, *Lantana camara*, is the cause of liver disease and photosensitization in cattle and sheep.


Dr. C.I. Liu, Taiwan, ROC



**PLATE 27: USED MOTOR OIL TREATED
FENCE POST (LEAD
POISONING)**

The large splinter from a buried end of a fence post does not show much except dark staining of the wood. As is often the case, this is all with which the clinician might be presented with. This is one of many posts which had been cut then upended to soak in a drum of used motor oil for its possible preservative qualities. Cattle had access to the lead from the used motor oil by licking the posts stacked on the ground before they were used. Numerous cattle are killed by lead yearly in this fashion.

Mr. J. Ebel, Cornell, USA



**PLATE 28: TAXUS SPP. (JAPANESE
YEW)**

The twigs and berries shown here were found in the stomach of a horse which died suddenly. No lesions were seen in the horse grossly or microscopically. This was the entire quantity obtained after the horse had only one or two mouthfuls from an ornamental *Taxus cuspidata* (Japanese Yew) that it stood near while a door was being opened to lead it into the barn. Other experimental horses were fed varying amounts from the same tree and it killed some and not others, demonstrating the great individual variation of animals in such cases.

Dr. M. Walter, Iowa, USA



PLATE 29: *MELIA* SPP.

These are the leaves and berries from a common ornamental tree, *Melia* spp., in South Africa and elsewhere that are quite toxic. They cause nonspecific lesions but after a rapid death these berries may be found in the pig's stomach. In one outbreak studied by one of us the problem occurred following a heavy wind that knocked down the toxic berries. This is one of many toxic agents that can cause death without lesions.

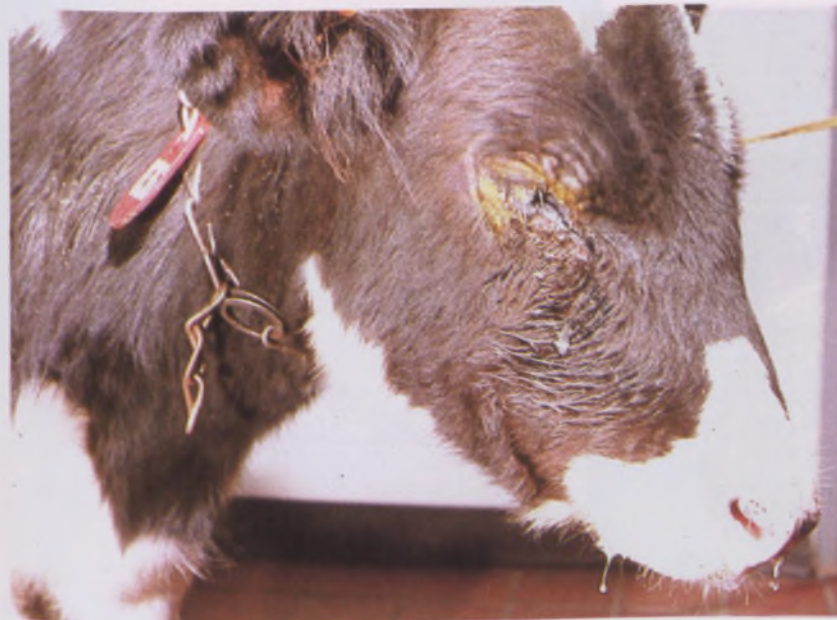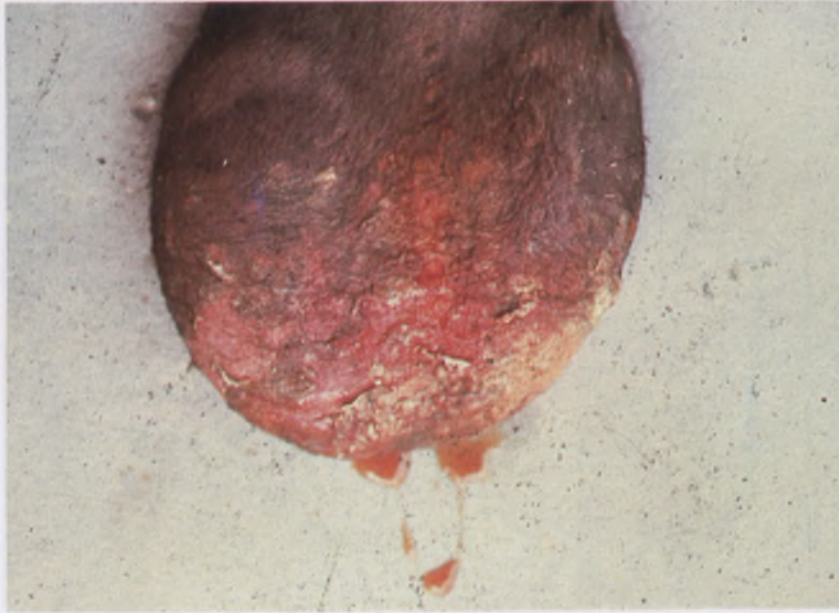


PLATE 24: ULCERATIVE, VIRAL (BOVINE VIRUS DIARRHEA) PODODERMATITIS

The marked interdigital ulcerative pododermatitis is the result of chronic Bovine Virus Diarrhea (BVD). Although not associated often in BVD it must be in

PLATE 30: VIRAL (BOVINE MALIGNANT CATARRH) CONJUNCTIVITIS

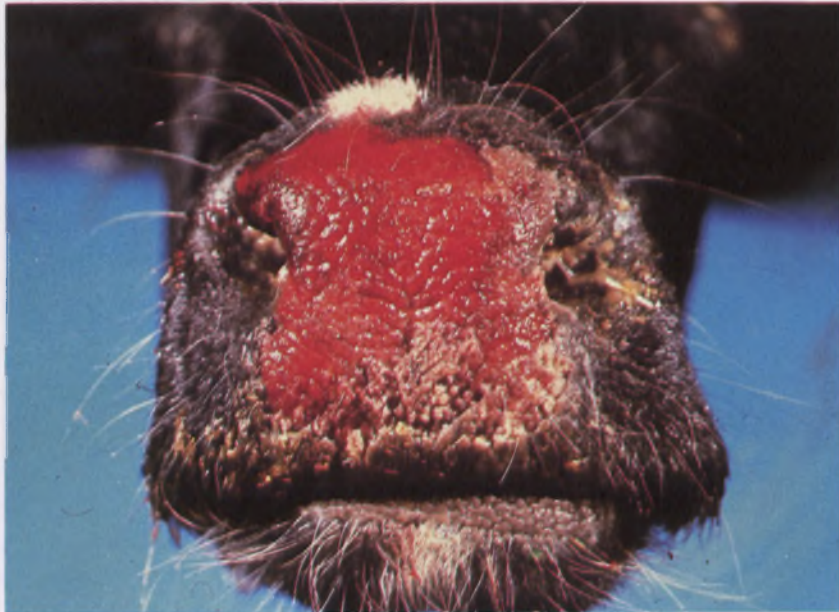This conjunctivitis is one of the three lesions commonly seen in animals with Bovine Malignant Catarrh (BMC) (Malignant Catarrhal Fever, MCF). The others include central nervous signs and a high fever. Grossly other lesions are also diagnostic.



Mr. J. Lutz, Cornell, USA

PLATE 31: VIRAL (BOVINE MALIGNANT CATARRH) DERMATITIS

The reddened, ulcerated surface of this bull's scrotum should make one also consider photosensitization or a chemical burn in addition to what it is, Bovine Malignant Catarrh (Malignant Catarrhal Fever). High fever, conjunctivitis and central nervous signs are usually seen in this disease clinically and generalized vasculitis, round cell (lymphocytes, plasma cells and monocytes) infiltration of the liver and kidney and a nonsuppurative encephalitis can be seen in most cases histologically.



Dr. M. Walter, Iowa, USA

PLATE 32: MALIGNANT CATARRHAL FEVER (MCF; BMC) DERMATITIS

The red nose on this cow is the result of having sloughed off the superficial epithelium as the result of Bovine Malignant Catarrh. Out of context, it could be considered a possible candidate for Bovine Virus Diarrhea and even Infectious Bovine Rhinotracheitis but the other lesions would be more definitive.

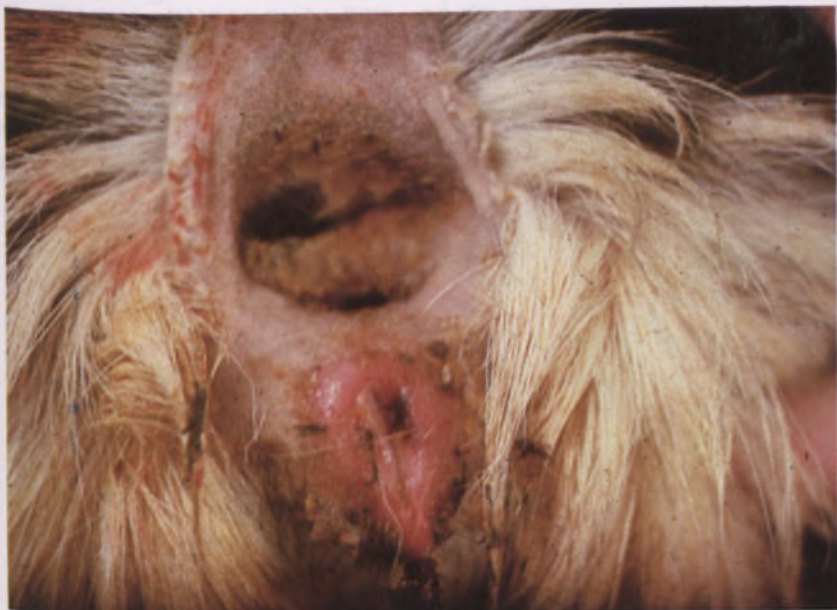

PLATE 33: VIRAL (MALIGNANT CATARRHAL FEVER) DERMATITIS

The well marked dermatitis around the anus and vulva of this goat along with the high fever, conjunctivitis, central nervous system signs grossly, round cell infiltration of the liver and kidneys, marked generalized vasculitis and nonsuppurative encephalitis histologically all tend to confirm the diagnosis of Malignant Catarrhal Fever. This goat as well as several cattle posted by us over the years also had very definitely pale, swollen coronary vessels grossly and marked vasculitis microscopically.

Dr. T.H. King, Kansas State University, Manhattan, Mo.

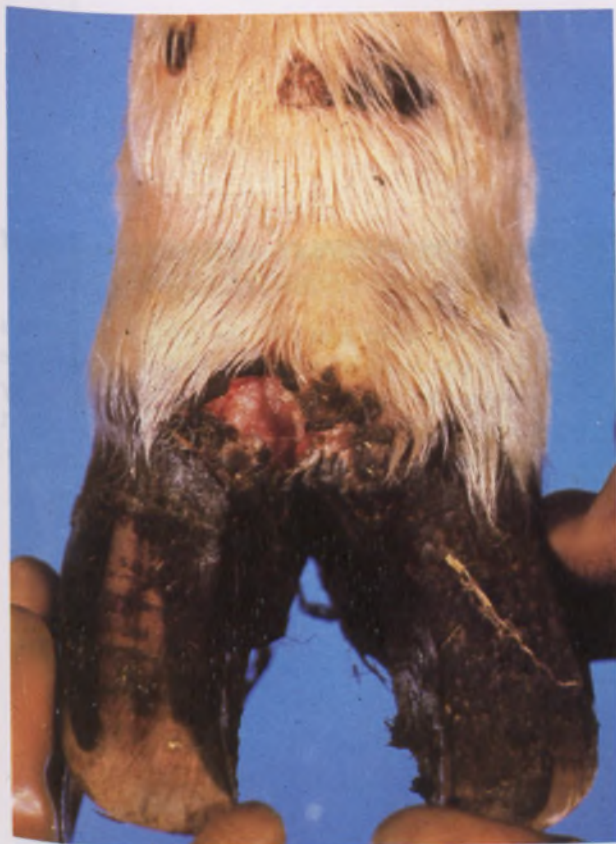

PLATE 34: ULCERATIVE, VIRAL (BOVINE VIRUS DIARRHEA) PODODERMATITIS

The marked interdigital ulcerative pododermatitis is the result of chronic Bovine Virus Diarrhea (BVD). Although not seen too often in BVD it must be in the list of differentials when it is seen. By itself it could just be a case of early Foot Rot.

Dr. C. B. Anderson, Kansas State University, Manhattan, Mo.

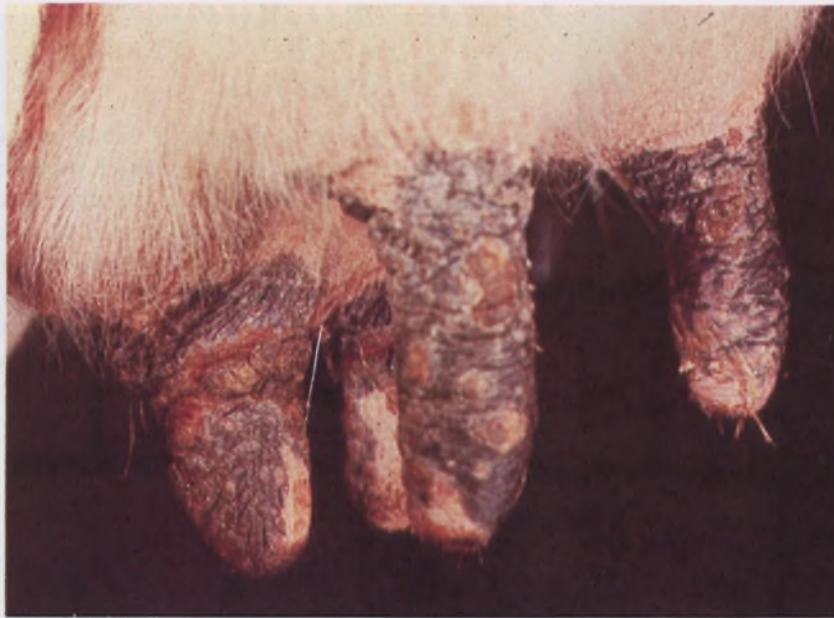

PLATE 35: VIRAL (BOVINE VIRUS DIARRHEA) THELITIS

The ulcerative lesions on the teats of this cow are the result of Bovine Virus Diarrhea. They are not often seen but can be in some cases. The other mucosal diseases also must be considered.

Dr. R. Whitlock, Pennsylvania, USA

PLATE 36: ULCERATIVE VIRAL (BOVINE VIRUS DIARRHEA) PODODERMATITIS
The marked interdigital necrotic pododermatitis is the result of chronic Bovine Virus Diarrhea (BVD). Although not seen too often in BVD it must be

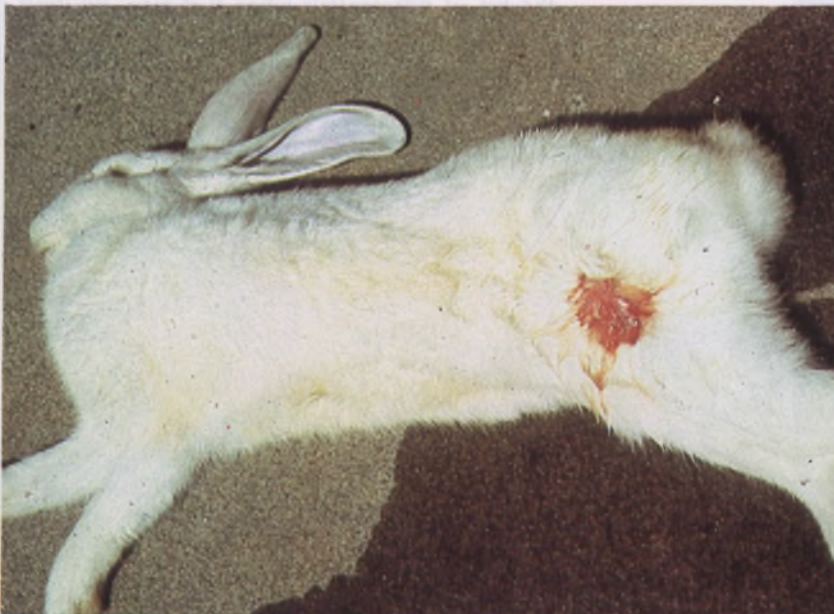
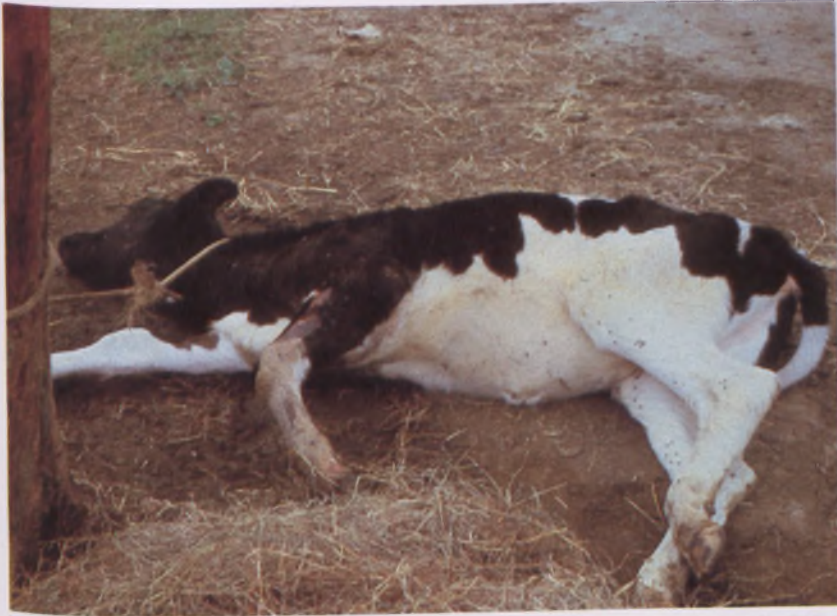
PLATE 36: DERMAL TRAUMA FROM SELF MUTILATION

The bloody moist area near the side of this rabbit's stifle is the result of self mutilation as this was the injection site for material from pigs subsequently proven to be infected with Pseudorabies. The rabbit is the animal often used for this diagnostic technique.

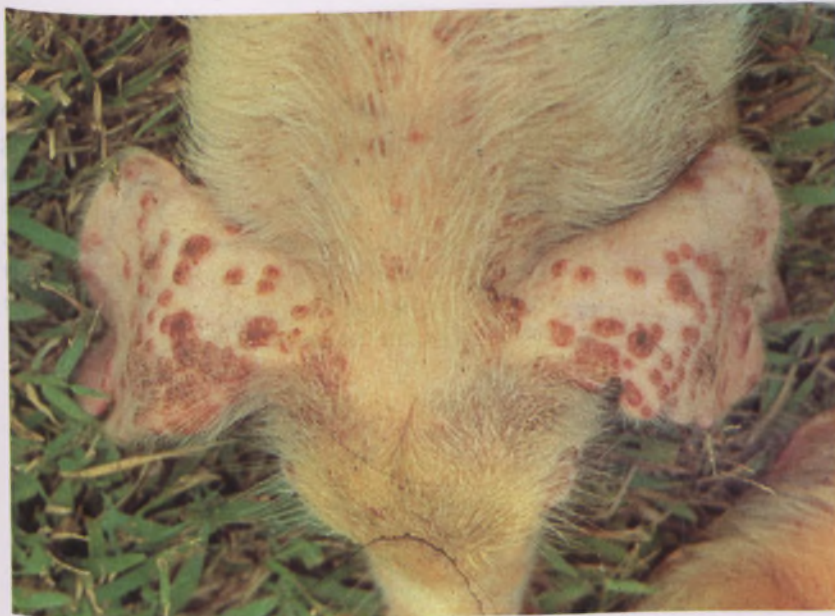Dr. C.I. Liu, Taiwan, ROC



**PLATE 37: TRAUMATIC DERMATITIS
OF AUJESZKY'S DISEASE**

This cow has just died as a result of Pseudorabies, a virus disease usually contracted from swine, the more likely nonsymptomatic carrier of this herpesvirus. The large area on one front leg is devoid of hair and ulcerated as a result of the cow constantly rubbing the area. This latter clinical activity or sign helps give the common name of Mad Itch to the disease in cattle, sheep, dogs and other animals.

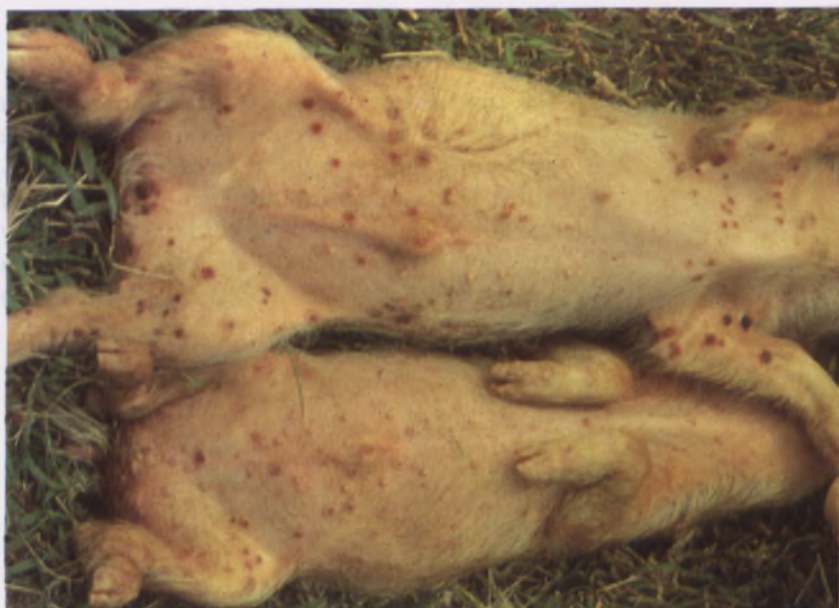Dr. T.H. Wang, Tansui, Taiwan, ROC



**PLATE 38: VIRAL (SWINE POX)
DERMATITIS**

The multiple lesions on this pig's ears are the classical lesions of Swine Pox, a specific viral disease of swine. The lesions can be seen all over the body in many cases.

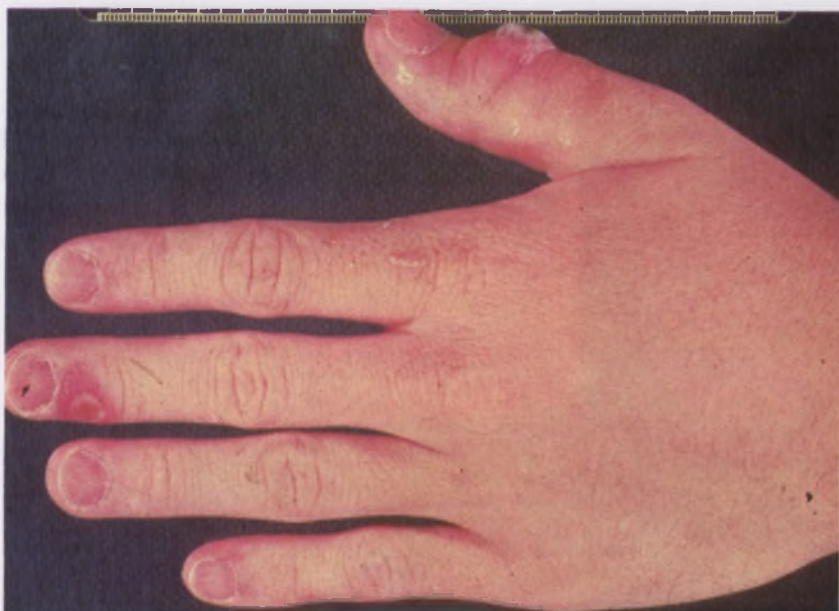Dr. C.I. Liu, Taiwan, ROC



**PLATE 39: VIRAL (SWINE POX)
DERMATITIS**

These are classical pox lesions caused by Swine Pox Virus. The typical slightly elevated lesions with a central portion slightly discolored is what one often looks for, but doesn't always find, in pox diseases in general.

Dr. C. I. Liu, Taiwan, ROC



**PLATE 40: CONTAGIOUS ECTHYMA
(ORF)**

This veterinarian had handled a group of sheep about 10 to 14 days prior to having two itching sores on this hand. This is a photograph 21 days later when they were warm, sore and itchy. The sores disappeared a few days later. Orf or Contagious Ecthyma is a virus disease usually of sheep and goats which is contagious to man. It usually affects the teats of ewes and the mouth of lambs.

Dr. G. Gibson, Cornell, USA



PLATE 41: SCRAPIE

This sheep is one of several in a flock that had a tendency to stand and scrape themselves against any firm surface. When they die the only lesion other than their traumatic ones from scraping are the presence of vacuolated neurons, mainly in the medulla oblongata. This is a viral disease and is of contemporary interest because of its relationship to a human disease, Kuru. Its long latent period and other viral qualities makes it a unique viral disease.

Dr. D. Baker, Cornell, USA

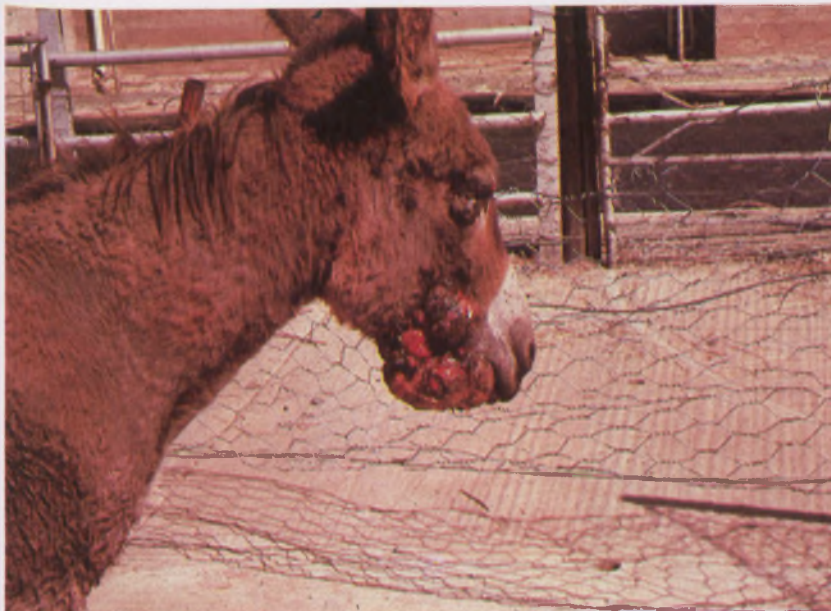

PLATE 42: EQUINE SARCOID

The bleeding masses around this donkey's eye and lips are the result of a viral infection, probably transmitted by flies or other insects. These are Equine Sarcoids and can easily be implanted to other areas of the same animal by contact. A junctional zone between affected and nonaffected areas must be looked at histologically to show the tumor like infiltration of the rete peg area to distinguish this from a fibrous tumor or granulation tissue for both of which it can and often is easily mistaken.

Dr. G. ...



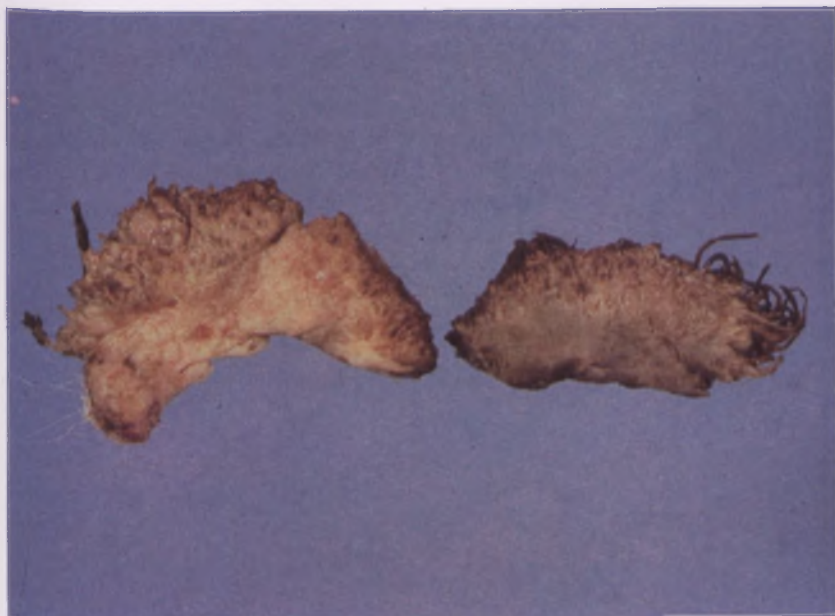
PLATE 43: EXUBERANT GRANULATION TISSUE

This horse had an eighty pound mass of mature granulation tissue removed from the wire cut area of its leg. This is an example of Exuberant Granulation Tissue. For some unknown reason the horse is more likely to form excess granulation tissue following injury than most domestic species. It is often difficult to distinguish this from an Equine Sarcoid.

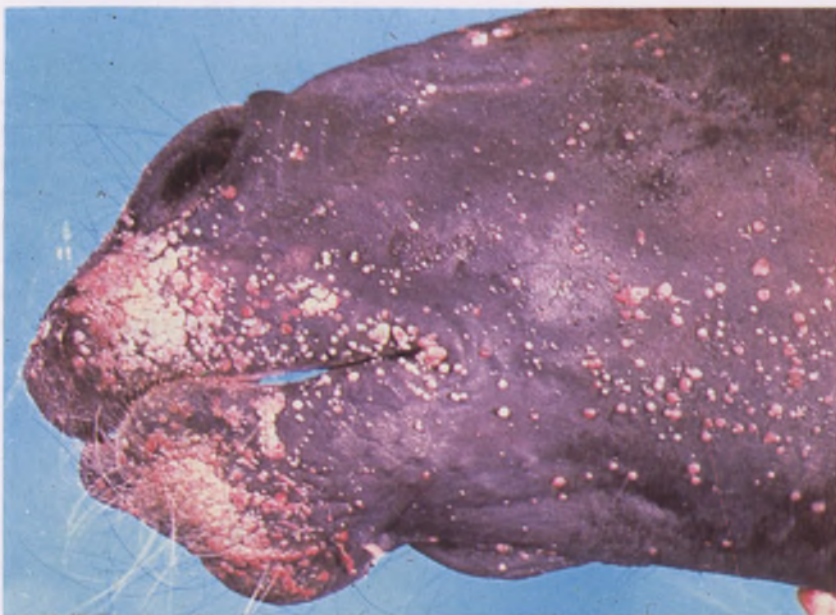

PLATE 44: CUTANEOUS PAPILLOMATOSIS (WARTS)

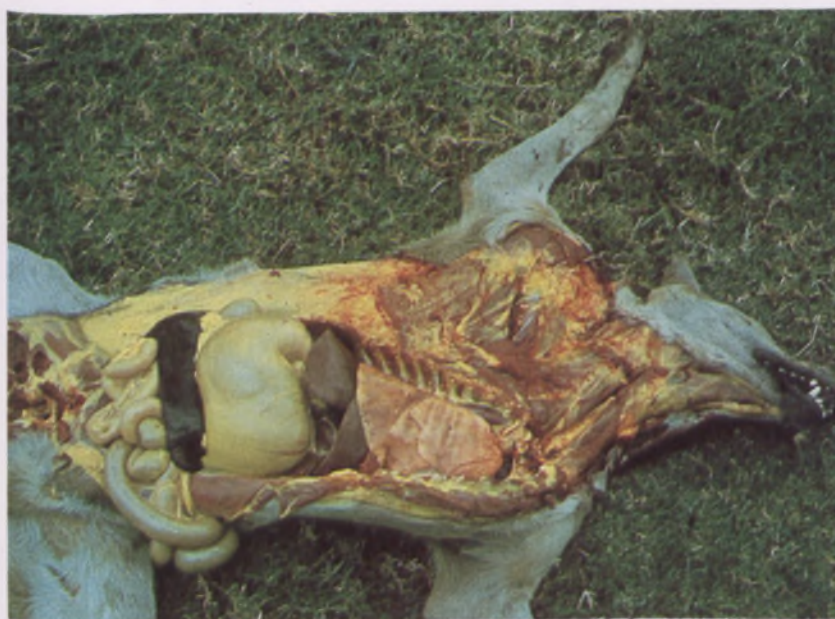The many small masses on the skin of this horse's face are Warts or Cutaneous Papillomas. These viral induced benign tumors are seen in many species and can become significant by being so profuse that they may obstruct sight in wild animals or even cause starvation in cases where they are located in the mouth or esophagus. They usually regress spontaneously.



Dr. W. Rebhun, Cornell, USA

**PLATE 45: INTERDIGITAL WARTS
(PAPILLOMAS)**

These irregular masses are Interdigital Warts from cattle. Many dairy animals were affected in several herds with this problem which was characterized by extreme pain in the affected foot. Histologically, these consisted primarily of marked hyperkeratosis and some acanthosis. Many mature cattle on a sporadic basis get interdigital calluses which usually are not painful nor do they occur as spot outbreaks as these do. A virus is the suspected cause. Their relationship to the common Warts usually seen on or about the head and neck is not known.



Dr. G. Appel, Kenya, Africa

**PLATE 46: ICTERUS AND SPLENO-
MEGALY**

This dog is extremely jaundiced (icteric) as a result of a protozoal disease, Babesiosis, caused by *Babesia canis*. The spleen is also enlarged. Anemia with slightly less icterus should make one think of AIHA (Autoimmune Hemolytic Anemia). Leptospirosis cases can also be this icteric but they will have renal disease. Infectious Canine Hepatitis (ICH) cases can also be as icteric but the liver lesion should be helpful. Neither Leptospirosis nor ICH will have appreciably enlarged spleens. Many hemolytic and hepatic toxins may cause icterus as severe as this.

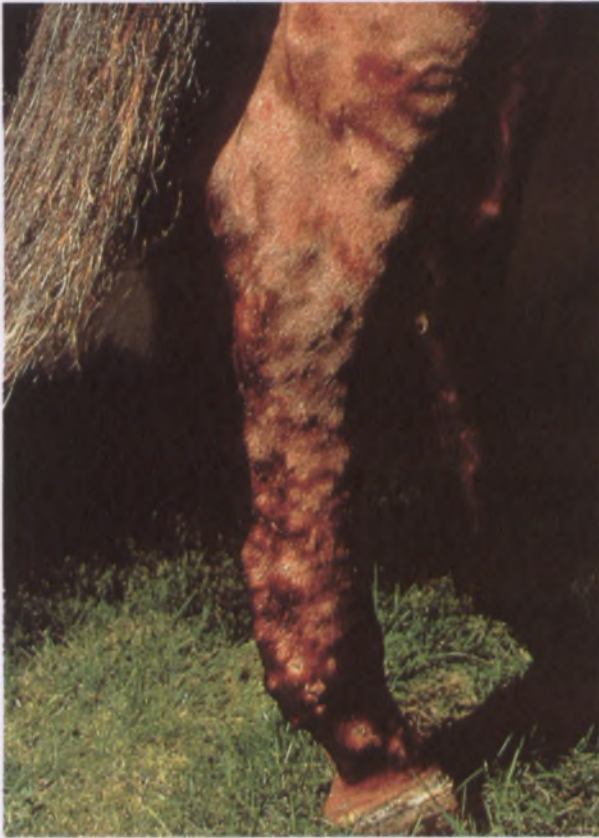

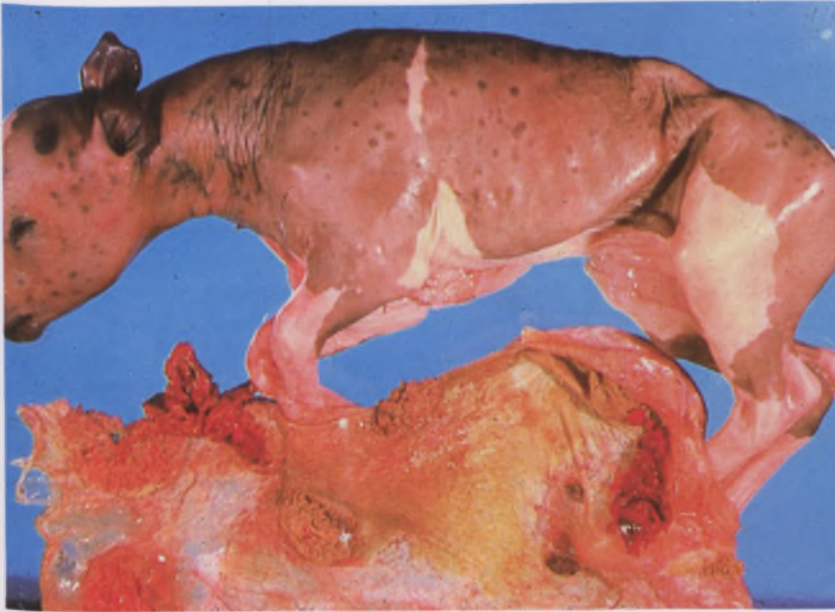PLATE 47: MYCOTIC (*SPOROTRICHUM SCHENKII*) DERMATITIS

The multiple nodules in the skin of this horse are pus filled abscess pockets along the cutaneous lymphatica. Many are ulcerated or are in the process of becoming so. The cause is a fungus, *Sporotrichum schenkii* and the disease is called Sporotrichosis. It is most common in horses. Chronic phlegmon (cellulitis) and Cutaneous Glanders (Farcy) may appear like this. Cultures are necessary for an accurate diagnosis.



PLATE 48: MYCOTIC DERMATITIS

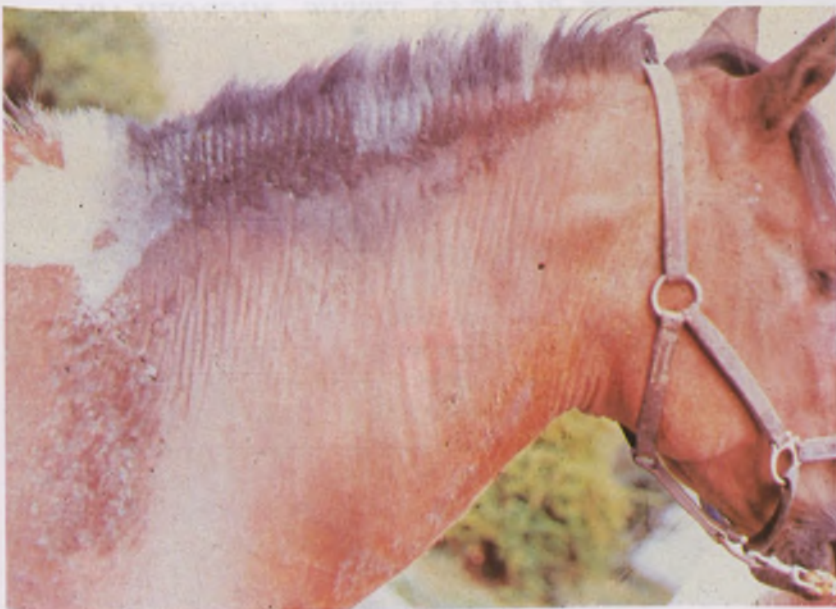The thick, patchy dermatitis seen in this young bull is the result of a severe mycotic infection. It is a common disease in many species and is often associated with warm, wet conditions. Polar bears in the zoo suffer from this quite commonly. While molds such as *Aspergillus* spp. and many others can cause this type lesion. A common bacterial agent, *Dematiophilus congolensis*, cannot be excluded from the differential diagnosis without checking for it specifically by smears and cultures.



Dr. D. Cordes, New Zealand

PLATE 49: MYCOTIC DERMATITIS AND PLACENTITIS WITH ABORTION

Scattered on the calf fetus are dark, slightly raised foci of Mycotic Dermatitis. The placenta is normally clear in some areas, but it is tan and thickened in others. The red cotyledons are essentially normal but their tan thickened rims are affected with mold. The yellowish tan centers of some cotyledons should not automatically be considered mycotically infected as they could represent recently detached cotyledons with its expected early autolysis. This Mycotic Placentitis and Dermatitis is one of the most common known causes of abortion in New York State. Agents such as *Aspergillus* spp. and *Mucor* spp. are commonly isolated but *Mortierella* spp. is more commonly isolated in other countries such as New Zealand. Subsequent pregnancies are usually normal.



Dr. J. Bentinck-Smith, Cornell, USA

PLATE 50: ALLERGIC DERMATITIS (QUEENSLAND ITCH)

The relatively dry scaly lesions on the side of this horse's neck is the chronic resolving stage of Queensland Itch, a sensitivity reaction to *Simulium* spp. and *Culicoides* spp. It can be a very severe pruritic, weeping dermatitis when acute. It is possible that a sensitization to other biting insects may also be causative.

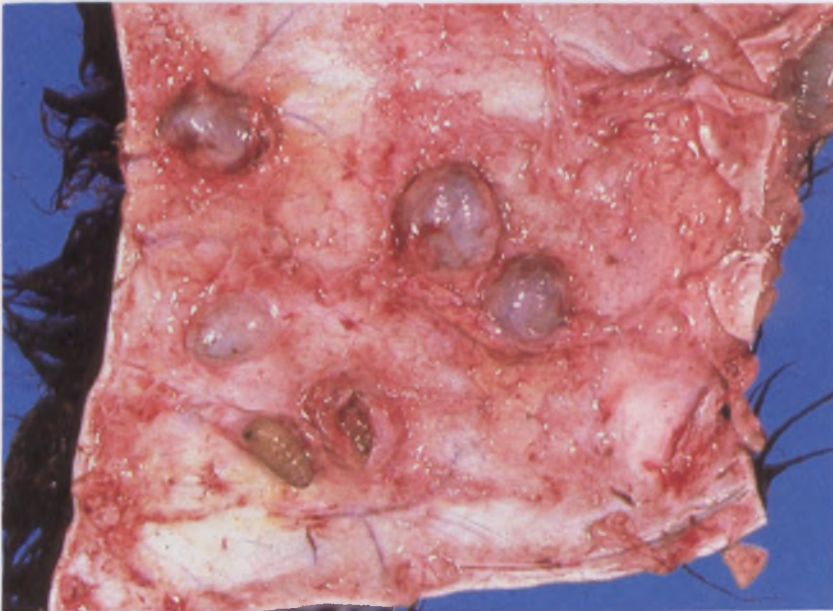


PLATE 51: CATTLE GRUBS (OX WARBLES)

The multiple nodules, one of which has been opened to release the parasite, are in the subcutaneous tissue of a cow. These are the developing larval stage of *Hypoderma* spp. One maggot (larval form) of this Ox Warble Fly has been cut out. These destroy a large part of the value of a cow's hide by direct damage as they make a respiratory opening in the skin that they later crawl out of and fall to the ground where they pupate. These are commonly squashed *in situ*, which on subsequent squashing of another grub may cause fatal Anaphylaxis. Similar parasites are seen all over the world and in other species, for instance, the Newfoundland Caribou with *Edemamagena tarandi*. *Hypoderma bovis* and *H. lineatum* are common in the U.S..

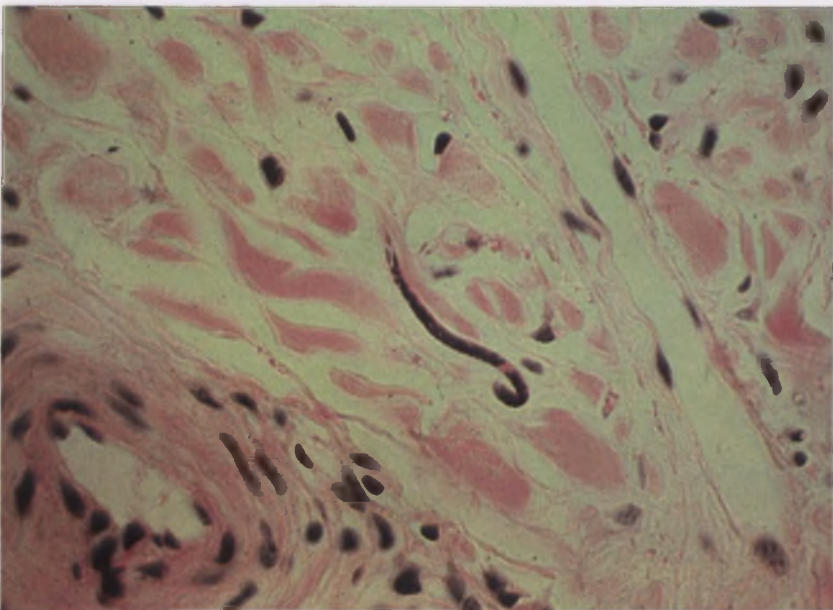


PLATE 52: TISSUE MICROFILARIA

Microfilaria, such as this long thin worm like structure, are the immature stage of many nematode parasites. These are seen in many species and it is difficult to identify them from the microfilaria alone. This one is the microfilaria of a horse with *Onchocerca* spp. *Setaria* spp., the abdominal threadworm also has microfilaria as do *Dirofilaria* spp., *Dipetalonema* spp., *Elaeophora* spp., and others. For the most part these microfilaria are usually found in skin lesions where they congregate in order to be picked up by their intermediate arthropod vectors or deposited there by them. It does not seem far from logical that they should congregate at certain areas possibly because of a tropism factor such as saliva deposited by the intermediate host. The location of the adult parasite is quite consistent for the species involved.

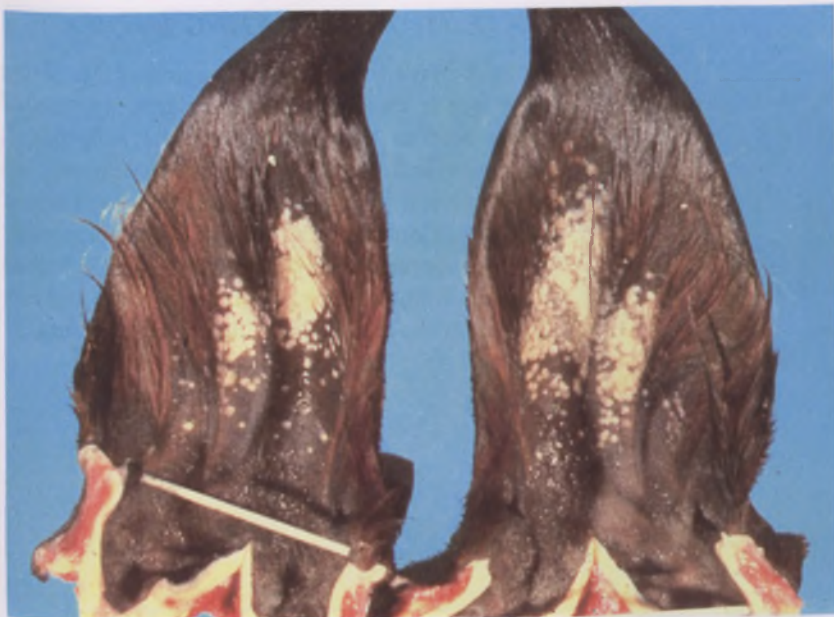


PLATE 53: PAPILLARY ACANTHOSIS

These areas of white plaque formation are on the inner surfaces of a horse's ears. They consist histologically of a marked focal acanthosis without any appreciable cellular response. It may be that a cellular response was there previously but there is no proof of this. One wonders if this may be a form of chloracne, but several different owners have said "they have never treated the horse's ears"

Dr. P. Olafson, Cornell, USA

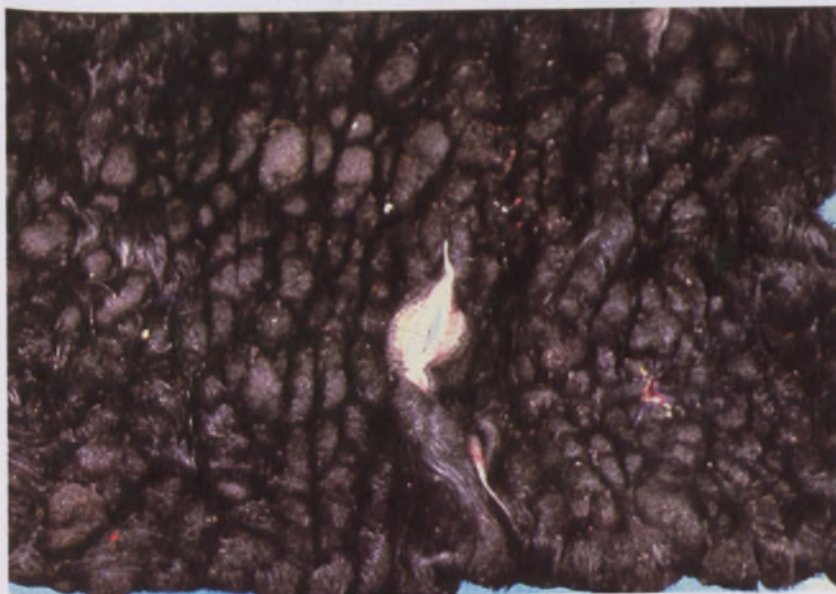


PLATE 54: MULTIFOCAL CUTANEOUS LYMPHOSARCOMA

The multiple lumps in this cow's skin are caused by the cutaneous infiltration of malignant lymphoid cells in this case of Dermal Lymphosarcoma. Lesions may or may not be elsewhere in the body. If they are present, the right heart, abomasal wall and uterine wall are likely target organs. These skin nodules were found all over the body of this cow.



PLATE 55: INFILTRATING LIPOMA

The large massive swelling on the side of this young cow's face is the result of a slow growing mass of mature adipose tissue infiltrating the soft tissues. The cow was in no pain and was not clinically affected except for its presence. Histologically it consisted of only mature adipose tissue completely normal in appearance. We have seen similar lesions in the hind limb muscles of cattle and dogs and one publication has named these Infiltrating Lipomas.

Dr. P. Dixon, Cornell, USA

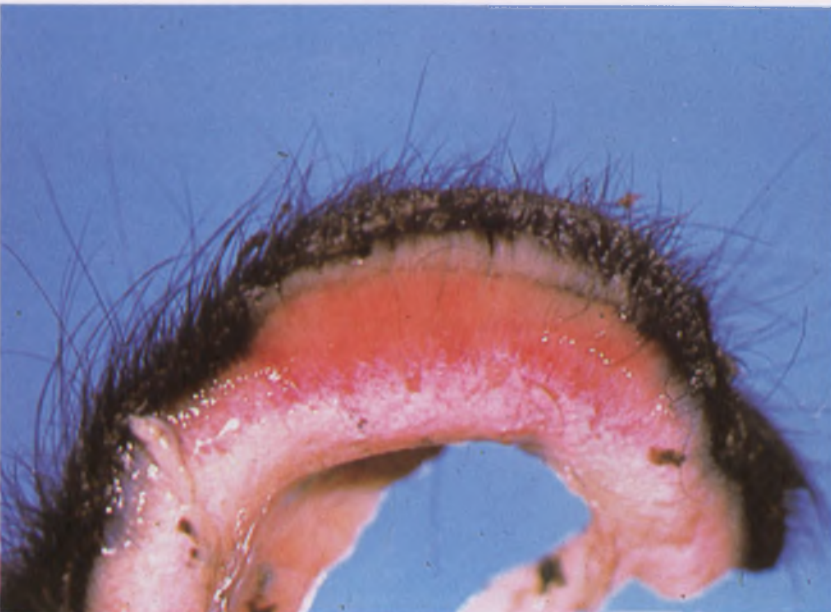
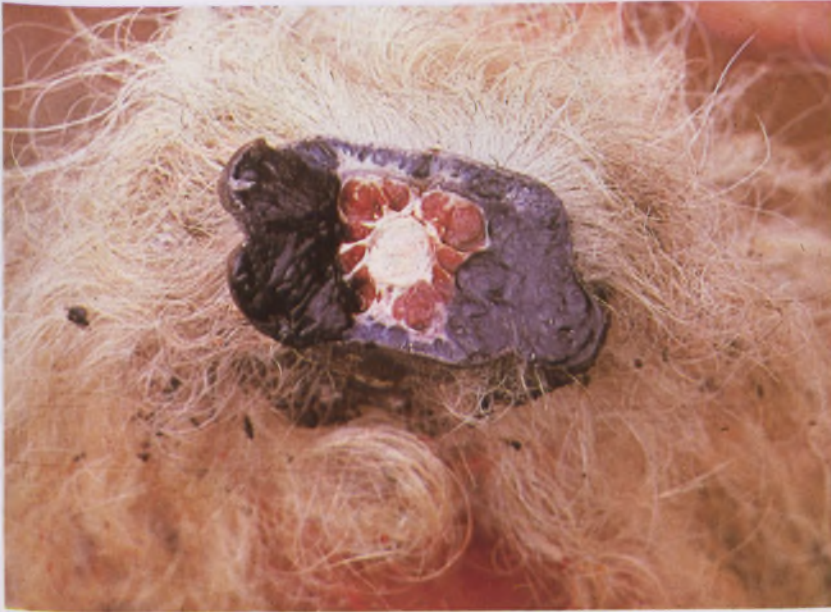
PLATE 56: CUTANEOUS LYMPHOSARCOMA

In this case of Lymphosarcoma in a cow, the pale outer zone in the hair and the inner reddish zone directly underneath have been infiltrated solidly with malignant lymphoid cells. Many of these were scattered in the cow's skin.

Dr. W. Mac, Cornell, USA



**PLATE 57: MELANOSARCOMA
(MALIGNANT MELANOMA)**

The skin and subcutaneous tissue around this cut off horse's tail shows the marked infiltration by a Melanoma, the most common tumor of older grey horses. It has a tendency for slow growth and local metastases to regional nodes. The pigment is water soluble and water based fixatives in museum specimens get darkened easily. These are also common in other species. In the dog however they are usually benign unless located in the mouth or on the feet.

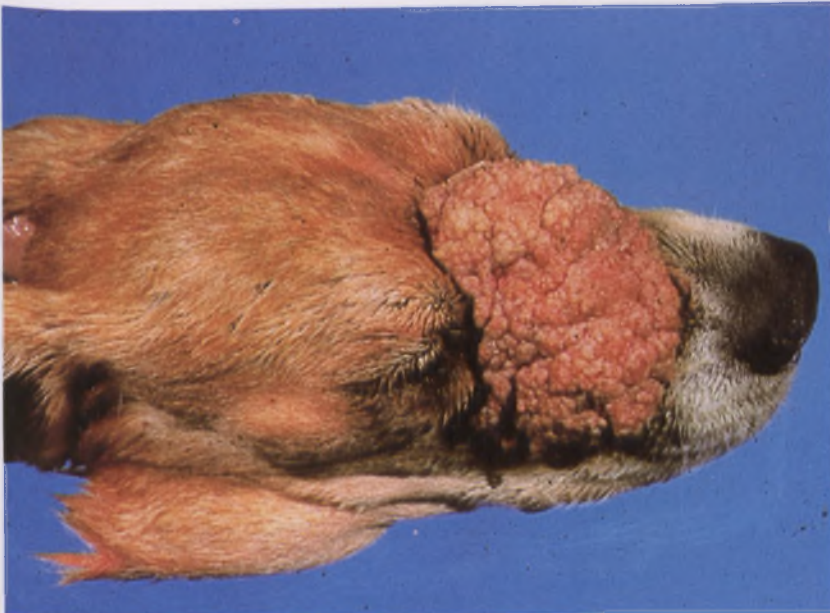


PLATE 58: FIBROSARCOMA

The large, fleshy, fungoid mass on this dog's nose can, out of context, be one of many tumors or even a fungal dermatitis. It turned out to be a typical Fibrosarcoma consisting of mature connective tissue which had eroded deeply into the underlying soft tissue and bone. Microscopic examination is almost always needed to be sure of the diagnosis.

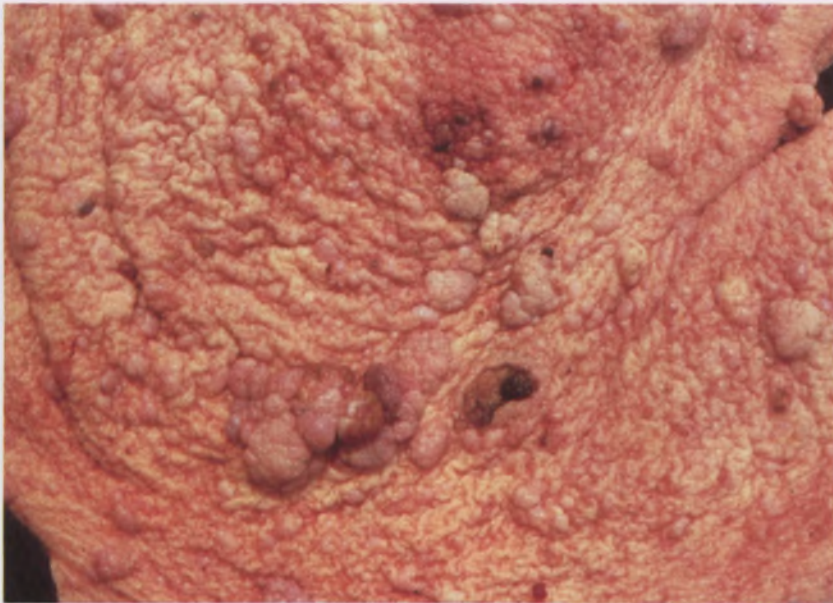


PLATE 59: SCROTAL ANGIOMATOSIS OF SWINE

These multiple pale to purplish nodules from 1-8 mm. are located on a mature boar's scrotum. They are thought to be more prominent in the warmer southern part of Taiwan than in the northern cooler area. They occur in boars 2½ years old and older and may get as big as one's thumb, 2-3cm. Their cause is not known. They get traumatized easily and bleed profusely. Histologically they consist of masses of thicker walled than normal capillaries and small arterioles. A relatively recent British paper describes them in cattle and we have also seen them in cattle. It is doubtful if these are true neoplasms. They have not been found as metastases in any other tissue and they don't appear to spread by infiltration locally.

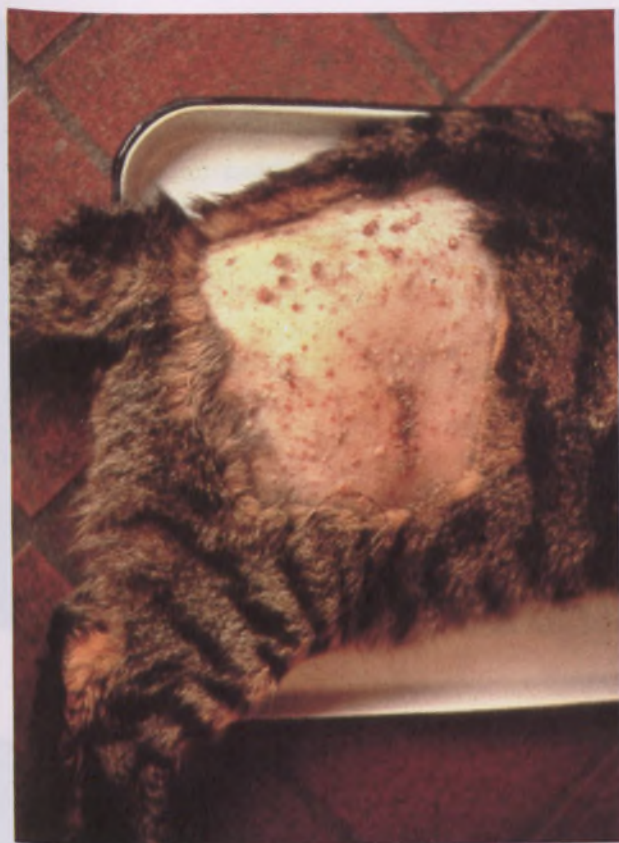Dr. F.M. Wu, Taiwan, ROC



PLATE 60: SCROTAL MAST CELL SARCOMA

The entire scrotum is shown with the two testicles from a dog. The testicles are normal which makes the scrotum comparatively enlarged. This is a case of a diffuse infiltration of the scrotum with a Malignant Mast Cell Sarcoma. The more common Mast Cell Tumor in the dog, found scattered on the body is usually a benign one and easily removed by surgery but those located on the scrotum, in the mouth or on the feet are usually of the malignant variety.

Dr. F.M. Wu, Taiwan, ROC



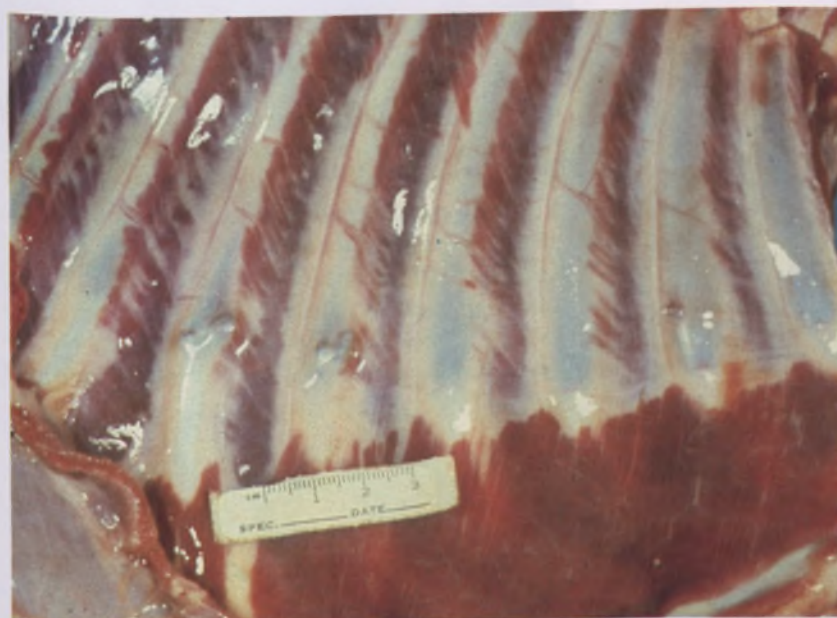Dr. J. Post, Connecticut, USA

PLATE 61: MASTOCYTOSIS

The large number of masses all over this cat, but especially seen in the shaved area are multiple Mast Cell Tumors. When multiple like this, the condition is usually called Mastocytosis and it can be seen in horses, cattle and other species. There may or may not be any internal neoplasms. Duodenal ulcers may sometimes be found in these cases.

**PLATE 66: HYPERTHYROIDIC
OSTEODYSTROPHY.**

The smaller plates of this young dog with hyperthyroidism show many of these and the swollen costochondral junctions are the primary lesions seen in this disease.



**PLATE 62: MULTIPLE CARTILAGE-
NOUS EXOSTOSES**

The several irregular, 0.5-1 cm masses on three of the ribs shown near their costochondral ends are Multiple Cartilagenous Exostoses in a dog. The disease is seen in several species especially, men, horses and dogs and it affects many different bones. At Texas A & M, Dr. Bridges had a colony of dogs with this disease. It probably is the result of small patches of perichondrium which persist in the periosteum instead of being completely replaced by it. Bone is then made abnormally in these areas to make these projections. If these projections are in areas of muscle and ligaments, the bony projections can cause mechanical damage to the muscles and tendons.

Dr. L. Knook, Cornell, USA

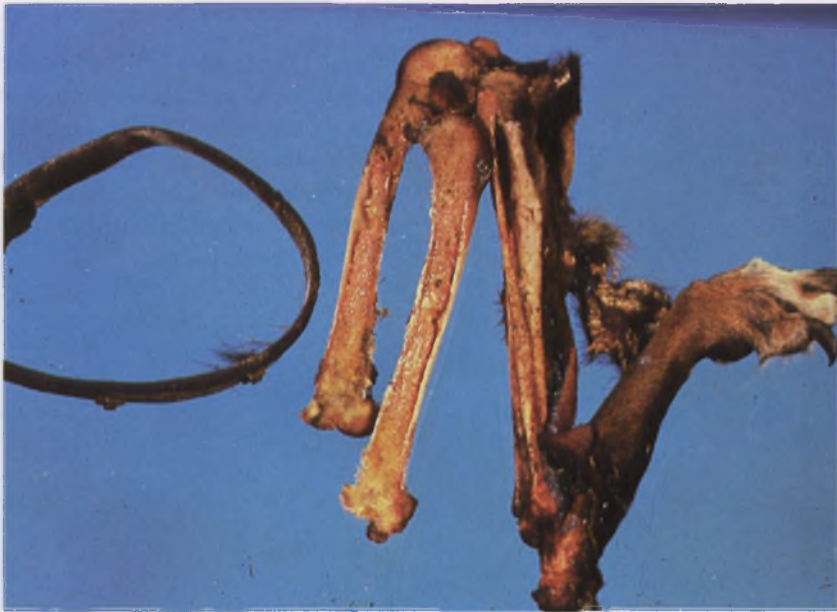

PLATE 63: FATTY BONE MARROW

This dog collar and legbones are all that were submitted for examination. The question asked was if the dog had died as a result of starvation. These bones had been lying around for several months in cool and even some warm weather. The split femur shows the marrow cavity to be relatively filled with fat marrow. This suggests that the dog did not suffer from chronic starvation. Of course there is a direct relationship to the initial amount of body fat in an animal, but in one small study done, bone marrow depletion of fat in a mature dog took over a month to show and it wasn't complete.

Dr. F.M. Wu, Taiwan, ROC

Dr. J. Post, Connecticut USA

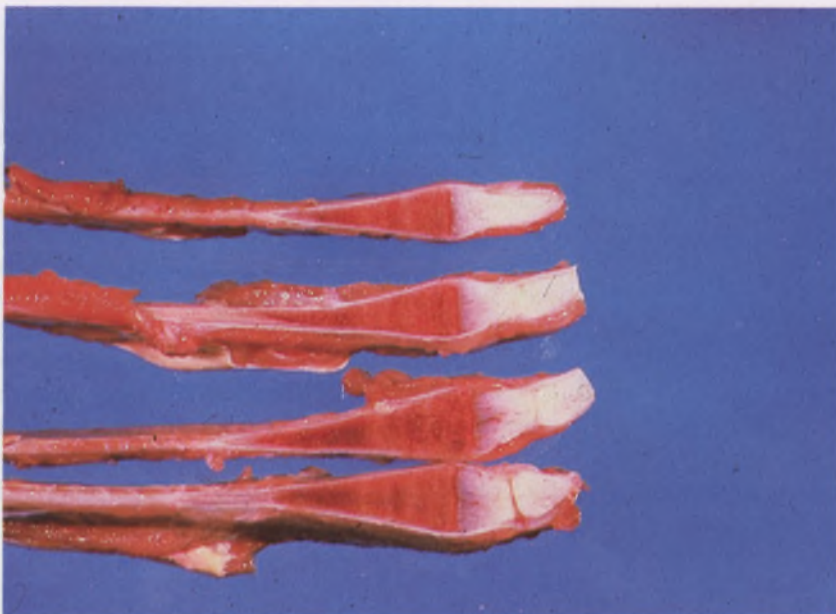


PLATE 64: MULTIPLE OSTEODYSTROPHIC LINES

The four longitudinally sectioned ribs of this calf show five rather distinct pale white zones in the bone just above the costochondral junction. One line is usually seen in this nutritional problem affecting all species and is the result of a vitamin/mineral imbalance. It is one of the best indicators in a carcass of such an imbalance. The five zones in this calf are a rare finding and suggests that the imbalance was a marked one for five short periods of time in this rapidly growing animal.

Dr. F.M. Wu, Taiwan, ROC

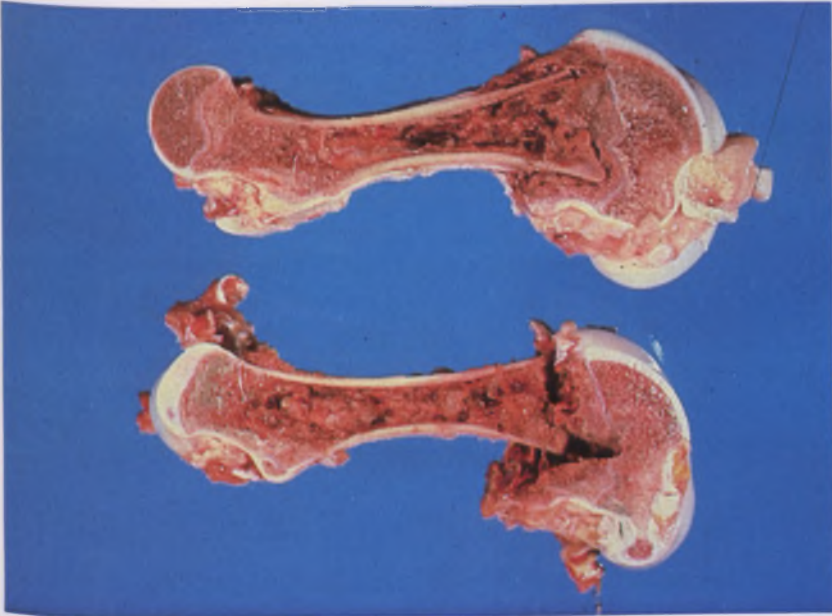


PLATE 65: RICKETS AND PATHOLOGICAL FRACTURES

These half sections of two femurs from a calf both show complete fractures of the diaphysis just above the distal epiphysis and both sides of the diaphysis appear to have been driven down into the distal epiphysis. This is a 5 month old beef calf that was never allowed out in the sun and these can be called Pathological Fractures as the result of Rickets. The simple definition of Rickets as a deficiency of Vitamin D probably should be defined more specifically. In many cases Rickets can be caused by a deficiency of Vitamin D due to lack of sunshine, however probably most natural cases of Rickets in the world, at least as far as animals are concerned, are due to Vitamin A excess, as Vitamin A is anti Vitamin D.

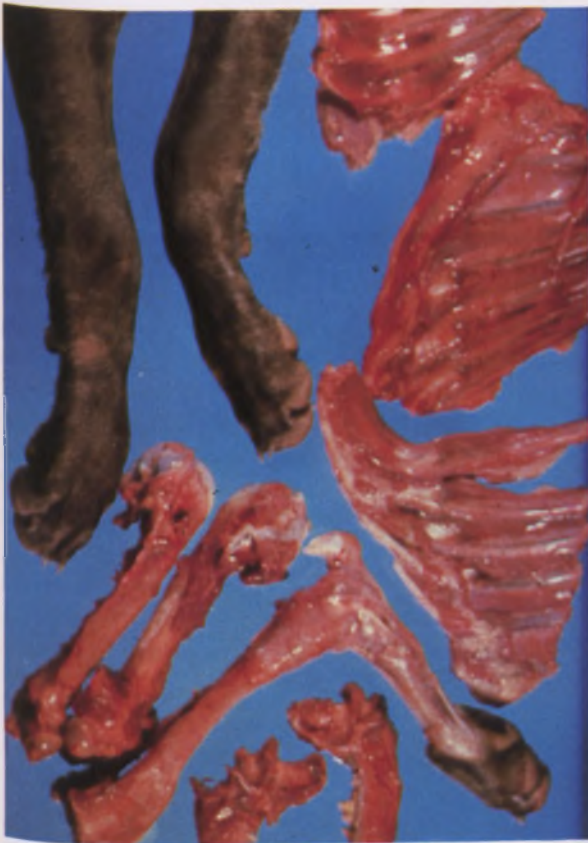
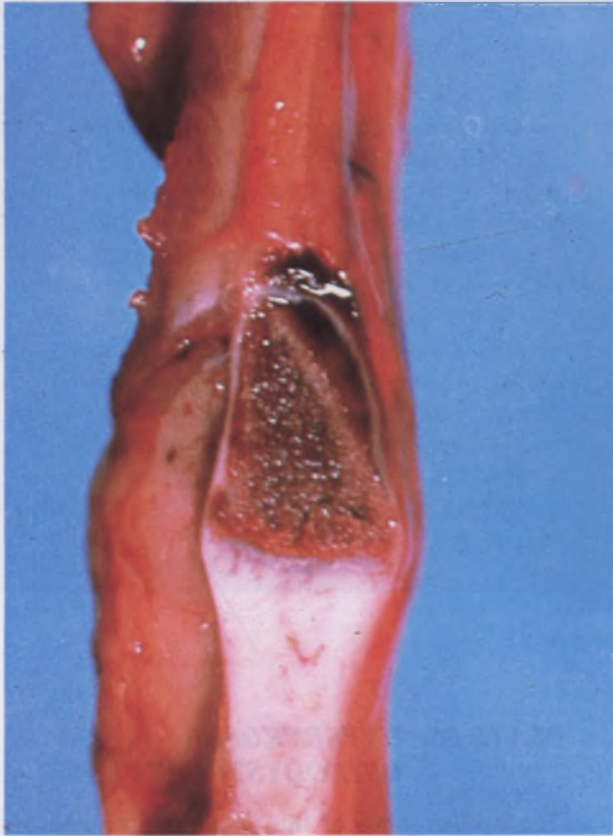
PLATE 66: HYPERTROPHIC OSTEODYSTROPHY

The swollen joints of this young dog with hemorrhage about many of them and the swollen costochondral junctions are the primary lesions seen in this disease called Hypertrophic Osteodystrophy. The joints of the dog are clinically painful and radiographically, loss of bone can be seen under the periosteum near the joints. Just changing the diet can cure most cases. The cause is not known although Vitamin C deficiency was at one time considered primary, but experiments at Cornell have tended to disprove this. This disease of Hypertrophic Osteodystrophy is to be differentiated from Hypertrophic Pulmonary Osteoarthropathy which is related to a tumor or mass of any type in the thoracic cavity or its content which results, in some unknown fashion, in multiple exostoses at the ends of most long bones and distal small bones. Similar exostoses may also be associated with tumors in the urinary bladder and other tissues without any in the lung.



Dr. A. Teare, Cornell, USA

**PLATE 67: HYPERTROPHIC
OSTEODYSTROPHY**

The elevated portion of periosteum by blood at the costochondral end of this rib, is one of the common findings of the disease, Hypertrophic Osteodystrophy. The exact cause is not known. The elevated periosteum here and around many of the dog's joints are the probable cause for the pain shown clinically in these cases. This is to be differentiated from Hypertrophic Pulmonary Osteoarthropathy which is a condition of exostosis at the ends of long bones associated with a space occupying lesion, usually tumors, in the chest cavity or its associated tissues. It is sometimes seen on flat bones.



**PLATE 68: NUTRITIONAL SECONDARY
HYPERPARATHYROIDISM**

The large swollen maxillary bones, Big Head, in this horse are the result of Nutritional Secondary Hyperparathyroidism and was caused by an abnormal diet. These are usually seen in cases where the horse eats an all bran diet which is high in phosphorus (Bran Disease). The histological lesion is one of bone loss, connective tissue increase and an increase of osteoid without mineralization, that is Fibrous Osteodystrophy. Cats, lions and other meat eaters can also get Fibrous Osteodystrophy from eating only meat which has a 30/1 phosphorus to calcium ratio.

Dr. C. Bridges, Texas, USA

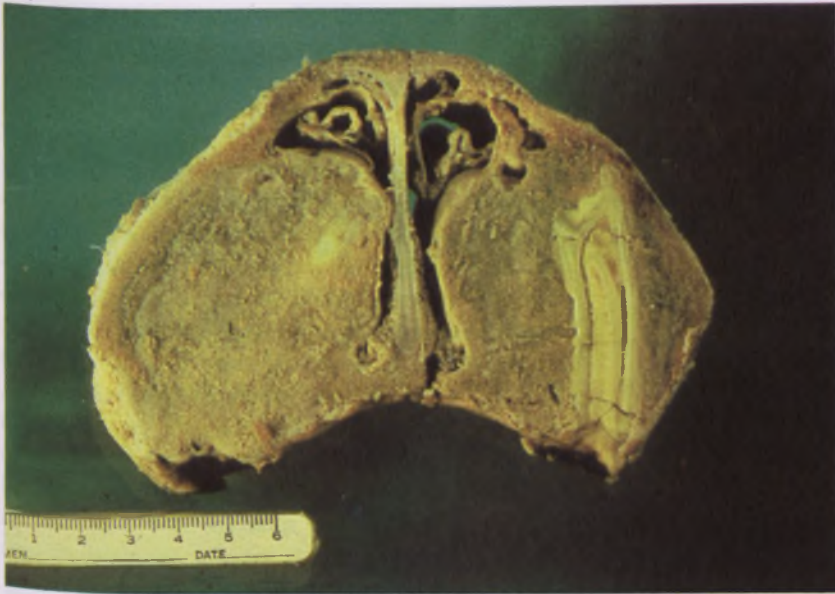

PLATE 69: NUTRITIONAL SECONDARY HYPERPARATHYROIDISM

The maxillary bone around the teeth are markedly enlarged and practically obstructs the nasal cavity. This is Fibrous Osteodystrophy, caused by Nutritional Secondary Hyperparathyroidism and is associated with an imbalanced mineral diet. In horses it is often associated with eating bran with its high phosphorus content (Bran Disease).

Dr. M. Conrad, Cornell, USA

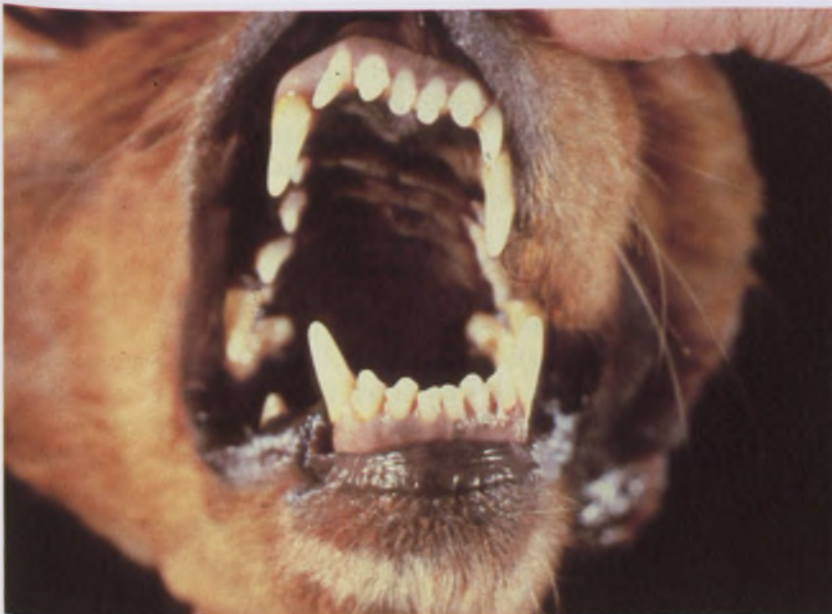
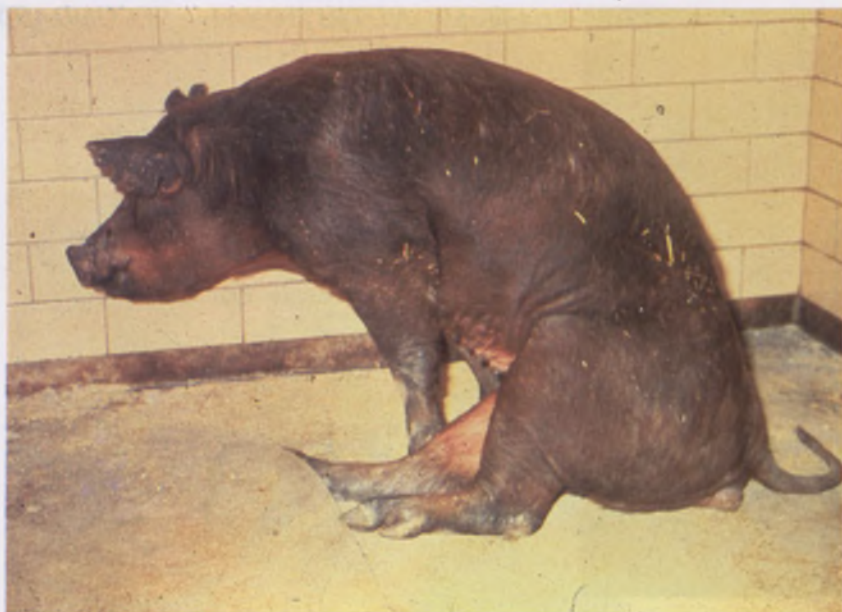
PLATE 70: RENAL SECONDARY HYPERPARATHYROIDISM

The jaws of this young dog are very pliable and able to be twisted in this fashion without necessarily damaging the bones further. This is a case of Rubber Jaw or Renal Rickets as a result of severe chronic renal disease of any sort causing Renal Secondary Hyperparathyroidism. Histologically, the lesion in the bone is characterized by loss of bony spicules, connective tissue formation and increased osteoid without mineralization.

Dr. M. Conrad, Cornell, USA



Dr. M. Cohen, Cornell, USA

**PLATE 71: DOG SITTING POSITION
FROM VERTEBRAL
ABSCESS FORMATION**

Animals that do not normally have this "dog sitting" posture should immediately make one think of a vertebral abscess in the thoracic or lumbar spinal cord. The sow has a thoracic abscess. If their bones are soft a vertebral fracture should also be considered. Vertebral abscesses that arise from a hematogenous source are often seen just above the heart or above the kidneys and may be related to the lack of vertebral vein valves in these two areas. Tail docking or biting are common causes in pigs and other species. These animals are paralyzed in the hind quarters. Venous return from the tail and parts of the hind quarters have been shown in some cases to return via the vertebral sinuses which may play a part in this type lesion.

Dr. A. From, Cornell, USA



PLATE 72: VERTEBRAL ABSCESS

The large pockets of purulent debris and chronic reaction with a pronounced bulge compressing the spinal cord of this calf is the result of an abscess involving two thoracic vertebrae. The most common location for vertebral abscesses in calves, pigs and sheep are in the vertebrae directly above the heart and above the kidneys. No proven cause is known but it is thought that the lack of vertebral vein valves which are in most vertebral veins except those above the heart and kidneys play some role by allowing blood to reflux to the areas during deep respirations. The agents isolated are the usual common pathogens such as *Corynebacterium pyogenes* and *Streptococcus spp.* Tail docking and tail biting in sheep and pigs are common predisposing factors.

Dr. H. Evans, Cornell, USA

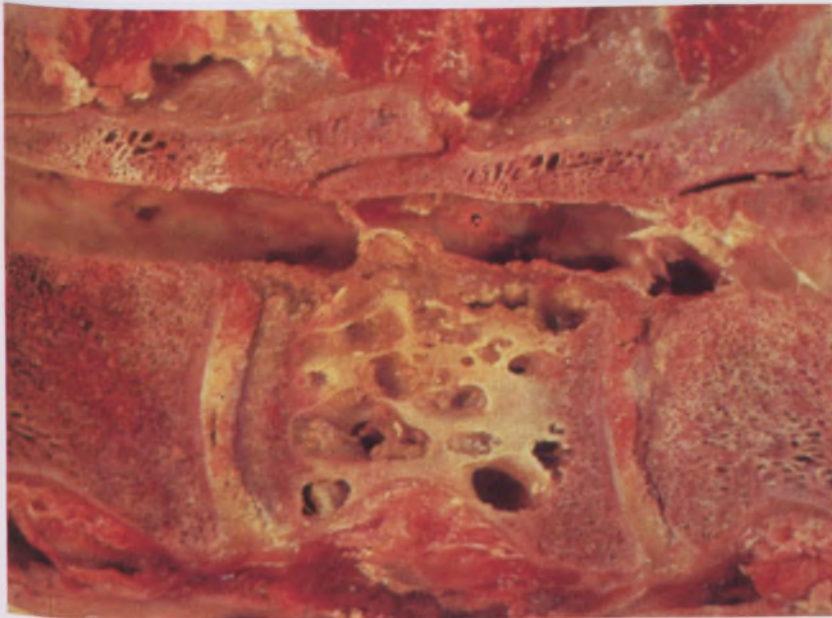


PLATE 73: ECHINOCOCCOSIS

The fine cystic cavitation of the vertebral bodies seen here are normal but the central vertebral body has large cystic cavities and thickened bone spicules, the result of Hydatid Disease in a cow. These cysts are the intermediate stage of *Echinococcus granulosus* which occur in the tissues of many animals including man. The adult tapeworms are found in carnivores.

PLATE 75: LYMPHOSARCOMA

The fleshy mass mass in the lymphatic space and extending up the ribs under the peritoneum of a dog is Lymphosarcoma. This tumor is probably the most malignant tumor of all animals.

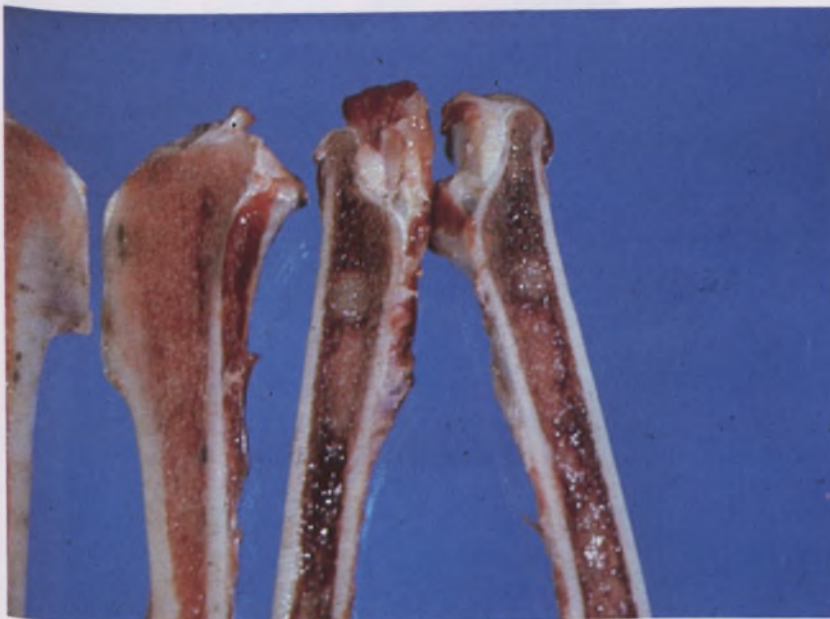

PLATE 74: MAST CELL TUMOR OF BONE MARROW

The several distinct pale masses in the darker bone marrow of a dog are Mast Cell Tumors. One's first guess would usually be Multiple Myeloma or Plasma Cell Tumors but this points out the need for smears and histological sections to be definitive in most cases of neoplasia. The other bone with lighter bone marrow is normal. Even Lymphosarcoma could appear like this tumor. Note that contrary to common opinion, it is relatively rare for metastatic tumors to so massively invade bone marrow that it causes clinical anemia. There is no doubt that some 'anemia causing factor' may be elaborated by malignant tumors, but it is rare for them to replace sufficient bone marrow to cause anemia.

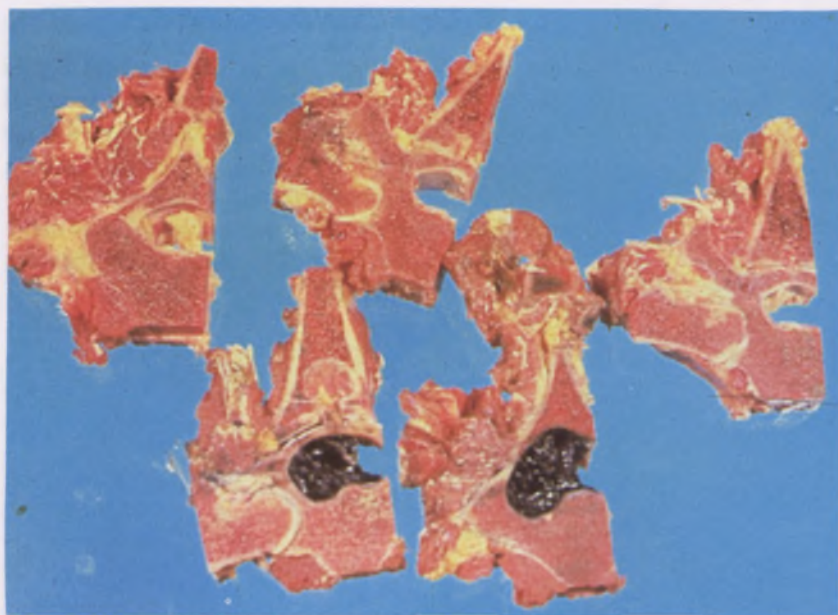

PLATE 75: VERTEBRAL MELANOMA

The horse's vertebrae shown here have been sectioned initially longitudinally to remove the spinal cord, and then in cross section to show the Melanoma, cut in two, which almost fills one area of lumbar vertebral canal. It had compressed the cord to cause posterior paresis in this old grey horse. It was, however, the only location of tumor found in the horse and a diligent search was made for it in the more commonly affected areas such as the skin and areas around the tail, head and anus. Embryologically, as there is the relationship of melanocytes to nervous tissue, it is possible that the melanocyte foci, giving rise to the tumor, had been sequestered in this region since early embryonic life.

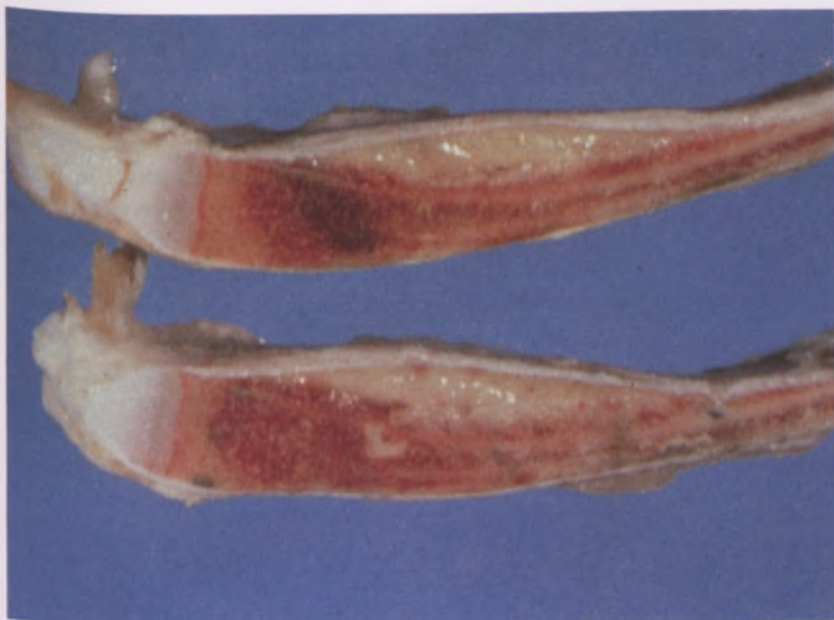
Dr. M. Cohen, Cornell, USA

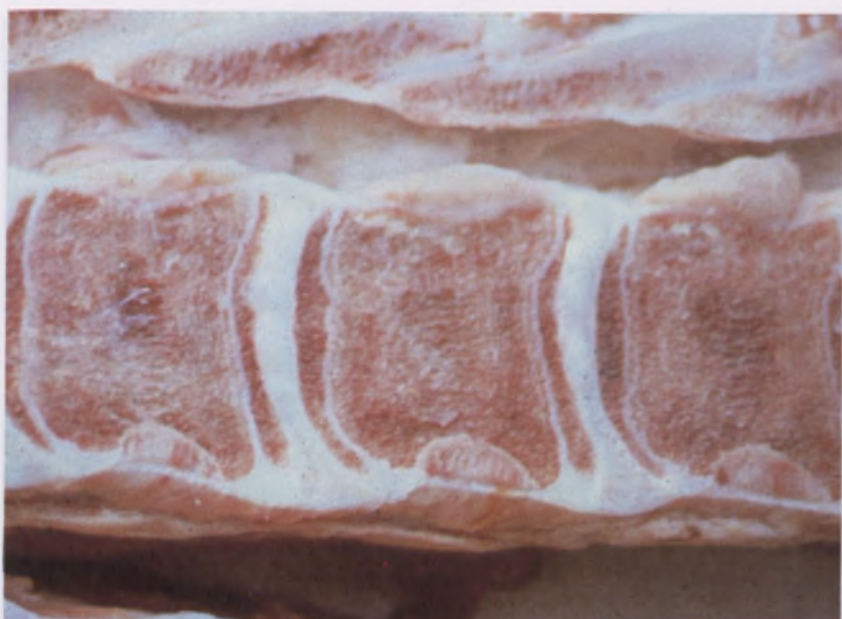

PLATE 76: SUBPERIOSTEAL LYMPHOSARCOMA

The pale tissue, more dorsally than ventrally, associated with these vertebral bodies in this 6 month old heifer are neoplastic lymphoid cells, in this case of Lymphosarcoma. It should be noted that it is under the periosteum and it is not associated with the intervertebral discs. These can often be large enough to cause spinal cord damage with clinical signs. The tumor masses may also be only around the dura mater of the cord proper.

Dr. H. Evans, Cornell, USA



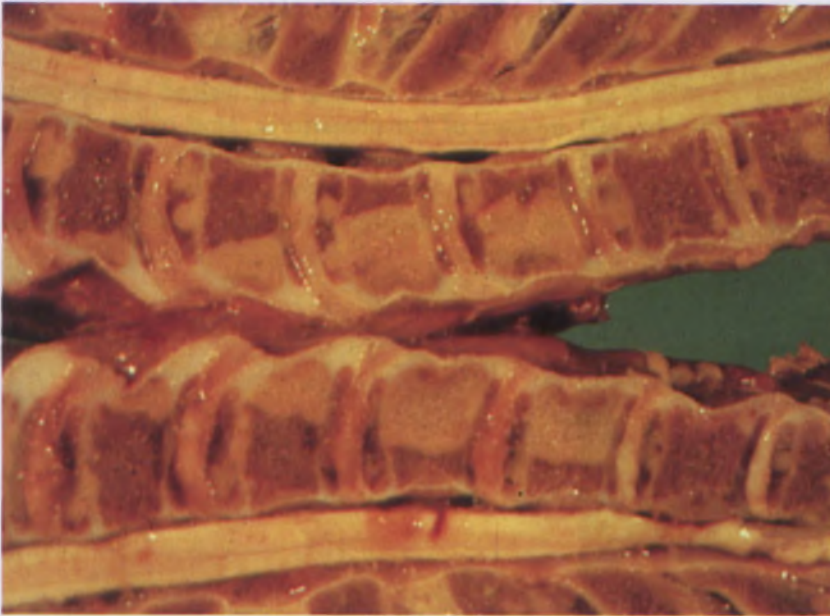
**PLATE 77: SUBPERIOSTEAL
LYMPHOSARCOMA**

This calf's rib shows a well marked, subperiosteal invasion of Lymphosarcoma. Most of the ribs were affected. The pale white zone, in the spongy bone of the rib, just above the costal cartilage is an area of Osteodystrophy caused by a Vitamin/Mineral imbalance.

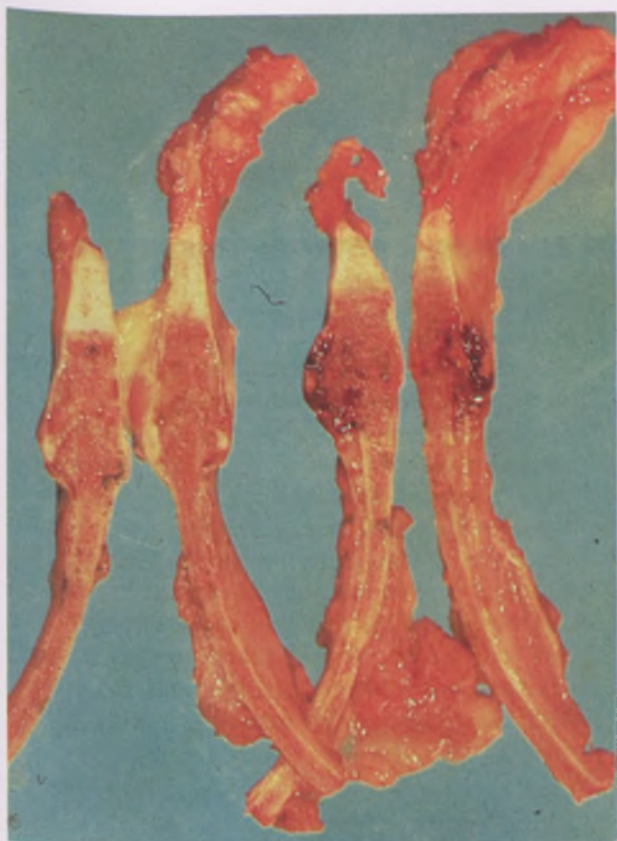

PLATE 78: LYMPHOSARCOMA

The fleshy tissue masses in the hemorrhagic areas and extending up the ribs under the periosteum of a dog is Lymphosarcoma. This tumor is probably the most malignant tumor of all animals.

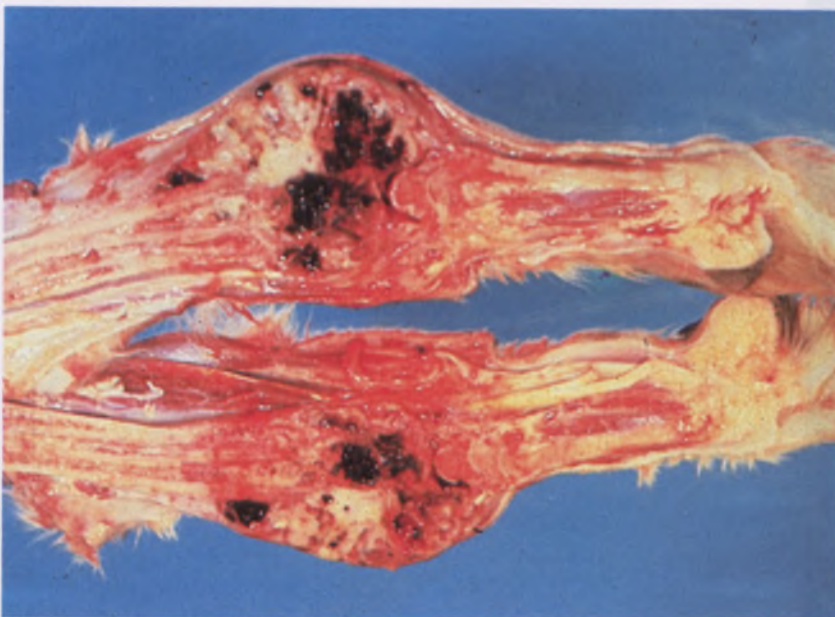


**PLATE 79: VERTEBRAL BODY
INFARCTION**

The pale white areas, mostly in the ventral halves of these vertebral bodies in a calf, are areas of Infarction associated with Lymphosarcoma. They are scattered in several of the epiphyses of the vertebral bodies also. This form of Infarction is more common in calves than in other animals. Neoplastic cells can be seen in these areas grossly and microscopically.

PLATE 78: LYMPHOSARCOMA

The body of the tumor is the largest mass and extending up the side the posterior of a dog is Lymphosarcoma. This tumor is probably the most malignant tumor of all animals.



**PLATE 80: OSTEOGENIC SARCOMA
AND PATHOLOGICAL
FRACTURES**

The distal radius of this dog has a large irregular swelling with much hemorrhage present in it. It is an Osteogenic Sarcoma, a usually very malignant neoplasm of bone that in many cases, when the tumor becomes clinically evident, may have already metastasized to the lung. Also, these tumors usually spare the nearby joints by not invading through the joint capsule, but, in this case the hemorrhage in the mass and the epiphysis suggest that the tumor has caused weakening of the bone with resultant fractures, called Pathological Fractures, in the shaft and through the articular surface.

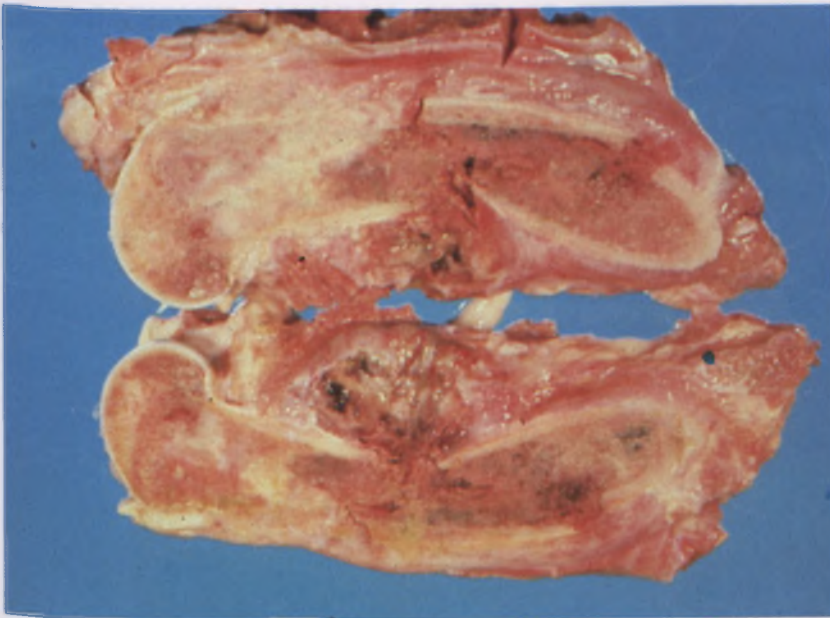


PLATE 81: OSTEOGENIC SARCOMA AND PATHOLOGICAL FRACTURES

The large mass projecting out from the mid shaft region of this dog's humerus is an Osteogenic Sarcoma. The cortex of the bone has been eroded at this site and an irregular fracture line can be seen across the shaft. Another small area of bone loss and fracture can be seen in one cortical bone section also. These fractures, the result of an underlying disease process, are called Pathological Fractures.

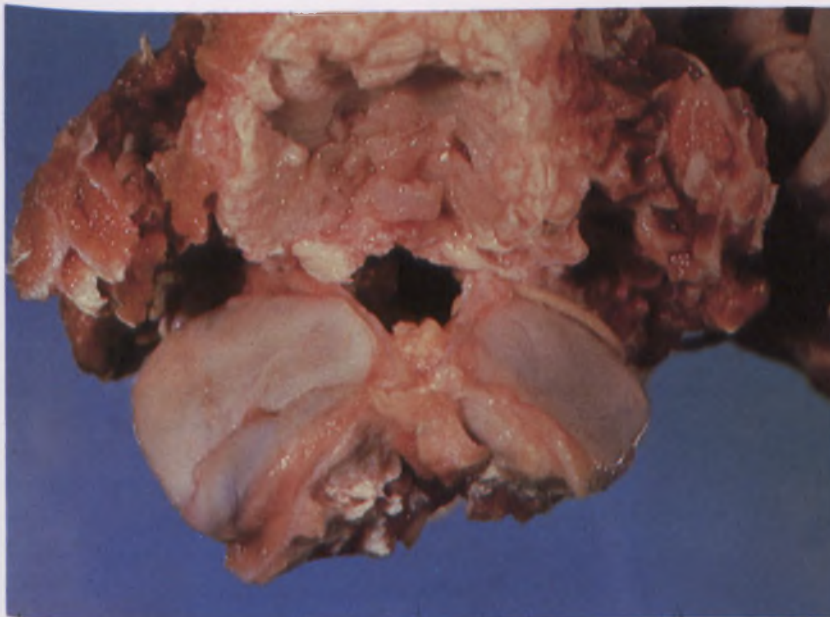


PLATE 82: CERVICAL VERTEBRAL DYSPLASIA (STENOSIS)

This caudal view of a cervical vertebra shows the marked asymmetry of the articular processes and vertebral foramen. In some cases combinations of the asymmetry of the foramen and the articular processes along with the production of a pronounced lip of the vertebral head actually bulging into the vertebral canal all tend to decrease the vertebral canal and allow pinching of the spinal cord to cause the classical "Wobbler Foal Syndrome". The caudal cervical vertebrae are the most commonly affected bones to cause the problem with the cranial cervical vertebrae being next. Clinically in the past it has often been difficult to differentiate between this lesion, Equine Herpes Myelitis, Protozoal Myelitis and even Degenerative Myelitis of older horses. These lesions are not apparent at birth but may be first seen at several months of age.

Dr. J. Mayhew, Florida, USA

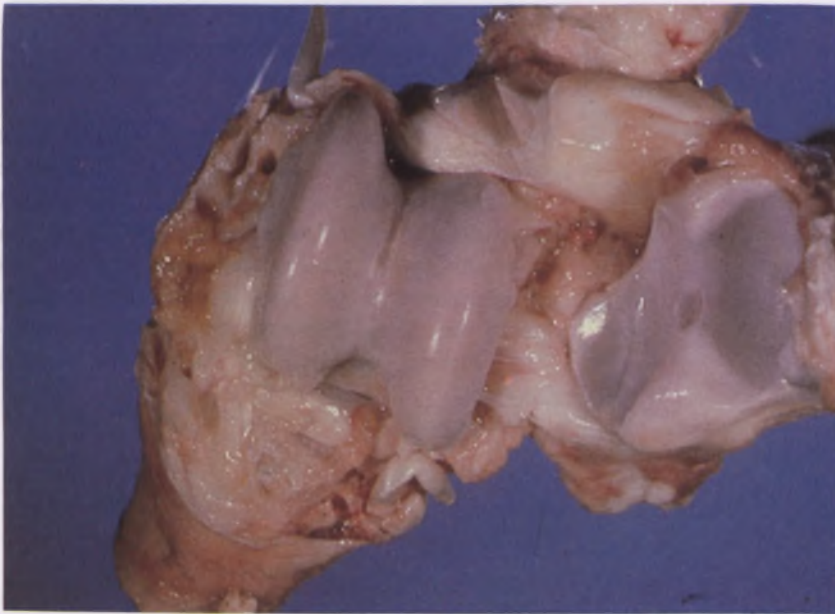


PLATE 83: NORMAL SYNOVIAL FOSSAE

At the base of the trochlear groove of the larger bone, the tibial tarsal bone, is a definite rough surfaced depression, and the other bone, the distal articular surface of the tibia, has a similar but smaller rough depression. These are normal synovial fossae and are often mistaken for pathological erosions or other abnormal processes. They are in other joints as well and their actual distribution varies somewhat in the different species.

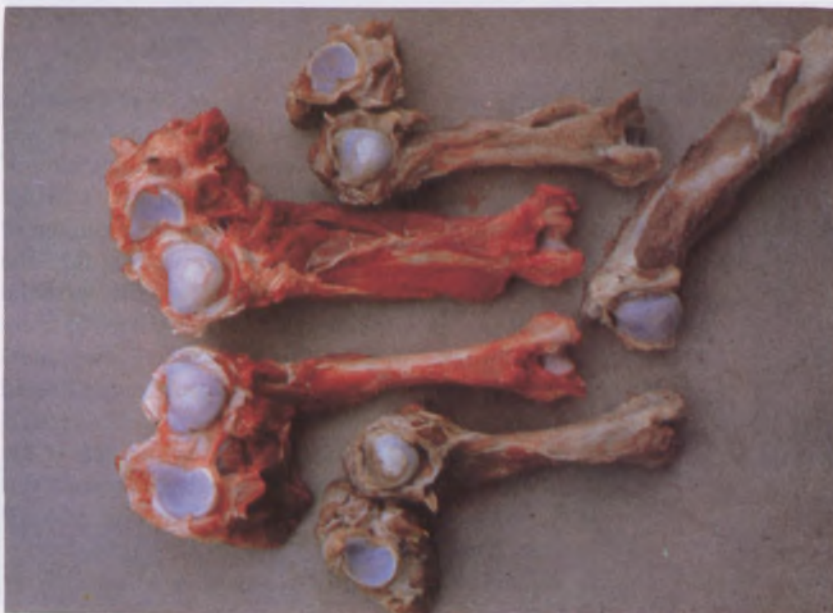

PLATE 84: OSTEOCHONDROSIS DISSICANS

The four joints symmetrically placed all show a distinct cartilaginous degeneration at the approximate center of the articular surface of their humeral heads. It is more opaque and slightly raised with an irregular border and even partial fracture of the cartilage. A normal surface is shown on the single bone. These pieces of degenerate cartilage can be easily raised and in time they do detach naturally and may become free floating bodies called Joint Mice. This articular surface degeneration is usually seen in young dogs. The shoulder joint is the most commonly affected joint, but it can be seen in other joints and in other species. There are several different suggested causes for this. As there is no good evidence that there is an inflammatory component to this disease, the older name of Osteochondritis Dissicans should not be used.

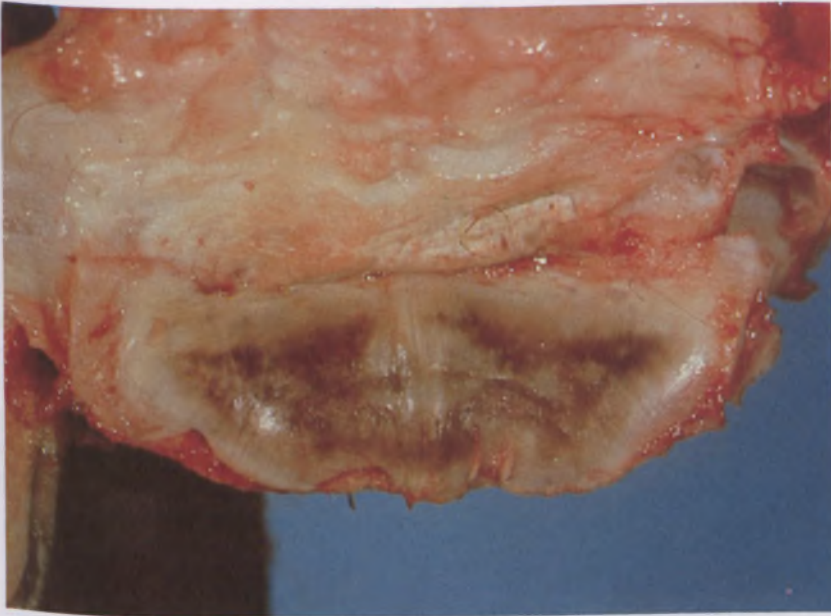


PLATE 85: CHRONIC NAVICULAR DISEASE

The flexor surface of this navicular bone (distal sesamoid) is well grooved with linear streaks and stained dark brown from old hemorrhage. The corresponding flexor tendon surface would most likely be similarly affected in most cases. The actual cause is not understood and neither is the fact that a small lesion in this area can cause a disproportionate amount of clinical problems.

Plate 85: Hip Dysplasia may be unilateral. The cause for this has not been determined.

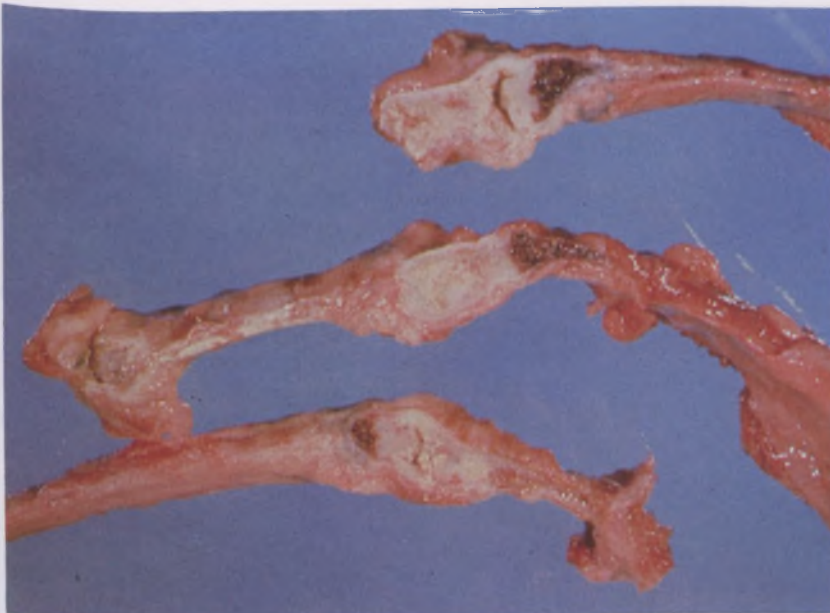
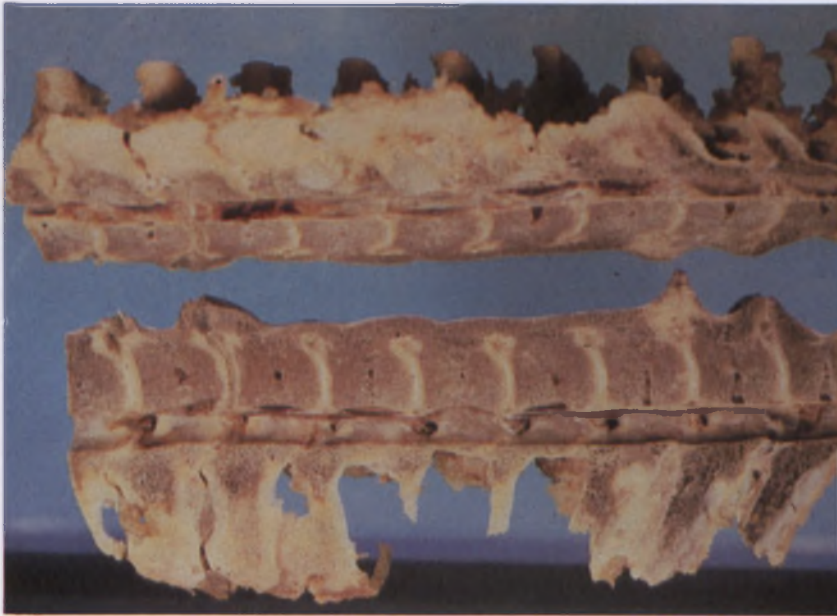
PLATE 86: COSTAL CARTILAGE DEGENERATION

The three dog ribs shown, show typical chronic degeneration of the costochondral junction cartilage due to aging. It is a common lesion and while most have opaque white chalky material in the degenerative area, some have a distinct greenish to yellow coarse fibrillar material. The middle rib has a similar lesion at its sternal insertion. The cause is not known.



**PLATE 87: VERTEBRAL BRIDGING
SPONDYLOSIS**

Many of the bodies of the vertebrae shown here are bridged by proliferating exostoses from the vertebral bodies themselves. In four areas vertebral motion has resulted in false joints being formed so that true bony ankylosis (solid bridging without movement) has not formed. This problem of spondylosis is more common in aged bulls but has been seen in many animals such as the llama, dogs, cats and horses as this case demonstrates. Many consider that this is a nutritionally induced disease especially in breeding bulls maintained on a milking cow's diet. Often such cases die as the result of a vertebral fracture at one end of the long fulcrum formed by the fusion of so many vertebrae.

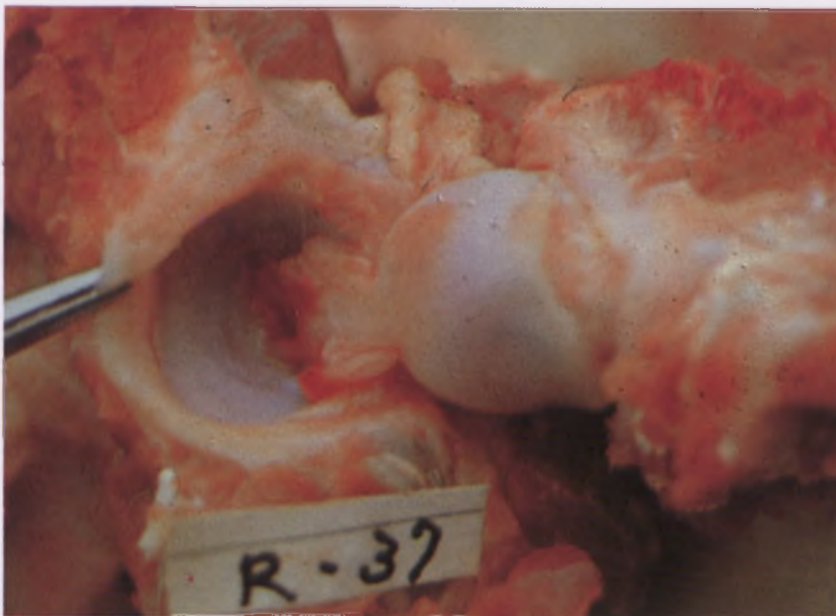

PLATE 88: HIP DYSPLASIA

This coxo-femoral joint of a 9 month old dog shows three of the four primary lesions of this disease; 1, the band like piece of connective tissue held by the forceps at the rim of the acetabulum is in marked excess of normal; 2, the cartilage erosion of the femoral head, as evidenced by the area of darkened articular surface; 3, the cartilage erosion of the acetabular surface, which is also darker than normal and slightly grooved. The fourth lesion, not seen in this early case, is the presence of exostoses at the synovial-cartilage junction around the femoral head itself. Of course other lesions will develop as the disease progresses.

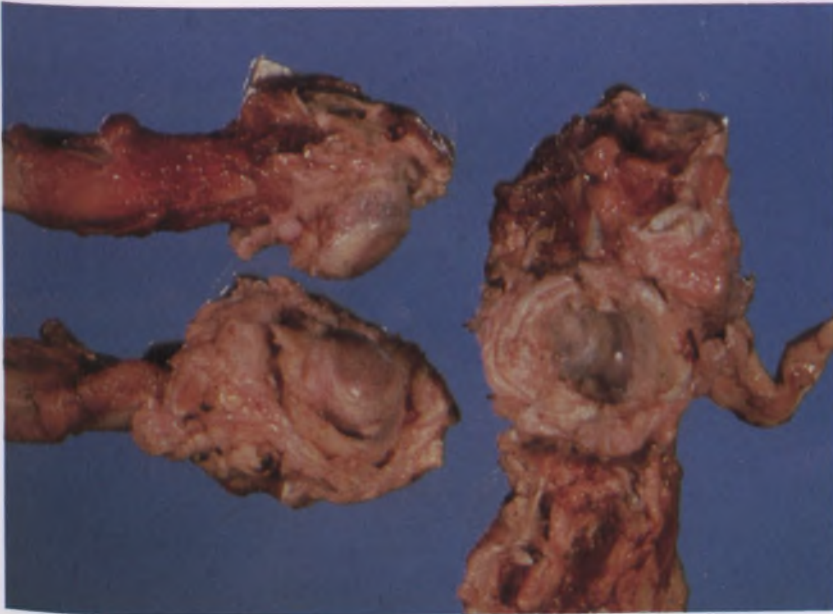

PLATE 89: CHRONIC ARTHRITIS

The acetabulum shown has massively thickened periarticular connective tissue, as do both femoral heads. The cartilage of all three specimens have been destroyed almost completely, and the underlying bone polished to a dark and shiny surface by a process called Eburnation. Both femoral heads are flattened and the acetabulum is shallow. Proliferating small spicules of bone, exostoses, are scattered around the femoral heads and the synovial membranes of all three bones are hyperplastic. Out of context, one could not definitely say this was caused by hip dysplasia initially, unless one was sure of the history of the animal, as it could easily be mistaken for chronic Degenerative Osteoarthropathy. The flattened femoral heads would help to suggest it was more likely Hip Dysplasia. Also Degenerative Osteoarthropathy would usually have similar lesions of the shoulder joints. Hip Dysplasia may be unilateral. The cause for this has not been ascertained.

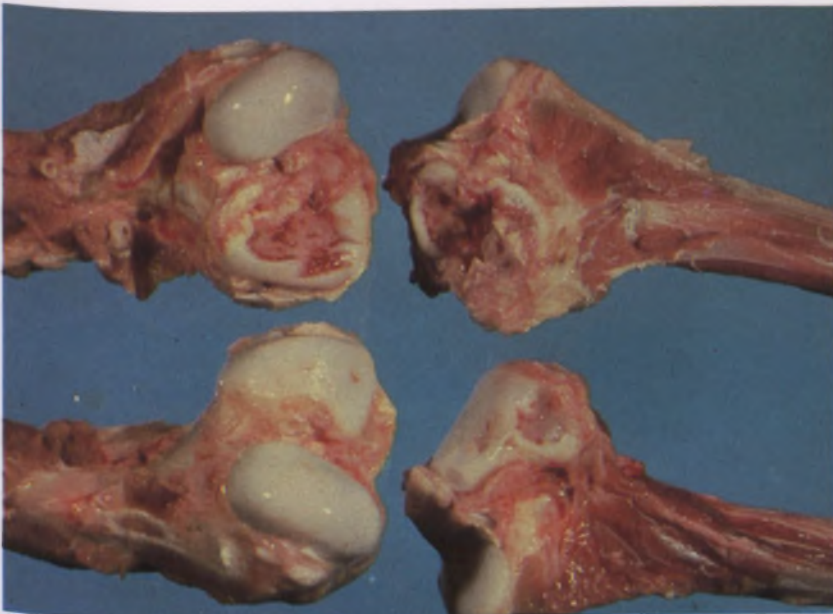
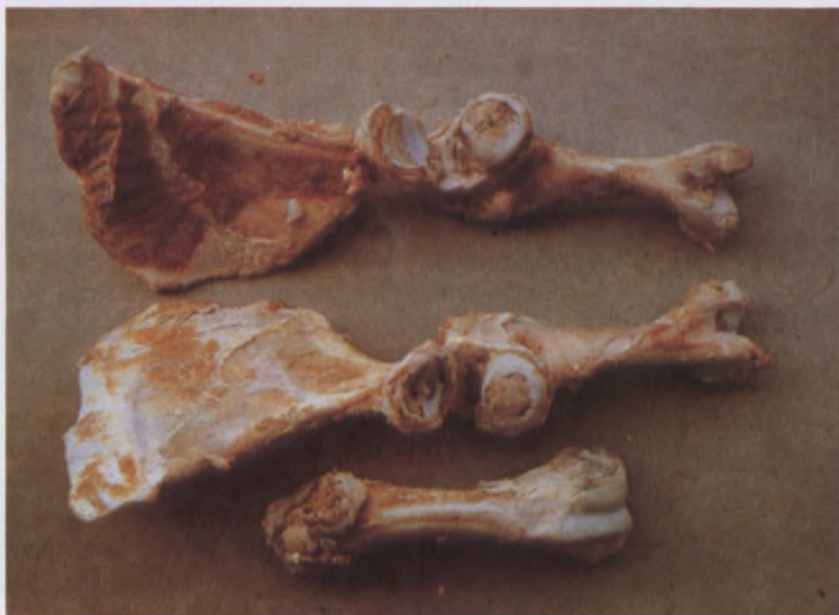

PLATE 90: TRAUMATIC ARTHROSIS

Shown are the medial articular surfaces of a foal's stifle joints which some time previously had been damaged by trauma, destroying much of the cartilage. One side is more severely affected than the other. Some discussion exists that this may be infectious, but it is too common a lesion and too localized for this to be so.



Joint Hip Displacements may be unilateral. The cause for this has not been ascertained.

PLATE 91: TRAUMATIC ARTHROSIS

The shoulder joints of this horse shows marked traumatic destruction of both articular surfaces. We have seen this lesion several times now and other cases have actually had fractures of the cortex of the humerus just under the humeral head to suggest its traumatic origin. As in this case, the femur lying alongside the shoulder bones shows a traumatic loss of the femoral head. To have such extensive damage to so many bones suggests an underlying nutritional problem.

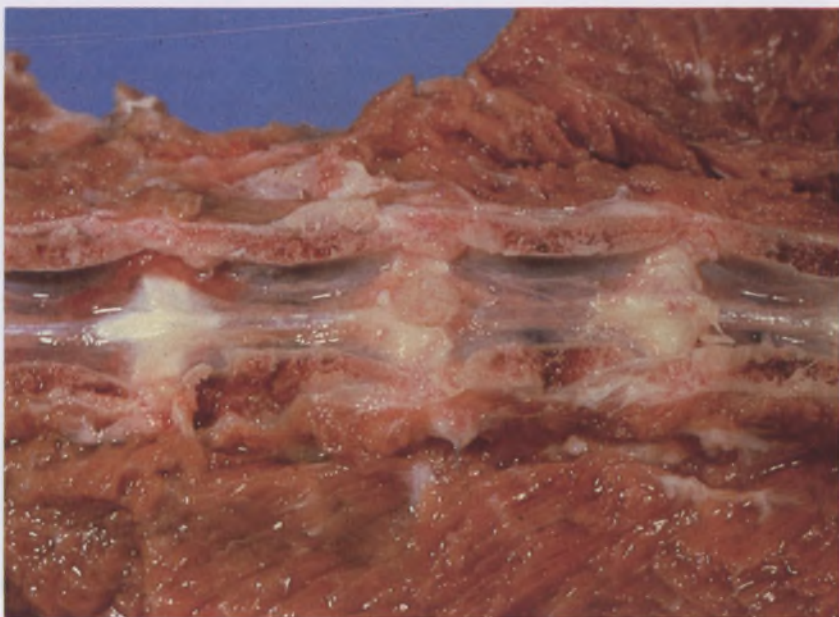

PLATE 92: PROLAPSED INTERVERTEBRAL DISCS

Three and a part of a fourth intervertebral joints are shown looking down on them after the spinal arches had been removed. The whiter joint area is normal but the other two show a definite irregular proliferation of connective tissue over the joint proper, and even extending laterally and up the inside of the vertebral canal. These two have some disc material pushed up through the annulus fibrosus into this area of the dorsal longitudinal ligament. Apparently this is quite an irritant, as much connective tissue can be seen even with a minimal of nucleus pulposus debris present. Increased movement also plays a part. The cause is not known but some consider that weakening of the fibrous ring of the disc may be involved and one suggestion includes a vitamin C problem associated with collagen. Of course trauma often plays a critical role in the clinical onset.

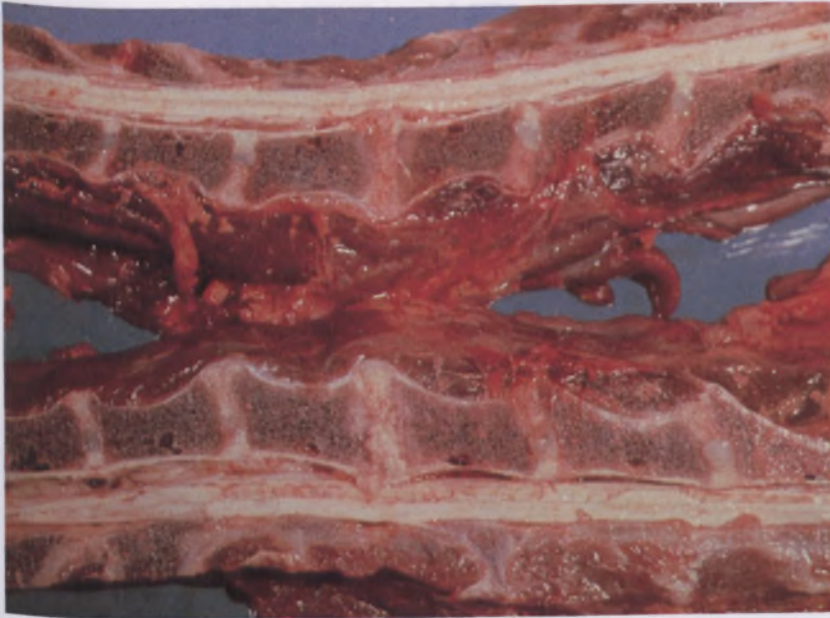


PLATE 93: PROLAPSED INTERVERTEBRAL DISC WITH SPINAL CORD COMPRESSION

The spinal cord of this 3 year old Basenji dog is shown compressed dorsally by a mass of irregular connective tissue and debris, which is the result of nucleus pulposus being extruded through the annulus fibrosus. The clear, glistening, normal nucleus pulposus is seen in the central areas of the other discs by comparison. Sometimes these discs rupture, the material mineralizes and becomes fibrotic without clinically affecting the animal, but at a later date the animal may compress its cord over the mass by a sudden arching of the back, and then clinical signs will be acute, even with a chronic disc protrusion. Many times in splitting the vertebral column like this, several or many of the pulpy nuclei of the discs *in situ* will be opaque white from mineralization.

Dr. B. Summers, Cornell, USA

Dr. B. Summers, Cornell, USA

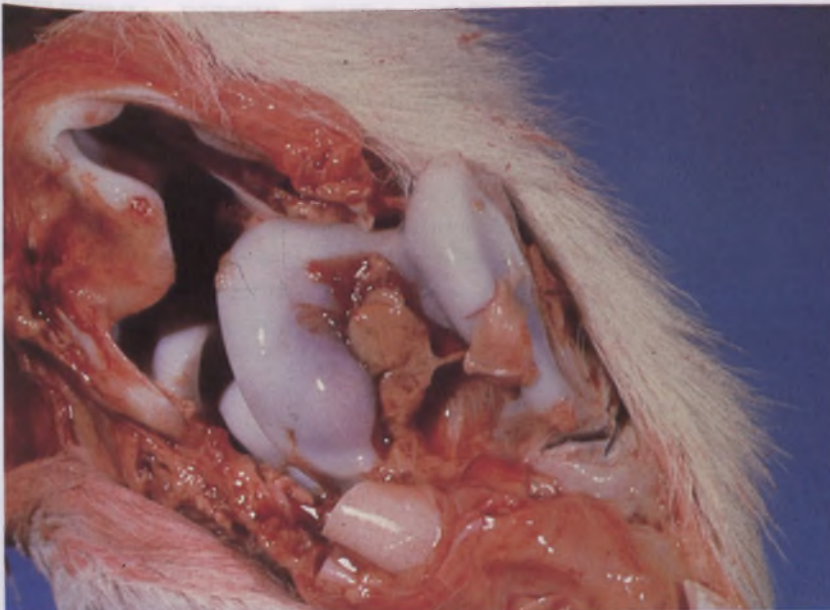


PLATE 94: ACUTE ARTHRITIS

Several small clumps of yellow red fibrin in this hock joint suggest the diagnosis given above, due to a case of *E. coli* septicemia in a calf. While fibrin tags may be found in any or all joints in severe calf septicemia cases, the hock is often the only joint with fibrin present in many fatal cases. Blood and small white tags of fibrin may be found quite often in the tarsal joints of normal calves several days old. Cultures of these joints are diagnostic.

Dr. J. J. Parsons, Oklahoma, USA

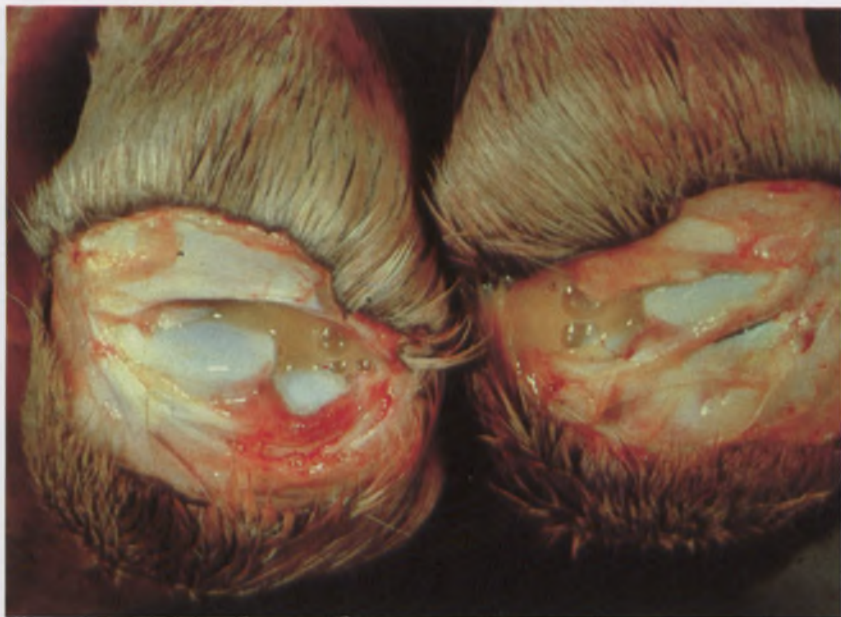

PLATE 95: ACUTE SEPTIC ARTHRITIS

The yellow, cloudy fluid in this foal's joints is an example of acute purulent arthritis caused by any one of a number of pathogens. In this case pure cultures of *Salmonella* spp. were isolated. In all such cases only a culture can be definitive.

Dr. B. Summer, Cornell, USA

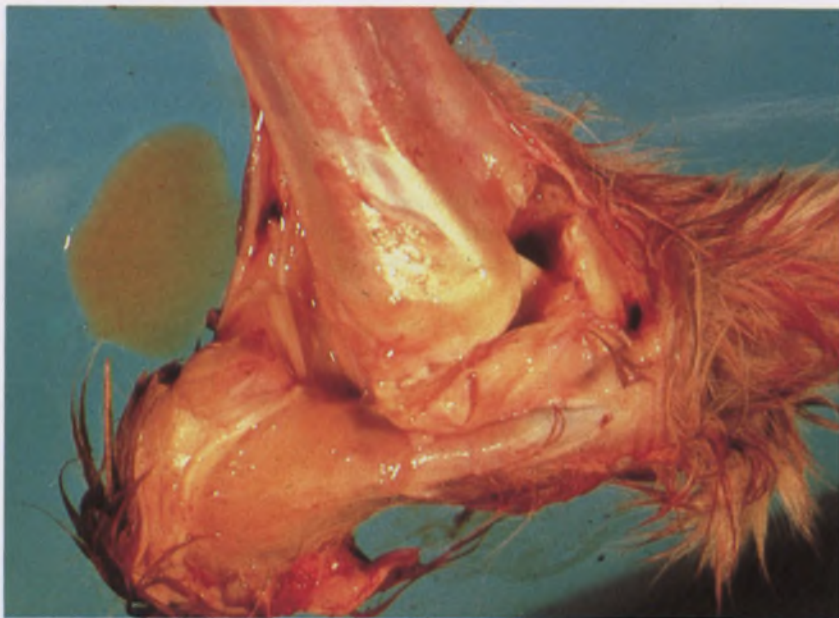

PLATE 96: ACUTE SEPTIC ARTHRITIS

The distinctly cloudy fluid that drained from this joint is evidence that an infectious arthritis is present. One of many common pathogens may be isolated but *Actinobacillus equuli*, the cause of Joint Ill, was isolated from this Sleeper Foal. Normal joint fluid may be thick or thin according to the state of hydration of the animal. etc., but it is never cloudy. It is also important to note that the infected joint itself may have no other lesions.

is not a role in the clinical case.



Dr. M. Cohen, Iowa, USA

PLATE 97: CHRONIC SEPTIC ARTHRITIS

The lumpy masses associated with the carpus of this pig are large abscess pockets filled with a cheesy pus. *C. pyogenes* is often isolated from such lesions but Staphylococci or Streptococci are also commonly found. In fact, almost any of the common pathogens may be isolated. When lesions like this are found in more than one animal, a husbandry problem should be suspected first as proper care, treatment, isolation and environmental control are not being utilized.

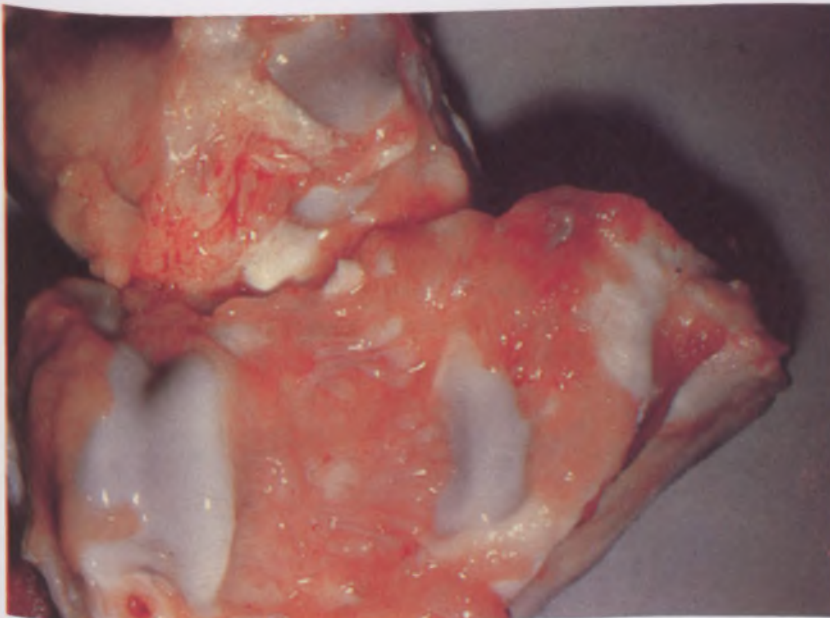


PLATE 98: CHRONIC PROLIFERATIVE SYNOVITIS

The long villous projections of the synovial lining of this joint are the result of chronic Erysipelas caused by *E. rhusiopathiae* (*E. insidiosa*) in this pig. Other agents could also cause a similar lesion in this or any species.

Dr. R. J. Panciera, Oklahoma, USA

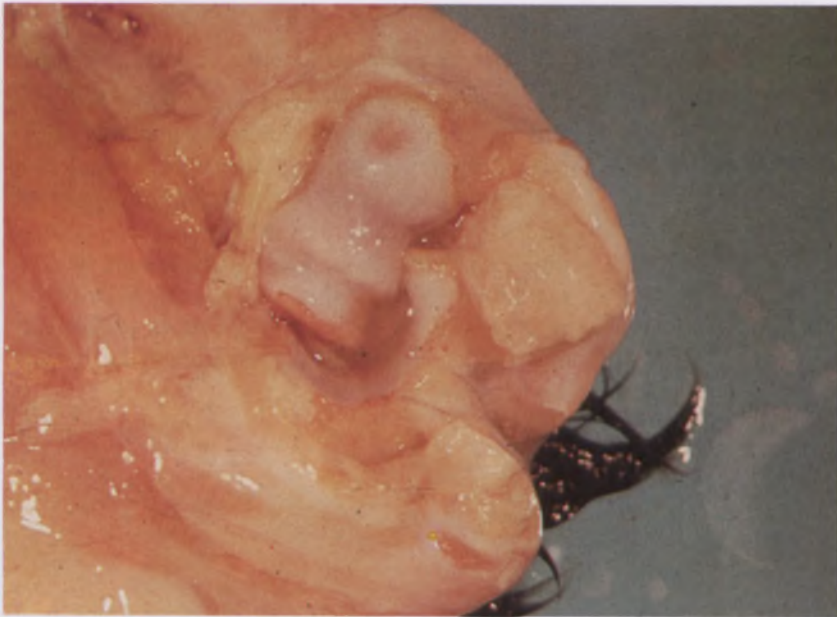


PLATE 99: ACUTE SEPTIC ARTHRITIS

The cloudy fluid in this goat's joint along with the periarticular edema suggests an infectious process. The round spot on the cartilage is an artefactual knife cut. Organisms such as PPLO and others have long been thought to be the primary cause and only recently have research workers shown that a virus is the most likely culprit. The work by Dr. L. Cork on the Caprine Leucoencephalomyelitis virus, a virus probably related to Maedi, Marsh's Progressive Pneumonia and Visna suggests this.

Dr. M. Smith, Cornell, USA

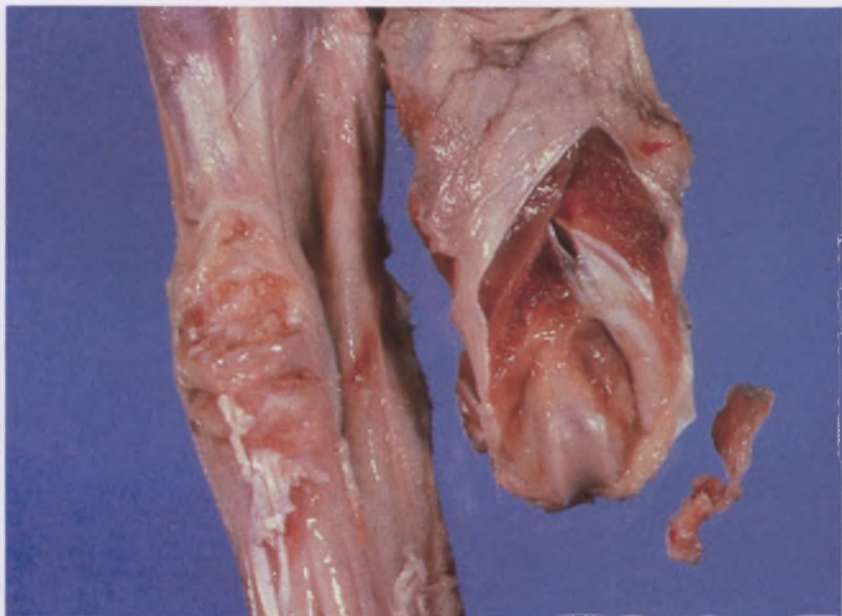

PLATE 100: FELINE POLYARTHRTIS

The slight discoloration of the synovia and tissues around this cat's joints along with the fibrin clumps from the joints and the periarticular edema is evidence for this relatively, newly recognized disease, Feline Polyarthrititis. Histologically an acute purulent infection is present in this case. The etiology has not been definitively determined. Some believe it to be a viral disease, related to FeSFV and FeLV, while other suspect *Mycoplasma* sp. to be the cause.

Dr. J. Crissman, Cornell, USA



**PLATE 101: MULTIFOCAL ACUTE
MUSCLE DEGENERATION
OF PORCINE STRESS
SYNDROME (PSS)**

Some knuckling is noted in one hind leg as this pig is going down and both hindquarters have abnormal muscle bulges in them caused by tonic muscle spasms. They are not clearly evident. Several farms noted this odd form of Porcine Stress Syndrome (PSS) when they moved their pigs. No proven cause was found but their adrenals were greatly reduced in size and scattered muscles had pale areas of acute Zenkers present as is usually seen bilaterally in the more common form of PSS.

Dr. F. M. Wu, Taiwan, ROC

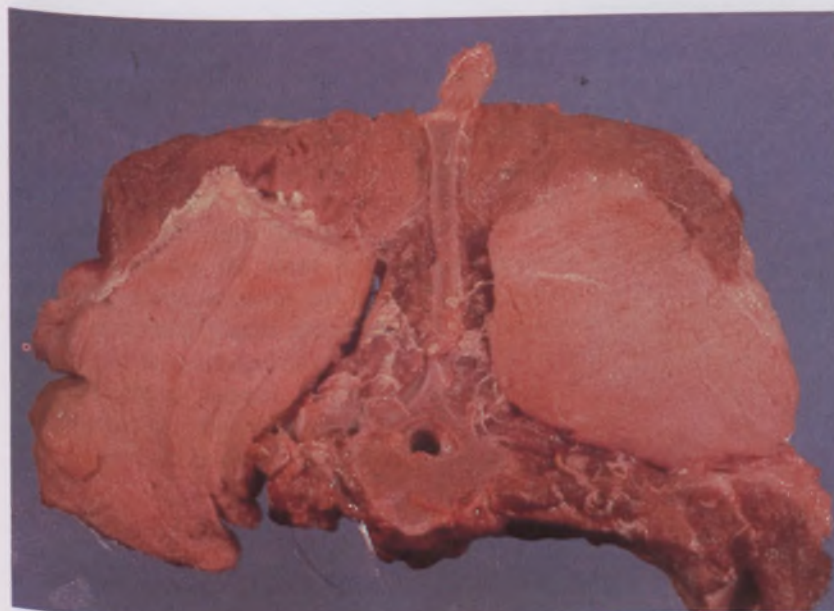


PLATE 102: MUSCLE DEGENERATION

The large pale muscle masses along this pig's back are examples of early Muscle Degeneration associated with Porcine Stress Syndrome. The actual pathogenesis of this lesion or in fact for the whole syndrome is unknown but most cases are associated with adrenals that are smaller and darker than normal.

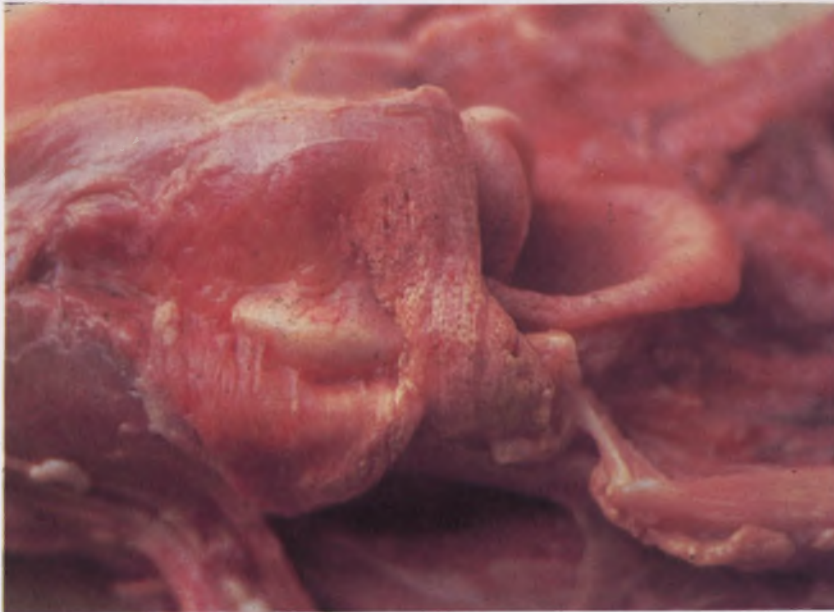

PLATE 103: ZENKER'S DEGENERATION OF MUSCLE

The dorsal muscles of this calf's larynx have many discrete opaque white fibers affected with Zenker's Degeneration caused by a Vitamin E/Selenium Responsive Disease and in this case by a true Vitamin E/Selenium Deficiency. Actual contraction bands are well demonstrated by the stratified effect of this Muscular Dystrophy. Most cases of this disease in animals on natural feeds are probably caused by an Antivitamin E or Selenium factor that develops in spoiled or wet feed. Some cases such as this calf, were on a completely manufactured milk replacer which did not have any, or not enough, Vitamin E/Selenium.

Dr. G. Rumsey, Cornell, USA

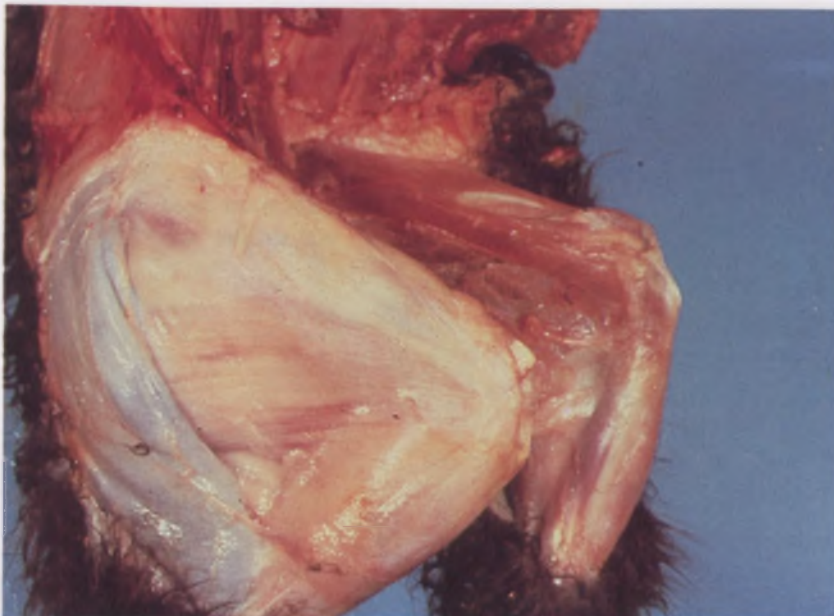

PLATE 104: ISCHEMIC DEGENERATION

This case of extremely pale muscle in the one hind limb of this cat is called Ischemic Degeneration and is the result of an embolus from the heart that blocked the femoral artery on that side. The vascular problem is often called Aortic Thrombosis and is usually associated with thrombosis that develops in the left heart for whatever reason, most usually one of the common forms of Cardiomyopathy. The thrombus usually embolizes to the caudal part of the aorta and causes posterior paresis with absence of normal femoral pulse and cold limbs. Why it is not seen more often in cases of left heart problems in other species is an enigma.

Dr. J. Crisman, Cornell, USA

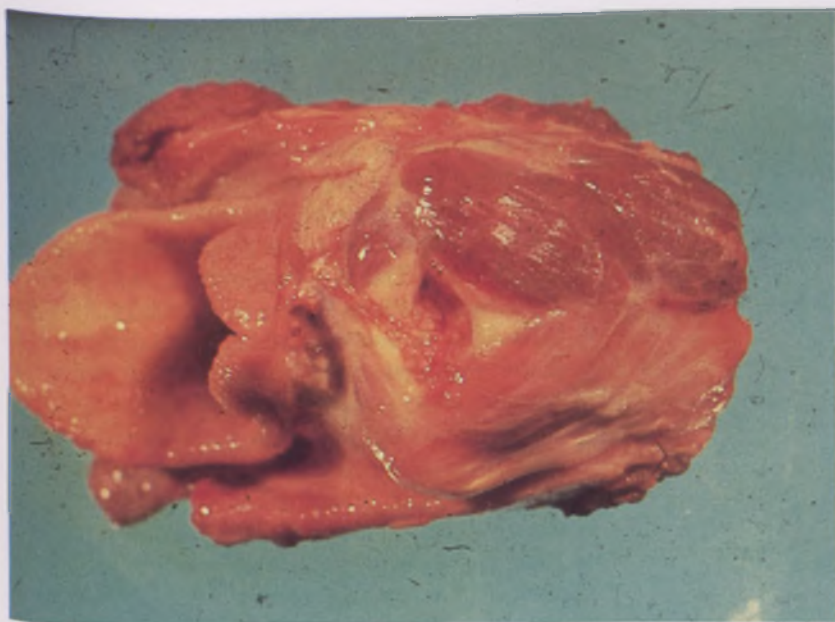


PLATE 105: UNILATERAL NEUROGENIC DISUSE ATROPHY

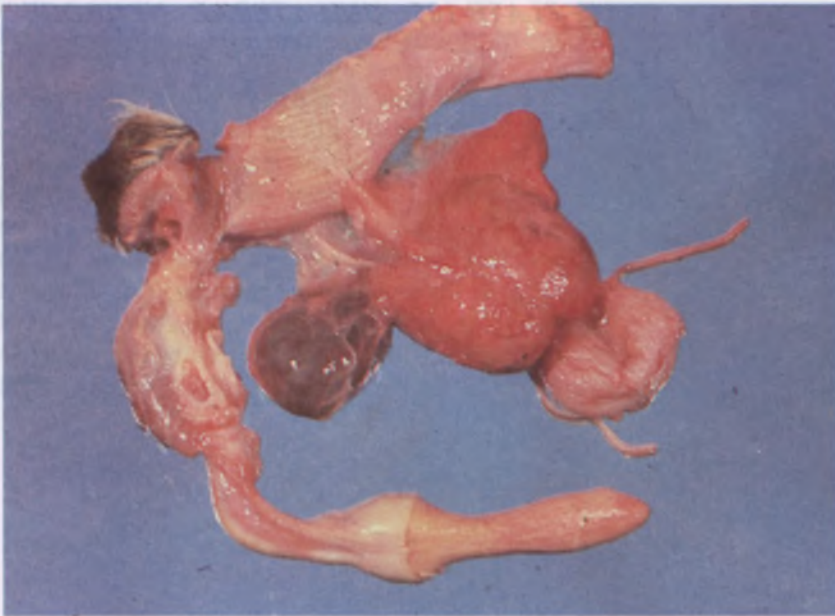
This dorsal view of a horse's larynx with muscles attached shows the normal dark crico-arytenoideus dorsalis muscle on one side and its paired component as a much paler and smaller muscle. This is the result of Disuse Atrophy caused by the recurrent laryngeal nerve as it courses around the aorta to the muscle being damaged. This Unilateral Disuse or Neurogenic Atrophy results in abnormal cartilage movement during breathing and the horse makes a loud abnormal respiratory sound called Roaring.

Dr. R. Habel, Cornell, USA

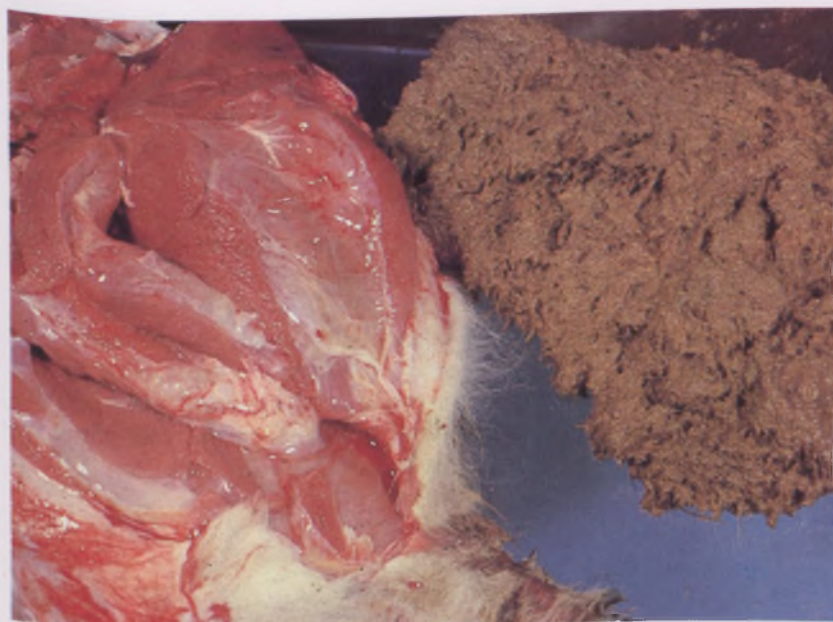

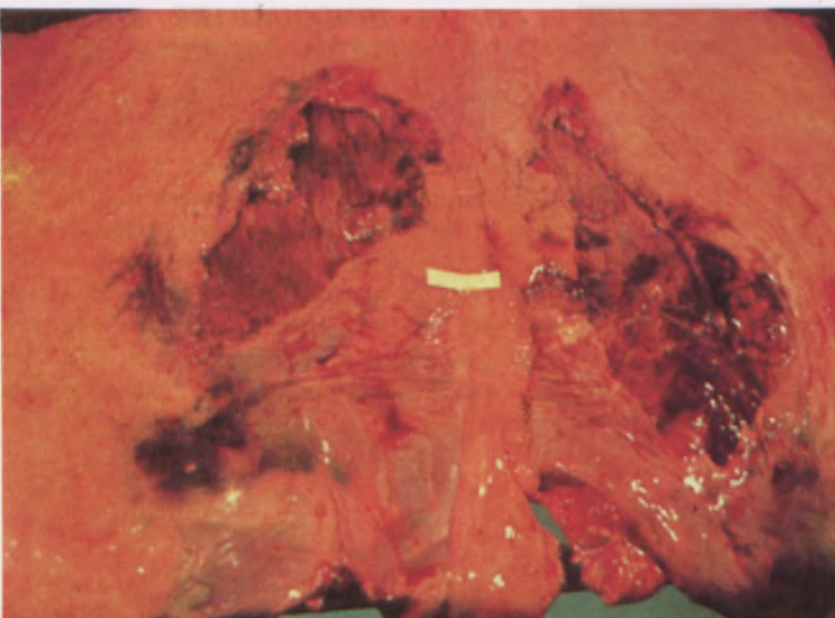
PLATE 106: HINDQUARTER EDEMA FROM FROTHY BLOAT

The well marked paleness and edema of the hindquarters are seen in the subcutaneous tissue and muscle fascial planes of this calf. A very frothy, light rumen content is also present to show the cause of the hind limb edema and anemia. Frothy Bloat is often diagnosed by these lesions as well as a Bloat Line which is a distinct line of separation of a pale distal esophagus from a more congested esophagus, cranial to the thoracic inlet, caused by the greater intrathoracic and intraabdominal pressure.



**PLATE 107: PERINEAL HERNIAL CYST
PROSTATIC CYST**

The anus, rectum, urinary bladder, prostate, urethra and penis from a dog are shown which are essentially normal. However, between the prostate and the curved urethra is a dark cystic mass attached to the prostate. This is a Periprostatic Cyst which is a relatively common finding in male dogs. Its origin however is in doubt, as some consider them peritoneal inclusion type cysts associated with the prostate, while some believe they are the result of dilated lymphatics caused as the result of chronic prostatitis blocking the lymphatic outflow from the pelvic area, and others consider that they are in effect actual "blownout" prostatic diverticulae. They are thought to develop when a hard fecal mass is passed in the rectum over a hyperplastic prostate which ruptures one of the many diverticulae making up the gland. The escaped secretion causes the inflammation with more enlargement to cause continued straining or tenesmus. It finally forces the cyst caudally out, through the perineal soft tissues as a perineal hernial cyst. Some have a definite lumen continuity with the prostate, as this one did, and others are completely separate suggesting the dilated lymphatic type structures.



**PLATE 108: RECTUS ABDOMINIS
MUSCLE RUPTURE**

The large amount of hemorrhage in the abdominal floor associated with the torn fibers of rectus abdominis muscle attest to this being an Antemortem Bilateral Rupture of the Rectus Abdominis Muscle. The horse was pregnant, a condition in which these muscles are commonly seen ruptured in horses and cattle. The horse was obese as well. A general lack of body muscle tone is usually considered a prime factor in the production of this lesion. While this muscle ruptured about 1/3 of the way forward of the pelvis in this case, many are seen ruptured at the pelvic brim itself.

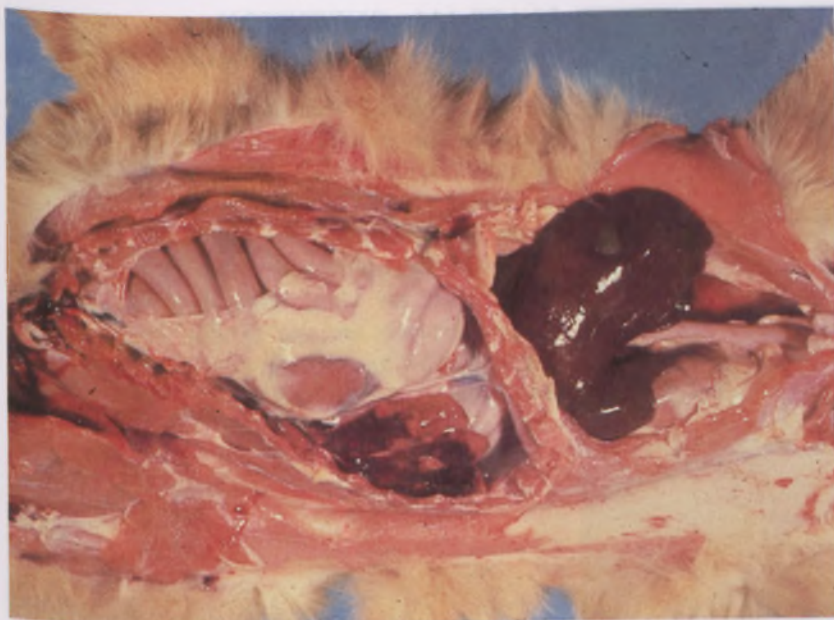


PLATE 109: DIAPHRAGMATIC HERNIA

The major portion of this cat's gastrointestinal tract is in the thoracic cavity and got there through a well healed diaphragmatic hernia that was known to be caused 4 years earlier by an automobile accident. There is no doubt that parts of the intestine and other loose viscera may have slipped in and out of the hernial ring many times during this period but only recently did the right combination of ingesta, gas and peristalsis pull the major portion of bowel into the chest cavity with fatal results. Before the animal was opened the chest was noted to be enlarged and the abdominal cavity "empty".

Dr. E. Trotter, Cornell, USA

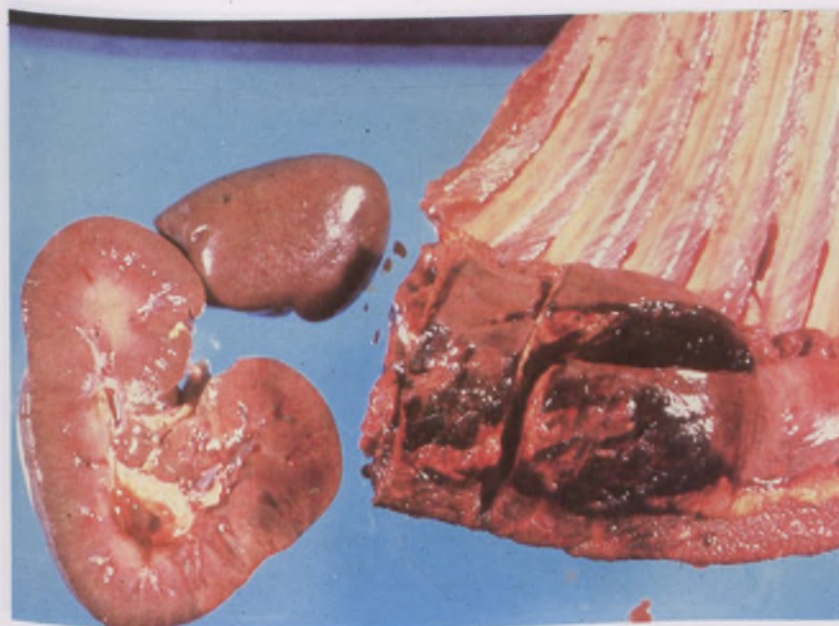
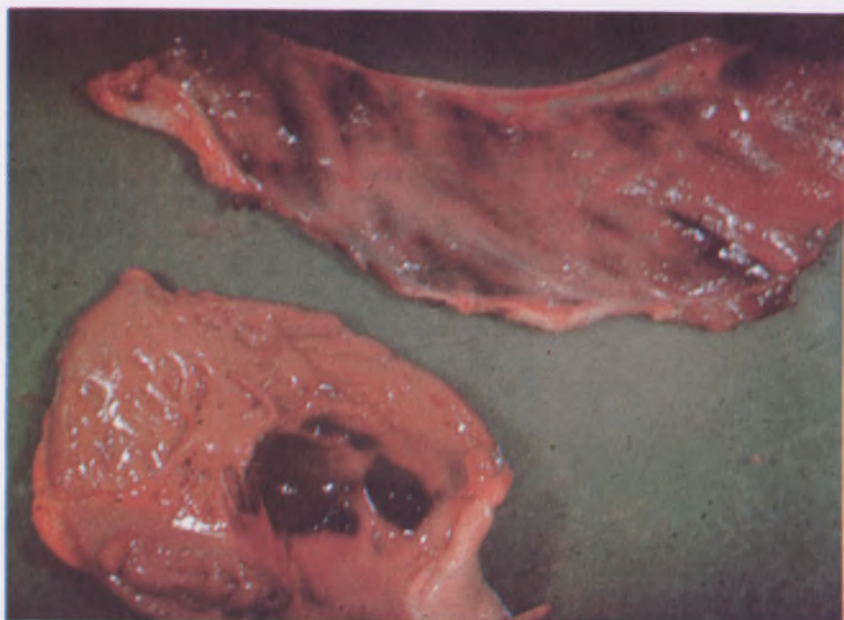


PLATE 110: DICOUMEROL POISONING

The large mass of hemorrhage in the fat attached to the diaphragm and the renal infarction with hemorrhage at the middle portion of the kidney are the result of Dicoumerol Poisoning in an attempt to prevent and treat chronic laminitis in a horse. Hemorrhages were present in other areas as well.



**PLATE 111: SUFFUSION
HEMORRHAGES**

The large areas of hemorrhages, Suffusion Hemorrhages, in the muscles of the heart and diaphragm are quite diagnostic for Enterotoxemia *Clostridium perfringens* type D in sheep, when no other cause of the hemorrhage can be established. They may be found on the intestinal serosa. Fluid with fibrin in the heart sac along with bilateral brain stem encephalomalacia are also helpful in making this diagnosis. The hemorrhage alone might also make one think of some bleeding disease or poisoning with materials such as spoiled Sweet Clover Hay.

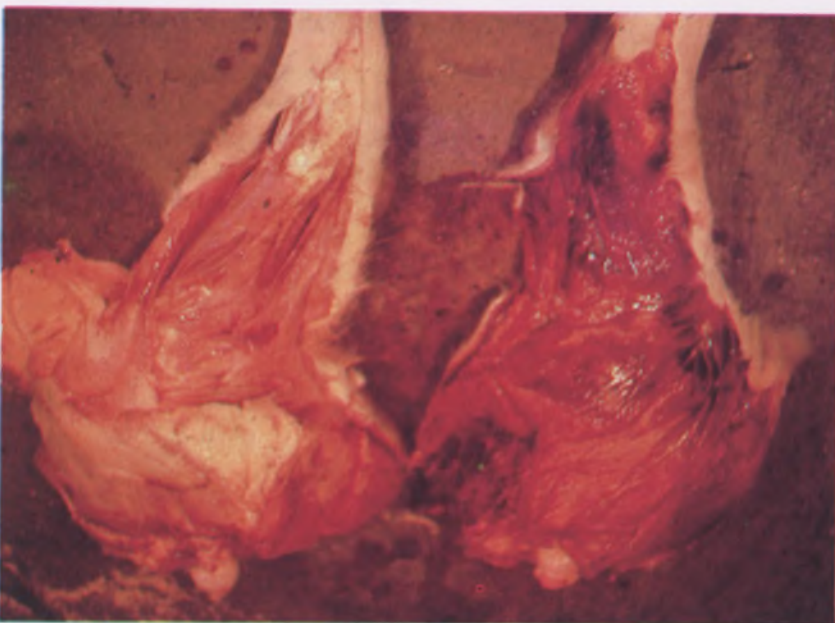
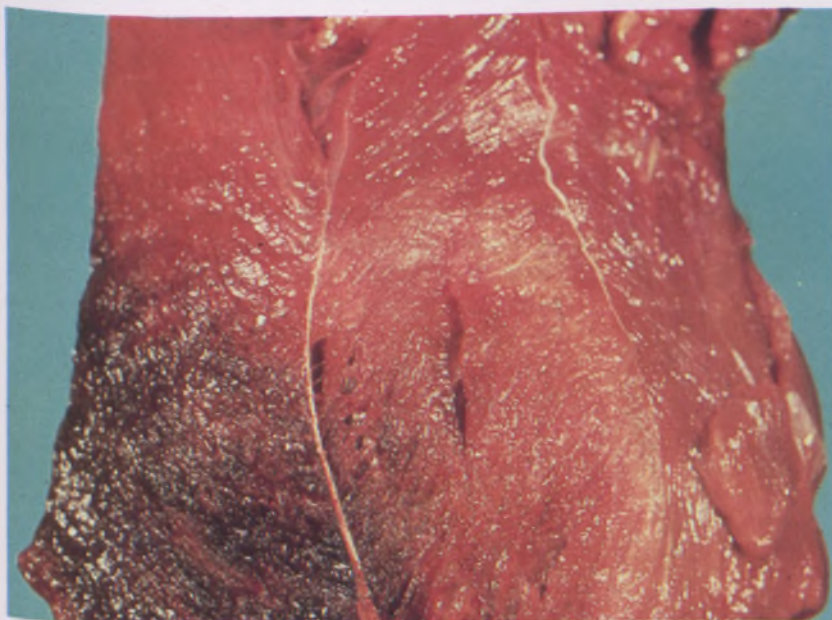


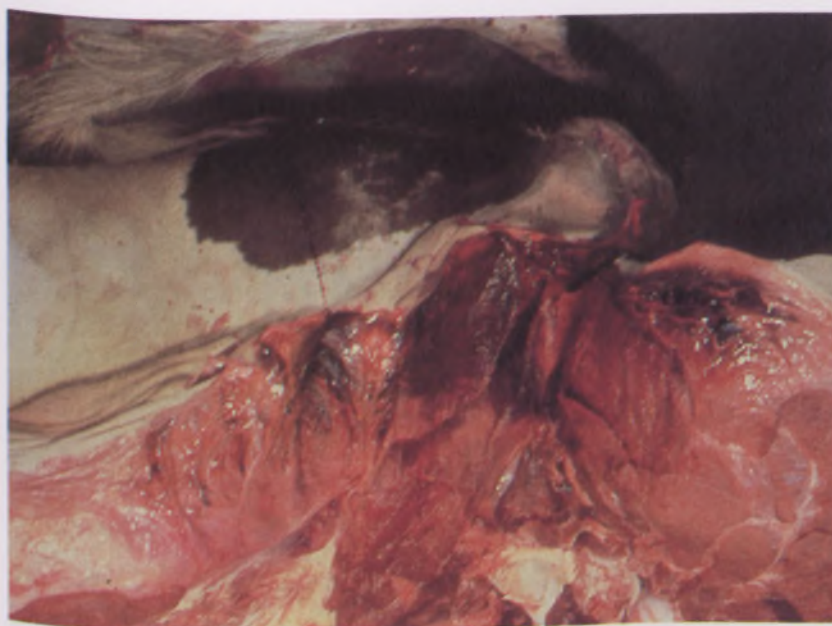PLATE 112: BACTERIAL (*CLOSTRIDIUM CHAUVOEI*) MYOSITIS (BLACKLEG)

The large dark scattered hemorrhagic and edematous areas in one leg as compared to the normal leg are caused by *Clostridium chauvoei*, the causative agent of Blackleg. These areas when freshly cut are often dry with a metallic sheen and emit a sweet odor of fermentation that is thought to smell like the goat acids, capric, caprillic and caproic. Usually no wounds are associated with this disease whereas a similar appearing disease Malignant Edema, caused by *Clostridium septicum*, most often is associated with a wound. Blackleg may also be seen as a focal myositis affecting just the heart or diaphragm.



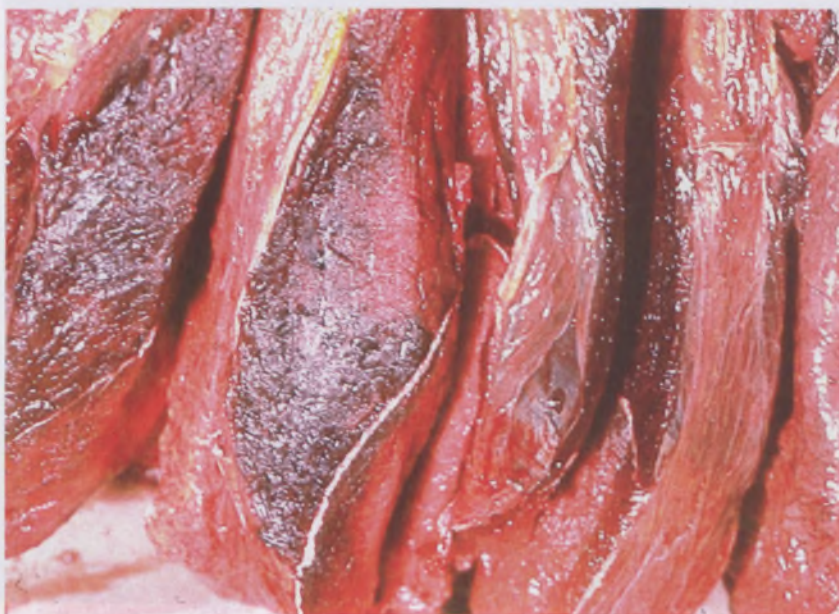**PLATE 113: BACTERIAL MYOSITIS
(BLACKLEG)**

This is a close up view of the gaseous nature of Blackleg caused by *C. chauvoei* in the muscles of a cow. A definite sweet odor of fermentation is also present. Cultures and fluorescent staining techniques are necessary to be definitive.



**PLATE 114: POSTPARTUM BACTERIAL
(CLOSTRIDIUM CHAUVOEI)
MYOSITIS**

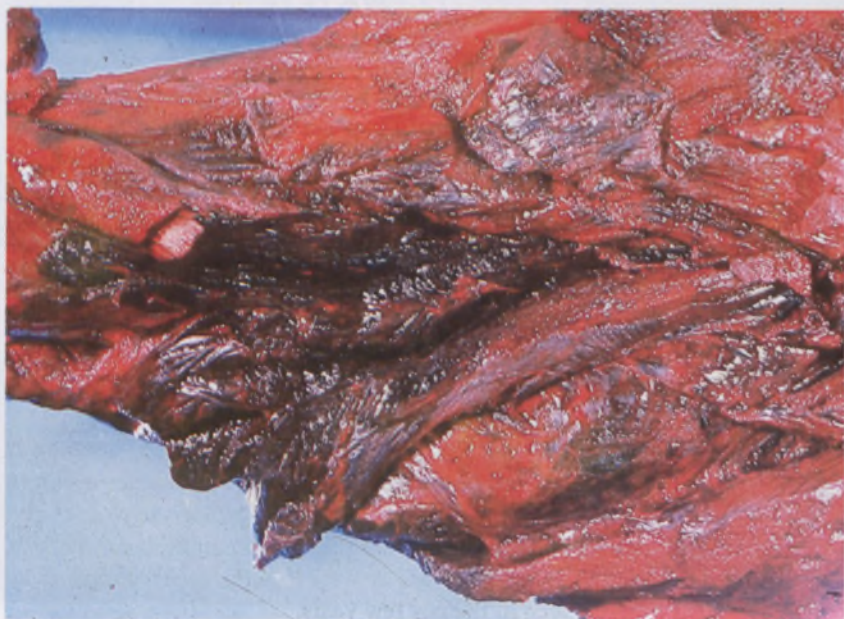The large dark foci are areas of hemorrhage and edema in the muscle associated with some dullness of the muscle itself, gas bubble production, and a distinct sweet odor of fermentation. This is an area of acute Bacterial Myositis, Blackleg, caused by *Clostridium chauvoei*. Most cases are seen as outbreaks in young adult cattle but many are individual, sporadic cases like this one. It was one of several to occur in mature dairy cows 30-60 days after parturition with the lesion in the major muscles of the caudal dorsal hip region, commonly the semimembranosus muscle. The cause of course is *C. chauvoei* and the predisposing factor is recent parturition but the actual mechanism is not known. A wound has not been found in the several cases seen in the last few years.



**PLATE 115: BACTERIAL MYOSITIS
(CLOSTRIDIUM CHAUVOEI)
IN A HORSE**

The distinctly dark red areas of shiny muscle from which a sweet fermentation gaseous smell can be expressed in this horse is a Bacterial Myositis caused by *Clostridium chauvoei*; the cause of Blackleg in cattle. It is indeed rare to find it in a horse but both cultural and fluorescent tests were positive for *C. chauvoei*. The precipitating factor as in cattle is unknown. Both grossly and microscopically this is similar to the disease in cattle.

Dr. S. Shin, Cornell, USA



**PLATE 116: BACTERIAL MYOSITIS
AND CELLULITIS
(CLOSTRIDIUM SEPTICUM)
(MALIGNANT EDEMA)**

This large area of hemorrhagic and edematous muscle involving a major portion of one side of a horse's neck is an acute Bacterial Myositis and Cellulitis caused by *Clostridium septicum* the causative agent of Malignant Edema. Of current interest is the apparent increase of this disease in horses associated with the cervical injections of concentrated nutrients as amino acids and corticosteroids. The actual cause can only be surmised as being a possible contamination problem.

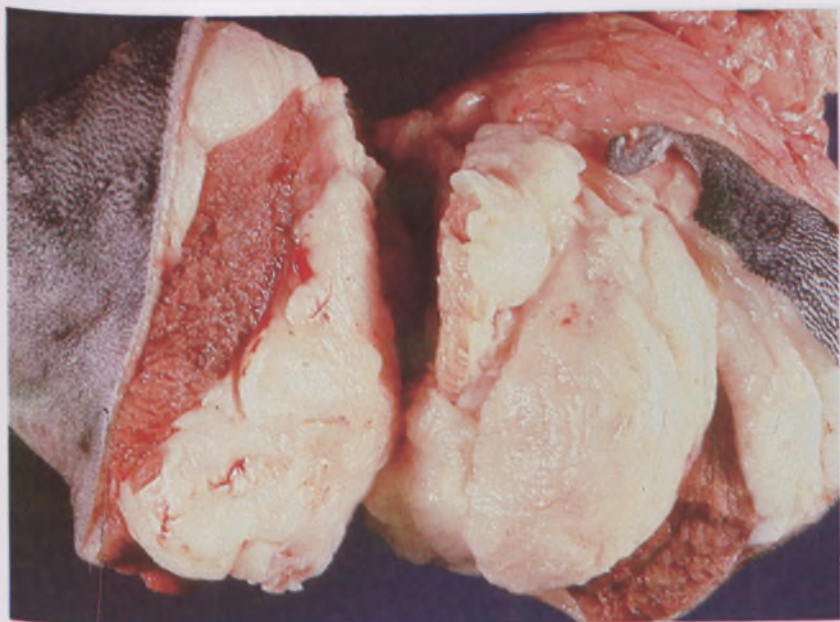


PLATE 117: INFILTRATING LIPOMA

A large mass was present in this horse's leg clinically and biopsy specimens only revealed mature adipose tissue histologically. The horse was killed and this large mass of mature fat tissue was found infiltrating the soft tissues *in situ*. Its benign nature histologically belies its infiltrating gross appearance and a recent journal publication has named them Infiltrating Lipomas. This is to be distinguished from Steatosis which its frank infiltration of muscle bundles with normal depot fat, but in larger than normal amounts bilaterally, in the major muscles of the body. Usually seen in cattle, it is also to be distinguished, when in a dog, from the relatively common, fairly well defined masses of fat, within fat depot areas of the chest and flank, called Lipomas. These latter Lipomas in the dog are also benign histologically and do not infiltrate but they do grow by expansion. Malignant tumors of fat, Liposarcomas, often may not be fatty grossly and there is usually no doubt as to their malignant nature histologically.

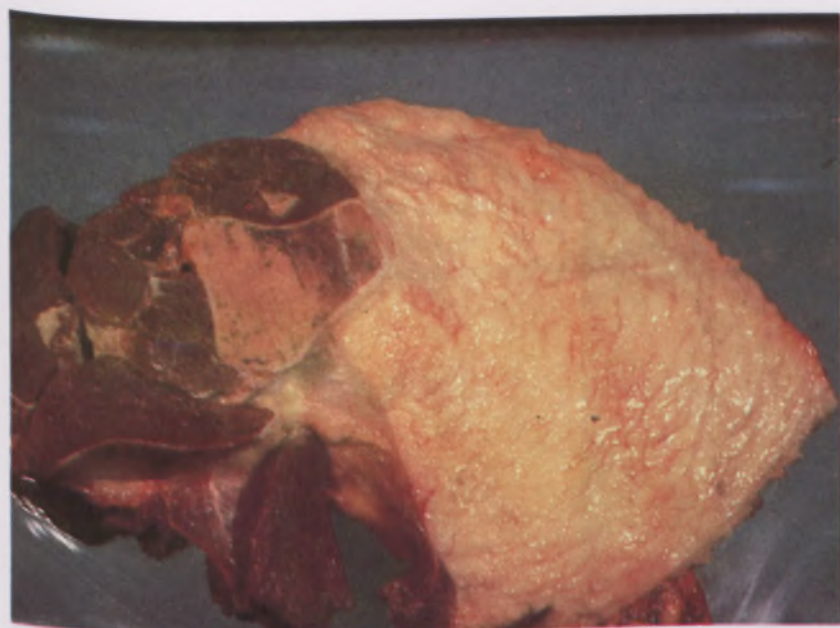

PLATE 118: INFILTRATING LIPOMA

The large masses of fatty tissue invading the fascia about these muscles of the hind limb in a dog are composed of histologically benign, mature adipose tissue. Because it is benign, mature tissue without any histological evidence for malignancy, it has recently been called an Infiltrating Lipoma, in spite of its infiltrating nature grossly. It is practically impossible to remove surgically unless such drastic measures as amputation, as was practiced in this case.

Dr. G. Cockerell, Cornell, USA

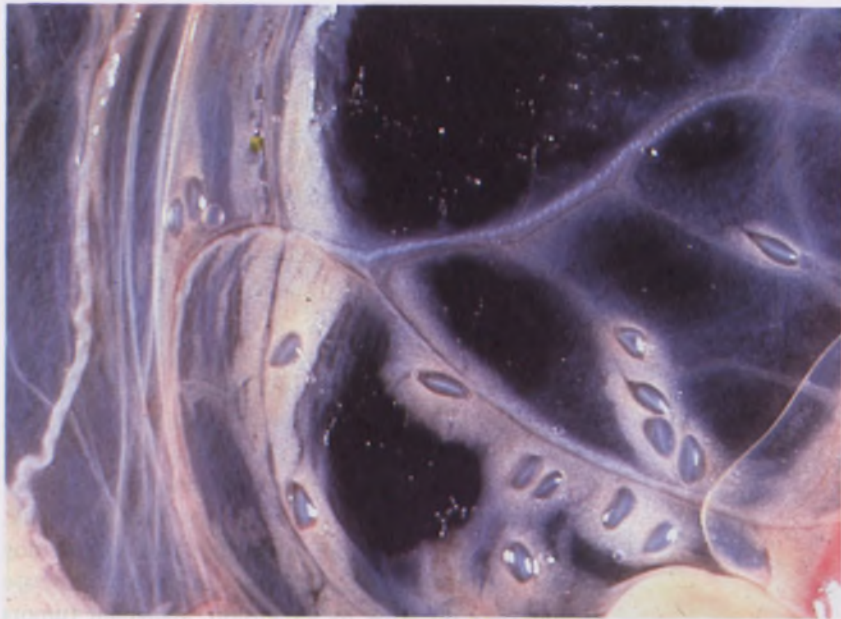


PLATE 119: NORMAL PACINIAN CORPUSCLES

The clear oval structures, scattered in the mesocolon along the nerves of this cat are normal Pacinian Corpuscles. While these are considered to be important in pressure reception, their prominence in the mesocolon and pancreas is not understood.

Dr. G. Cockrell, Cornell, USA
The clear oval structures, scattered in the mesocolon along the nerves of this cat are normal Pacinian Corpuscles. While these are considered to be important in pressure reception, their prominence in the mesocolon and pancreas is not understood.

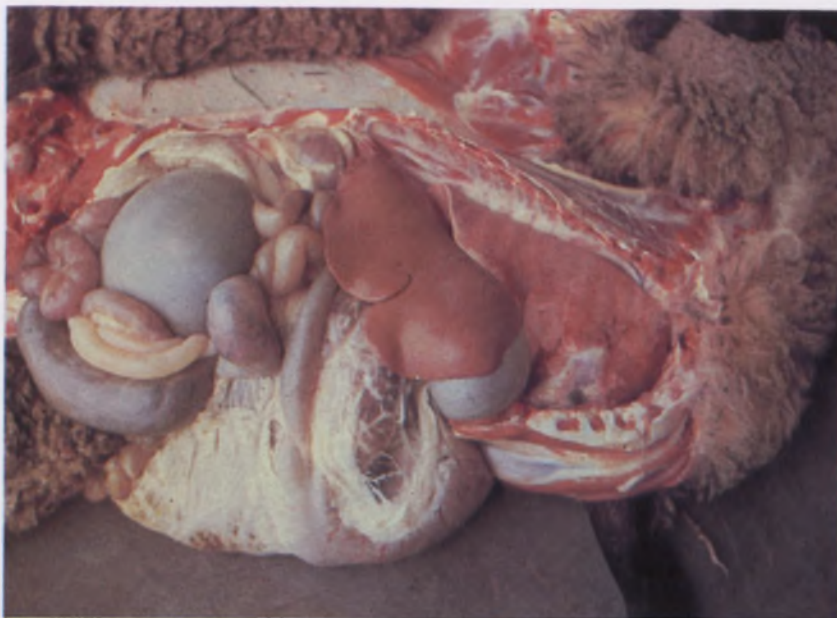

PLATE 120: GENERALIZED ANEMIA

The entire carcass of this sheep is anemic. Stomach worms, *Hemonchus contortus*, are a likely cause in sheep, but many different agents and factors can be involved in animals in general. Bleeding gastric ulcers commonly cause this in pigs and cattle, there is often a distinct sweet odor of fermentation noticed when the stomach is opened.

Dr. G. Cockrell, Cornell, USA

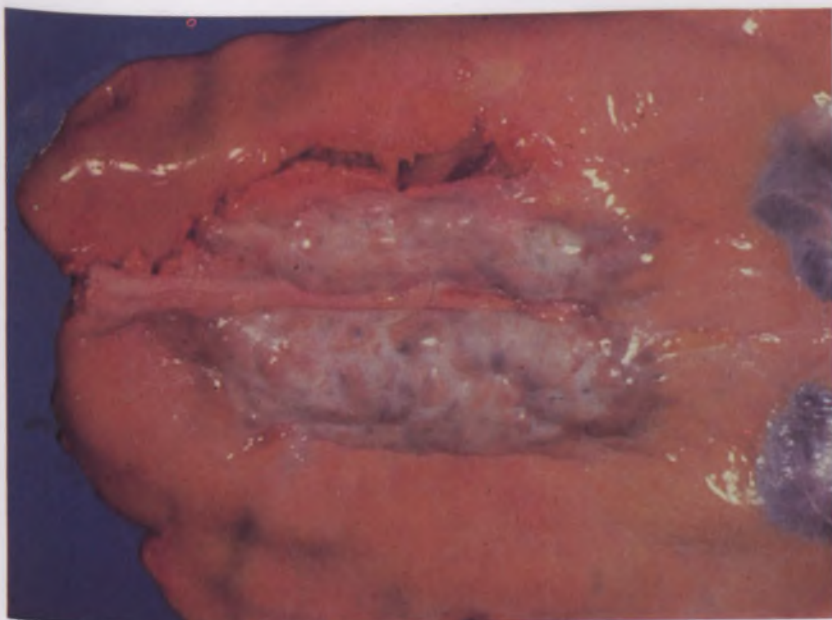

PLATE 121: RETROPERITONEAL FAT NECROSIS AND SCLEROSIS IN THE HORSE

This picture is of the major portion of the ventral abdominal wall seen through its serosal surface. Two large firm granular areas are seen on each side of the midline. These are areas of Retroperitoneal Fat Necrosis and Sclerosis but the cause is unknown. It is usually seen in this ventral abdominal floor area but a recent case also had it high in the caudal region of the peritoneum.

the lesion
problem of some kind it probably the basis for
found in or near the lesion. Therefore a secondary
all more, and in fact presents the usually not

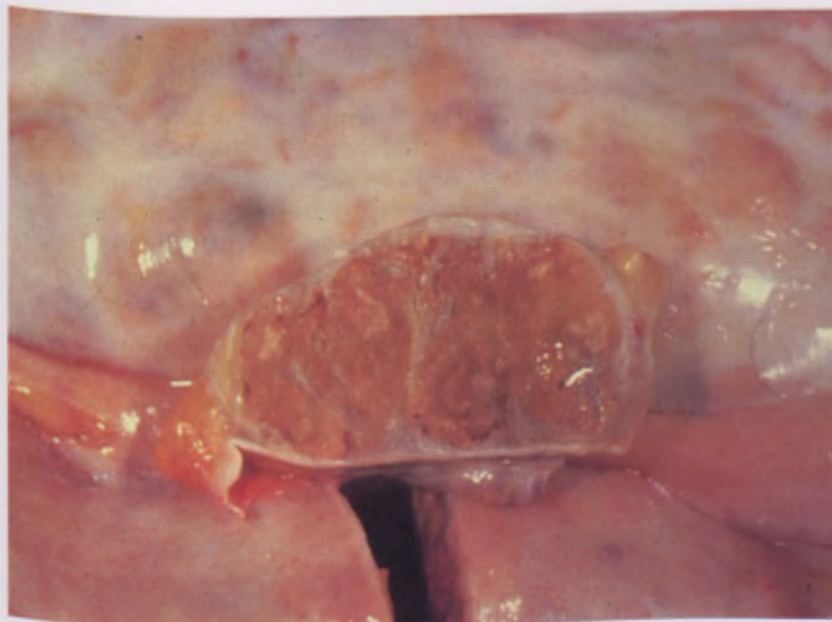

PLATE 122: RETROPERITONEAL FAT NECROSIS AND SCLEROSIS IN THE HORSE

This section of tissue has been taken out of one of the two large 30 x 50 cm plaques of tissue, one lying on each side of the midline of the abdomen adjacent to the sternum in this horse. They bulged into the abdominal cavity as they are large masses of fat necrosis and fibrosis in the retroperitoneum of this area. The cause for this is not known. Most cases are bilateral and in the cranial ventral abdominal floor but one case also had a similar, slightly smaller mass associated with the retroperitoneum near the left ischium at the pelvic inlet. No evidence for trauma has been seen in these areas.

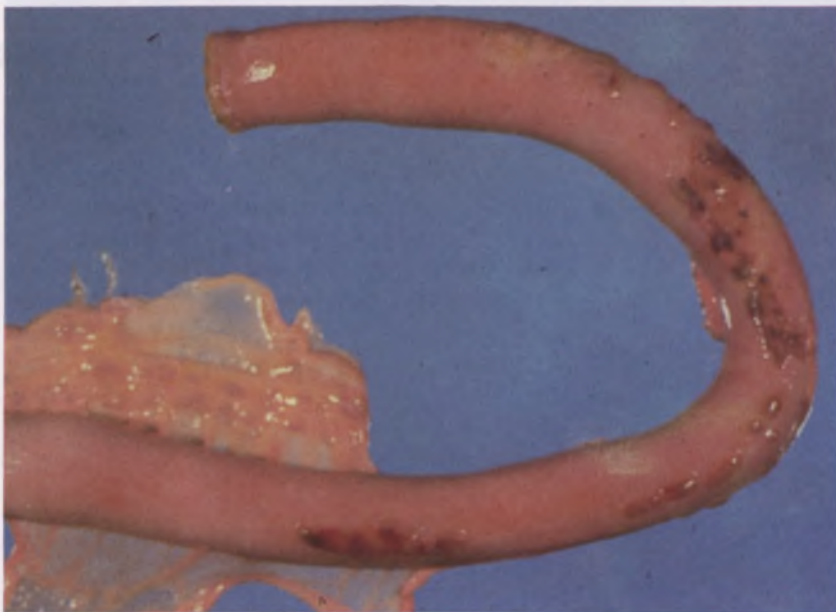


PLATE 123: HEMOMELASMA ILEI

The brown to red plaques of serosal thickening on this horse's ileum are called Hemomelasma ilei. They are usually located opposite the mesenteric attachment as the brown older ones are in the portion of the ileum which normally has one mesenteric attachment. Where the two mesenteric attachments are also found, the Hemomelasma ilei lesion is equidistant from both attachments. The cause of these is unknown though some suspect *Strongylus* spp. larvae migration. This is probably not the only cause, although they may play a part in the pathogenesis. These lesions usually are too symmetrical to be parasite induced. They are often in various stages of development even in older horses. Similar lesions can be seen throughout the small intestine in cases of Granulomatous Enteritis in horses. The lesion can be seen progressing up the mesenteric vessels without direct continuity to the gut serosa, and in fact parasites are usually not found in or near the lesion. Therefore a vascular problem of some kind is probably the basis for the lesion.

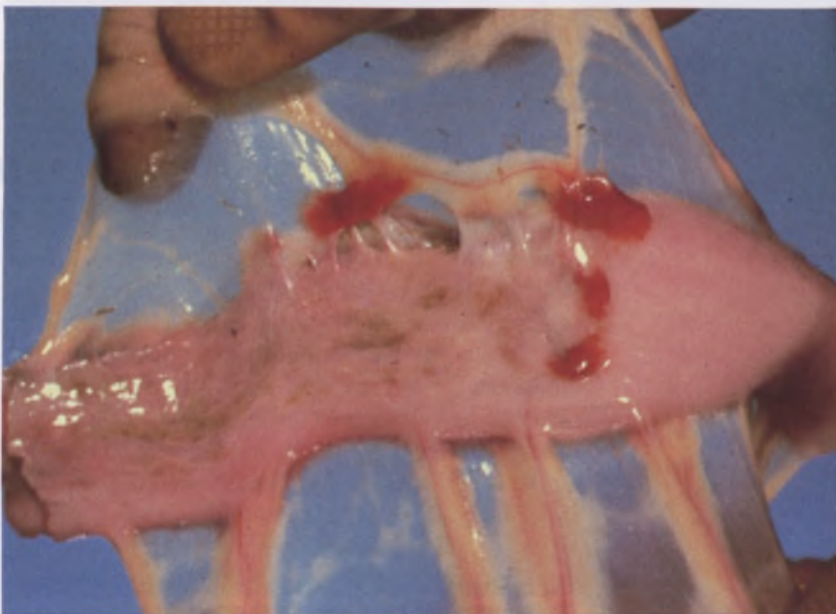


PLATE 124: PROGRESSIVE HEMOMELASMA ILEI

The ileum of a horse is shown here with its two mesenteric attachments, the mesoileum and the ileocaecal fold. On the serosa of the ileum proper can be seen brown stained granulation type tissue called Hemomelasma ilei. At the periphery of this brown, apparently more chronic reaction, is a more acute hemorrhagic lesion which even extends up the mesentery a short distance. This is a progressive form of this lesion of Hemomelasma ilei. The actual cause is unknown although a vascular basis is probably at fault. *Strongylus vulgaris* larvae may be one of the causative factors.

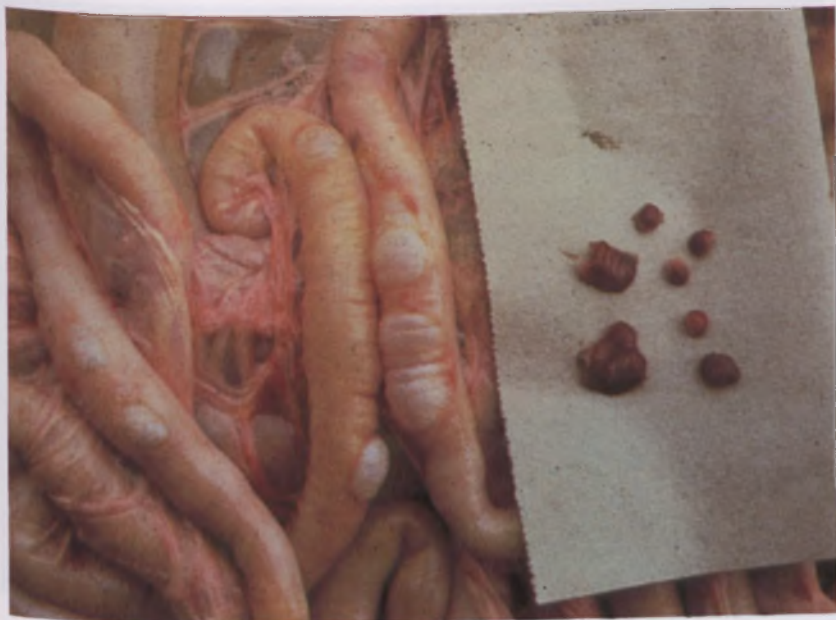

PLATE 125: HEMOMELASMA ILEI

The several dark brownish red bits of tissue on the paper towel are the actual lesions of *Hemomelasma ilei* which have been removed to show that there is no continuous lesion direct from the mucosa and through the tough whitish submucosa. Parasites were not found in any of these pieces. The actual cause of this is not known but a vascular problem is suspected. In one experiment with young parasite free foals, inoculation with pure cultures of *Strongylus vulgaris* larvae resulted in the production of many acute lesions of this type.

surface of the lamina propria is usually marked by the irregular growth of the tissue into a mass of firm tissue while both "lipomas" are usually homogeneous collections of normal fat. Often any of these masses can wrap themselves around segments of bowel to cause strangulation of the bowel.

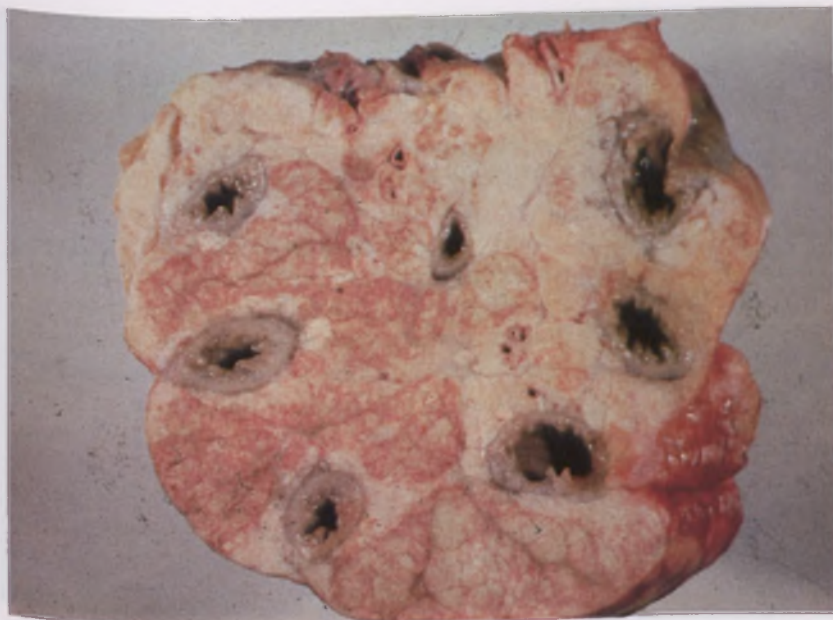

PLATE 126: GRANULOMATOUS FAT NECROSIS

The large masses of fat around these cross sections of intestine are firm and fibrotic with the increased connective tissue seen as grey strands of tissue scattered in the mass of fat. This is Granulomatous Fat Necrosis. The cause is unknown but it is quite common in the Channel Island breeds of Guernsey and Jersey cattle, having a genetic basis in these cattle. It is also seen in some cattle on Fescue grass. These animals often die as a result of intestinal obstruction.

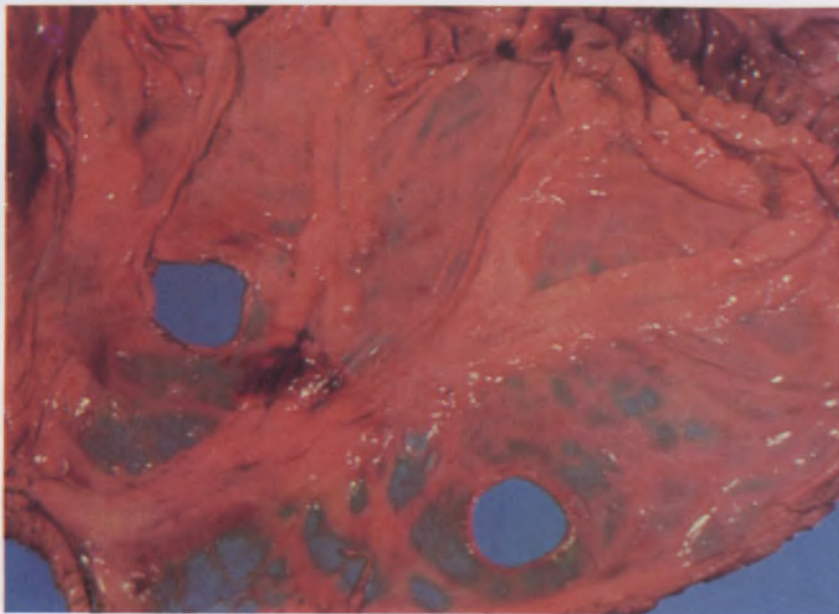


PLATE 127: MESENTERIC HERNIAL RINGS

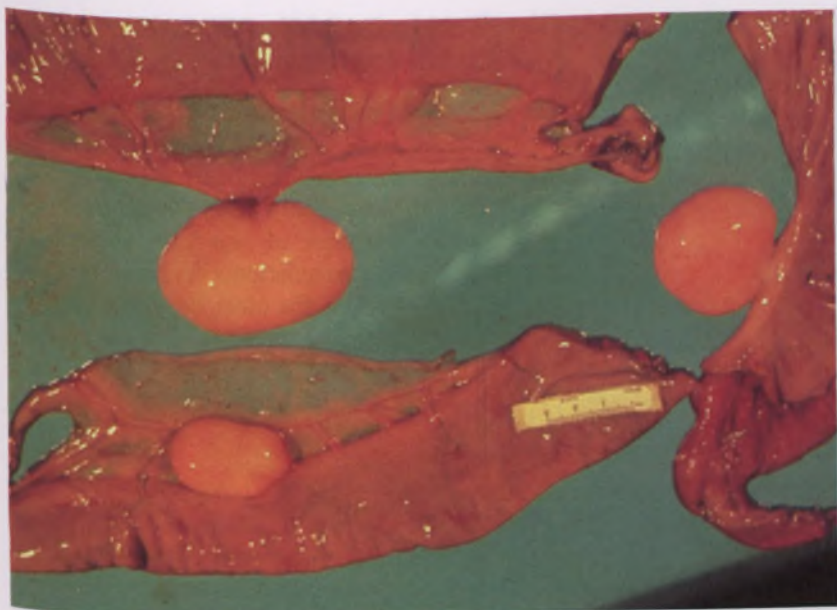
The two, small, several centimeter diameter holes in this mesentery have a definite thickened rim of tissue some of which is fat and some connective tissue. These Hernial Rings had a piece of bowel through them which had strangulated to kill the horse. The cause of these holes is unknown as the horse was just a pastured horse without a history of prior surgery, bullet wounds or the like.

get across, and in fact sometimes are usually not found in or near the lesion. Therefore a vascular problem of some kind is probably the basis for the lesion.

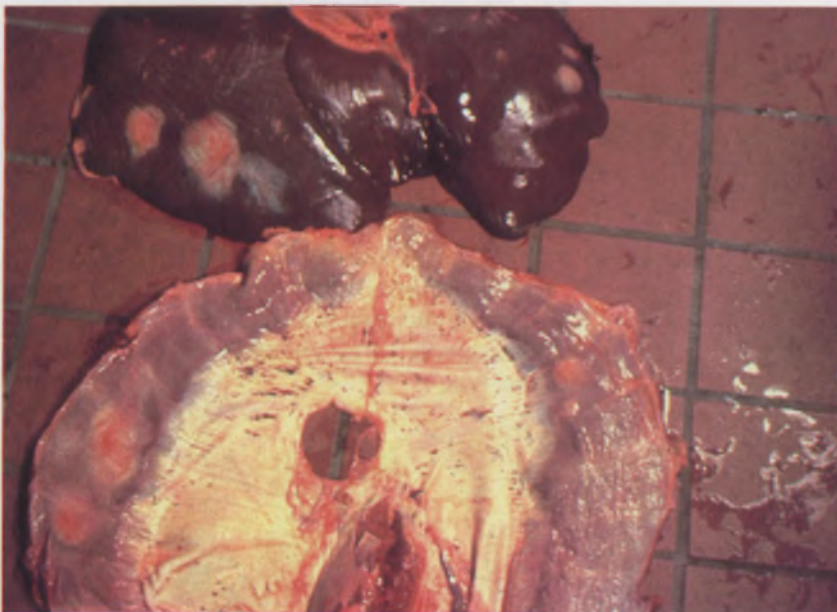

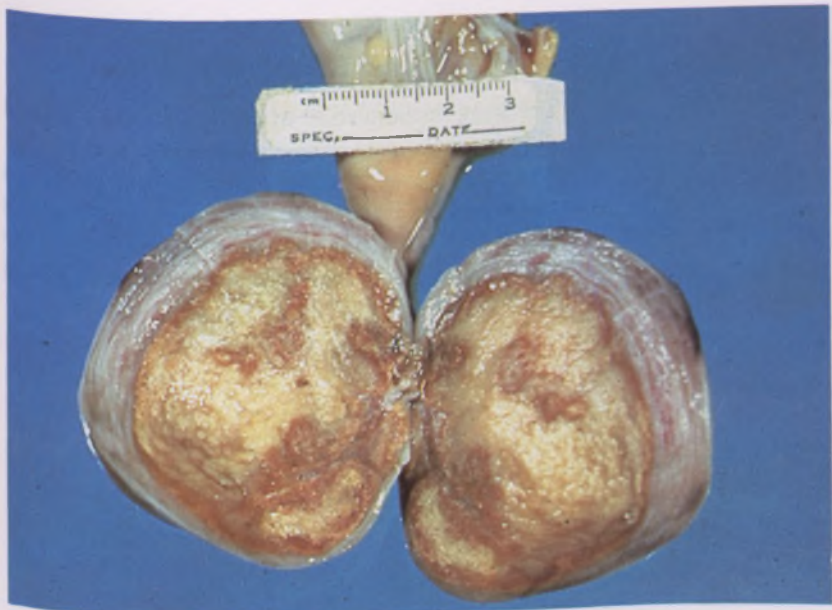
PLATE 128: PERITONEAL FIBROTIC PLAQUES

The dark linear streaks in the tendinous center of the horse's diaphragm are terminal hemorrhages and of no significance. On the peritoneal surface of the muscular part of the diaphragm are four distinct foci of fibrosis which have their exact counterparts on the diaphragmatic surface of the liver. The cause of these Focal Peritoneal Fibrotic Plaques are unknown but they are common in horses. One suggestion is that they represent areas of fibrosis as the result of some form of non-infectious peritonitis with fibrin formation which was held in these areas between the liver and diaphragm by capillary action until it was organized. Even more common than these large plaques are the multiple small Fibrous Tags on the liver and diaphragm probably with the same pathogenesis.



**PLATE 129: PEDUNCULATED
"LIPOMAS" AND
LEIOMYOMA**

Intestinal segments from three horses are shown here. The largest, pale, fatty mass attached with only a short peduncle is a Pedunculated "Lipoma", a metabolic mass of depot fat, not a true tumor, which are very common in fat horses and less so in fat cows. The smallest mass also touching the intestine but attached to the mesentery is also a Pedunculated "Lipoma" although it has a sessile attachment and not a pedunculated one. The third mass, although it looks similar, is quite firm and one can see its direct attachment to the smooth muscle taenia of this portion of colon. This is a Leiomyoma, a benign, true neoplasm of smooth muscle. The two Pedunculated "Lipomas" are very soft but they can be firm when the pedunculated stalk twists and the mass becomes mineralized. The cut surface of the Leiomyoma is usually streaked by the irregular growth of the tumor into a mass of firm tissue while both "Lipomas" are usually homogeneous collections of normal fat. Often any of these masses can wrap themselves around segments of bowel to cause strangulation of the bowel.



**PLATE 130: NECROTIC PEDUNCULA-
TED "LIPOMA"**

This relatively nondescript mass of tissue at the end of a stalk is very firm and has a definite connective tissue capsule. This is a Necrotic, Pedunculated "Lipoma" from a horse. Normally, many focal accumulations of fat are found in fat horses which develop from small blebs of fat that continue to enlarge with normal depot fat to become pedunculated. The stalk may then allow twisting which cuts off the blood supply to the fat more or less and the fat then mineralizes. Its necrotic properties stimulate the connective tissue seen here. These, as well as the nonmineralized masses, can cause bowel strangulation and they often do. The term Lipoma is an old one and is incorrect as these are not true neoplastic growths.

Peritoneum

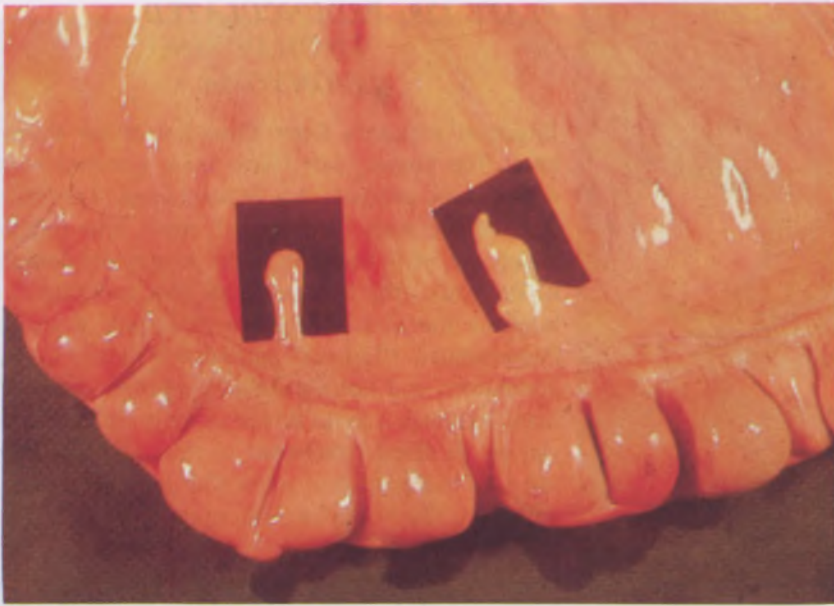


PLATE 131: EARLY PEDUNCULATED "LIPOMAS"

The two polyps backgrounded with black plastic are two fat filled early stages of Pedunculated "Lipomas". These will often continue to enlarge with metabolic depot fat. When large enough these may twist around a segment of bowel and cause bowel obstruction and strangulation. These are not true neoplasms in spite of the older name that persists.

surface of the lipoma is usually treated by the irregular growth of the tumor into a mass of firm tissue while both "lipomas" are usually homogeneous collections of normal fat. Often any of these masses can wrap themselves around segments of bowel to cause strangulation of the bowel.

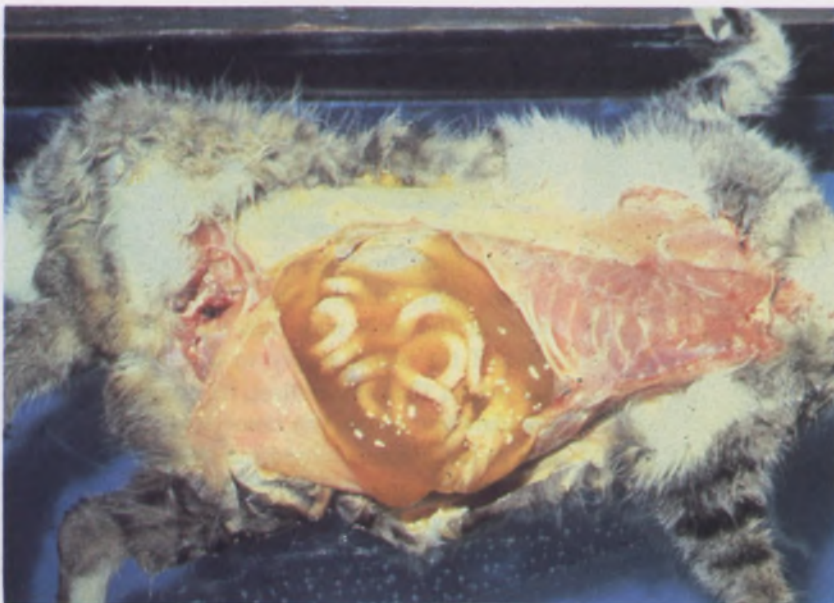


PLATE 132: ACUTE TO SUBACUTE PERITONITIS

The large accumulation of semisolid, yellow ascitic fluid is an Exudate with enough fibrin in it to clot after the animal had died from Feline Infectious Peritonitis (FIP). Many small, opaque white nodules of fibrinous necrosis can be seen adherent to the serosa of the intestines and in the omentum. This is the Wet Form of FIP, a viral disease of cats.

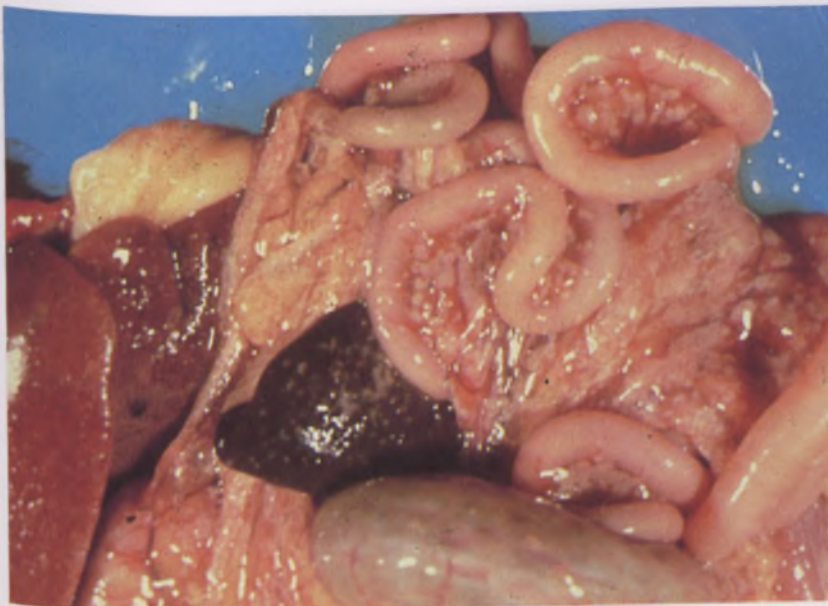

PLATE 133: FELINE INFECTIOUS PERITONITIS (FIP)

The peritoneum over the spleen, liver and omentum have numerous pale white foci of necrosis scattered throughout. Only relatively few are on the intestinal serosa proper. This is one of the forms of Feline Infectious Peritonitis, a viral disease of cats. Most cases also have these focal necrotic areas on the gut serosa.

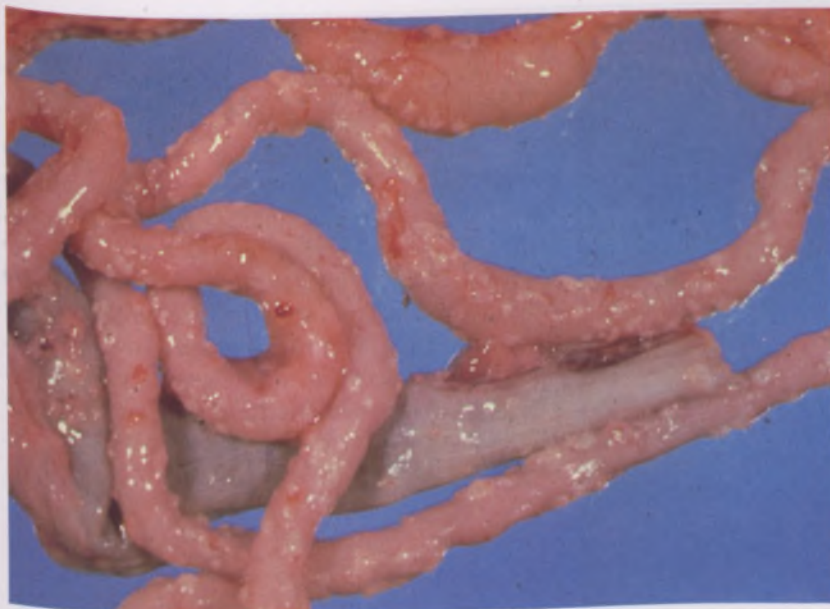

PLATE 134: FELINE INFECTIOUS PERITONITIS

The multiple, small, white foci scattered on the intestinal serosa of this cat are areas of Subacute Fibrinous Necrosis caused by the virus of Feline Infectious Peritonitis (FIP). These foci are usually scattered over all the abdominal viscera, mesentery and omentum and in a few cases on the pleura. Varying degrees of ascites and hydrothorax are usually seen. When a great deal is present it is usually referred to as the Wet Form of FIP. Joint and meningeal involvement is also occasionally seen. Histologically, the lesion is characterized by a well marked necrotizing vasculitis.

Peritoneum

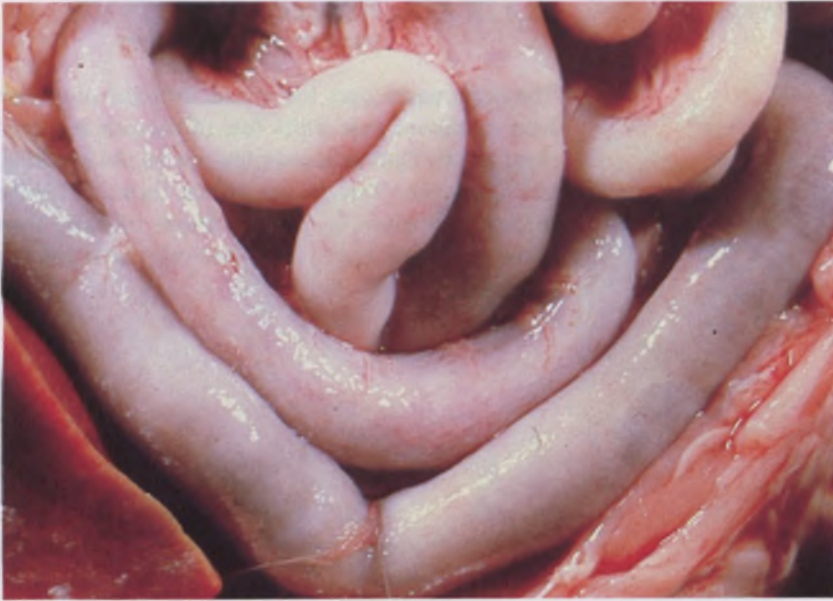

PLATE 135: SEROSAL GRANULARITY

The very fine granularity of the serosa covering this dog's intestine is due to an apparent focal serosal thickening that is seen in cases of Infectious Canine Hepatitis (ICH) and in cases of Canine Parvovirus Disease. It is probably due to a surface lymphatic reaction but its real cause is not known. The liver in ICH will often have this lesion in its capsule.

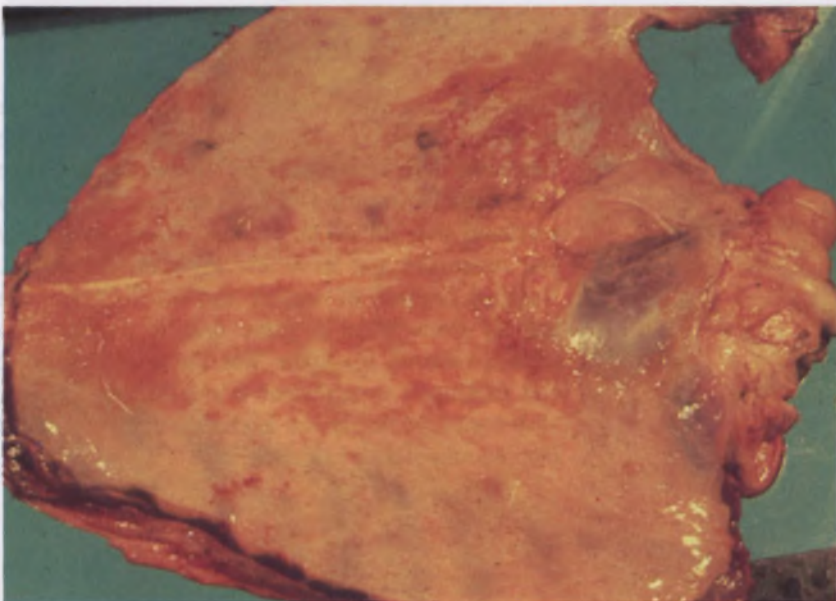
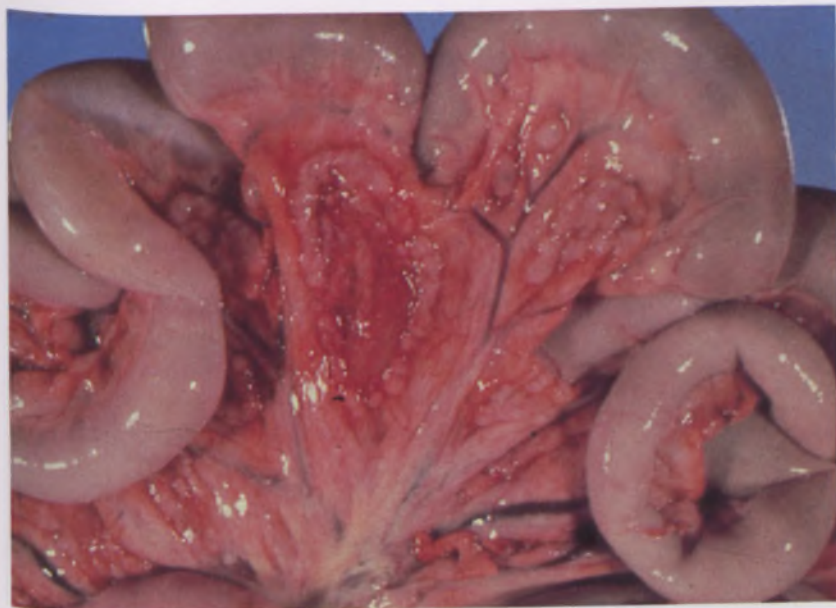


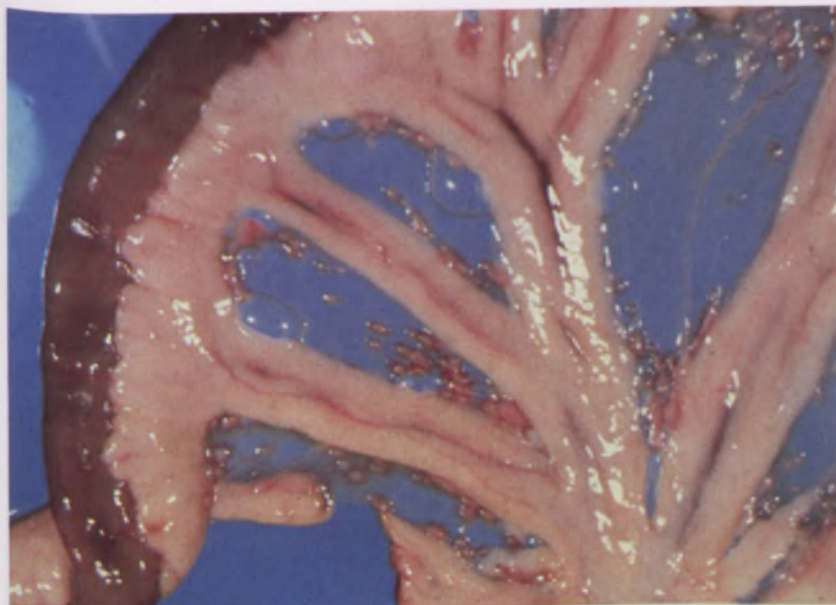
PLATE 136: CHRONIC PARASITIC (*STRONGYLUS EDENTATUS*) PERITONITIS

The roughened peritoneum on both sides of the midline of this horse's ventral abdominal wall is Parasitic Peritonitis caused by *Strongylus edentatus*, many of which are seen on and under the peritoneum itself. The several purple foci are areas of hemorrhage caused by the parasite under the peritoneum. Most *S. edentatus* are usually in the retroperitoneum in the vicinity of the kidneys but with more severe infections they may be more generally spread and even found ectopically in various organs like the lung and liver.



**PLATE 137: METASTATIC
ADENOCARCINOMA**

The mesenteric festoons of this dog's intestines have firm, white nodules in a line along side the mesenteric vessel tracts. These are Implantation foci or Embolic foci of a Pancreatic Adenocarcinoma. The exact mechanism for how these neoplasms get to this area and in this specific distribution is unknown.



**PLATE 138: METASTATIC GASTRIC
ADENOCARCINOMA**

This loop of dog's intestine and attached mesentery shows many small nodules of malignant Gastric Adenocarcinoma in the smaller vessels of the mesenteric web, and not as expected in the major vessels and nerves. The actual mechanism for the metastatic spread of this tumor is not known, but we have seen it several times in different species.

No explanation for this is readily available.
cells could be found in the area of metastatic adenocarcinoma.
the gastrointestinal tract. Only a few tumor

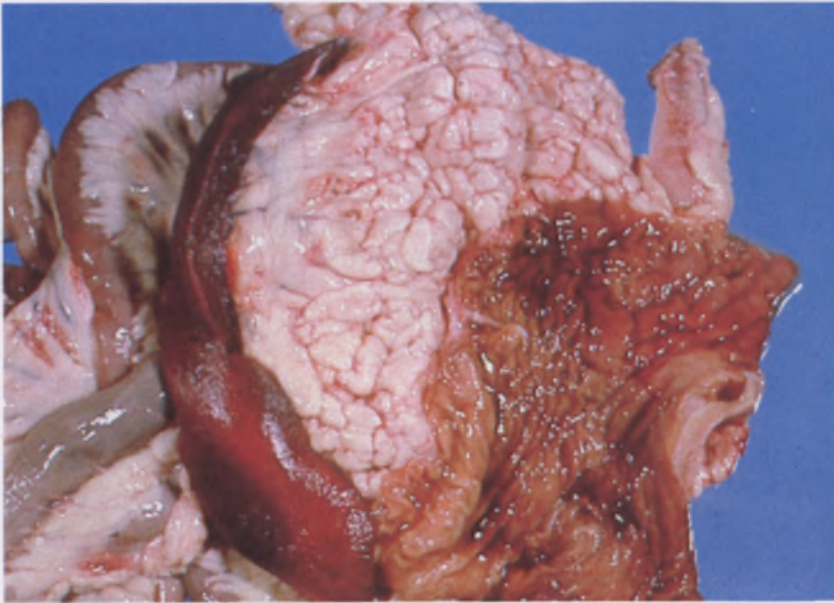


PLATE 139: NEOPLASTIC GASTRO-SPLENIC OMENTAL SCLEROSIS (FIBROSIS)

The gastro-splenic omentum is thrown up into many nodules by an apparent increase of connective tissue which has matured and constricted to form this pattern. When seen, this is almost always due to a Metastatic Sclerosing Adenocarcinoma from the bowel or pancreas. In this case, it is due to a gastric carcinoma that is not apparent here. It is surprising but characteristic that there is so much connective tissue in these affected areas as only a few neoplastic cells can be found.

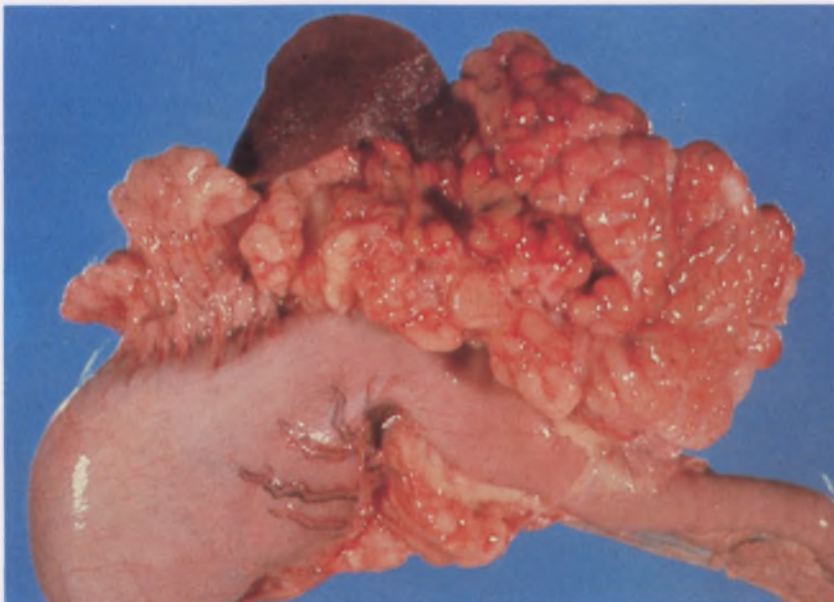


PLATE 140: NEOPLASTIC GASTRO-SPLENIC OMENTAL SCLEROSIS (FIBROSIS)

Between the pylorus and the ventral end of this dog's spleen, the gastro-splenic omentum is markedly firm and nodular, with greyish streaks of new connective tissue scattered in it. It is also congested in places. This is a relatively unique lesion and is seen mainly with metastatic adenocarcinomas of the bowel or pancreas and it affects primarily only this area of the omentum. Histologically, there are very few tumor cells to be seen in the area of sclerotic fat and it is often difficult to find those. This is to be differentiated from a Sclerosing Adenocarcinoma *in situ* or even one that has metastasized to another organ as the lung and caused sclerosis there. This dog had an adenocarcinoma of the colon and its primary metastatic site was this gastrosplenic omental area. Only a few tumor cells could be found in this area of marked sclerosis. No explanation for this is readily available.

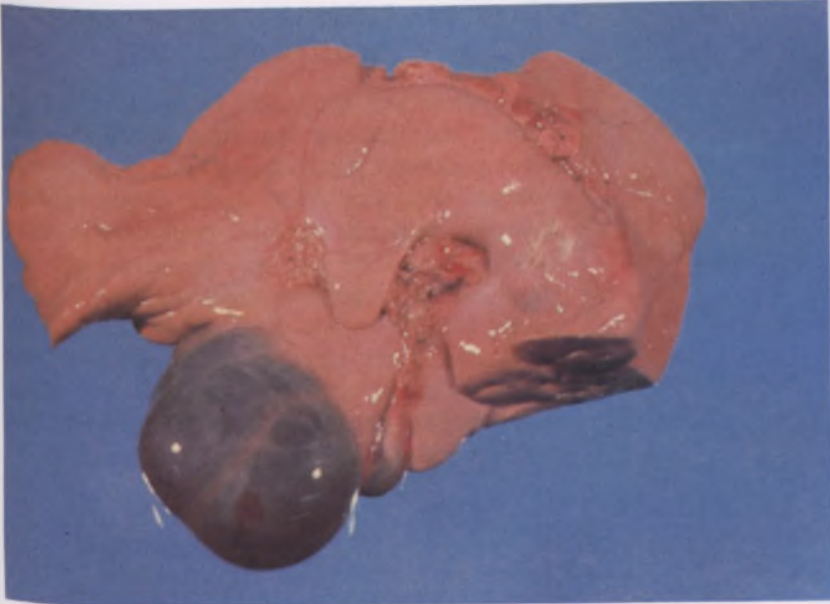


PLATE 141: CONGENITAL HEPATIC CYSTS

The large clear cyst in the region of the left lobe near the umbilical fissure (not shown) and to the side of the gall bladder is a very common Hepatic Cyst of calves. Its origin is not known. They are often filled with clear watery fluid and the lining epithelium varies in each case from simple cuboidal to simple squamous. Some consider them of biliary origin and others of possible peritoneal origin. These usually disappear early in life. We have found no connection to the bile ducts in our cases. An anomalous ventral mesentery may be involved.

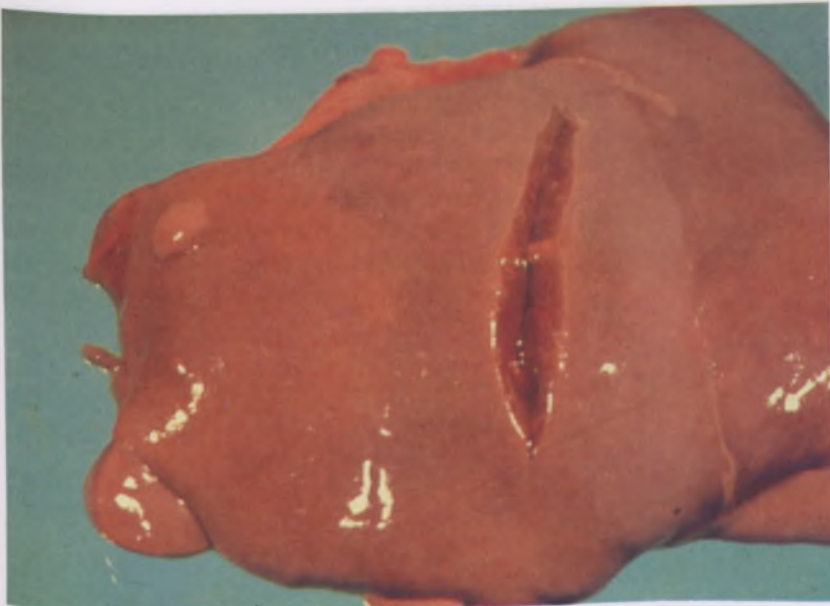


PLATE 142: HEPATIC HAMARTOMAS

One pale nodule is seen protruding from the surface and one is seen in the middle of the cut surface on this fetal bovine liver. These are nodules of liver cord cells normal in appearance but grouped in discrete foci called Hepatic Hamartomas. Hamartomas are redundant masses of tissue normal to the area in which they are found. Some call them Fetal Tumors. Most are vessel related. No known cause has been established. These are not rare in bovine fetuses or newborn calves.

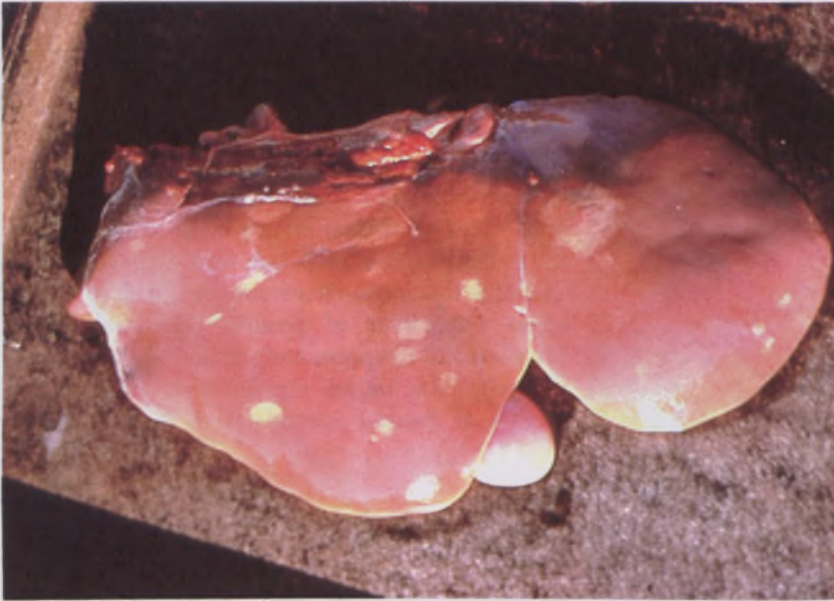

PLATE 143: POSTMORTEM DECOMPOSITION (AUTOLYSIS)

The discrete pale white foci in this sheep's liver, without any reaction are areas of Postmortem Decomposition or Autolysis. All livers are not sterile even in life, thus when death occurs resident organisms, generally anaerobic, proliferate to make these "lesions". They also are carried through the portal system to the liver from the bowel if the carcass is moved while the blood is still fluid. In some cases, if the agonal period is prolonged, the intestinal barrier may break down and allow bacterial showering of the liver before death. Gas bubble production can be marked in these areas.

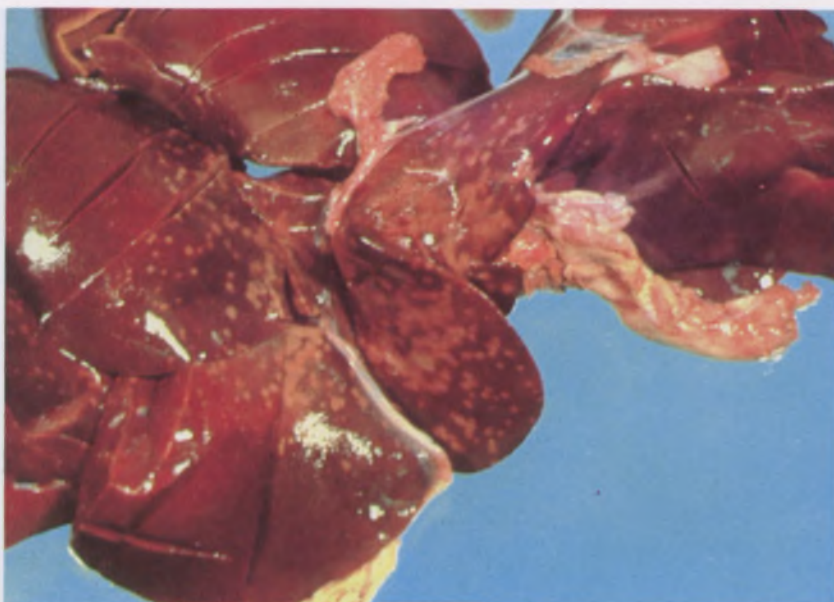


PLATE 144: POSTMORTEM DECOMPOSITION (AUTOLYSIS)

The very discrete pale foci primarily in the hilar area are classical foci of Autolysis or Postmortem Decomposition in this pig's liver. Their limitation in this case, to the hilar areas of the liver lobes, suggests that these are spread postmortem via the portal vein, and probably not from a postmortem proliferation from resident bacteria sometimes present in the liver.

the gastropleuric connective site. Only a few tumor cells could be found in this area of marked sclerosis. No explanation for this is readily available.

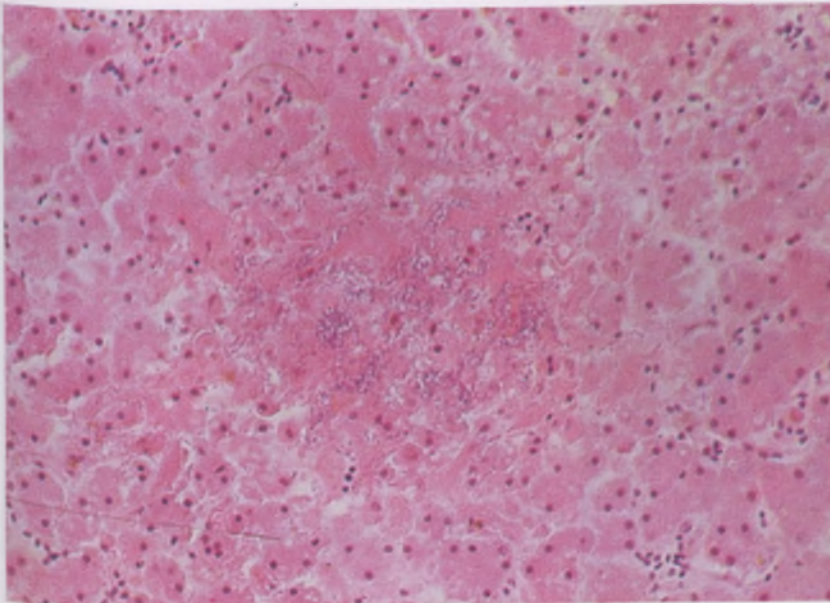
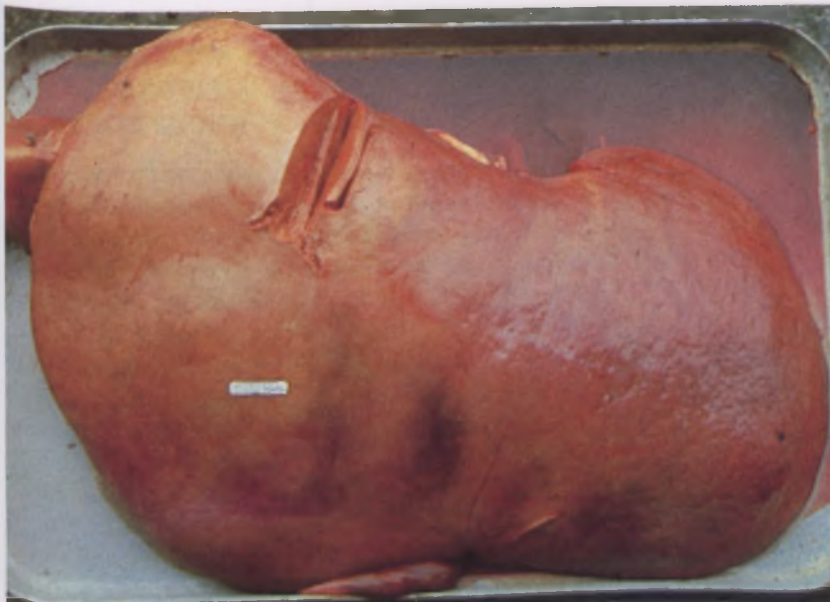


PLATE 145: POSTMORTEM BACTERIAL CONTAMINATION (AUTOLYSIS)

This clump of bacteria in the sinusoids of an animal's liver has no evidence of host response because it is a near terminal, or Postmortem Bacterial Contamination. It might be a very acute bacterial invasion of less than several hours duration, but without specific knowledge of the case it is usually best to consider these initially as a common Postmortem Bacterial Contamination. It should not be considered Focal Necrosis.

PLATE 146: FATTY LIVER SYNDROME



The extremely enlarged fatty liver came from a high milk producing dairy cow that went off feed and milk production and in which no other lesions were found. This is a common finding in such cases and we have usually just called it Metabolic Death or Fatty Liver Syndrome. If a mastitis, displaced abomasum, metritis or some other obvious problem exists we would usually classify it under one of those names and add words to the effect that the fatty liver was secondary to the primary problem. In this disease Ketosis is not a constant feature. Of course, Metabolic Death is a very broad term and must have more specific, modifying terms given with it. The difference between Fatty Degeneration and Fatty Infiltration is that with Fatty Degeneration one also finds evidence as icterus that the liver has failed metabolically whereas with Fatty Infiltration there is no evidence of liver failure *per se*. In this Fatty Liver Syndrome it is Fatty Infiltration and not Fatty Degeneration.

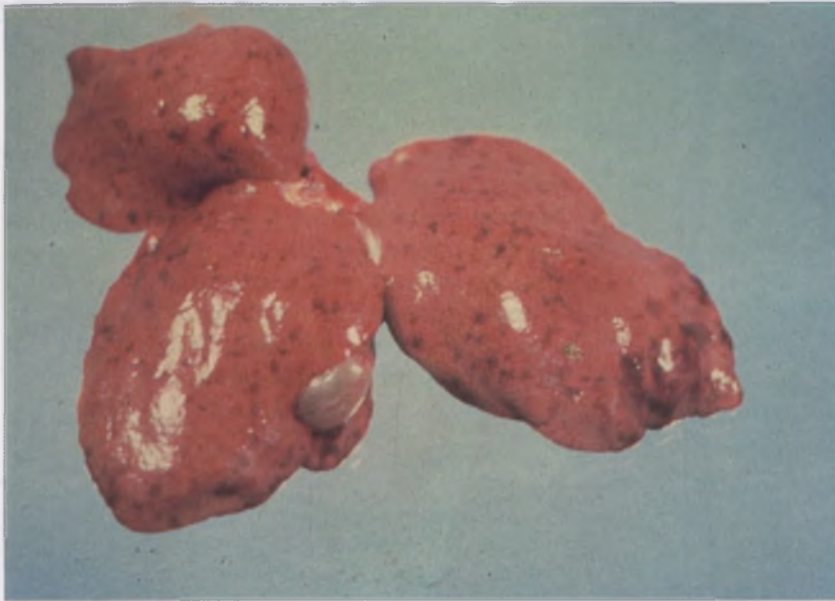

PLATE 147: TELANGIECTASIS

The multiple dark red foci, some of which are depressed and others elevated, are areas of focal dilatation of the hepatic sinusoids and are foci of Telangiectasis. This is very common in older cats, cattle, mink, ferrets, and young castrated bulls. The cause is unknown, but a hormonal upset is possible. It is a very common problem in the Dominican Republic where up to 80% of the cattle livers may be condemned because of this lesion.

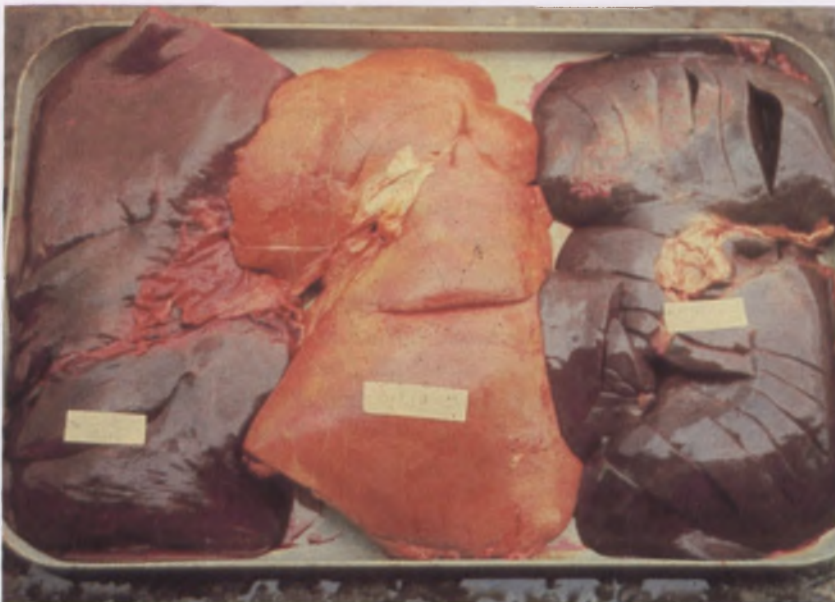

PLATE 148: ACUTE MASSIVE NECROSIS WITH ATROPHY, HEPATIC LIPIDOSIS AND STARVATION ATROPHY

The middle yellow liver is about two times normal size as a result of an improper lipogenic diet in this pony, Lipidosis. The dark liver with a large plaque of fibrosis on its surface is about one half normal size. It is much darker than normal and firm. It is the end result of chronic starvation in which all the fat, glycogen and some protein have been removed from the cells for survival i.e. Starvation Atrophy. The other, not so dark, liver is also from a large horse and its liver is about one half normal size. It is however extremely flaccid; we call it a Dishrag Liver, as the result of Massive Liver Necrosis associated with Theiler's Disease. This disease is related to the injection of a horse product, and 60-90 days later the horse may die with severe icterus, mania and a small, flaccid (Dishrag) liver.

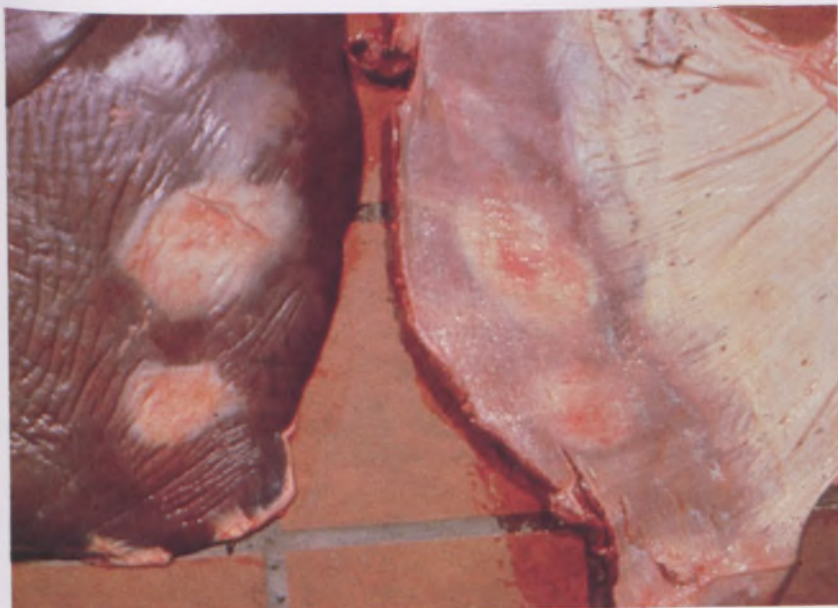

PLATE 149: MULTIFOCAL FIBROTIC PLAQUES

The two large fibrous plaques on the capsule of this liver, and their two corresponding ones on the diaphragm, are thought to be the result of capillary action holding fibrinous debris between the surfaces until they had granulated in to make this lesion. They are very common in horses and one or more may be present. This horse had four on the liver and correspondingly four on the diaphragm.

Dr. M. Smith, Cornell, USA
 liver, even if the cause is in the heart, the lesion in the liver may not affect all the liver equally. This is explained by some areas of the liver being drained of blood more easily and more freely, possibly because of hepatic vein anatomy, and also some areas may have less blood flow into them and thus be less affected by passive congestion.

PLATE 150: CONGESTIVE CARDIOMYOPATHY

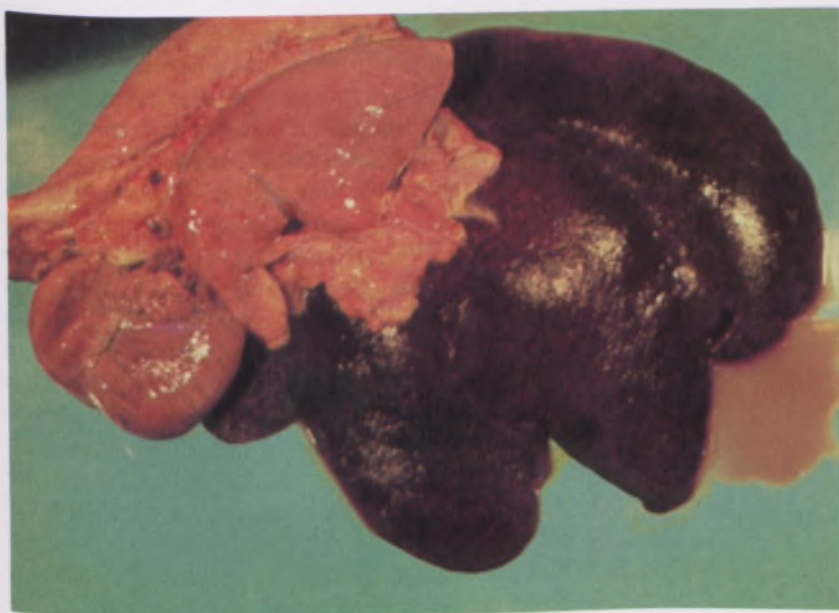
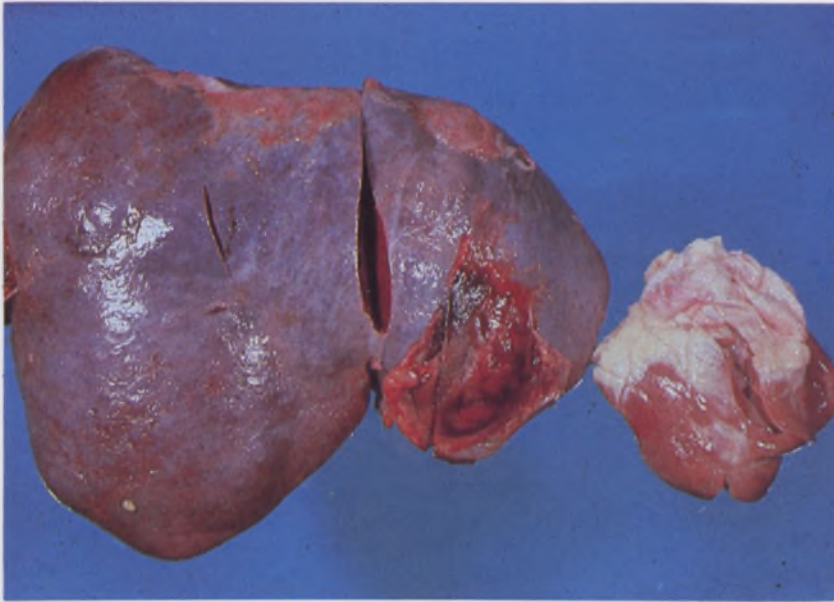


PLATE 150: CONGESTIVE CARDIOMYOPATHY AND CHRONIC PASSIVE CONGESTION (NUTMEG LIVER)

The enlarged dark liver shows the classic mottled appearance of Chronic Passive Congestion (Nutmeg Liver). The cause is usually from a heart lesion as it is in this case of a Congestive Cardiomyopathy. When the heart is weak, the blood fails to move "cardially" and instead backs up to the liver to cause the problem. Heart anomalies in young pigs commonly cause this. Most cases, but not all, of Nutmeg Livers in any species result in ascites.

Dr. J. Rein, Oklahoma, USA
 time to reach the threshold for regeneration. This is not a universally accepted explanation, but definitions in the various texts have differed. One reports to be simple and the most common



Dr. M. Smith, Cornell, USA

PLATE 151: MYOCARDIAL ATROPHY AND CARDIAC CIRRHOSIS

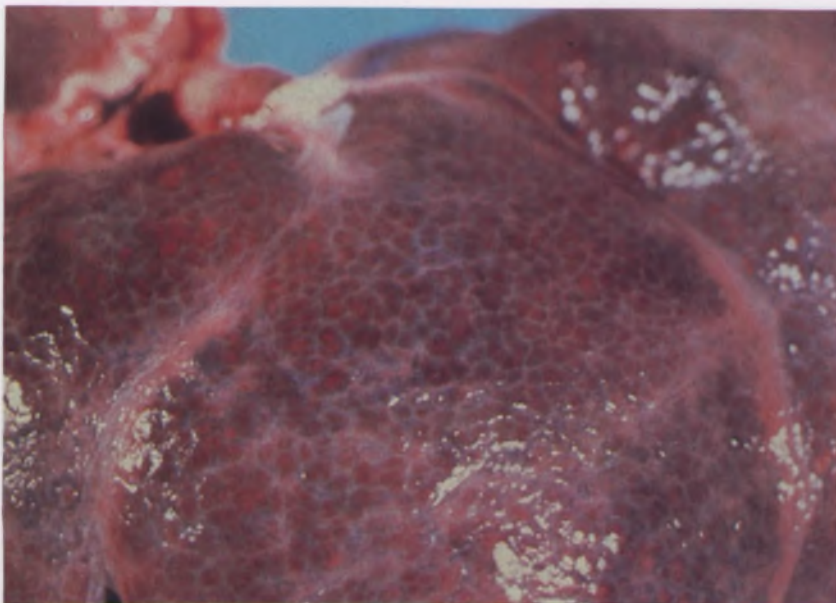
The enlarged goat's liver is the result of Chronic Passive Congestion (Nutmeg Liver), to the stage of Cardiac Cirrhosis. Cirrhosis is defined in this text as the increase of connective tissue in the same location of all or almost all hepatic lobules. In this case it would be in the central vein areas. Also shown in this picture is the cause of the Nutmeg Liver, the dilated, flaccid right atrium, auricle and part of the ventricle. This Myocardial Atrophy and Fibrosis is secondary to White Muscle Disease, a Vitamin E/Se Responsive disease that affected this goat and many others in the flock 6 months previously. The fibrin and connective tissue on the liver capsule is the result of the Ascites caused by the Nutmeg Liver.

Of note is the fact that in some cases of Nutmeg Liver, even if the cause is in the heart itself, the lesion in the liver may not affect all the liver uniformly. This is explained by some areas of the liver being drained of blood more easily and completely, possibly because of hepatic vein arrangement, and also some areas may have less blood flow into them and thus be less affected by passive congestion.

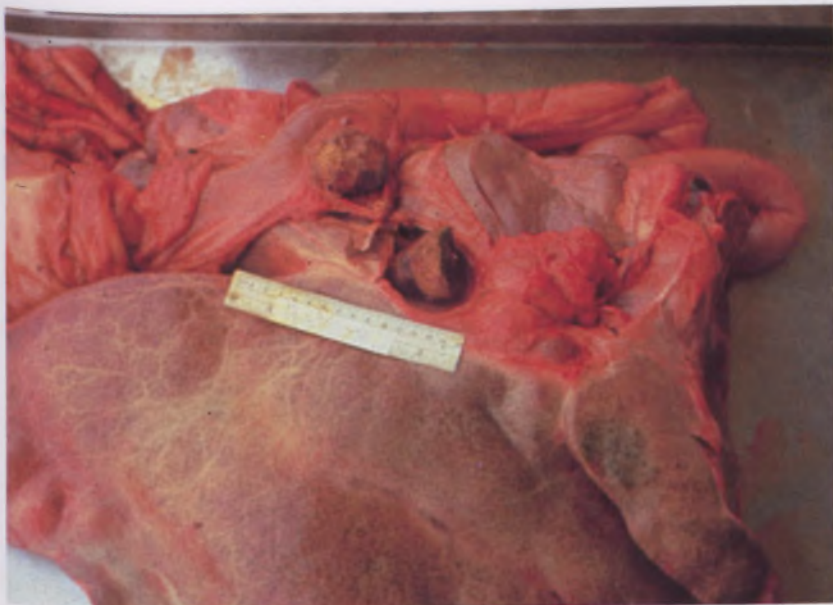PLATE 152: CARDIAC CIRRHOSIS

This is a case of Cardiac Charrhosis.

The fine reticular patterns of connective tissue that appear to be around each hepatic lobule, are in reality in the central vein areas of each lobule, and have joined together with the connective tissue from adjacent lobules in this case of Cardiac cirrhosis. It was caused by chronic congestive heart failure in this dog. Verrucous endocardiosis, heart anomalies and similar causes of right heart failure can cause this. It is Cirrhosis and not plain Fibrosis because each and every lobule has been affected in a similar fashion relatively to more or less the same degree. In Fibrosis only parts of lobules or parts of the liver are involved. For instance, in Postnecrotic Scarring or traumatic damage to the liver only the irregular damaged areas are replaced by fibrous connective tissue. Regeneration of the liver is not involved in either instance of connective tissue increase unless enough liver is damaged at one time to reach the Threshold for Regeneration. This is not a universally accepted explanation, but definitions in the various texts also disagree. This one appears to be simple and fits most conditions



Dr. L. Reth, Oklahoma, USA



**PLATE 153: CHOLESTEROL CALCULI
AND PORTAL CIRRHOSIS**

Large Cholesterol Calculi are in the hepatic duct and have effectively blocked it to cause icterus and a diffuse increase of connective tissue, around the portal areas of each and every hepatic lobule, a case of Portal Cirrhosis. It is of course, a form of fibrosis, but as it affects each and every lobule to the relative same extent and area it should be called Cirrhosis. No compensatory nodules of regeneration are seen as the liver was damaged slowly and not enough damage was done at any one time to reach the Threshold of Regeneration which is 15–20% in some species.

Dr. C. J. Liu, Taiwan, R.O.C.

**PLATE 154: MULTIPLE DIAGNOSTIC
LIVER LESIONS**

The liver at the 12 o'clock location is from a dog with the natural form of lymphoma. At 1 o'clock is a dog's liver with Cardiac Cirrhosis from chronic congestive heart failure. The large piece of

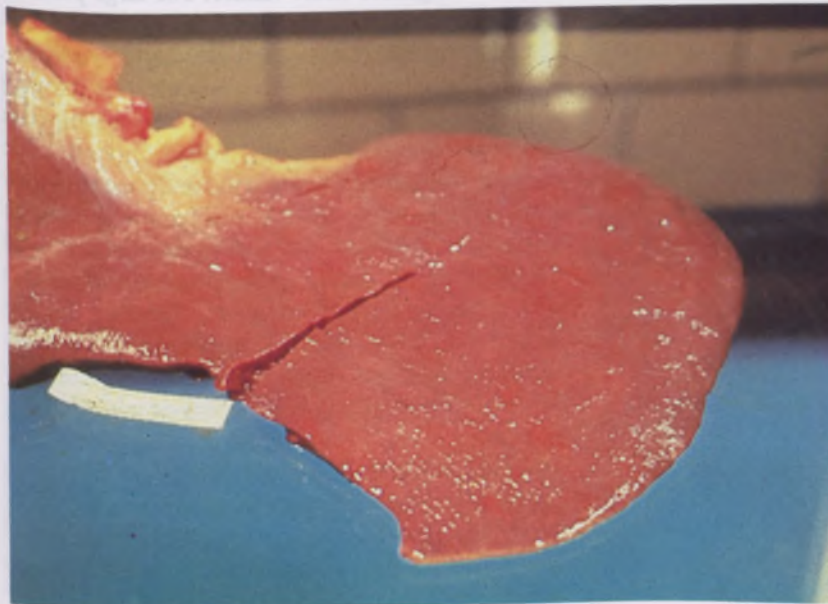


PLATE 154: COMPRESSION ATROPHY

Approximately one half of this bull's liver is shown here. It is very flattened as a result of Compression Atrophy. This condition is usually caused by one of the large portions of gut trapping the liver between it and the abdominal wall. This occurs more frequently in the horse than the cow. Most of the time the remaining liver will enlarge to compensate.

Dr. C. J. Liu, Taiwan, R.O.C.

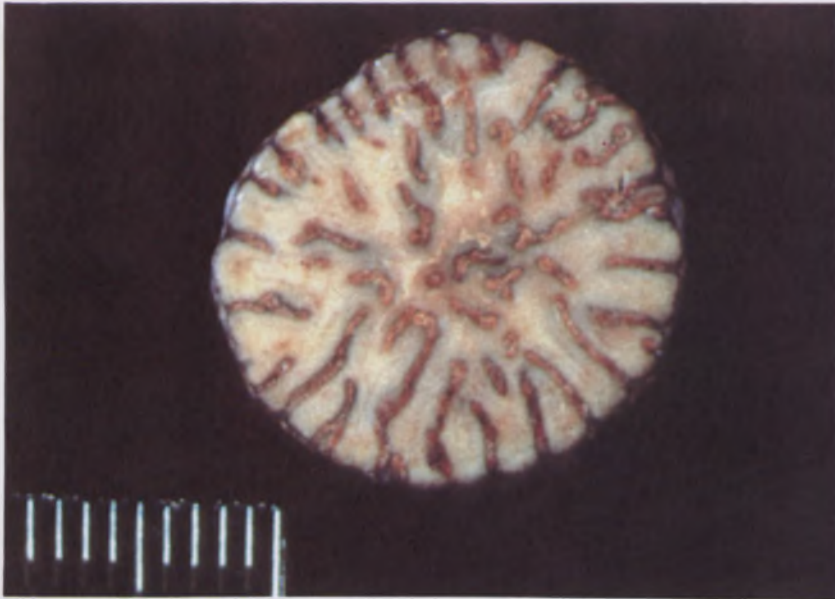

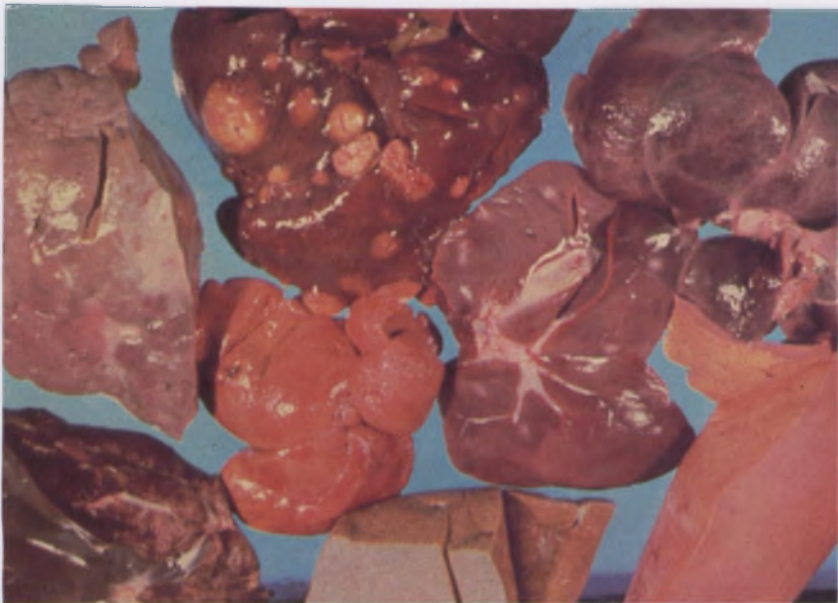PLATE 155: NUTMEG

This is the cross section of a Nutmeg, the aromatic kernel of the fruit of on East Indian tree. This is the structure by which the pattern of the liver in Chronic Passive Congestion has been named, a Nutmeg Liver.

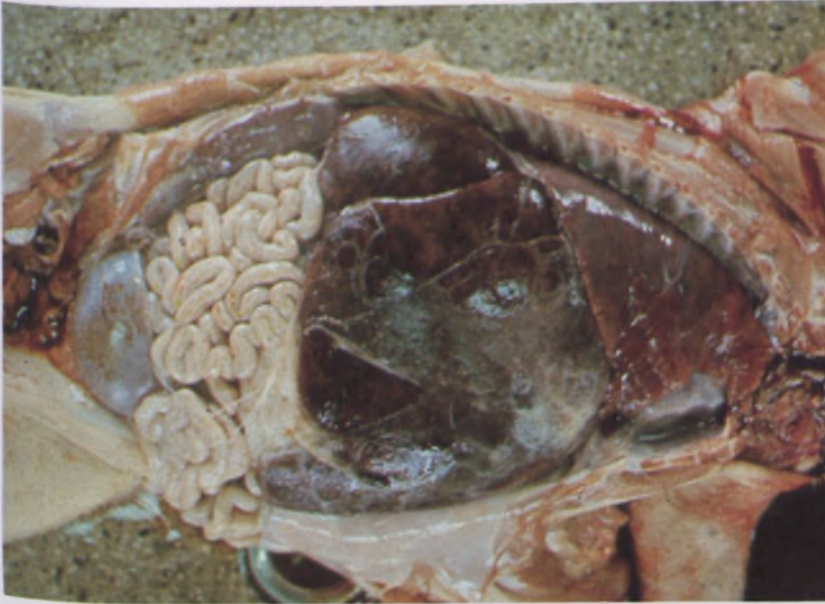
Dr. N. Smith, Cornell, USA

PLATE 156: MULTIPLE DIAGNOSTIC LIVER LESIONS

The liver at the 12 o'clock location is from a dog with the nodular form of Lymphosarcoma. At 1 o'clock is a dog's liver with Cardiac Cirrhosis from chronic congestive heart failure. The large piece of liver at 4-5 o'clock is from a cow with Hepatic Lipidosis associated with the Fatty Liver Syndrome. At 6 o'clock is a portion of a horse's liver showing a diffuse fibrosis of the entire liver involving each and every portal area, called Portal Cirrhosis. The classical Nutmeg or Chronic Passive Congestion liver from a horse with chronic pericarditis is seen at 7 o'clock. Between 9-10 o'clock the scattered dimpled, fibrotic areas mixed among normal areas is very diagnostic for Postnecrotic Scarring in any animal. This was a horse that apparently had a single access to a hepatic toxin. The small swollen liver in the middle touching the dog's liver with Nodular Lymphosarcoma and the horse liver with Post Necrotic Scarring is a cat's liver with diffuse Lymphosarcoma. The last liver also in the center but at the 3 o'clock side is a pig's liver with a few foci of Parasitic Fibrosis caused by ascarid migration.



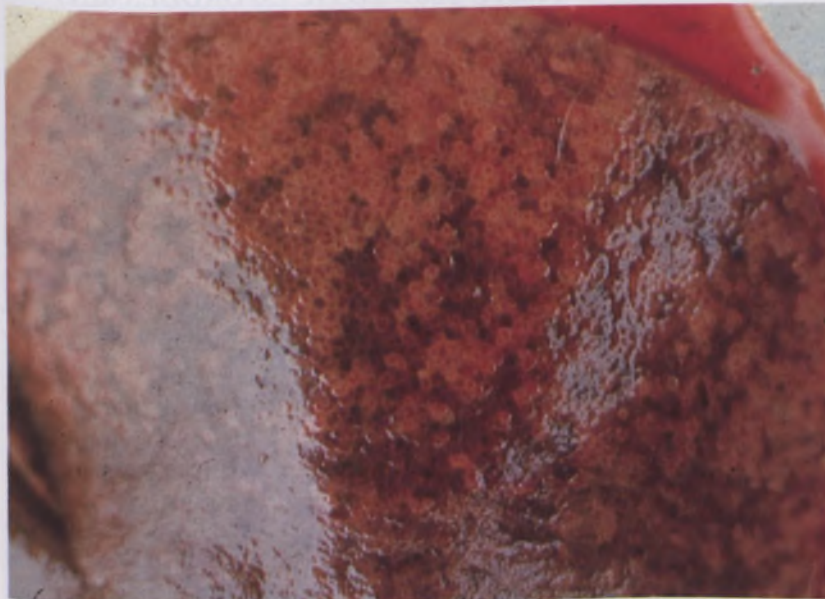Dr. L. Roth, Oklahoma, USA



Dr. C.I. Liu, Taiwan, ROC

**PLATE 157: TOXIC (ASPHALT
CONTAMINATED TALLOW)
HEPATOSIS**

The markedly enlarged mottled liver with sheets of fibrin on its surface is the result of acute Massive Liver Necrosis caused by toxins which leached into beef tallow from asphalt lined storage drums. Over 50,000 pigs died as a result. The liver lesion is a massive centrolobular hemorrhagic necrosis.



Dr. C.I. Liu, Taiwan, ROC

**PLATE 158: ACUTE TOXIC (ASPHALT)
CENTROLOBULAR
HEMORRHAGIC
NECROSIS**

Almost every lobule in this pig's liver is affected with acute Centrolobular Hemorrhagic Necrosis, seen here as the red centers of each lobule. The pale zone around these red centers are the remaining viable cord cells at the periphery of the lobules. The smallest zone seen here is the fine grey connective tissue that surrounds and connects each lobule to the next. This Central Hemorrhagic Necrosis is the result of a toxic principle present in asphalt, probably phenols, which contaminated beef tallow and killed over 50,000 pigs.

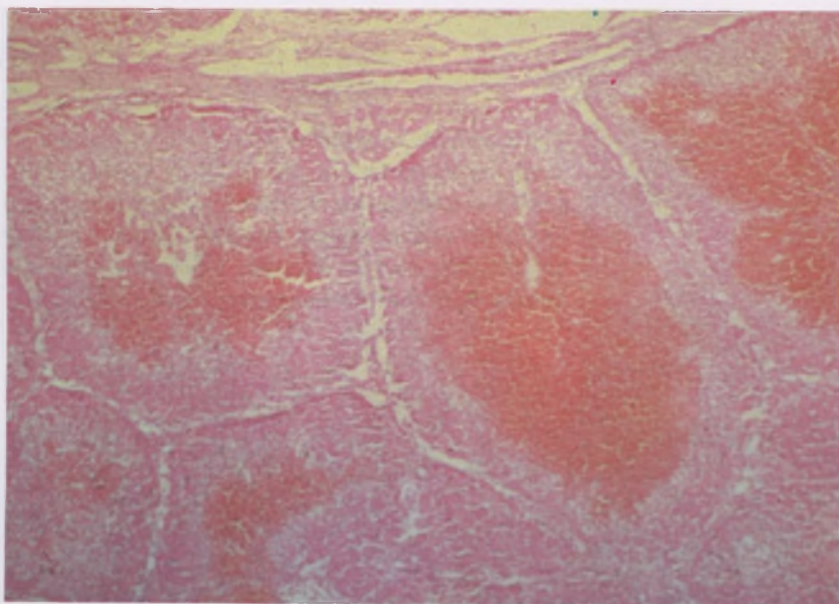


PLATE 159: ACUTE CENTRAL HEMORRHAGIC NECROSIS

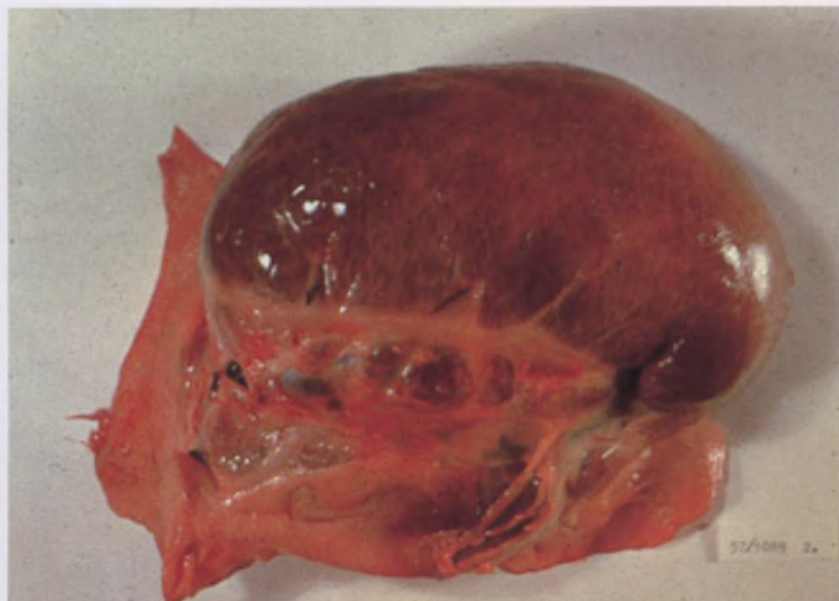
The well outlined liver lobules are characteristic for swine which in this case also show a marked Central Hemorrhagic Necrosis. This is from one of over 50,000 pigs that died after eating a diet containing 2.5% beef tallow. The tallow had inadvertently been put into used asphalt barrels. Apparently toxic substances leached out of the remaining asphalt to cause this problem. Phenol compounds are suspected. Out of this context, acute passive congestion could also be considered.

DR. C. I. Liu, Taiwan, ROC

PLATE 158: MULTIPLE DIAGNOSTIC LIVER LESIONS

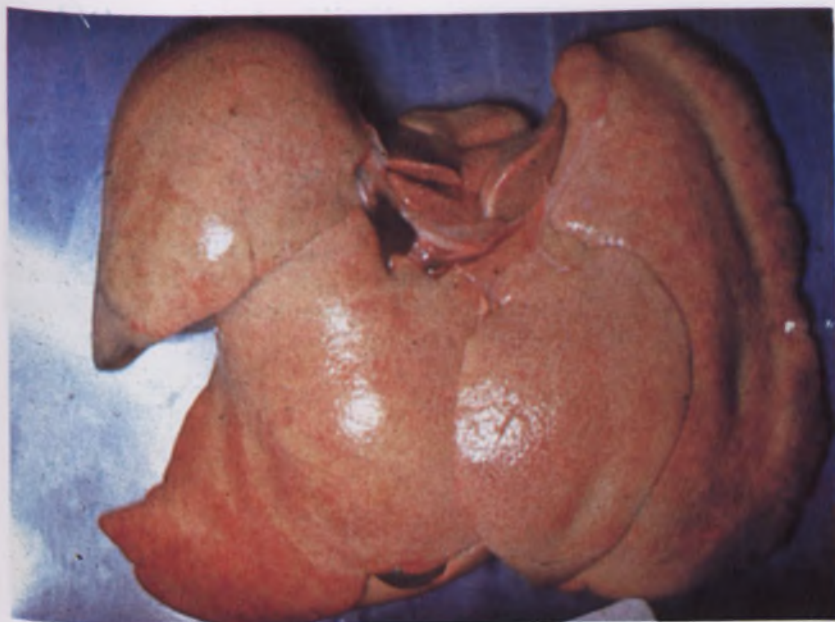The liver at the 12 o'clock location is from a dog with the white form of Leishmaniasis. At 1 o'clock is a dog's liver with Canine Cholangitis.

PLATE 160: TOXIC (SPORODESMIN) HEPATOSIS WITH FIBROSIS AND REGENERATION



A major portion of this sheep's liver is firm, very pale, and atrophic. The large kidney shaped mass attached to the small liver is an area of Nodular Regeneration. Usually one side of the liver is more affected by the toxin than the other. This toxin, called Sporodesmin, is produced by the mold, *Pithomyces chartarum* and it causes marked liver damage with bile duct proliferation and atrophy. The mold grows best with certain pasture grasses. The disease is common in New Zealand but similar diseases have been seen elsewhere although Sporodesmin's presence has not been proven. The liver injury usually results in varying degrees of Secondary Photosensitization, primarily around the head, and is called Facial Eczema.

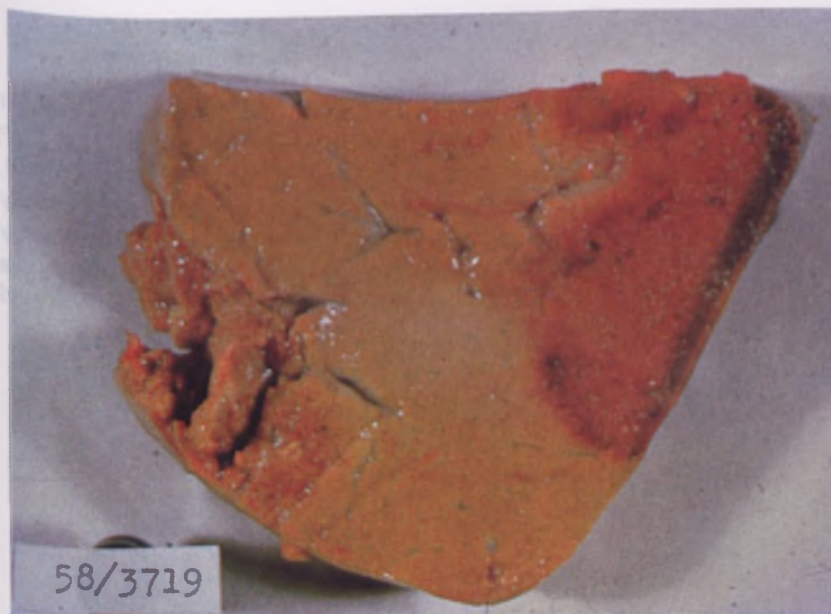DR. C. I. Liu, Taiwan, ROC



Dr. C. I. Liu, Taiwan, ROC

**PLATE 161: TOXIC (AFLATOXIN)
HEPATOSIS**

This fatty liver is from a dog that died of Aflatoxicosis as the result of eating peanut meal contaminated commercial dog food. The peanuts during harvest had been contaminated with *Aspergillus flavus*, a mold which elaborates several toxins under the general heading of Aflatoxins. The histological lesion is initially a peripheral lobular degeneration and necrosis which then progresses centrally. The toxin is alcohol soluble which explains the location of the liver lesion. The initial reports called this problem Hepatitis X.



**PLATE 162: BACTERIAL (CLOSTRIDIUM HEMOLYTICUM)
INFARCTION**

The red area in the normal brown liver of a cow is an area of acute infarction which is quite characteristic for Bovine Bacillary Hemoglobinuria caused by *Clostridium hemolyticum*. Often liver flukes are part of the pathogenesis but other problems can also result in the activation of this organism. In one outbreak of Bovine Virus Diarrhea, the cattle were treated heavily with steroids and in several which died infarction was a common finding. *Pasteurella* spp. infarcts may look somewhat similar.

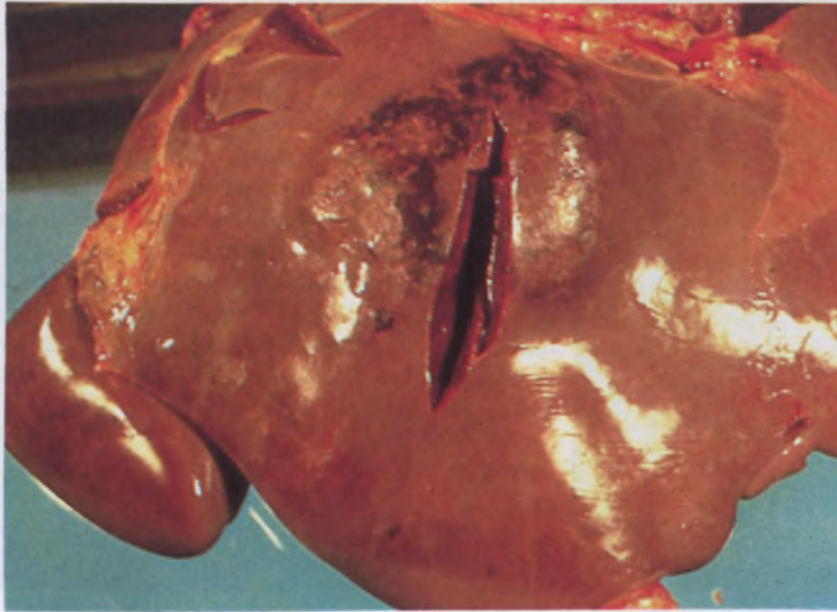


PLATE 163: BACTERIAL (*PASTEURELLA* SPP.) INFARCTION

The large swollen dark mass with fibrin on its surface is a very characteristic lesion of *Pasteurella* spp. Infarction. Most of these have been seen in veal calves being treated with different drugs for diarrhea and pneumonia. Sometimes this is the only lesion seen in the dead animal. Both *Pasteurella multocida* and *P. hemolytica* have been isolated from these lesions.

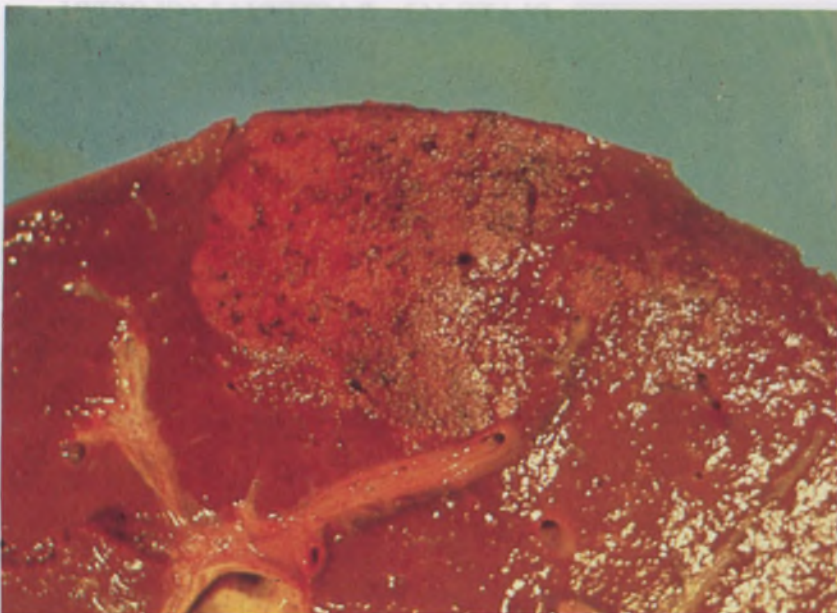
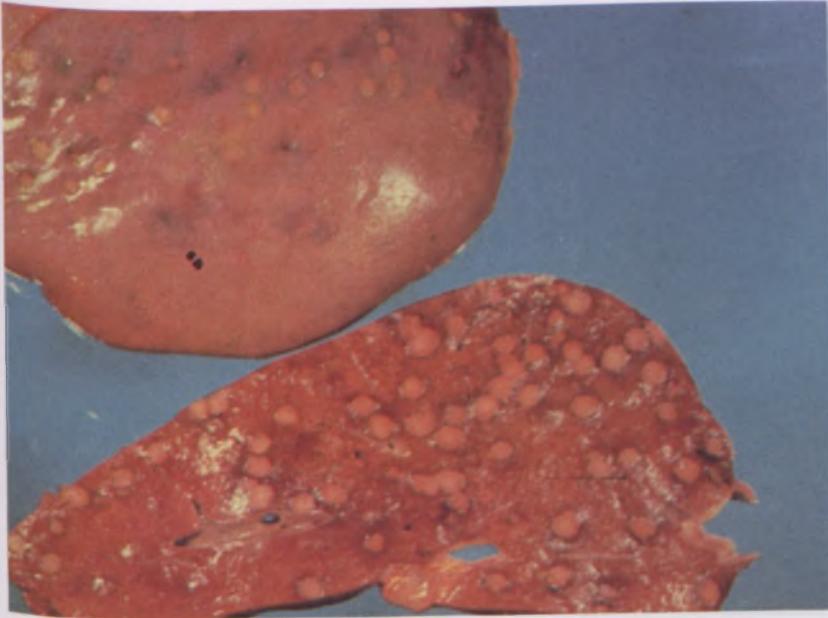
PLATE 164: BACTERIAL (*PASTEURELLA* SPP.) INFARCTION

This dull discrete patch of liver tissue is an Infarct caused by *Pasteurella* spp. in a calf. Either *P. multocida* or *P. hemolytica* is usually isolated. *Clostridium hemolyticum*, the cause of Bacillary Hemoglobinuria, has been the most commonly isolated organism in the past. These *Pasteurella* Infarcts are usually seen in calves heavily treated with drugs, mostly corticosteroids.



**PLATE 165: MULTIFOCAL BACTERIAL
(*FUSOBACTERIUM
NECROPHORUM*)
HEPATITIS (NECRO)**

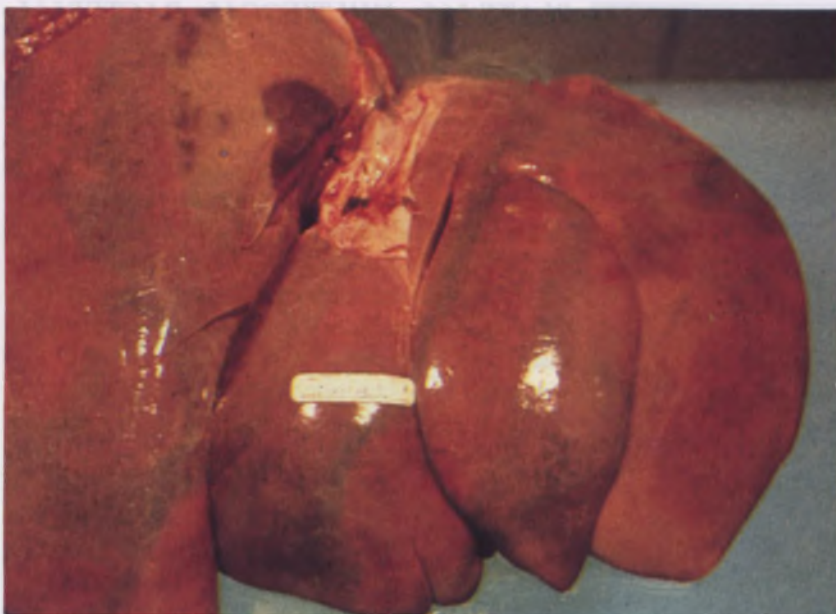
The multiple pale, dull areas with a small rim of congestion around each on both the cut and serosal view of this calf's liver are classical lesions of Necrobacillosis, caused by *Fusobacterium necrophorum* (*Spherophorus necrophorus*). Many consider that these are the result of embolism from rumen or gastrointestinal ulcers; however animals with this liver disease in fact only show a normal incidence of rumen ulcers. This organism is commonly isolated from foot infections.

Dr. C. I. Liu, Taiwan, ROC

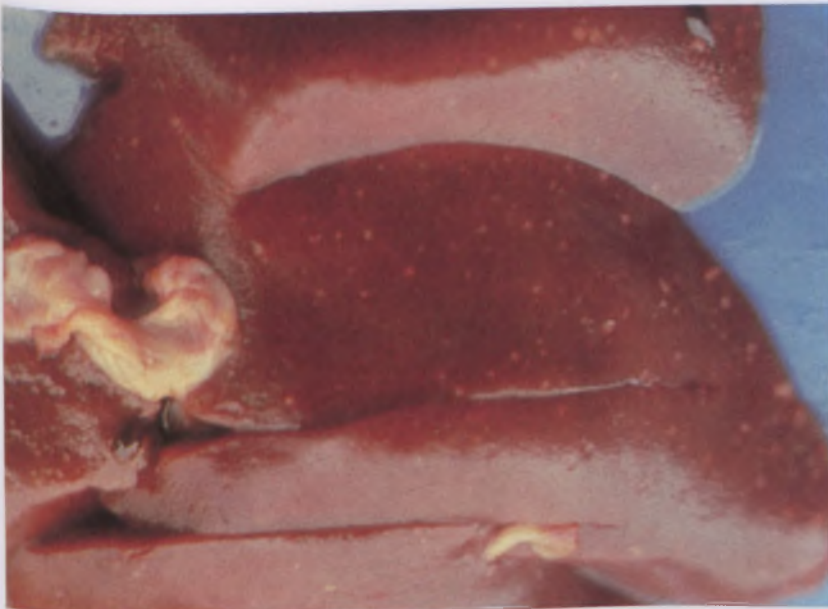

PLATE 166: MULTIFOCAL NECROSIS

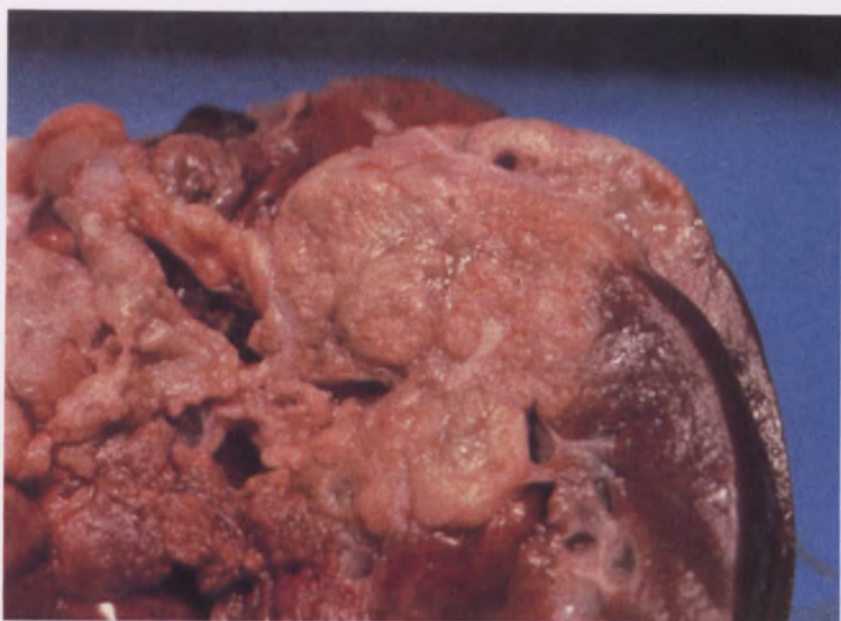The multiple pale foci in this liver may be due to a large number of things such as parasites, Toxoplasmosis, Pseudorabies, Salmonellosis, Tularemia and many others depending on the species of animal affected. All the ancillary diagnostic tests such as serology with acute and convalescent sera, bacterial cultures, fluorescent staining techniques, ELISA testing, animal inoculations and histological examination are often needed to make the diagnosis. This proved to be a case of Salmonellosis in this young pig.



**PLATE 167: MULTIFOCAL BACTERIAL
(*BACILLUS PILIFORMIS*)
HEPATITIS**

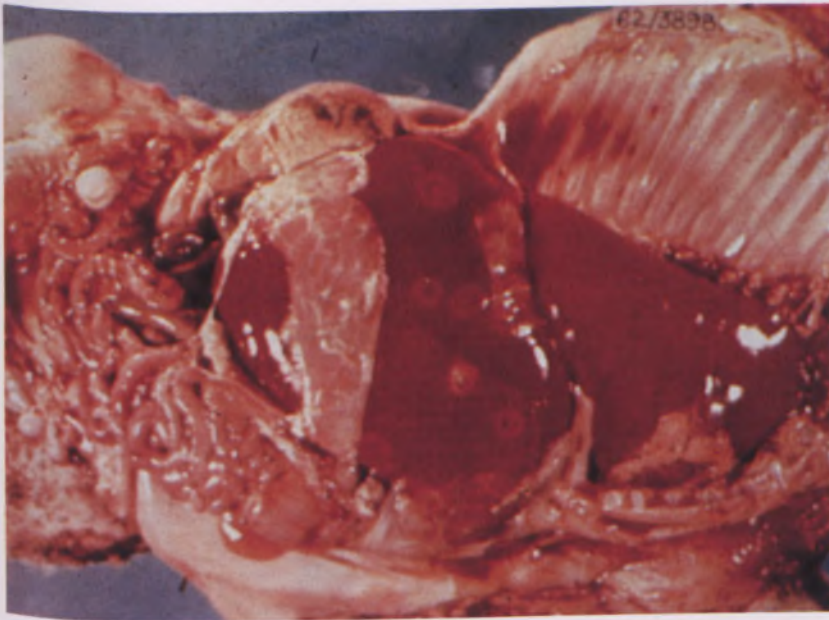
The swollen mottled liver with many minute pale and red 2–3 mm foci scattered on and in the liver is an example of Multifocal Bacterial Hepatitis, caused by *Bacillus piliformis*, in this case of Tyzzer's Disease in a foal. Initially described in laboratory animals it has now been seen in most species. Special stains are necessary to show the organisms that will completely fill the hepatic cord cells.

Dr. C. E. Johnson, R.O.C.



**PLATE 168: FOCAL BACTERIAL
(*NOCARDIA ASTEROIDES*)
HEPATITIS**

The granulomatous reaction in the hilar region of this dog's liver is quite characteristic for Nocardiosis, a bacterial disease caused by *Nocardia asteroides*. This probably is one of the more common primary sites for this infection in dogs although in the past pleuritis was considered more common. Nocardiosis is commonly seen as secondary to a Ruptured Lung Abscess. Usually grey green mucoid material can be expressed from these liver abscesses. It is not always easy to distinguish these from carcinomas *in situ*.



Dr. T. H. Wang, Taiwan, ROC

PLATE 169: VIBRIONIC ABORTION

The several discrete circumscribed, layered and umbilicated lesions in this aborted lamb's liver are quite diagnostic for Vibronic Abortion caused by *Campylobacter fetus*. This bacterial disease can also cause severe thickening and necrosis of the placenta.

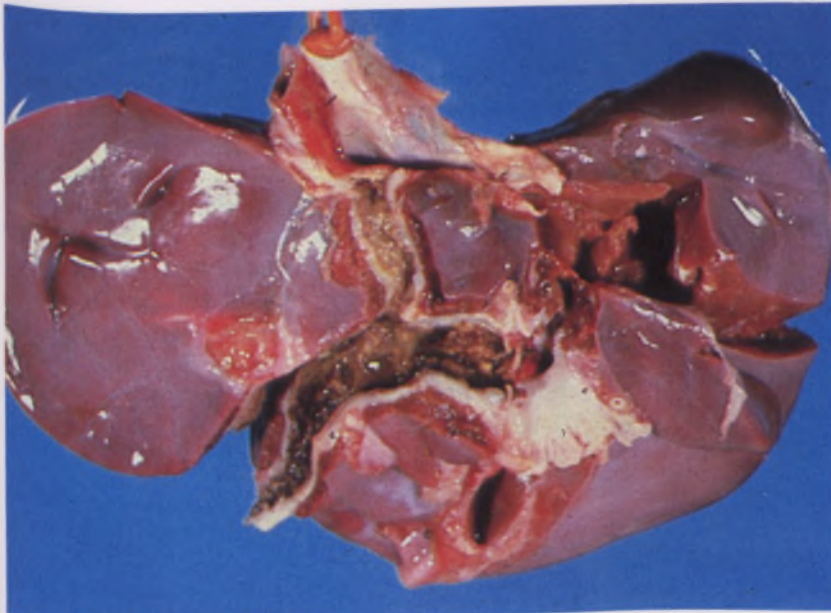


PLATE 170: SUPPURATIVE OMPHALOPHLEBITIS

The visceral surface of a calf's liver is shown. A dark, debris lined Y shaped vessel is prominent in the center. This is an Infected Omphalomesenteric Vein. The bottom portion of the Y leads to the umbilicus where the infection began and one branch, the ductus venosus, goes towards and enters the caudal vena cava. This is also infected, and in fact helped cause an Embolic Pneumonia in the calf. The other branch joins the wide, pale portal vein seen a little above the gall bladder. The portal vein itself is not affected. In embryonic life, the ductus venosus diverts some placental blood away from the liver directly into the general circulation via the caudal vena cava.

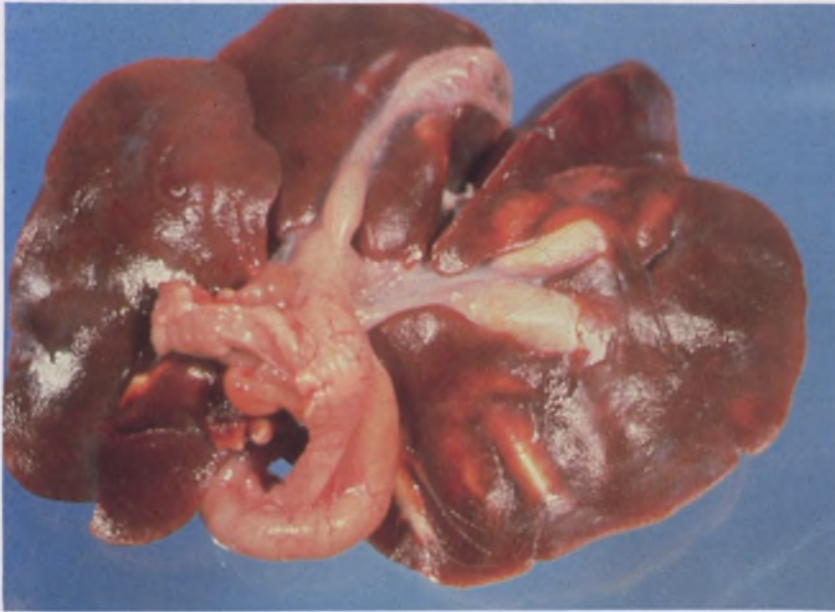


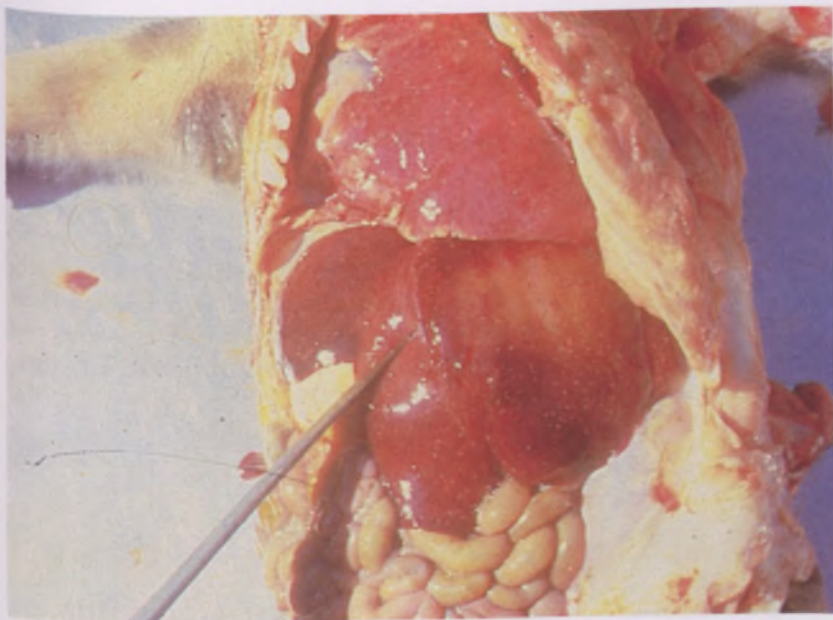
PLATE 171: CHRONIC SUPPURATIVE CHOLANGITIS

Many of the bile ducts in this pig's liver are dilated with pus and bulge from the surface. This is the result of a Chronic Suppurative Cholangitis, Many common pathogens can cause this lesion. Often a predisposing factor is aberrant round worm migration up the bile ducts. One wonders why no icterus was present in the pig as the ducts were effectively blocked by the chronic infection.

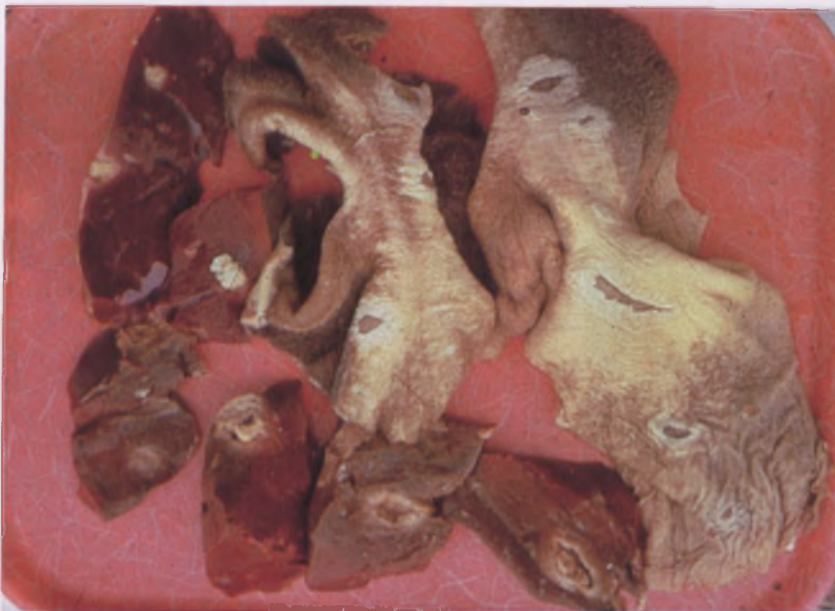

PLATE 172: RUMEN ULCERATION AND LIVER ABSCESES

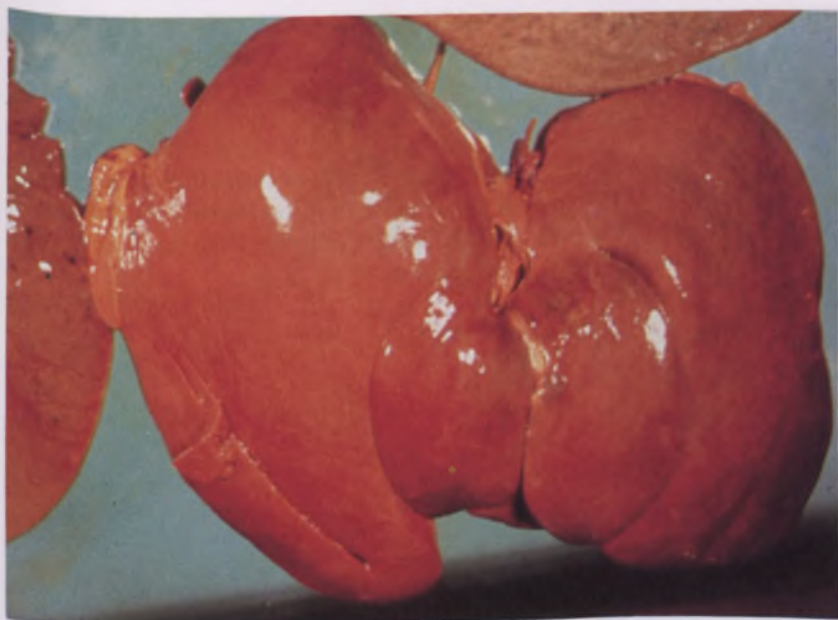
Numerous pieces of liver with an abscess in each are shown alongside several pieces of rumen with Healing Ulcers in the mucosa. This is to show that many Liver Abscesses are associated with Ulcers of the forestomachs and probably the intestine of cattle. This might have been a case of Toxic Rumenitis initially or even Necrobacillosis caused by *Fusobacterium necrophorum* of the rumen. Even after careful washing of the forestomachs prior to examination, less than 50% of the cases we have seen with liver abscesses had ulcers in the gastrointestinal tract.



Dr. T. H. Wang, Taiwan, ROC

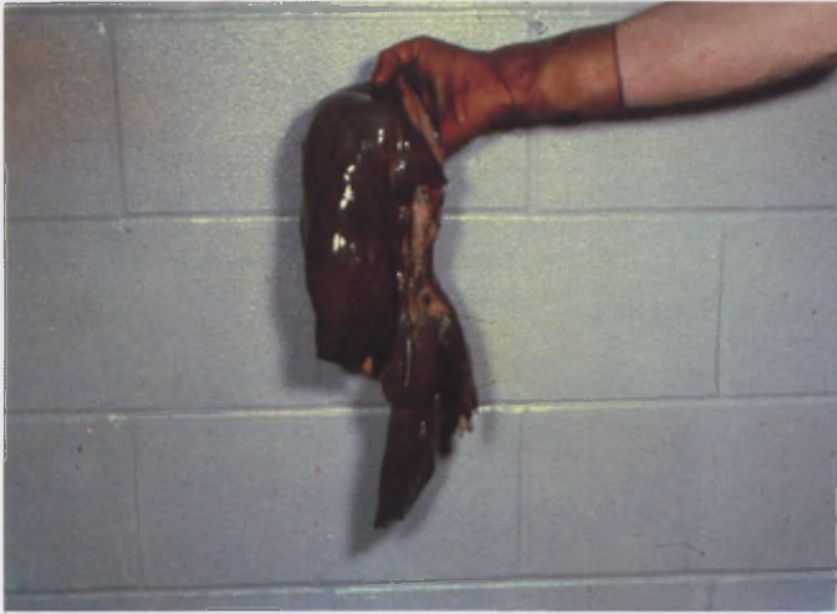**PLATE 173: MULTIFOCAL VIRAL
(PSEUDORABIES)
HEPATITIS**

The multiple foci in this liver are focal areas of necrosis caused by Pseudorabies virus in this piglet. In older pigs this disease of Pseudorabies or Aujeszky's Disease is usually seen as a nonsuppurative encephalitis. Intranuclear inclusions may be found in these necrotic areas.



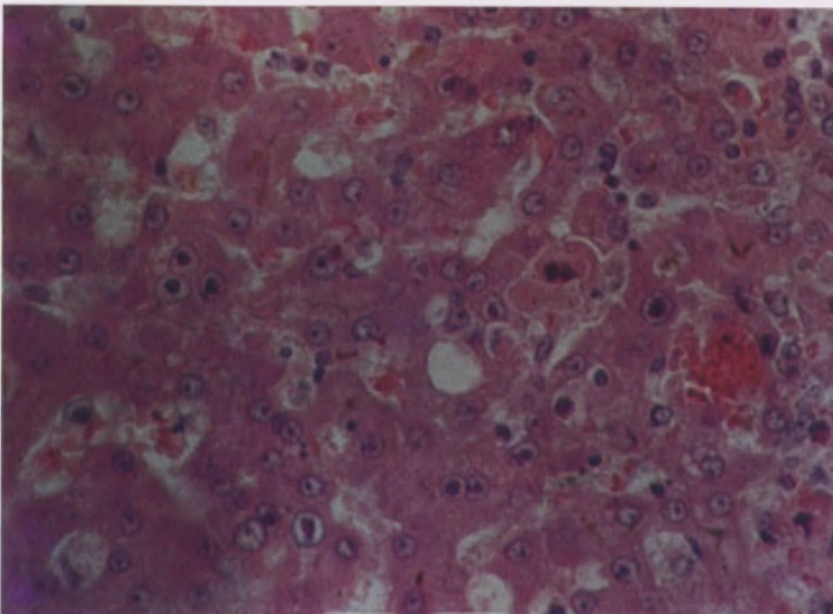
**PLATE 174: MULTIFOCAL NECROTIC
VIRAL (EQUINE VIRUS
ABORTION) HEPATITIS**

The few multifocal, pale areas of necrosis in this aborted foals liver is the result of Equine Virus Abortion. In most cases of this abortion the firm, meaty enlarged lung is the major diagnostic feature, but this Multifocal Necrosis of the adrenals, liver, kidneys and lung is common enough to make it a good diagnostic aid.



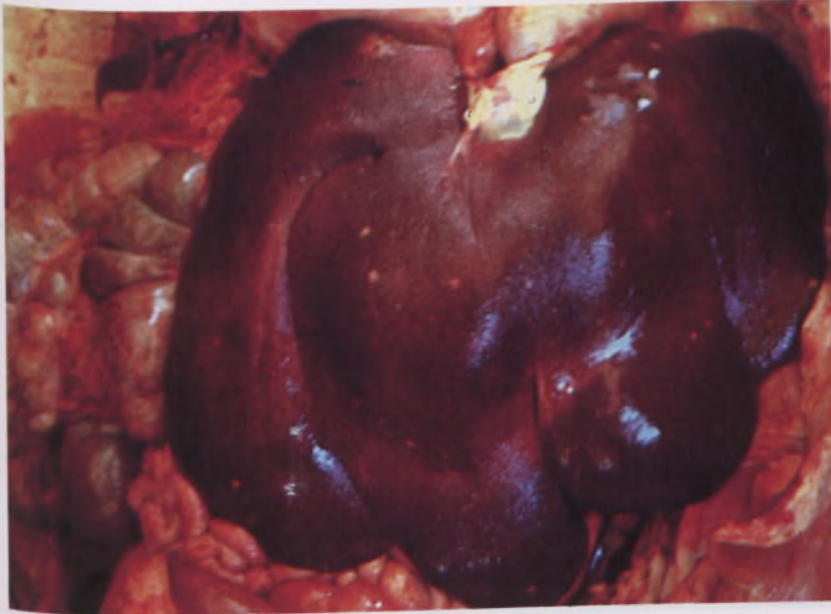
**PLATE 175: MASSIVE LIVER
NECROSIS (THEILER'S
DISEASE)**

The classical Dishrag appearance of a horse's liver affected with Theiler's Disease is shown here. It is greatly reduced in size, and extremely flaccid. The horse died 60–90 days after being injected with a horse derived product. This is the usual case, however similar cases have been seen in which there is no history of administration of horse derived products. Clinically the horses are icteric with signs of mania at death.



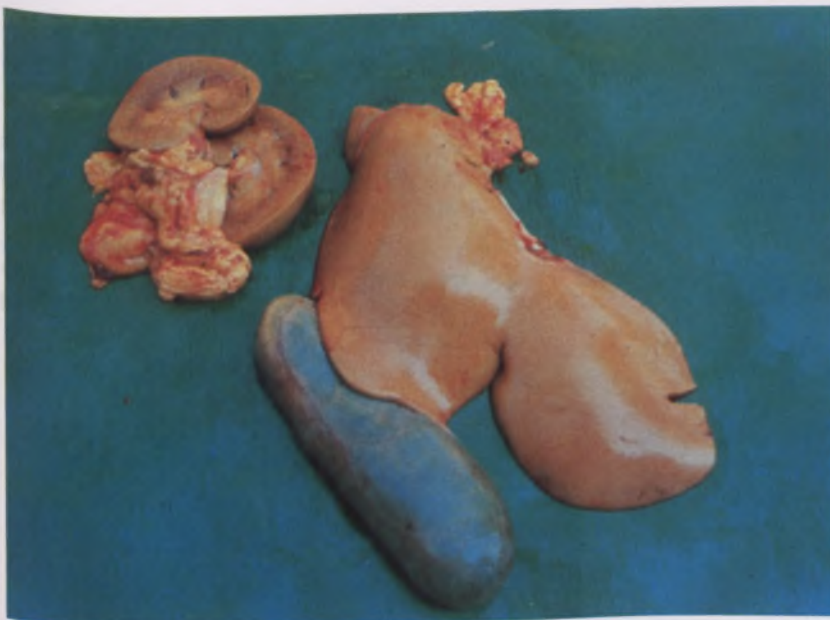**PLATE 176: INTRANUCLEAR VIRAL
(INFECTIOUS CANINE
HEPATITIS) INCLUSION
BODIES**

The many dark purple bodies with a clear halo in the nuclei of most of these hepatic cord cells are the typical, Viral Inclusion Bodies of Infectious Canine Hepatitis.



**PLATE 177: MULTIFOCAL PROTOZOAL
(*TOXOPLASMA GONDII*)
HEPATITIS**

These multifocal, pale areas of necrosis are caused by *Toxoplasma gondii* in this young pig. Actually many different agents can cause a similar lesion grossly and culture, virus isolation, and other tests must be done to prove the definitive cause. Microscopically parasites, organisms and inclusions would be looked for to be definitive.



**PLATE 178: BLUE GREEN ALGAE
(*MICROCYSTIS*)
POISONING**

In this case the liver is extremely small and pale, as a result of marked necrosis caused by the toxin of *Microcystis*, a member of the green algae phylum. In such cases a large quantity of free blood is often observed in the colon.

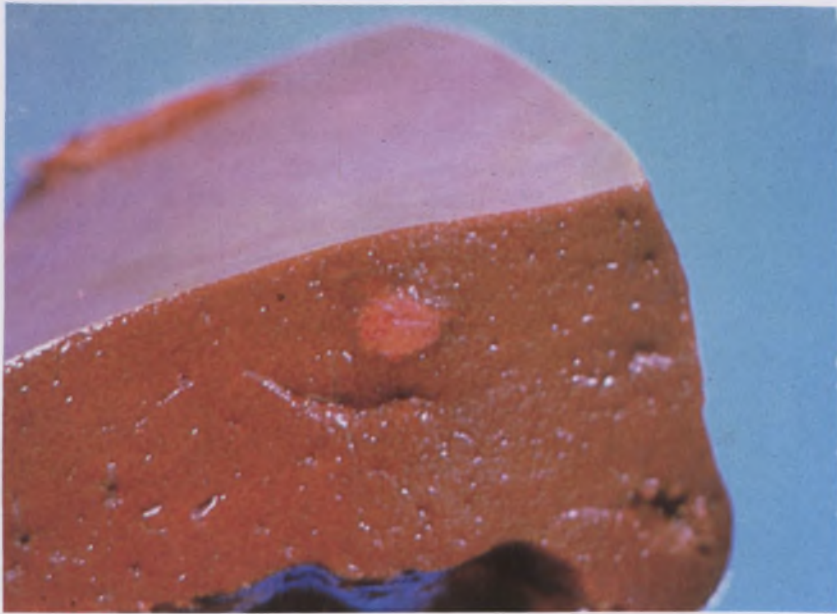

PLATE 179: FOCAL MYCOTIC HEPATITIS

The distinct pale focus in this cow's liver is an area of Mycotic Hepatitis, one of many scattered in the liver from emboli arising in vessels of the rumen. In such cases of Secondary Mycotic Rumenitis in a cows, *Mucor* spp. and *Aspergillus* spp. are common isolates. Most bacterial or fungal abscesses in the liver are considered to be embolic through the portal veins from the gastrointestinal tract.

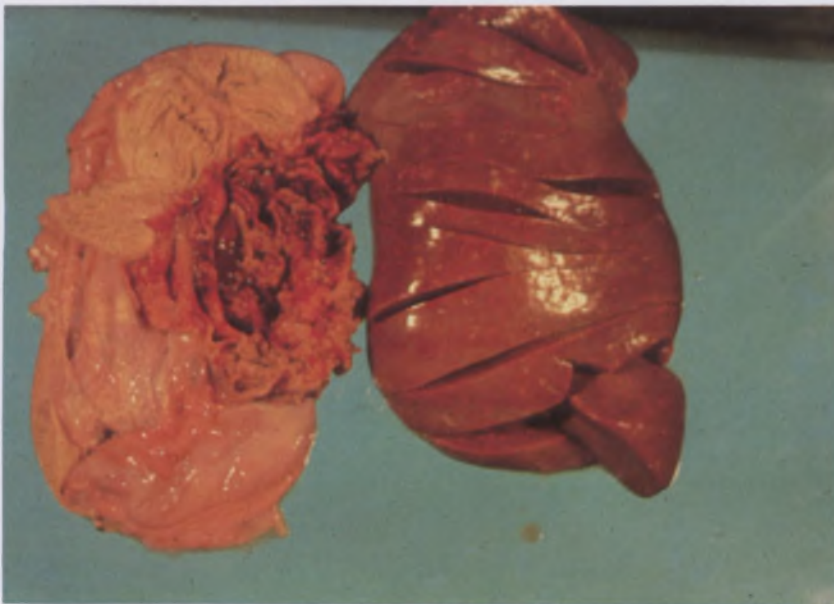


PLATE 180: MYCOTIC ABOMASITIS AND EMBOLIC MYCOTIC HEPATITIS

The multiple pale foci in this liver and the large area of necrosis, and debris in the abomasum of this calf demonstrate well the Embolic spread of a Mycotic Abomasitis to form Mycotic Abscesses in the liver. *Mucor* spp. and *Aspergillus* spp. are commonly isolated. Most mycotic gut infections are associated with antibiotic therapy.

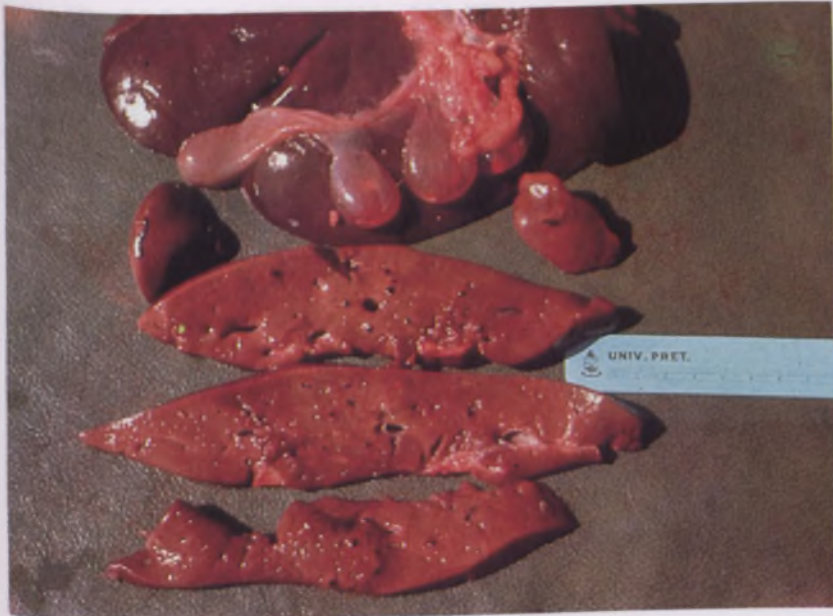


PLATE 181: PARASITIC (*CYSTICERCUS OVIS*) HEPATITIS

Several large cysts are present on the intact liver, many areas of focal hemorrhage are seen in the cut sections of liver and the two small masses of liver show linear pale outlined hemorrhagic streaks. These are the cysts or the migration tracts of Cysticerci in a sheep. These Cysticerci are the intermediate stages of *Taenia ovis*, a tapeworm of dogs and other carnivores.

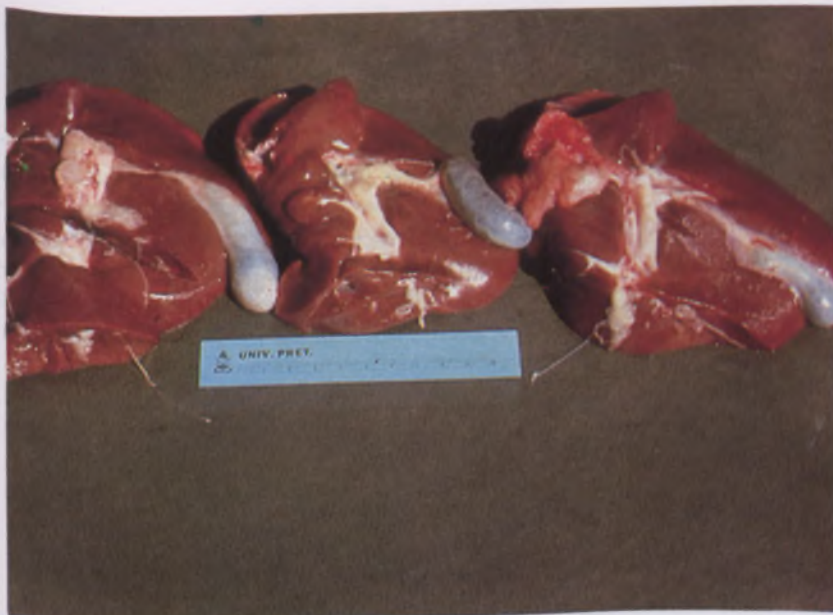


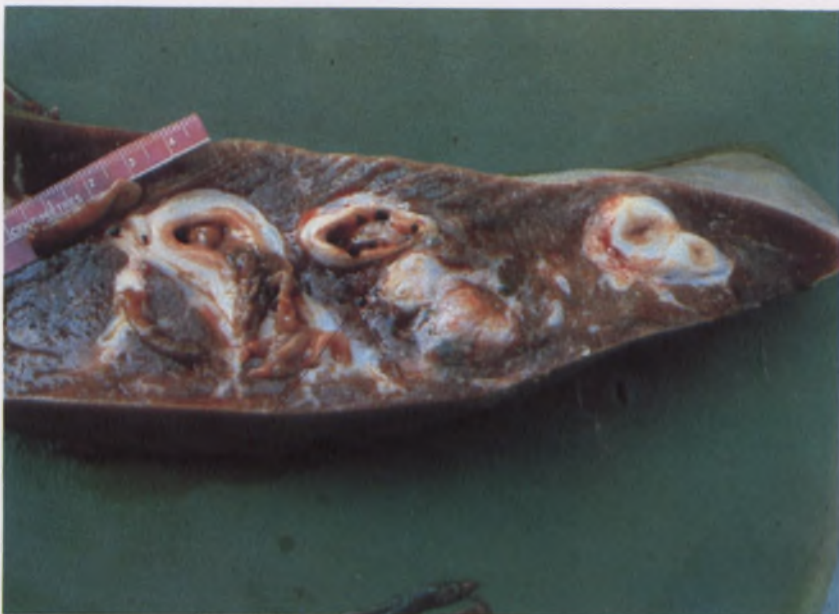
PLATE 182: BILE DUCT TAPEWORMS (*STILESIA SPP.*)

In these three sheep livers the clumps and strings of white material expressed from the bile ducts are tapeworms, *Stilesia* spp.. These are very common bile duct parasites in certain areas and although most do not cause significant lesions, their presence is not desired by the housewife. Much larger tapeworms, *Thysanosoma actinoides* are also common parasites of ruminant bile ducts.



**PLATE 183: MULTIPLE BLOOD FLUKE
(*SCHISTOSOMA SPP.*) EGG
GRANULOMAS**

The multiple, white foci in this sheep's liver are due to the embolization of the spined eggs of the blood fluke, *Schistosoma* spp., which causes these tiny granulomas. The joined flukes parasitize the portal vessels.



**PLATE 184: CHRONIC PARASITIC
(*FASCIOLA HEPATICA*)
CHOLANGITIS**

This cut surface of a cow's liver shows the markedly thickened bile ducts and many of the tan 2–3 cm flukes that causes this marked Bile Duct Hypertrophy. The flukes are the common liver fluke, *Fasciola hepatica*. The smaller lancet fluke, *Dicrocoelium dendriticum* also lives in bile ducts but usually only causes some distension and not such a severe Parasitic Cholangitis.

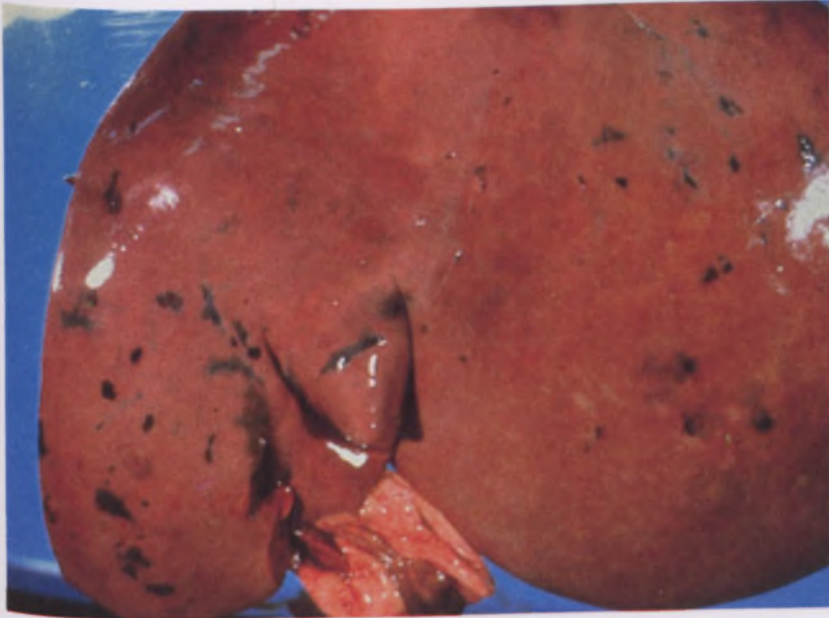


PLATE 185: FLUKE MIGRATION PIGMENT

The multiple black areas scattered in some parts of the liver more than others are the result of fluke migration. Most flukes leave this Fluke Pigment as they migrate through various organs and tissues. The exact nature of the pigment is not known. *Fascioloides magna* were identified in this liver.

Dr. W. H. Kraft, Oklahoma, USA

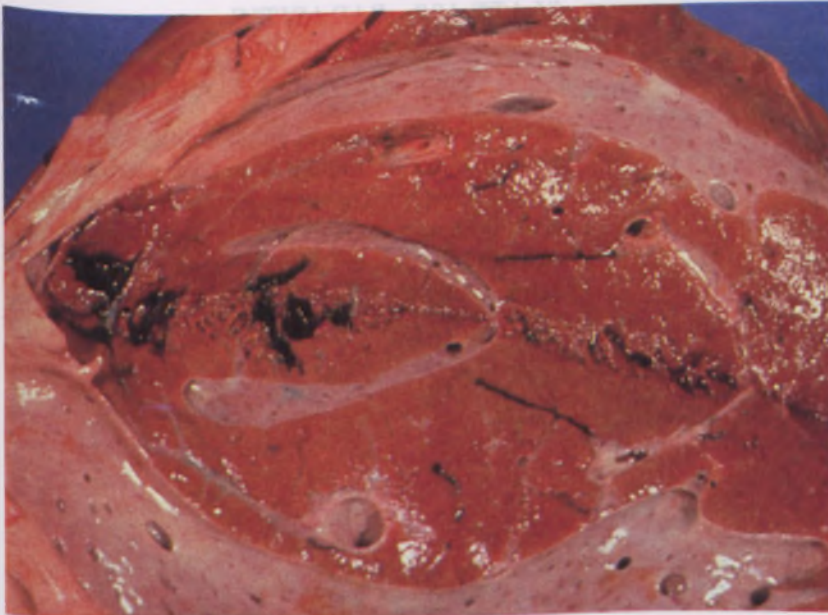
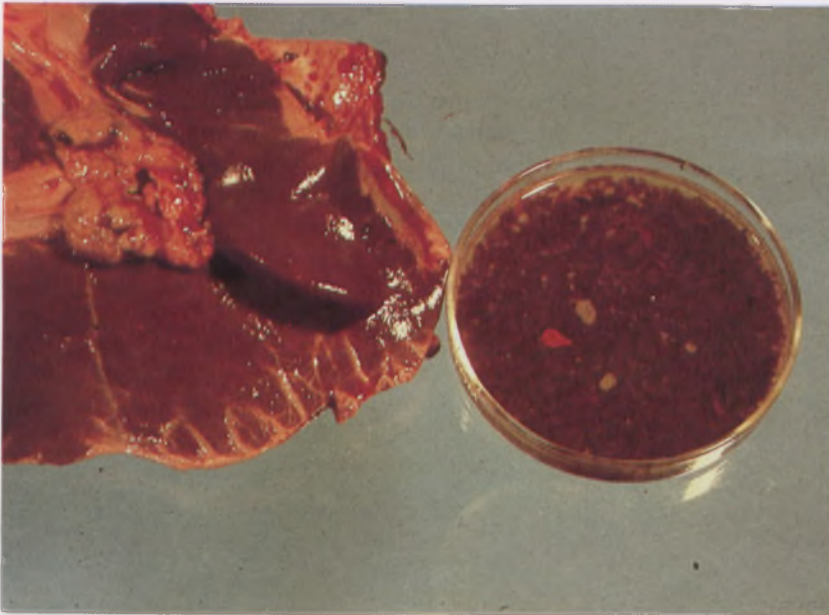


PLATE 186: FLUKE PIGMENTATION

The several black irregular areas and black lines in this cow's liver are evidence of fluke migration. In this case the black pigment was caused by *Fascioloides magna*, the large liver fluke. Most tissue migrating flukes like *Fasciola* spp. and *Paragonimus* spp. can produce a similar reaction.

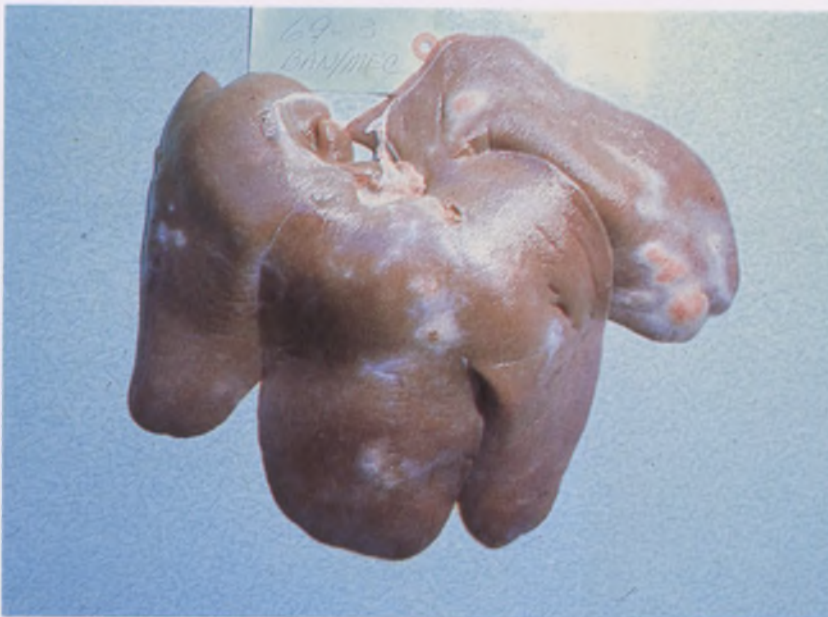Dr. L. Klätner, Missouri, USA



**PLATE 187: DISTOMIASIS
(DICROCOELIUM
DENDRITICUM)**

The multiple pale streaks near the edge of this cow's liver are dilated bile ducts caused by the many Lancel Liver Flukes, *Dicrocoelium dendriticum*, that are in the petri dish. These are common in some areas in cattle, sheep and goats and many other animals.

Dr. W. H. Krull, Oklahoma, USA



**PLATE 188: PARASITIC
(STEPHANURUS
DENTATUS) HEPATITIS**

The relatively large areas of hemorrhage and fibrosis are the result of Kidney Worm, *Stephanurus dentatus* migration. These lesions are easily confused with Roundworm, *Ascaris lumbricoides*, whose migration lesions are usually more numerous but much smaller than those of the Kidney Worm.

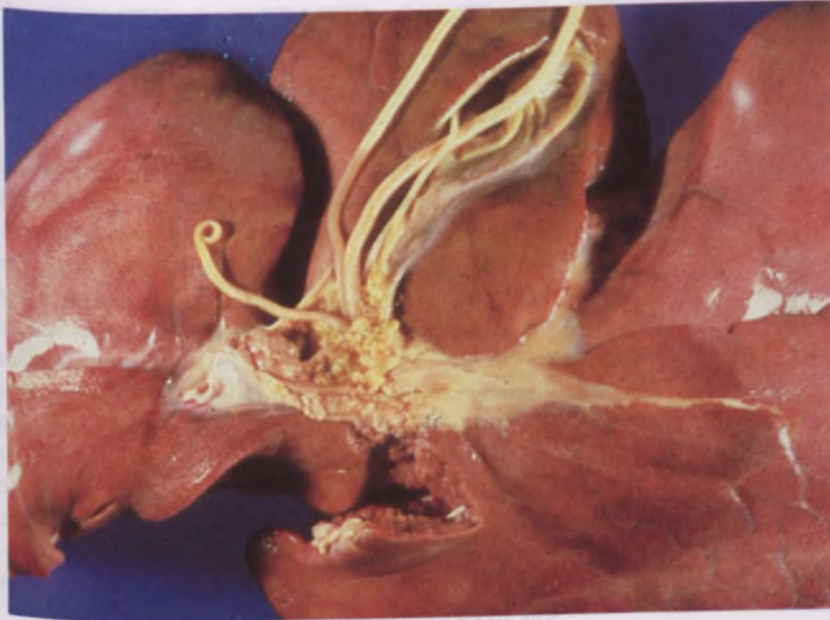

PLATE 189: POSTMORTEM MIGRATION OF ASCARIDS

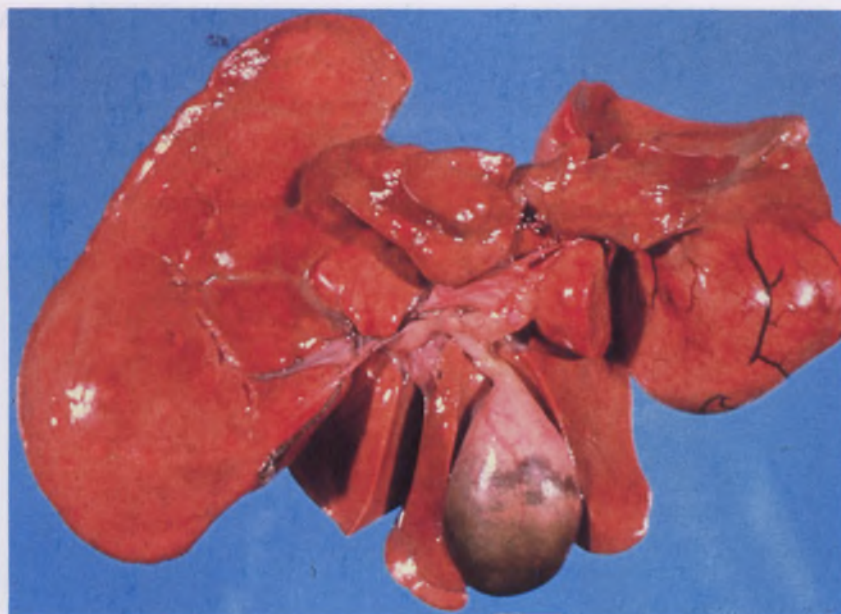
The lack of reaction in the bile ducts or gall bladder in this pig suggests what this often represents, a Postmortem Migration of Ascarids. These can and do migrate up the bile ducts during life and can result in cholangitis.

PLATE 190: PARASITIC (HEPATIC ADENOMA) (HEPATOMA)

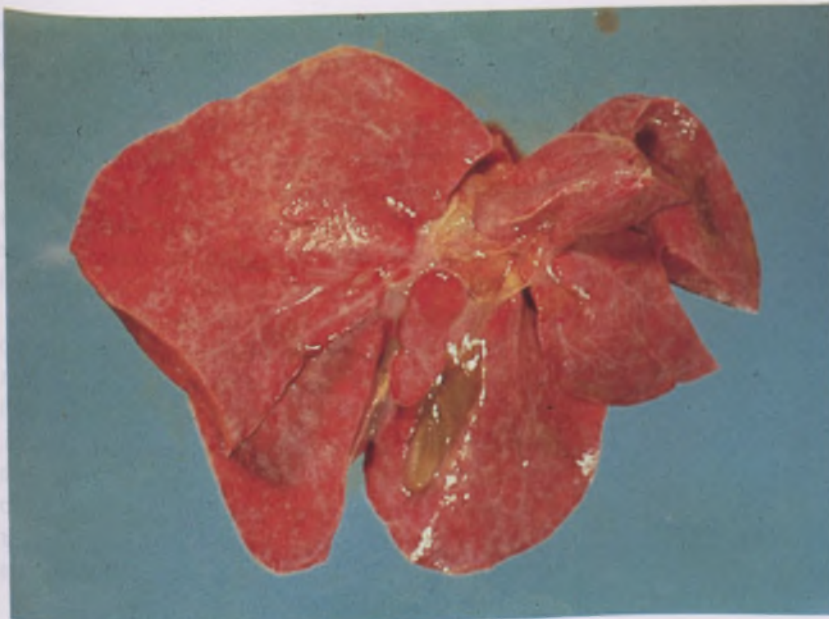

PLATE 190: PARASITIC (ASCARIS LUMBRICOIDES) MIGRATION FIBROSIS

Usually only a few pale white foci are seen in the liver as a result of the common Roundworm Migrations through a pig's liver. This photograph shows the result of a massive Parasite Migration Fibrosis. In some geographical locations the Kidney Worm, *Stephanurus dentatus*, can cause somewhat similar lesions.

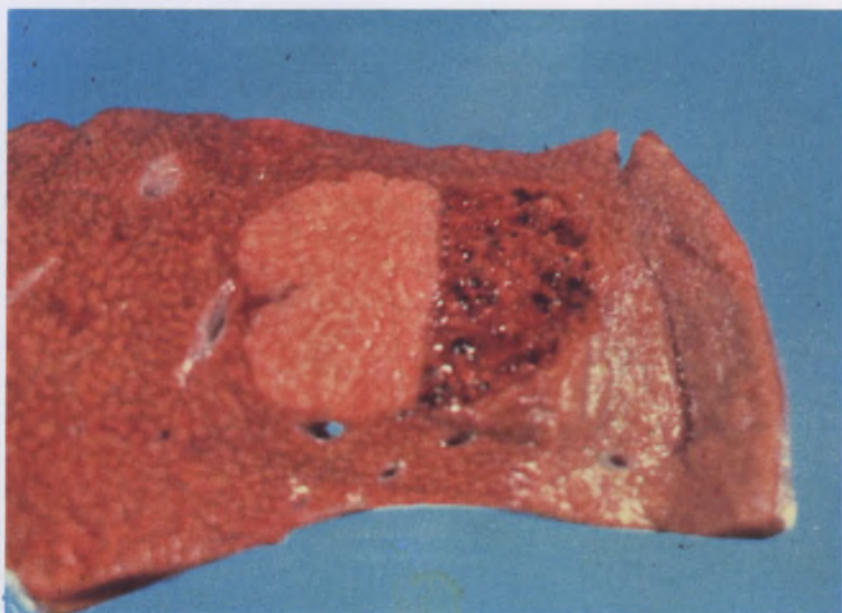


Dr. W. H. Krull, Oklahoma, USA

PLATE 191: HEPATOMAS (HEPATIC ADENOMAS) AND CYSTIC HYPERPLASIA OF THE GALL BLADDER

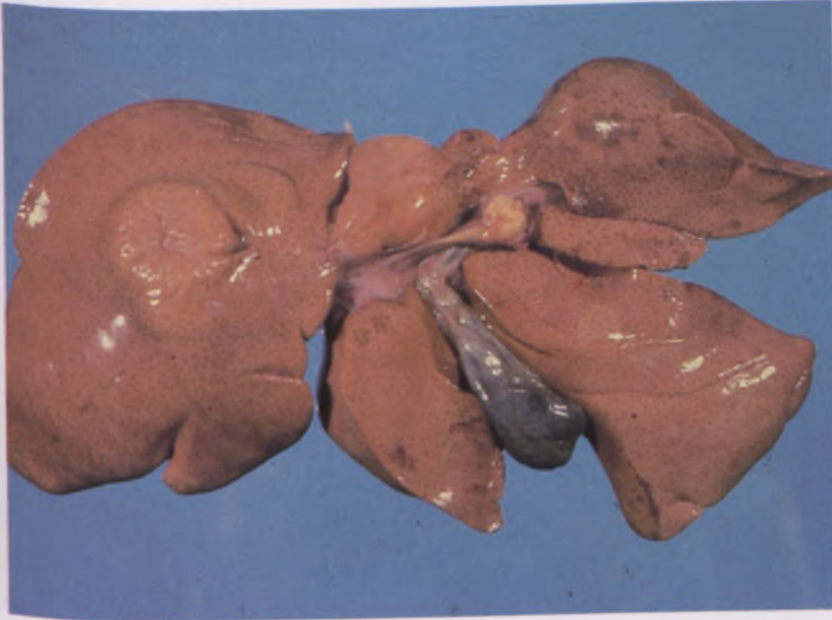
The several pale nodules with prominent vessels on their surface near the hilus, and the large ventrally bulging similar mass, again with prominent vessels, on the caudate lobe of this dog's liver, are Hepatomas (Hepatic Adenomas). They should not be called Nodular Hyperplasia, but often are so called. These are true benign neoplasms which occur almost entirely in tumor aged animals, mostly dogs and cats. There is no evidence in the remaining liver for compensatory need such as scarring or liver damage. These may get as large as the rest of the normal liver combined and they then can cause death by rupture of the capsule with exsanguination. The pale neck region of the gall bladder is due to Cystic Hyperplasia of the mucosa.

PLATE 192: HEPATIC ADENOMA (HEPATOMA)



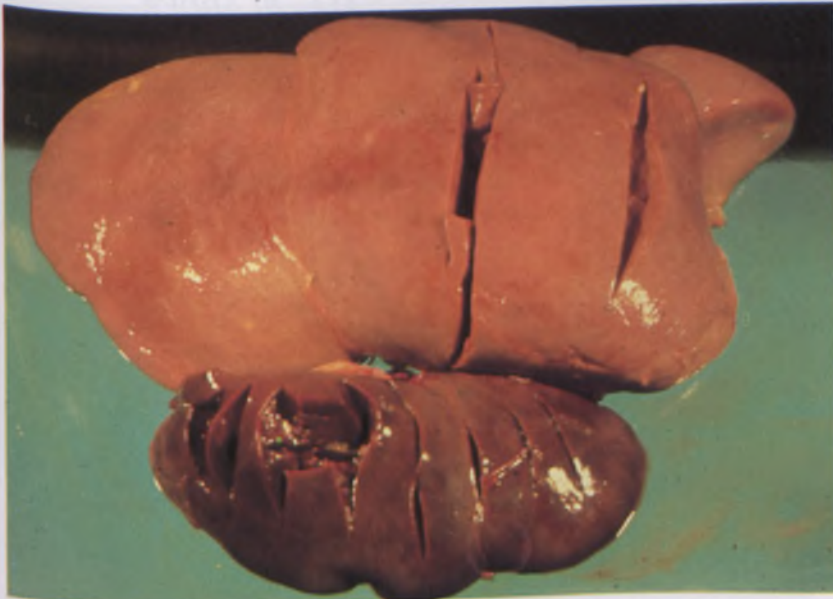The single mass in this dog's liver divided into two discrete portions by color and structure is a Hepatoma or Hepatic Adenoma. One part is very much more vascularized than the other. Hepatomas can be of two major types. One consists of a mass of almost normal appearing cord cells that seem to have originated from a *single cell or clone of cells* that just grew and expanded to compress the surrounding parenchyma. It does not have normal stroma, including bile ducts, or organized structure. The other common type of Hepatoma is made up histologically of a *group of hepatic lobules* that appear to proliferate without control, but they will have their normal stromal and accessory structures. These two types are true benign tumors as they are only seen in tumor aged animals and there is no evidence for compensatory need to cause their development. The lighter colored nodule shows this latter type character very well.

Dr. L. Kintner, Missouri, USA



**PLATE 193: HEPATIC ADENOMAS
(HEPATOMAS)**

The several dark areas scattered in this cat's liver parenchyma are foci of Telangiectases (foci of dilated sinusoids). The several large, slightly pale nodules, one with a slight depression in its center, are nodules of proliferating hepatic cord cells called Hepatomas. They are benign tumors of the hepatic cord cells. There has been much controversy about these being Hyperplastic Nodules. These, to our mind, are not compensatory for any known reason and they occur in tumor aged animals, mostly dogs and cats. Nodular Hyperplasia is a term which should be discarded or at best used only when known compensatory need is proven as in cases of Post Necrotic Scarring, in which Regenerative Nodules really do occur because of need. The pictured Hepatomas are almost always benign but they may attain extremely large size.



**PLATE 194: NORMAL LIVER AND
DIFFUSE LYMPHOSAR-
COMA OF THE LIVER**

The dark liver is a relatively normal liver from a newborn calf. The massively enlarged pale liver is from a newborn calf of approximately the same size with Diffuse Lymphosarcoma of the liver.

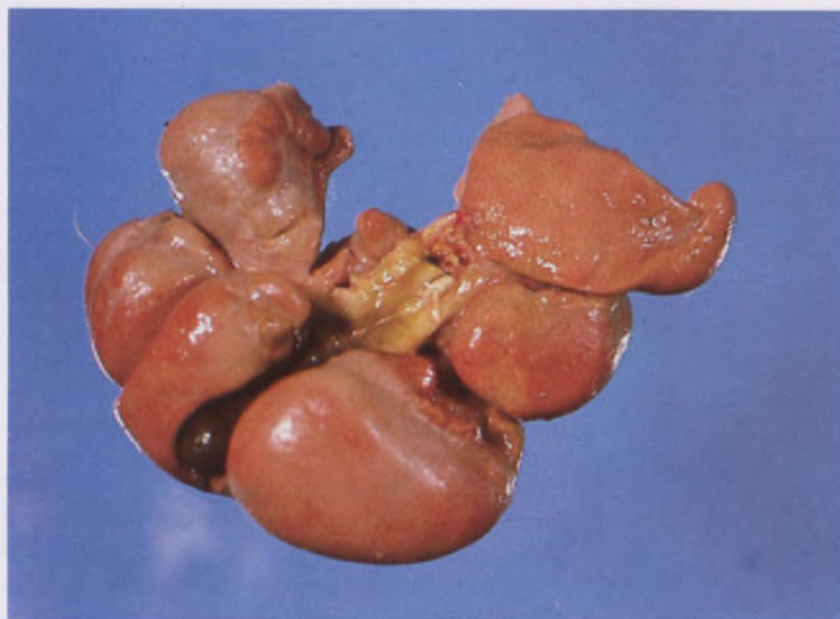

PLATE 195: NEOPLASTIC RELATED CAPSULAR FIBROSIS

The overall rounded appearance of this cat's liver lobes are quite diagnostic for this problem of Neoplastic Related Capsular Fibrosis. Adenocarcinomas of the bowel and pancreas are common types of tumor that cause this lesion but the pathogenetic mechanism is unknown. In many cases these tumors mentioned above are sclerosing and this probably plays a part in the disease, but why they should have so much effect, without more obvious fibrosis is not understood. The liver itself is normal histologically and it is roughly normal in overall size.

PLATE 196: GALL BLADDER ANOMALIES

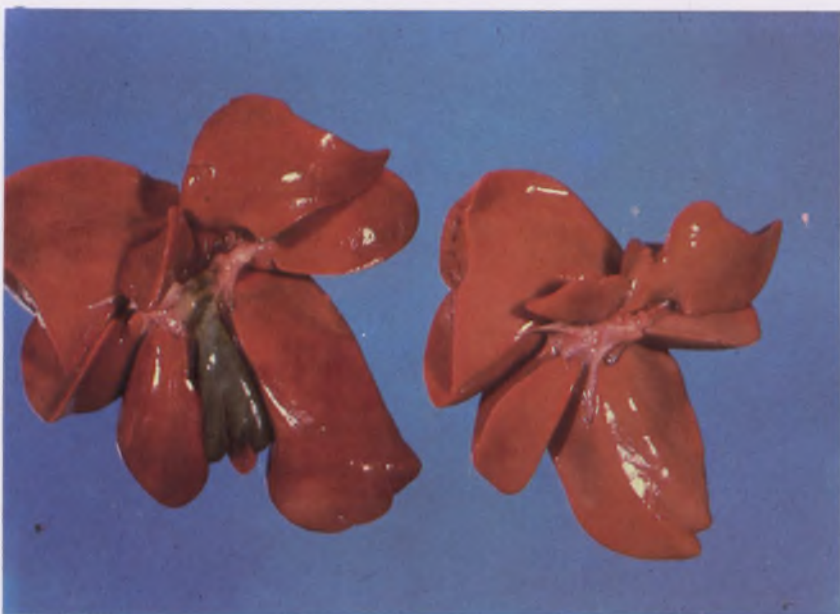
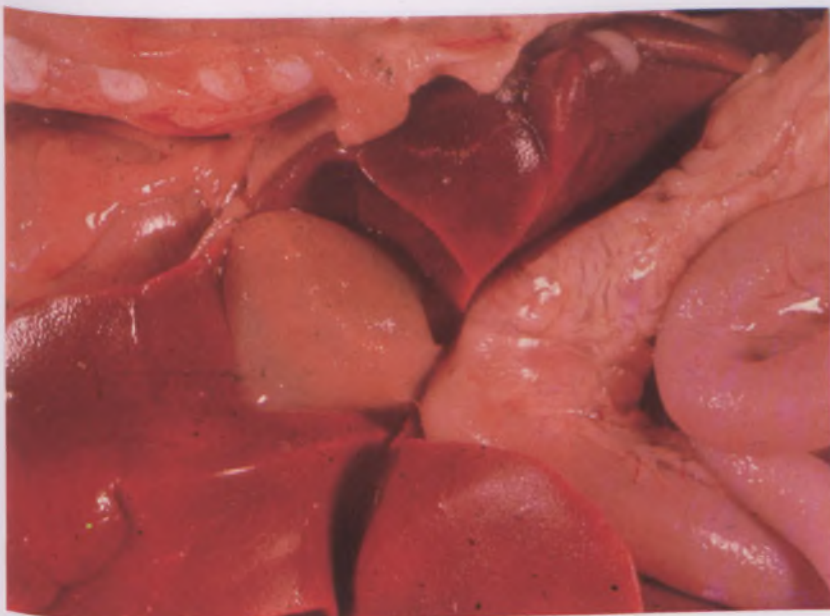


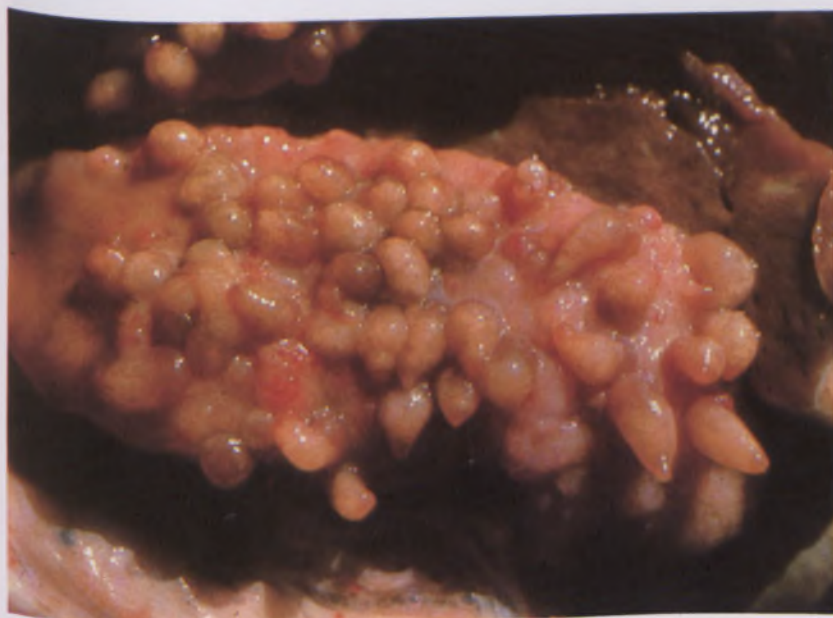PLATE 196: GALL BLADDER ANOMALIES

The two livers shown are from essentially normal cats. In one cat there is no gall bladder and in the other the gall bladder is bilobed. Of all animals, the cat is the one most likely to have Gall Bladder Anomalies such as these.



**PLATE 197: EDEMA OF THE GALL
BLADDER**

The marked swelling of this gall bladder in a dog is Edema, and it is quite diagnostic for Infectious Canine Hepatitis, when the history and related lesions are present. It can be seen under so many other conditions that by itself it should not be considered pathognomonic. It is also commonly seen in other species as well as dogs and associated with such diseases as heart anomalies, hypoproteinemia, Edema Disease of Pigs, and Toxoplasmosis.



**PLATE 198: BILE DUCT AND
PANCREATIC DUCT FLUKE
(EURYTREMA PANCREATI-
CUM)**

The multiple small conical masses attached to the bile duct of this cow are *Eurytrema pancreaticum*. They are usually reported found in the pancreatic duct.

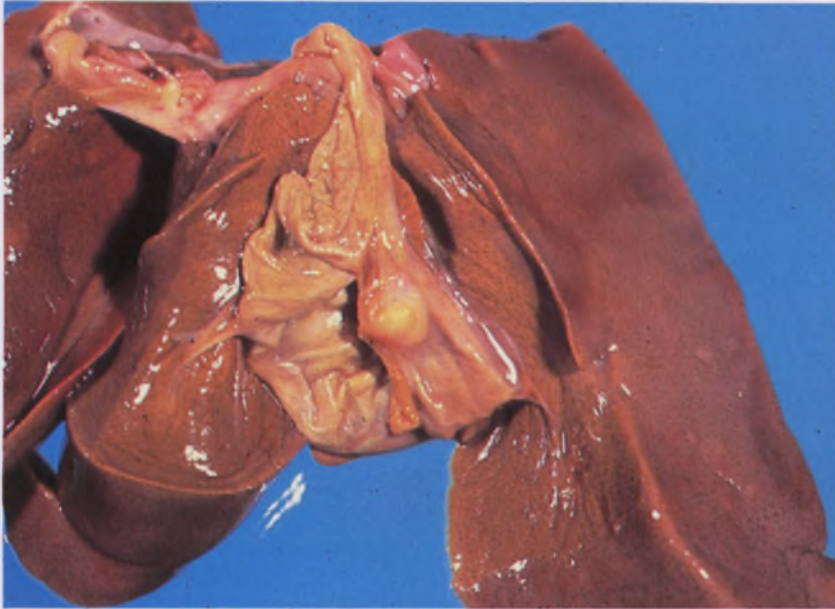


PLATE 199: DUCTAL ADENOMA OF THE GALL BLADDER WALL

Tumors can be found almost anywhere and the gall bladder wall is no exception as this Benign Ductal Adenoma demonstrates in this dog.

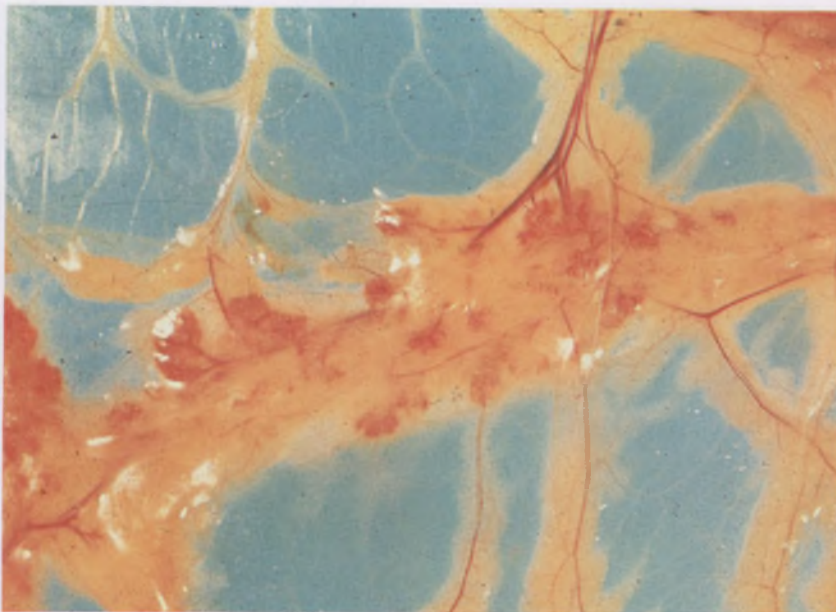


PLATE 200: PANCREATIC HYPOPLASIA

Only tiny nests of pink tissue can be seen in the pancreatic fat area of this dog. These are all that make up the pancreas in this case of Pancreatic Hypoplasia. This is not Atrophy as there is neither evidence in the form of increased connective tissue nor shrinkage in the area. This is probably a genetic problem. The animals usually become diabetic early in life but they do not always show evidence of pancreatic exocrine deficiency.

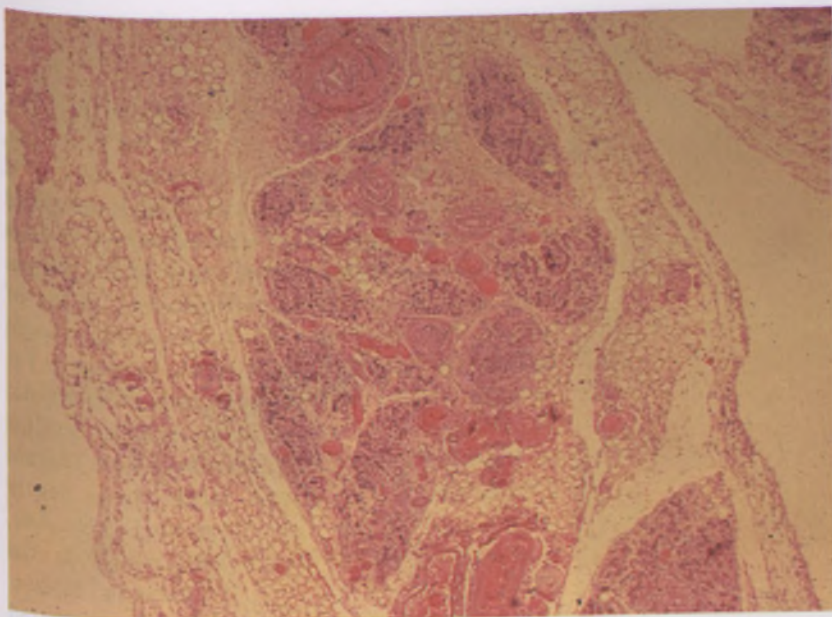


PLATE 201: PANCREATIC HYPOPLASIA

This is the cross section of an area of fat and pancreatic tissue in a case of Pancreatic Hypoplasia. Several larger ducts are seen scattered among some very primitive acinar and small ductular epithelium. A genetic disposition to this disease is probably at fault.

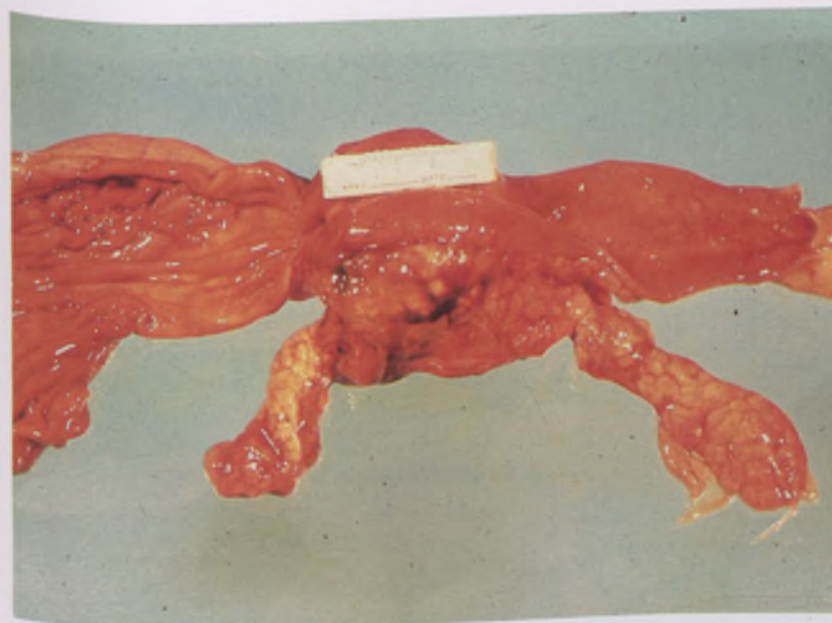


PLATE 202: ACUTE PANCREATIC NECROSIS AND LOBULAR FIBROSIS

The pancreas still attached to the duodenum is swollen, bloody and has fibrin attached to its surface. This is an example of Acute Pancreatic Necrosis. The left branch of the pancreas, (head), near the stomach is slightly smaller in width than the right branch, (tail), and is very firm. Its individual lobules are also slightly smaller than the lobules in the tail of the pancreas. This increased firmness is due to Diffuse Lobular Fibrosis in this left branch. The right branch (tail) of the pancreas is normal. The cause for the Acute Pancreatic Necrosis is unknown in most instances although reflux up the pancreatic duct is sometimes considered as is Toxoplasmosis. The Fibrosis is usually considered to be secondary to the acute inflammation but the pancreas may be somewhat different than other organs in this regard.

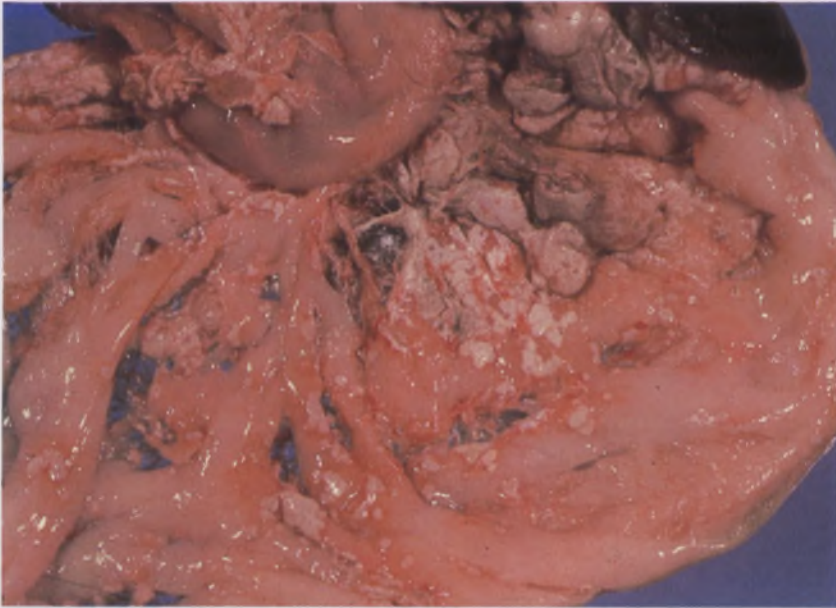


PLATE 203: PANCREATIC FAT NECROSIS

The pancreas is not shown, but the many scattered, opaque, white plaques in the fat of the omentum, mesentery and associated soft tissues are typical areas of Pancreatic Fat Necrosis. This is associated with Necrotic Pancreatitis with subsequent leakage of enzymes including lipases. Many of the plaques show a small border of inflammation. A list of typical Fat Necrosis and inflammation should include the following eight types. Pancreatic Fat Necrosis from necrotic pancreatitis. Traumatic Fat Necrosis from trauma in any species. Steatitis or Nutritional Panniculitis associated with Vitamin E/Selenium deficiency and rancid feeds mostly seen in cats and pigs, Granulomatous Fat Necrosis, a genetically related disease seen mainly in the Channel Island cattle breeds, Guernseys and Jerseys. Granulomatous Fat Necrosis in cattle associated with ingestion of Fescue grass under certain conditions. Retroperitoneal Fat Necrosis and Granulation in horses, which also has no known cause. Ischemic Fat Necrosis seen in strangulated Pedunculated

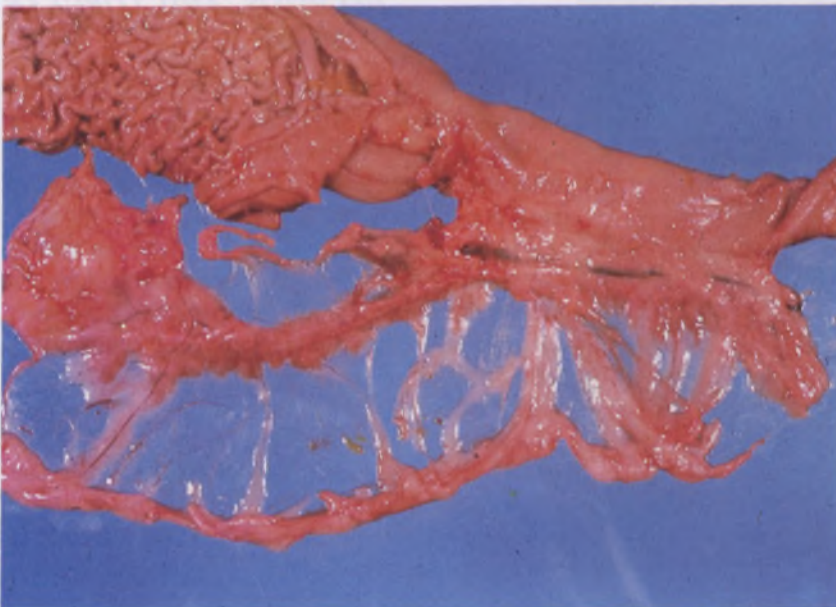


PLATE 204: PANCREATIC FIBROSIS AND ATROPHY

The entire pancreas of a dog is shown here with marked Pancreatic Atrophy of portions of the head and the tail, rendering it just recognizable as pancreatic tissue along its major axis. At the head there is a large round nodule of firm tissue, Similar firm tissue is present near the body but it is not as easily seen. These are the areas of Chronic Pancreatic Fibrosis, the probable end result of Necrotic Pancreatitis. It is surprising that some animals with only this much pancreas and even less do not have Diabetes Mellitus.

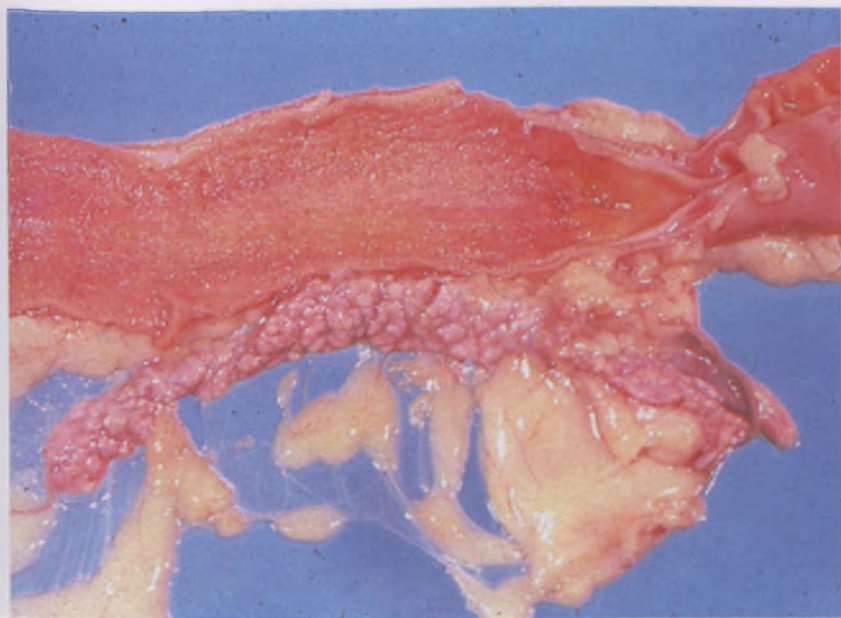


PLATE 205: CHRONIC PERILOBULAR FIBROSIS

The entire pancreas in this cat is only about $\frac{1}{2}$ normal size, very firm and the individual lobules are discretely rounded in this case of Chronic Perilobular Fibrosis. Histologically, connective tissue is increased around each and every lobule. A minimal number of inflammatory cells are present in this organ casting some doubt upon the idea that this is usually the result of chronic pancreatitis.

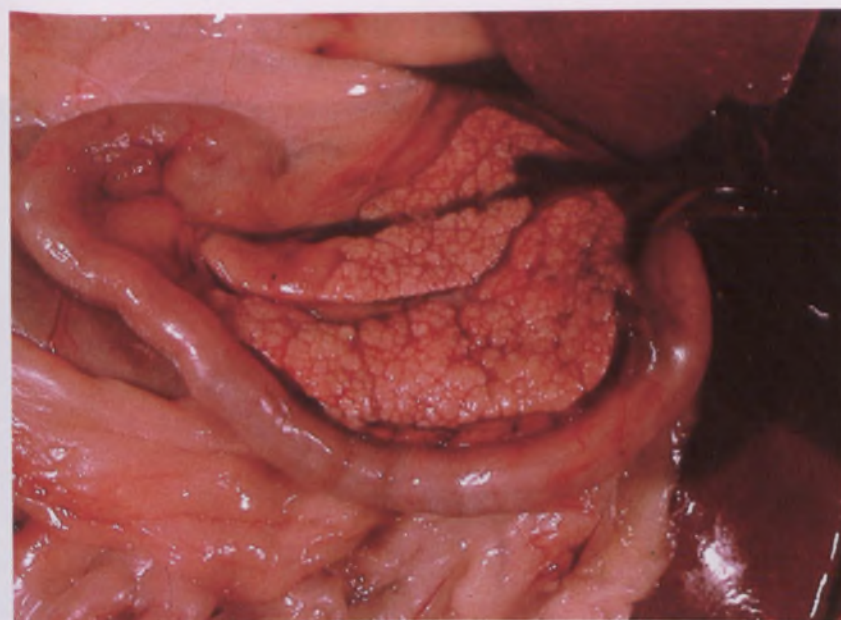


PLATE 206: DIFFUSE INTERSTITIAL PANCREATIC FIBROSIS

The pancreas in this cat is firm and finely nodular, and histologically there is connective tissue around and scattered diffusely throughout each lobule, in this case of Diffuse Interstitial Pancreatic Fibrosis. The cause is unknown and chronic inflammatory cells are not a significant feature of this disease. This disease is to be differentiated from both Chronic Post Necrotic Pancreatic Fibrosis; which would be far more irregular, and from Perilobular Interstitial Fibrosis; in which each and every lobule has connective tissue only around and between lobules but not within the lobules proper.

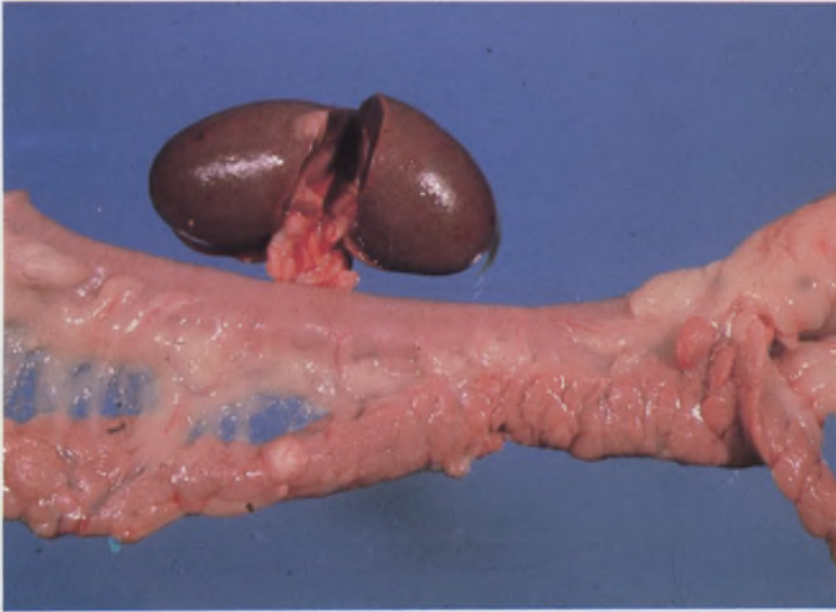


PLATE 207: PANCREATIC ADENOMAS

One large, white, firm nodule with several smaller ones nearby are adenomas. These occur in older, tumor aged dogs, cats and other species quite commonly. Most are benign and may be of acinar or ductal origin. It is possible they could be Islet Cell Tumors but these are usually single tumors. No clinical significance is usually noted with these Adenomas.

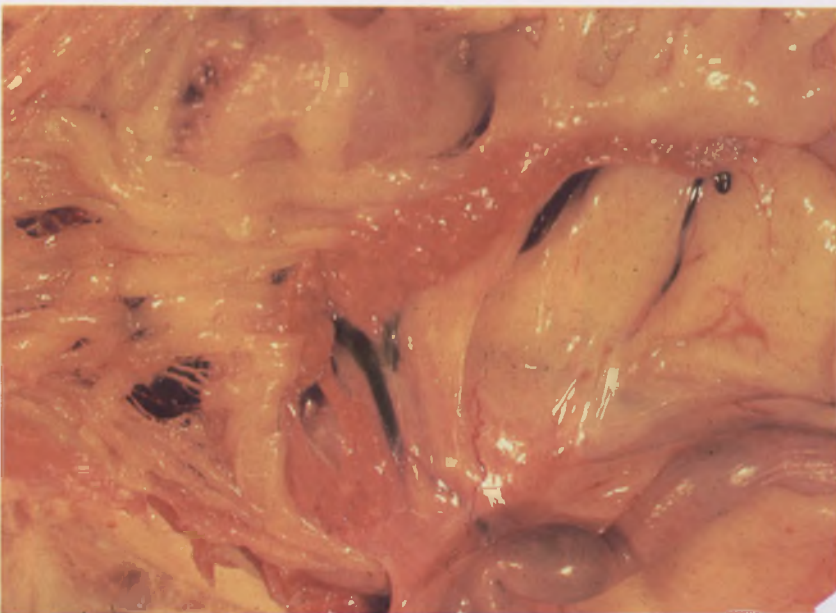


PLATE 208: MULTIPLE PANCREATIC ADENOMAS

The multiple pale nodules just visible in this cat's pancreas are Multiple Pancreatic Adenomas and are common enough to be found in most older dogs and cats. They are benign and may be derived from acinar or ductular epithelium.

**PLATE 209: RENAL HYPERPLASIA,
HYPOPLASIA AND APLASIA**

The slightly larger pale kidney is that of a mature cat which incidentally had only one kidney at birth. The other kidney was never present, a condition termed Aplasia. The pale color and prominent capsular vessels are normal for the cat. The other specimen has a large and a small kidney and is from a baby goat. The presence of, but failure to grow of the smaller kidney is termed Hypoplasia. In both animals the larger kidney is enlarged due to Compensatory Hyperplasia.

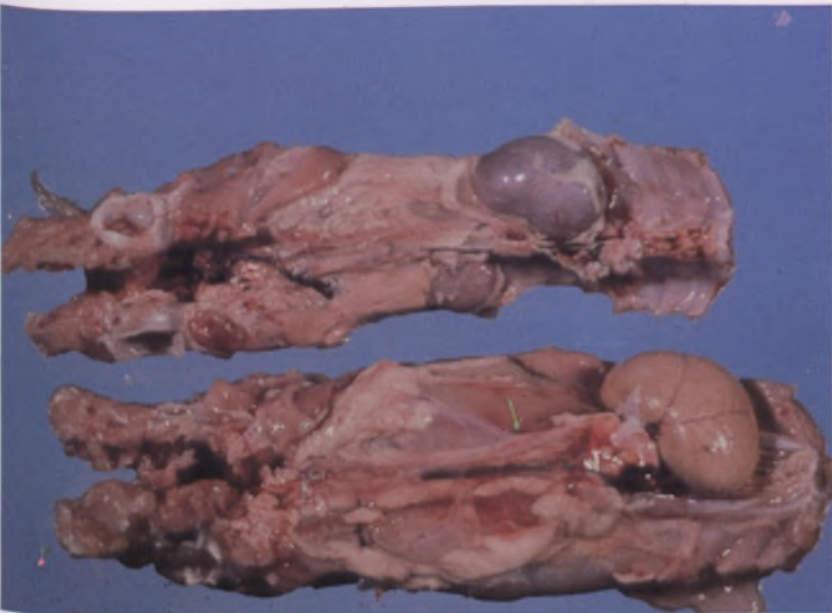
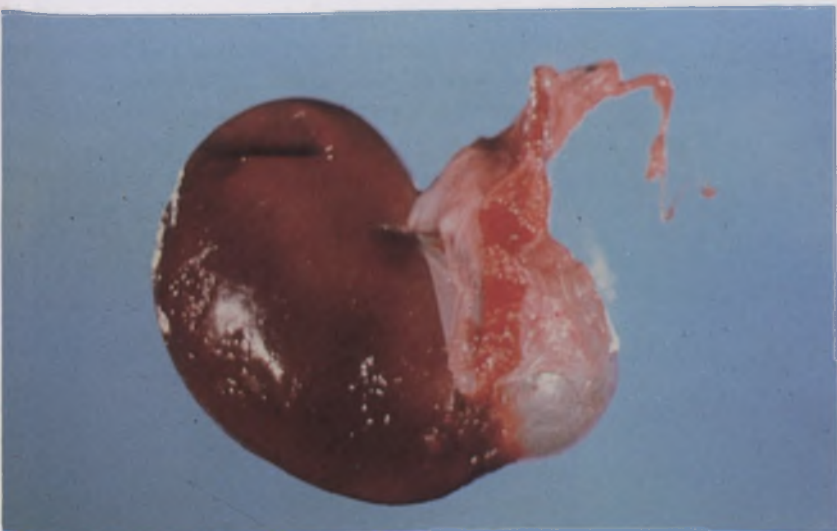

PLATE 210: CONGENITAL UNICYST

This dog's kidney has a single unilocular cyst at one pole. It is a congenital defect of development and not to be considered hydronephrosis, as there is no communication between the lumen of this cyst and the renal pelvis.



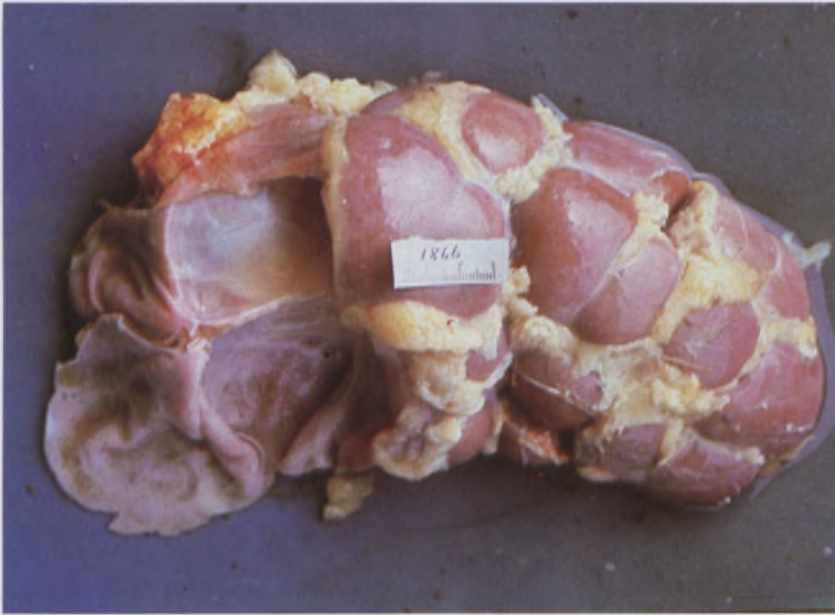


PLATE 211: CONGENITAL MULTIPLE RENAL LOBE CYSTS

Two distinct cystic lobes have been opened in this cow's kidney by cutting away the cortical cap so to speak. These are entire, hollow lobes themselves, and are to be distinguished from the usual polycystic kidneys which are multiple tubule dilatations scattered throughout the renal cortex. These can be likened to hydronephrosis of individual lobes, possibly because of an intrarenal congenital calyx obstruction.

Dr. T.H. Wang, Taiwan, ROC

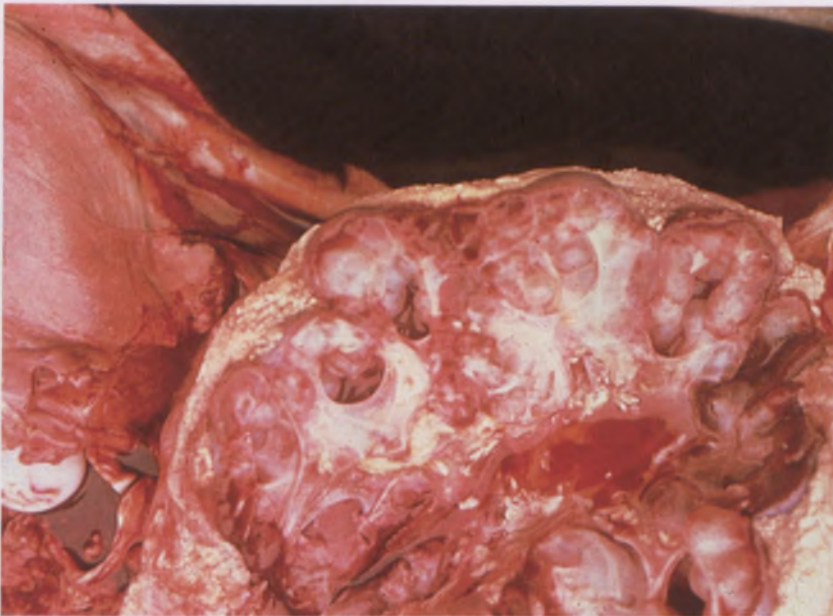
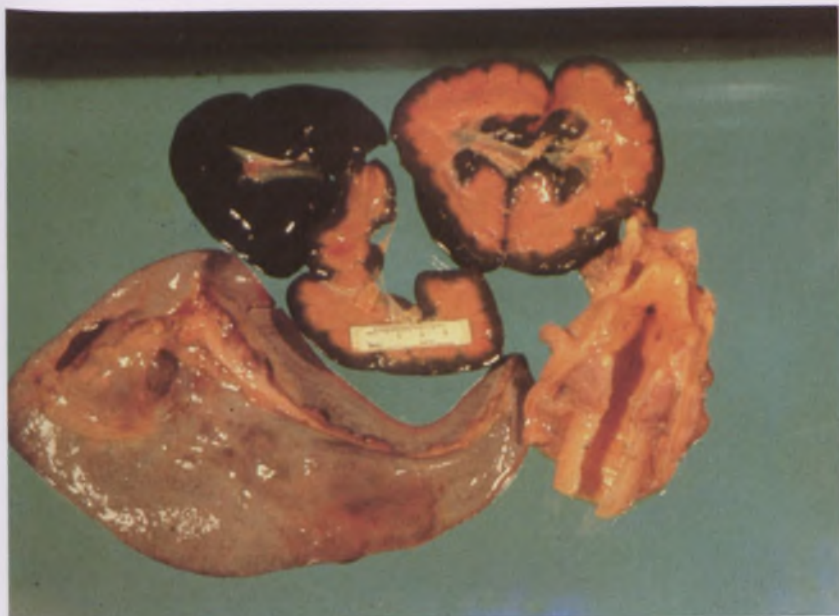

PLATE 212: MULTIPLE RENAL MEDULLARY CYSTS

This fetal calf kidney shows multiple, clear fluid filled cysts limited to the medulla and bulging into the lumen of each calyx. The actual cause is unknown but they are mainly seen in Prolonged Gestation calves. In older animals they may be acquired lesions as from medullary tubular fibrosis. These must be distinguished from the far more common multiple, congenital, cortical cysts.



**PLATE 213: NEONATAL
ISOERYTHROLYSIS**

The icteric larynx, slightly enlarged spleen, and dark, odd colored kidneys came from a few days old foal with Neonatal Isoerythrolysis (Hemolytic Disease of the Newborn). The antibodies to which this foal's red blood cells were sensitive are usually obtained from the colostrum which is different from man in that the antibodies are transferred to the fetus via the placenta. The reverse can occur in both species.

The kidney seen with a cystic center in the corner of one kidney is a kidney notable of Lymphoma. The pale kidney seen is an example of Ectopic Cortical Hypoplasia, a congenital disease of certain breeds of dogs. The dark kidney touching both of the above is from a young dog with multiple pale foci of Multifocal Intercapillary Nephritis caused by parasite migration, most commonly ascaris. The largest kidney seen in the corner has several well marked infarctions of the cortex with pale

Dr. L. Roth, Oklahoma, USA



**PLATE 214: NEONATAL
ISOERYTHROLYSIS**

These green kidneys came from a severely icteric several days old foal. It received antibodies against its own red blood cells from the colostrum. Its mother had at sometime in this pregnancy, or a previous one, absorbed fetal blood of another type to which she became sensitized and synthesized antibodies. These then are present in the colostrum of subsequent pregnancies. In the first few days of life, while the foal was still able to absorb large protein molecules it did so with these disastrous effects. The green discoloration is mostly due to biliverdin an incompletely metabolized bile pigment.

Dr. C. Huxtable, Australia

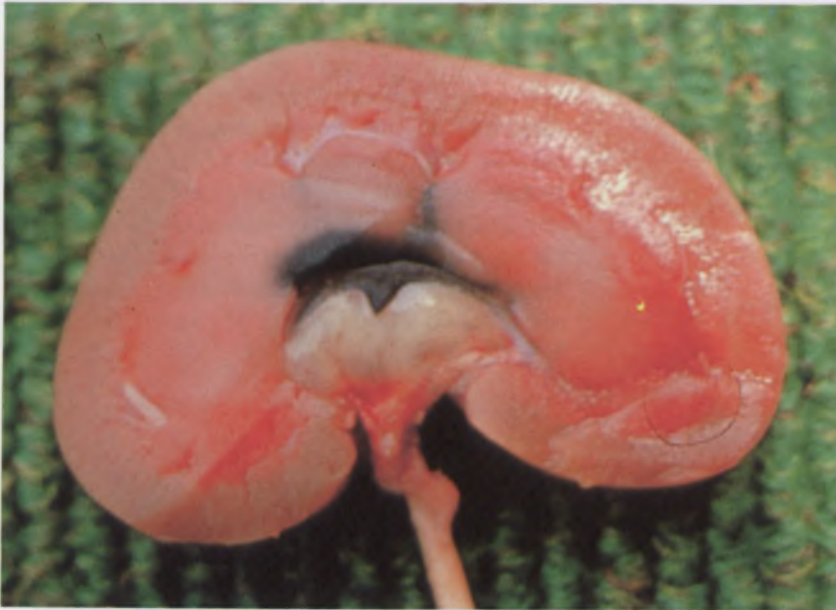

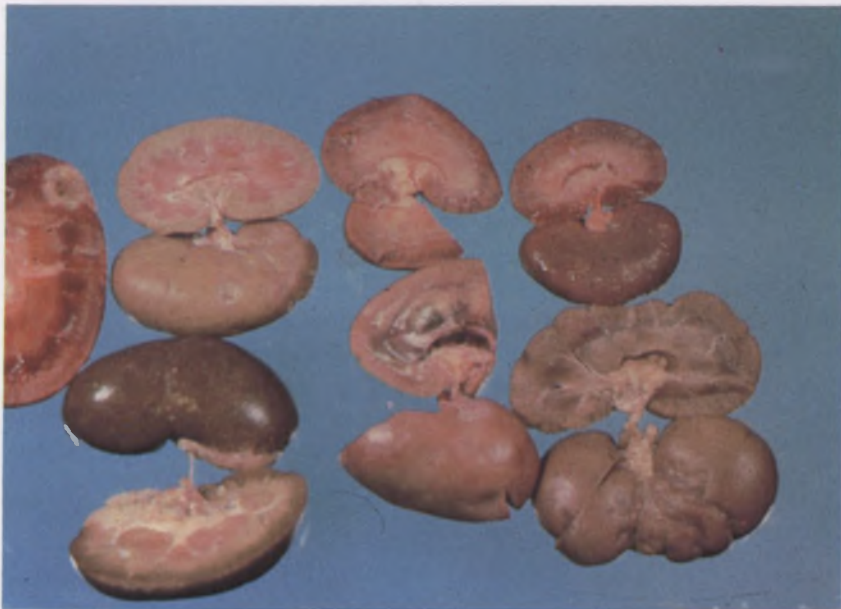PLATE 215: RENAL MELANOSIS

A portion of this lamb's renal pelvis and medulla has black melanin pigment deposition called Melanosis. This is normal and can affect the meninges, brain, adrenals, lung, aorta, uterus, liver, and other tissues as well as the kidneys. It is to be differentiated from Pseudomelanosis which is a bacterial reaction on blood with hydrogen sulfide production seen as a postmortem change most often associated with the bowels and organs adjacent to them.

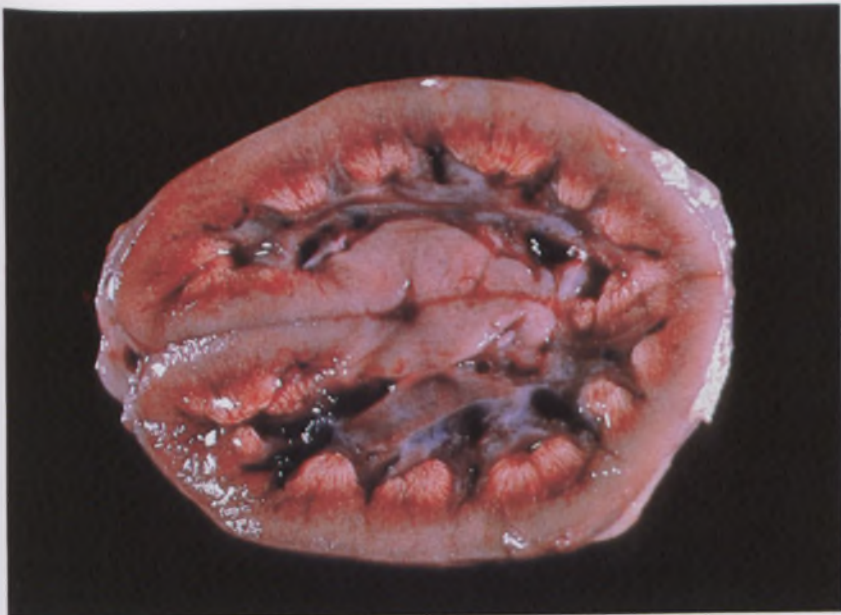PLATE 216: MULTIPLE CANINE RENAL LESIONS

Dr. L. Roth, Oklahoma, USA

The solitary mass with a cystic center in the cortex of one kidney is a solitary nodule of Lymphosarcoma. The pale kidney near it is an example of Endstage Cortical Hypoplasia, a congenital disease of certain breeds of dogs. The dark kidney touching both of the above is from a young dog with multiple pale foci of Multifocal Interstitial Nephritis caused by parasite migrations, most commonly ascarids. The largest kidney seen in the corner has several well marked indentations of the cortex with connective tissue. These represent either old Infarcts with scarring or areas of old Pyelonephritis with local scarring. Usually, but not always, chronic Pyelonephritis has more fibrotic lesions in the renal medulla, functionally underneath the cortical scars. In the other corner is a dog's kidney with many clear Cortical Cysts. These could be congenital or the result of toxic tubular injury that traps cortical tubules in the subsequent repair process causing them to dilate. The dog's kidney between the large corner kidney and the darkest kidney has a very swollen mottled pale medulla. This is a more diffuse form of Lymphosarcoma of the medulla. The last kidney to be described is in contact with this one and it shows a distinct pale zone at the inner cortical area. The exact cause of this rather common finding under many conditions is unknown but by frozen sectioning, the paleness is shown to be lipid, Tubular Lipidosis.

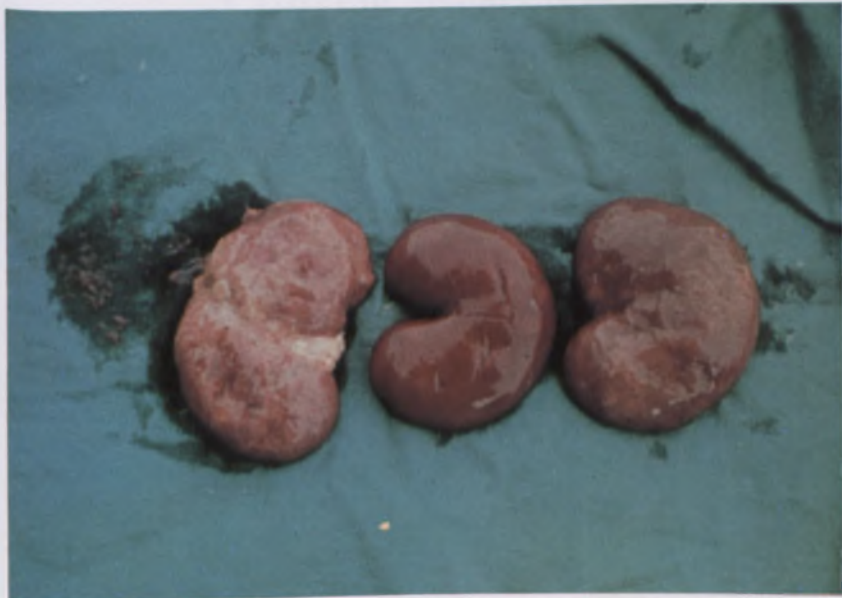


Dr. C. Huxtable, Australia

PLATE 217: DEHYDRATION SALTS

The distinct whitish streaks in the renal papillae of this baby pig's kidney are the result of precipitation of urinary salts, not washed out because of decreased fluid intake for whatever reason. They will wash out during histological tissue preparations so they will not be seen in H&E stained slides. Their significance is only to denote some degree of dehydration, but they are often mistaken for drug, especially sulfa drug, precipitates. Most deleterious precipitates would be higher in the medulla and would cause renal swelling and a wet parenchymal appearance with loss of distinct cortical striations.

Dr. L. Koch, Cornell, USA

PLATE 218: RENAL AUTOLYSIS

The two outside kidneys are very soft and friable compared to the center normal kidney. The soft friable condition is due to severe and rapid autolysis that occurred after death in a lamb dying from Enterotoxemia caused by *Clostridium perfringens* type D. It is partially explained by the fact that often the urine in such cases is positive for sugar and as is the renal parenchyma and this affords a better substrate on which autolytic enzymes can act. Everything else being equal, this is one case where autolysis helps to make a diagnosis easier.

Dr. J. Linn, Cornell, USA

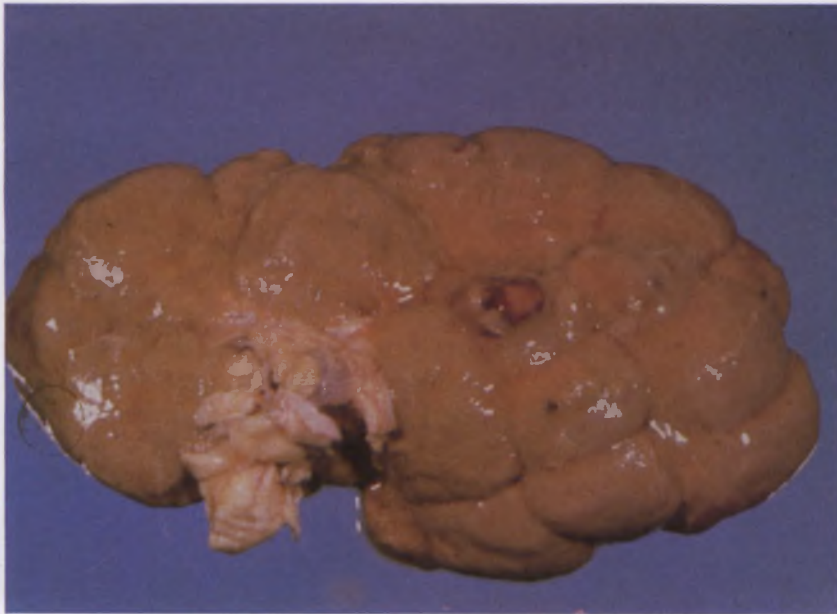

PLATE 219: PULPY KIDNEY AND INFARCTION

The soft, mushy nature of this cow kidney is apparent as is the single, discrete, hemorrhagic outlined infarct in one lobe. In actual fact, the infarct is firmer and less autolytic than all the remaining kidney as that area did not receive any glucose from therapy that the remaining kidney received just prior to death. After death the high glucose levels in the tubules allowed them to autolyze faster and further than the vascularly deprived infarcted area. The cow, incidentally, died as a result of a displaced abomasum.

Dr. L. Fourn, Oklahoma, U.S.A.

The kidney seen with a cystic lesion in the cortex of one kidney is a kidney module of *Lymphocystis*. The pale kidney seen is an example of *Endometrial Hyperplasia*, a congenital disease of certain breeds of dogs. The dark kidney (cutting back of the above) is from a young dog with multiple pale foci of *Interstitial Nephritis* caused by *prostatic neoplasia*, *prostatic carcinoma*. The largest kidney seen in the series has several well marked *interstitial nephritis* foci with *con-*

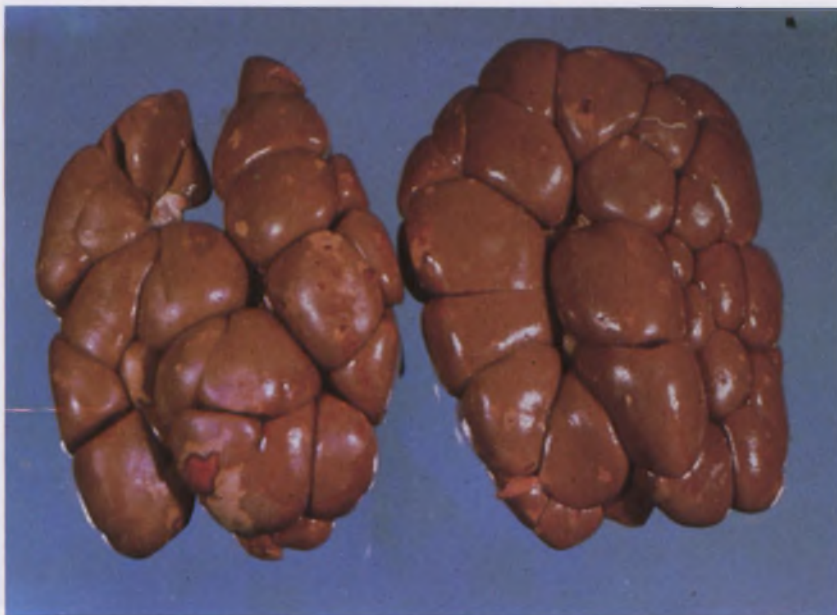

PLATE 220: MULTIFOCAL INFARCTIONS

The dark red areas scattered in these cow kidneys are hemorrhagic infarcts and are the result of intravenous fluid therapy. Around many of these is a definite yellow zone of parenchymal degeneration. In fact there are many areas of yellow degeneration without necrosis. The difference between these yellow areas of degeneration and the discrete red areas of necrosis, is that there is more vascular obstruction to the areas of necrosis than to the areas of degeneration. Some have termed these pale yellow areas as "incomplete infarctions". The pathogenesis for the infarcts from intravenous therapy may be emboli from the fluid itself or even thrombi which form in the kidney from the intravenous fluid.

Dr. L. Fourn, Oklahoma, U.S.A.

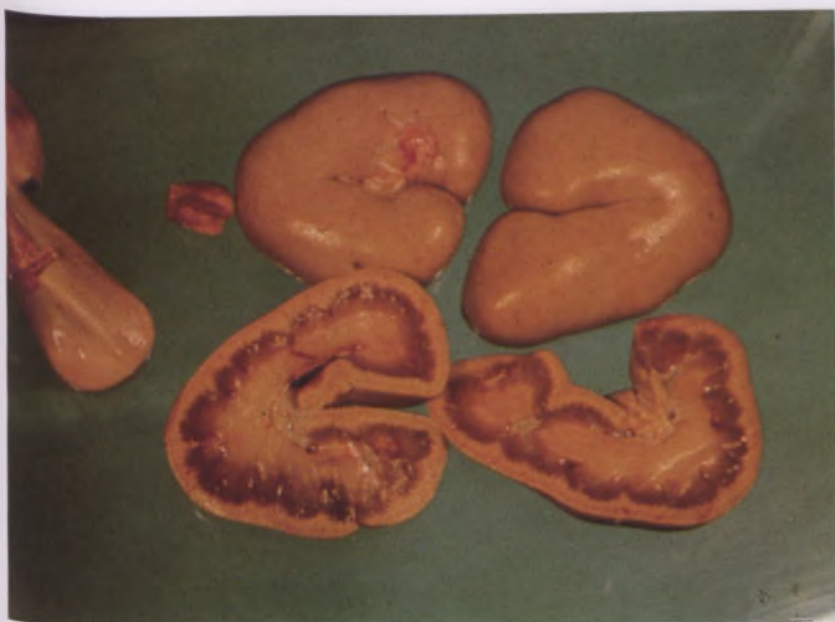

PLATE 221: DIFFUSE RENAL MINERALIZATION

The horse's kidney shown here is pale and when examined histologically shows massive mineralization of tubules and interstitium. Slight mineralization can be observed on the ventral surface of the tongue. In addition many soft tissues of the body were also mineralized grossly and microscopically. Excess Vit. D was the cause in this case but plant poisoning with such plants as *Cestrum* spp. and renal failure for any reason with uremia may also be causative.

Dr. L. Krook, Cornell, USA

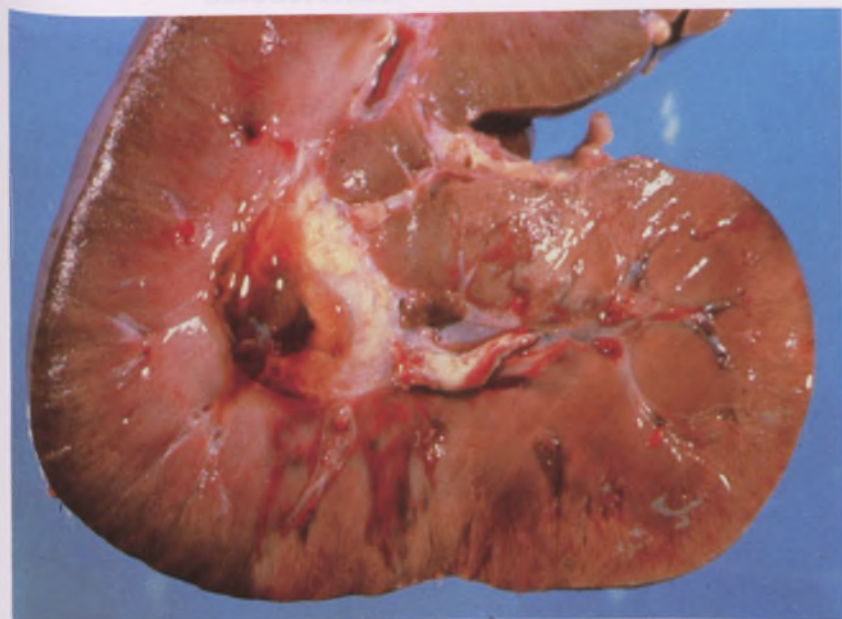


PLATE 222: MULTIPLE RENAL HEMORRHAGES

The scattered areas of blood in this horse kidney primarily near the major vessels of the corticomedullary junction are hemorrhages resulting from dicoumerol therapy for founder. It resulted in frank hematuria. Such a lesion is also common in pigs on a Vit. K deficient diet.

Dr. J. Lowe, Cornell, USA

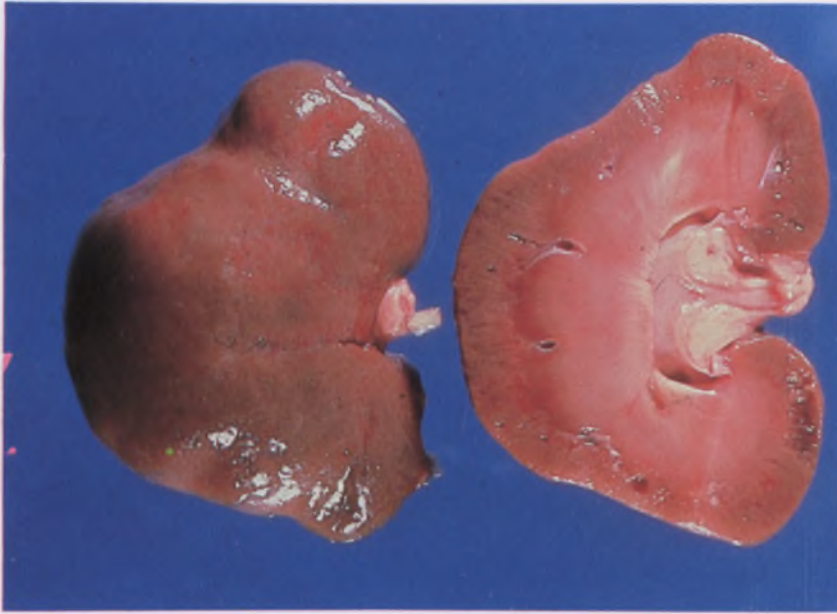
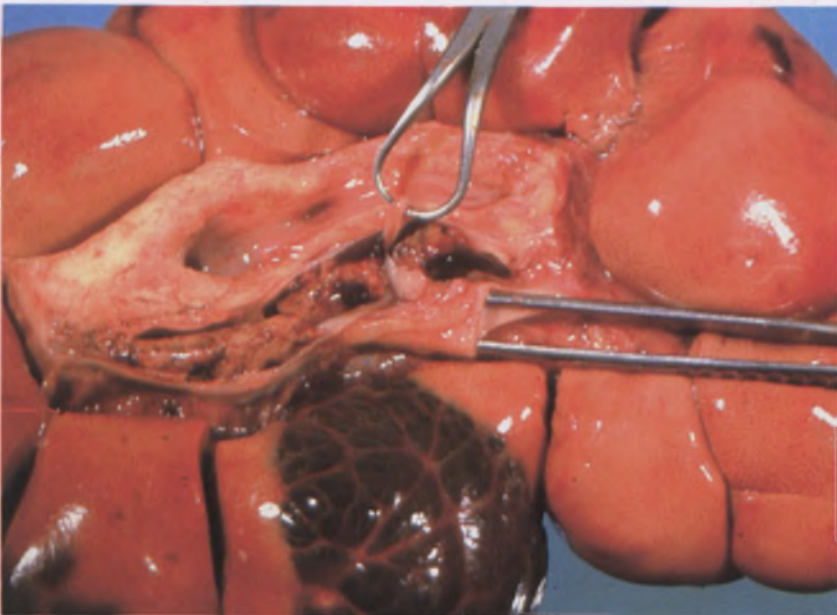


PLATE 223: HEALED POLAR INFARCTION

The distinct blunted triangular form of this kidney is due to atrophy of both poles. The actual cause is in dispute in these cases. One idea is that it is the result of urinary back pressure closing off vessels that make the acute bend to run to the poles. Another idea is that it is a reflux nephritis.

Dr. T. Van Winkle, Cornell, USA

PLATE 224: RENAL VEIN THROMBOSIS



The spring tooth forceps are holding the renal artery open just under a dark cystic renal lobule. A pair of towel forceps have pinched into a renal vein wall to show the presence of a fragile Renal Vein Thrombus. Some of these are associated with renal infarcts. Clinically most are associated with the animal having a history of diarrhea or extensive electrolyte fluid therapy. This has been seen in many species but mostly cattle and horses. It is well recognized in man. The cause is not known but it probably has to do with the severe electrolyte shifts in the renal capillary bed allowing for venule side intravascular clotting. The congenital cystic lobule is of no consequence in this case. This cow did have pulmonary artery embolism from these renal vein thrombi which were in both kidneys. They are often unilateral. Being a relatively new finding, their clinical importance is still to be evaluated.

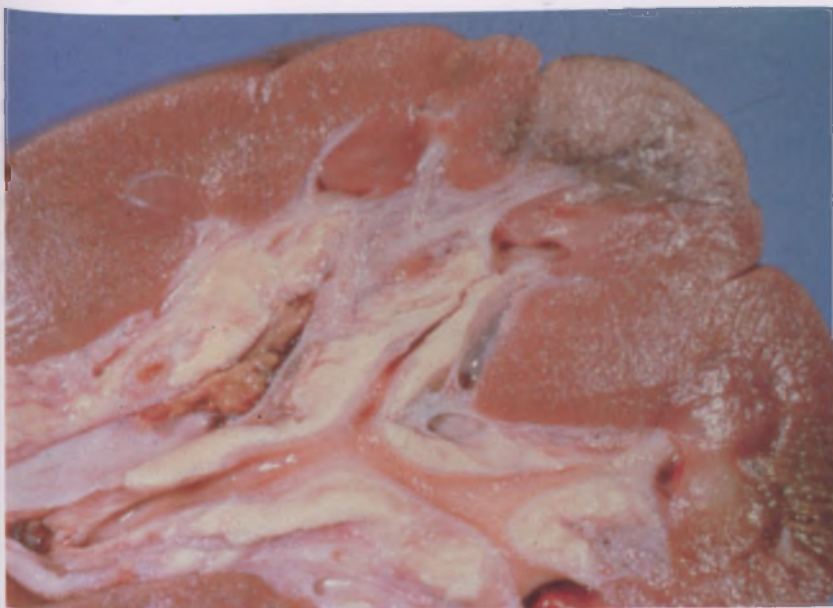


PLATE 225: RENAL VEIN THROMBOSIS

This bull's kidney shows a well formed Renal Vein Thrombus and distal to it a discolored area of renal infarction. While some, as this one did, have infarction associated with them, many do not. The cause is not known, but they are associated in humans and in the animals noted to date, with diarrhea or intensive electrolyte therapy. They are easily overlooked.

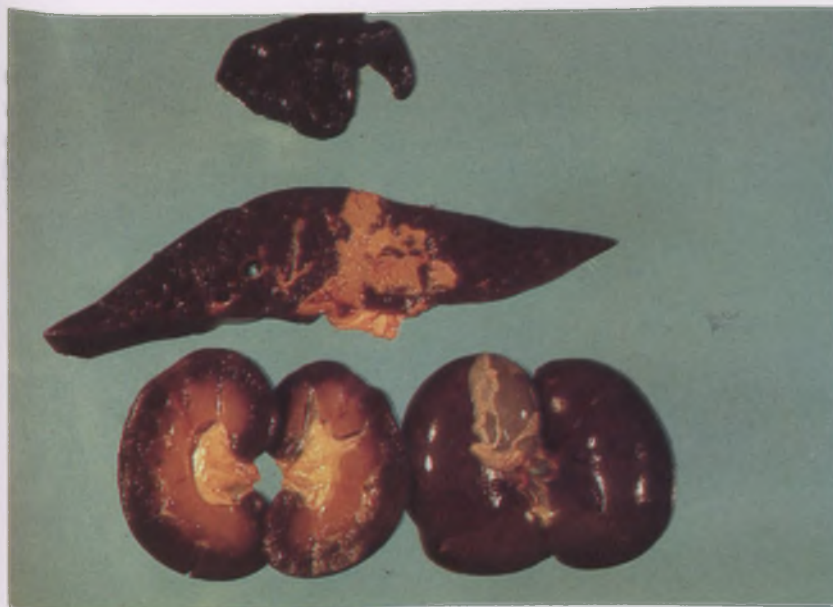
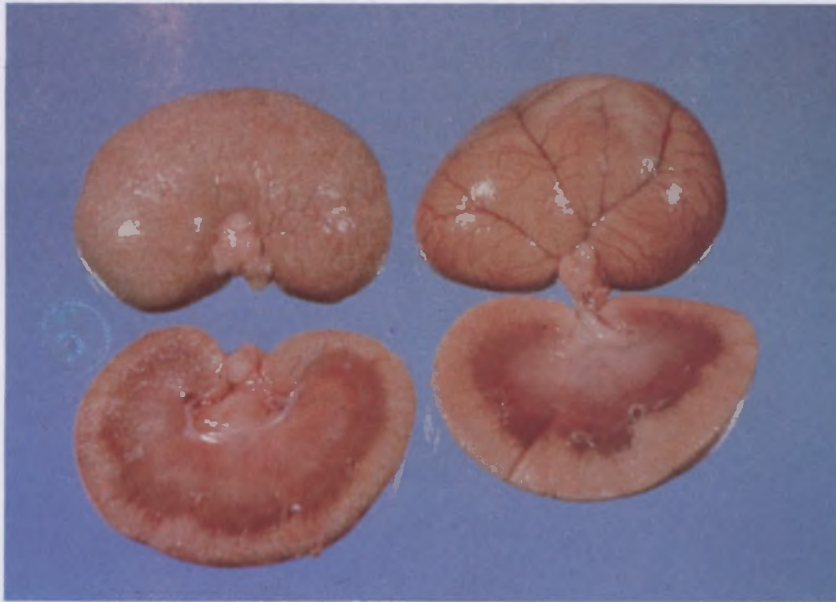
PLATE 226: HEMOGLOBIN STAINED KIDNEYS

The double pointed piece of tissue in this picture is a piece of sheep liver showing a central area of necrotic debris with a layer of fibrin over the area. A mass of abdominal blood clot is also shown along with the two dark hemoglobin stained kidneys. This is one of several sheep that had a traumatized liver following shearing with abdominal hemorrhage and subsequent hemoglobinuria. If the sheep had lived, it could have developed hemoglobinuric nephrosis. It is thought by most that hemoglobin itself will not cause the nephrosis, but that severe blood breakdown plus the anemia occasioned by that can cause the nephrosis. Even blood loss into the gastrointestinal tract as seen with bleeding gastric ulcers can cause hemoglobinuria and icterus.

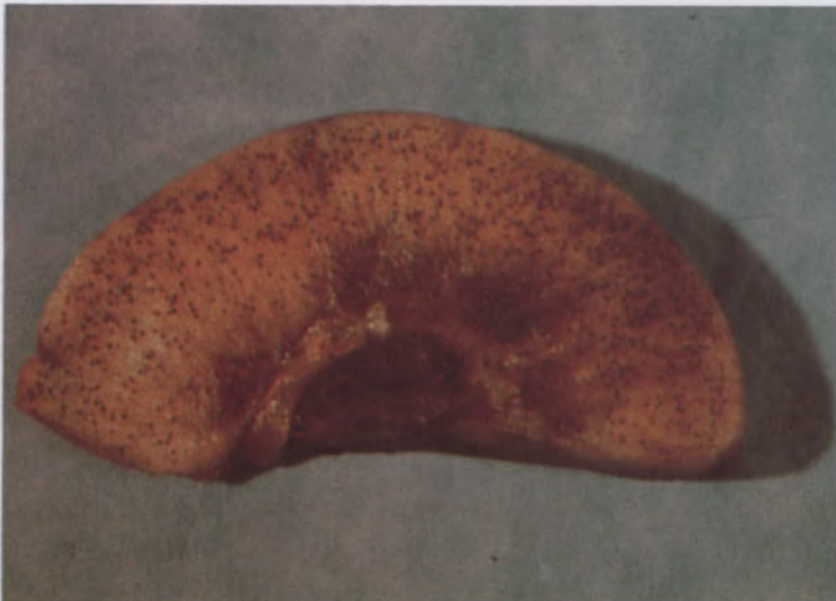

Dr. R. M. Lewis, Cornell, USA

PLATE 227: RENAL AMYLOIDOSIS

The slightly smaller kidney with prominent surface vessels is from a normal cat. The other kidney is small and firm with a decreased cortical thickness and many tiny opaque white foci scattered in and on the cortex. This latter kidney is from a dog with renal amyloidosis. At one time kidneys with amyloidosis were thought to be enlarged, pale and firm but now they are almost any combination of lesions or even appear normal.

PLATE 228: RENAL VEIN THROMBOSIS



Dr. L. Roth, Oklahoma, USA

PLATE 228: RENAL AMYLOIDOSIS

This dog's kidney has been stained with iodine to show the affinity of the starch like amyloid for iodine. Each and every affected glomerulus stains mahogany brown. It should be noted that not all cases of renal amyloidosis, in fact only about 50 per cent, show this positive staining reaction.

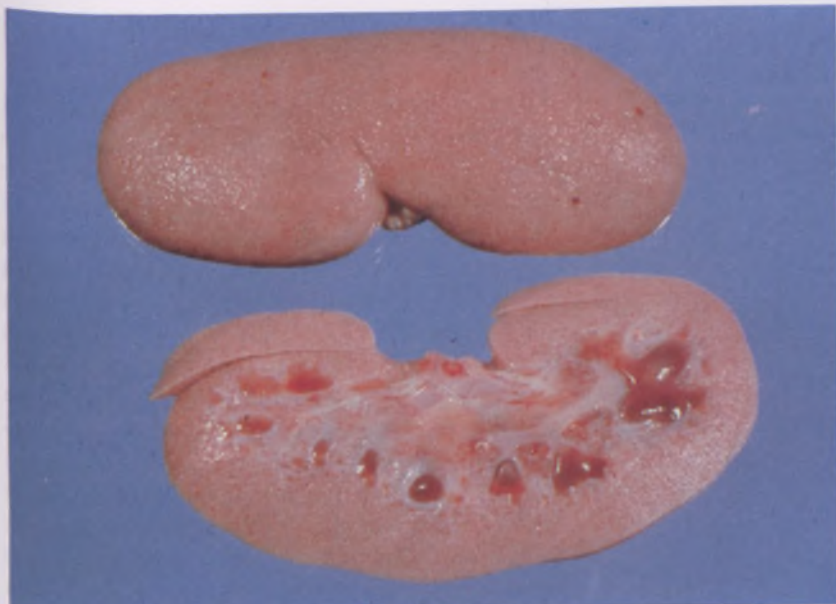


PLATE 229: DIFFUSE RENAL INTERSTITIAL FIBROSIS

This is an excessively firm pig kidney due to large amount of fibrosis distributed throughout the kidney but more in the cortex than the medulla. Affected kidneys may be normal or slightly enlarged. this is a case Ochratoxicosis caused by the mycotoxin, ochratoxin elaborated by the mold *Aspergillus ochraceus*. Chronic lead poisoning in the pig could also be suspect in such cases.

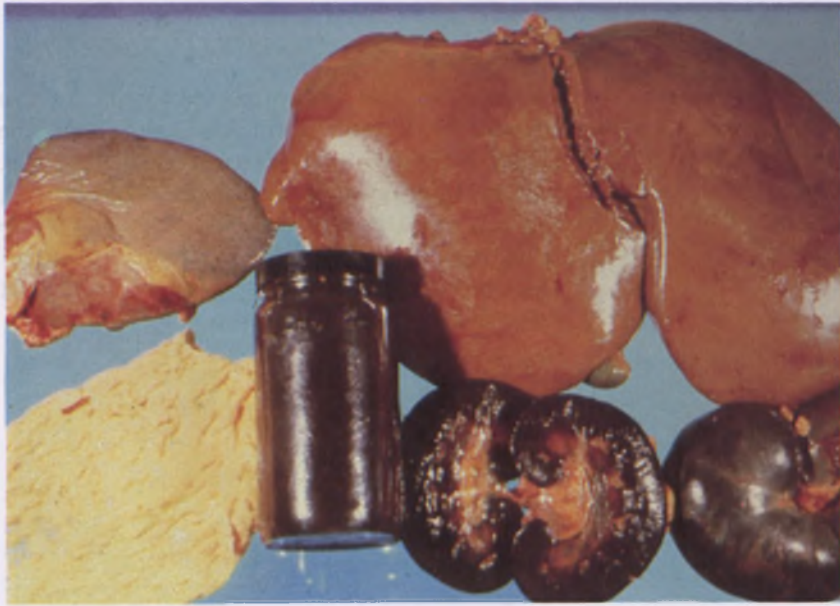Dr. C. Wilke, Cornell Univ. School of Veterinary Medicine, Ithaca, N.Y. 14853. This kidney was found in a pig that had been fed a diet containing a large amount of moldy feed. The kidney was found to be excessively firm and the cortex was thickened. The medulla was normal. The cause of this condition is not known.



PLATE 230: CESTRUM SPP.

This plant is quite widespread in the world. Certain species of it when eaten by animals can cause generalized soft tissue mineralization leading to debility and death. This plant was growing in Africa.

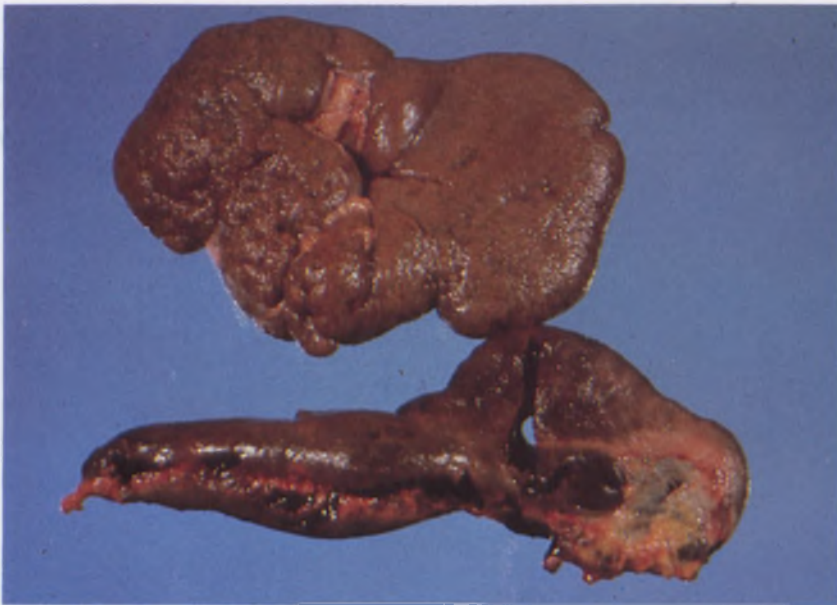Dr. G. Appel, Africa



Dr. C. Wilhelmsen, Cornell, USA

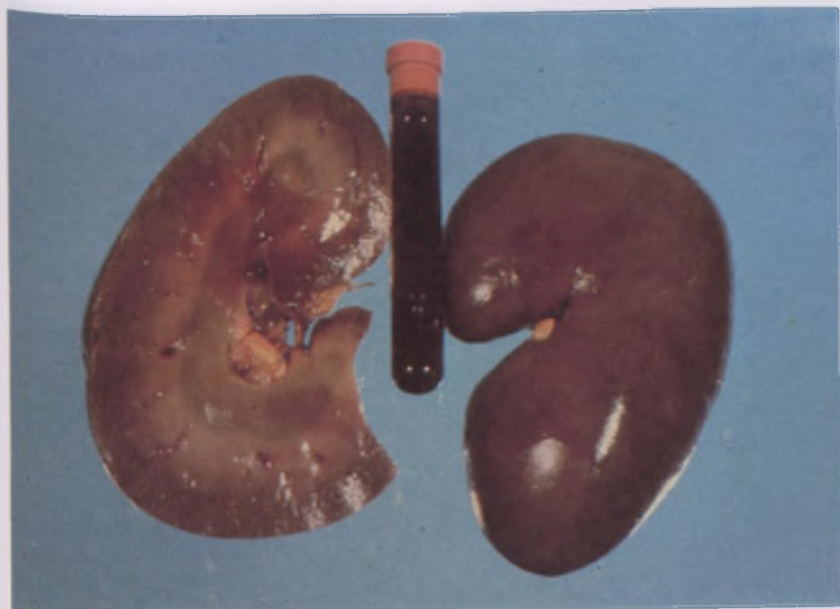
**PLATE 231: CHRONIC COPPER
POISONING**

The enlarged pulpy spleen, icteric omental fat, fatty liver, dark kidneys and dark red urine are all findings consistent with prolonged ingestion or massive ingestion of copper. Often it is associated with sheep drinking foot dip materials containing copper, eating the grass near these dips, eating grass treated with copper or being wormed over a long period of time. Initially the problem was considered to be directly related to the amount of copper ingested but many animals even in the same flock with similar lesions would have essentially normal levels of hepatic or renal copper. In 1976, Cornell Emeritus Professor, Dr. Peter Olafson, suggested this might possibly be due to a unique red blood cell sensitivity to copper. It was subsequently shown that following prolonged copper therapy that sheep red blood cells do in fact become sensitized on their cell membrane and spontaneously hemolyze even without elevated copper levels. Maybe this might explain some of the many puzzling cases of Enzootic Icterus in the world.



**PLATE 232: HEMOGLOBINURIC
NEPHROSIS**

This horse died as a result of renal failure caused by hemoglobin from abdominal blood breakdown. The spleen had ruptured previously causing intra-abdominal hemorrhage and was the source of blood. Histologically, tubular nephrosis and fibrosis and much brown pigment was present in the tubules and interstitium. The multiple irregular depressions are the result of the maturation shrinkage of the connective tissue along with tubular collapse associated with the nephrosis. Anemia is considered by some to be a necessary factor to cause nephrosis in such cases.



**PLATE 233: RED MAPLE
HEMOGLOBINURIA**

The dark kidneys and dark urine in the tube are from a horse that ate slightly wilted leaves from a Red Maple tree (*Acer rubrum*). It caused an acute hemolysis with the resultant hemoglobinuria and dark hemoglobin stained kidneys. Moderate icterus was also present in the horse. This relatively newly recognized disease results from horses eating the leaves of recently damaged red maple trees. Recently many cases followed a hurricane along the eastern shore of the United States. Apparently other species so far have not been affected and some horses are more susceptible than others.

Dr. S. Dill & Dr. B. Tennant, Cornell

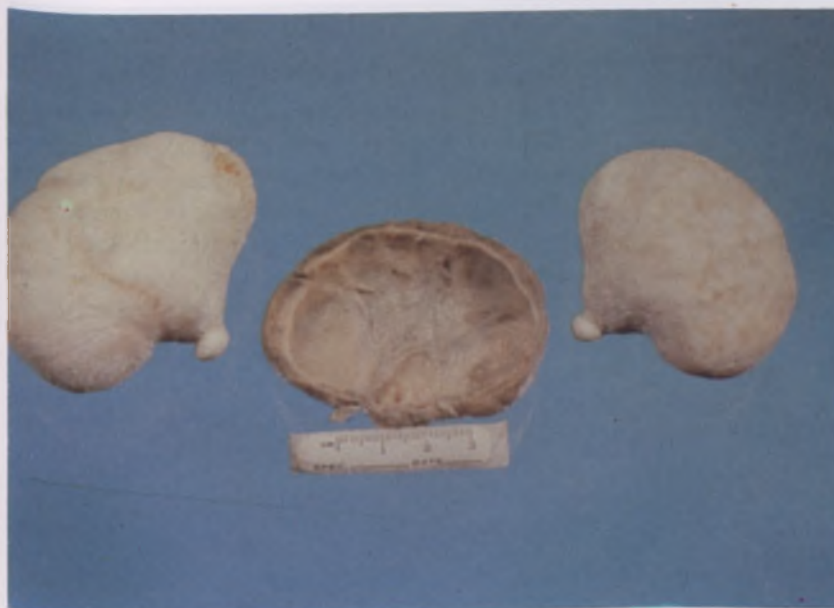

PLATE 234: RENAL CALCULI

This dog was considered normal almost to the day it died with these enormous calculi. Only the half of one kidney is in the picture with the calculus from each kidney. It is of interest to realize animals can live with so little vital, normal tissue.

Dr. G. Sykes, Cornell, USA

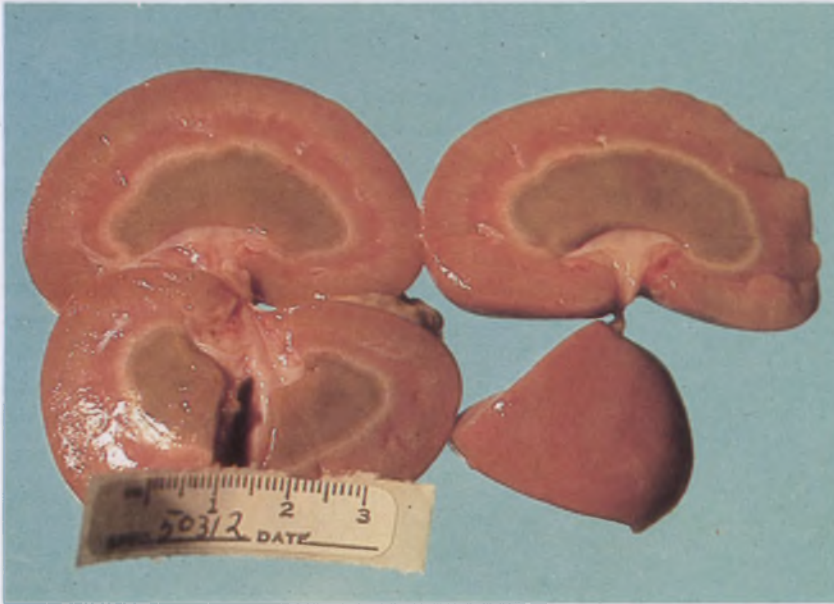

PLATE 235: TOXIC (ARSENIC) MEDULLARY NECROSIS

This dog's kidney shows massive discoloration of the entire medulla as the result of necrosis due to Arsenic Poisoning. In the dog this is the most common lesion, while in cattle arsenic is usually a nasal mucosa irritant. In one outbreak studied, large numbers of dogs died or had to be destroyed because dog feed was mixed in the same commercial mixer that arsenic treated chicken feed had been mixed, without thorough cleaning between mixings.

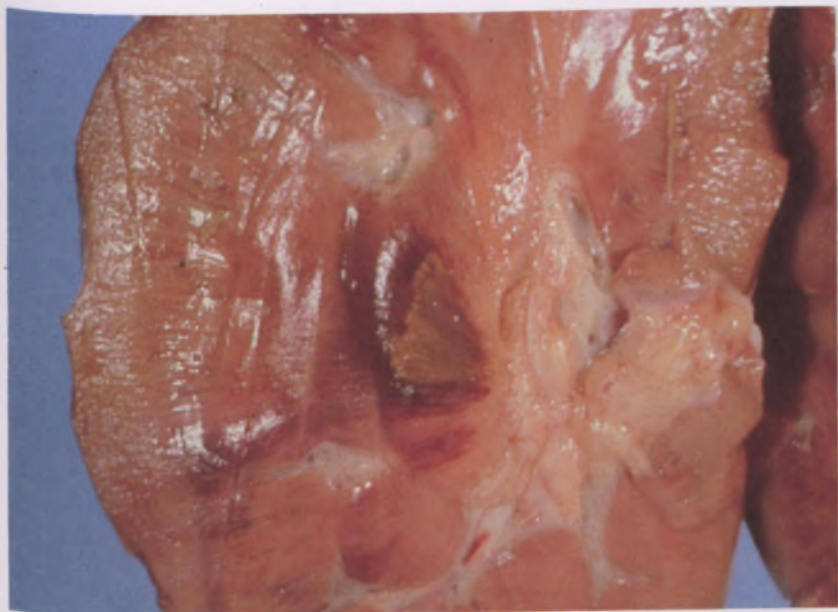
Dr. C. I. Liu, Taiwan, ROC

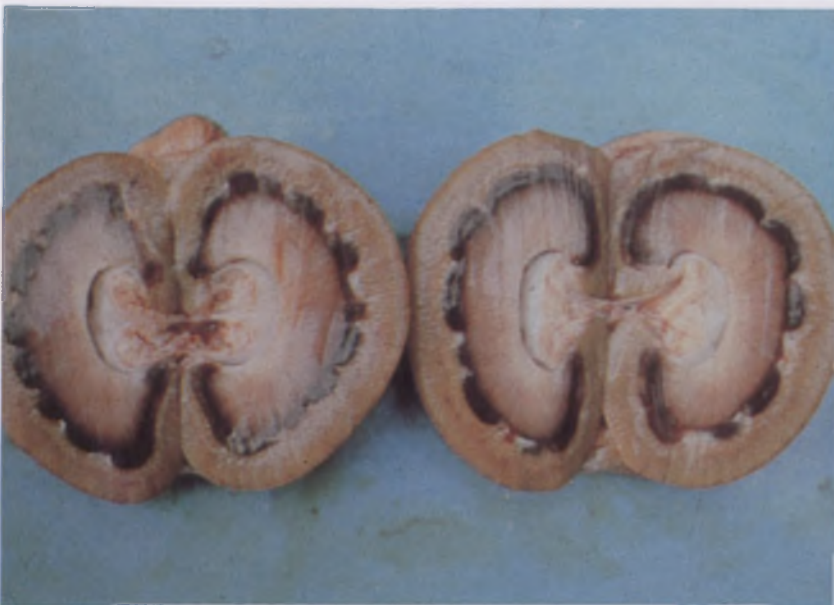

PLATE 236: TOXIC (ARSENICAL) NEPHROSIS

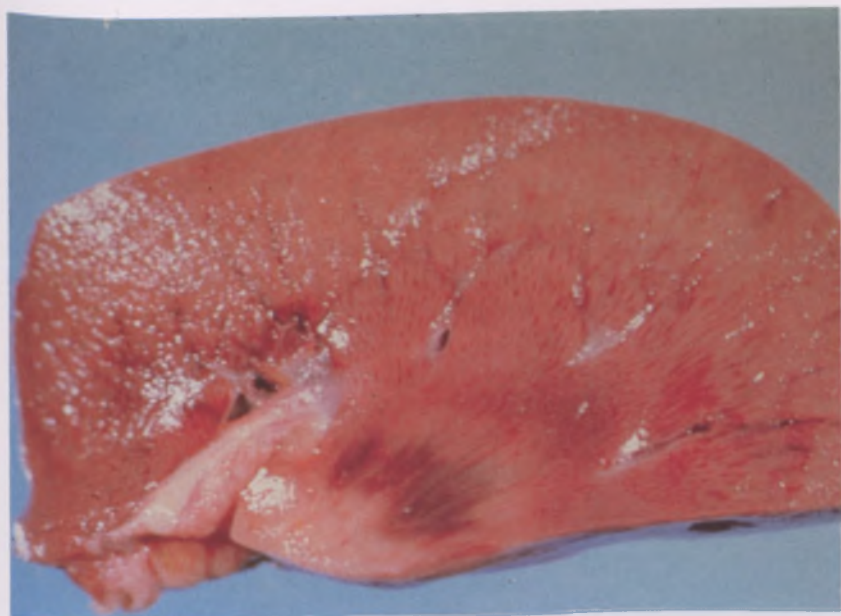The corticomedullary zones of this dog's kidneys are swollen and markedly congested. Histologically early outer zone papillary necrosis was observed. The dog had been overdosed with arsenicals for heartworm control. It is of note that some dogs are more susceptible than others as such a lesion may be seen with only a small overdose of similar compounds.

Dr. C. I. Liu, Taiwan, ROC



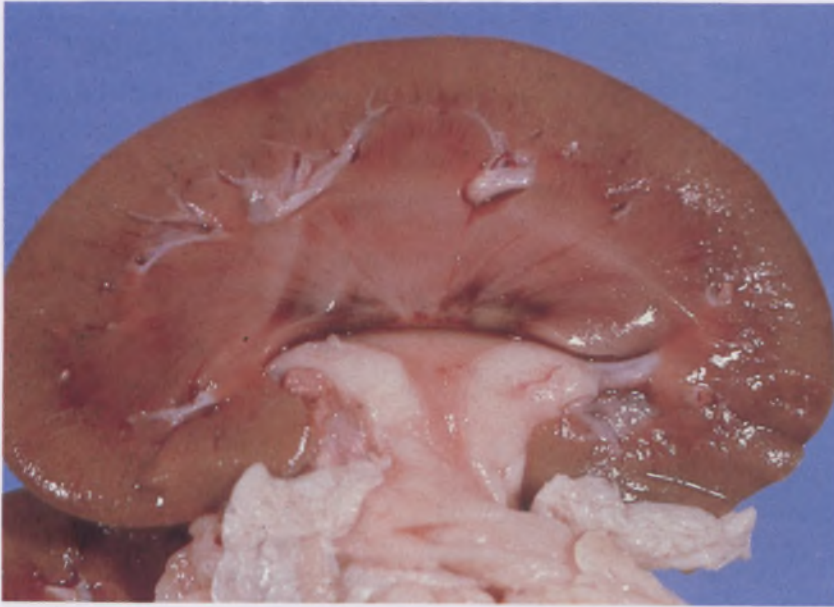**PLATE 237: ACUTE RENAL
PAPILLARY NECROSIS**

The yellow green triangular area of dull tissue is evidence of papillary necrosis in this horse kidney it is surrounded by an inflammatory zone. This lesion is most often associated with nonsteroidal anti-inflammatory drug use. By itself it is usually not considered a significant lesion.



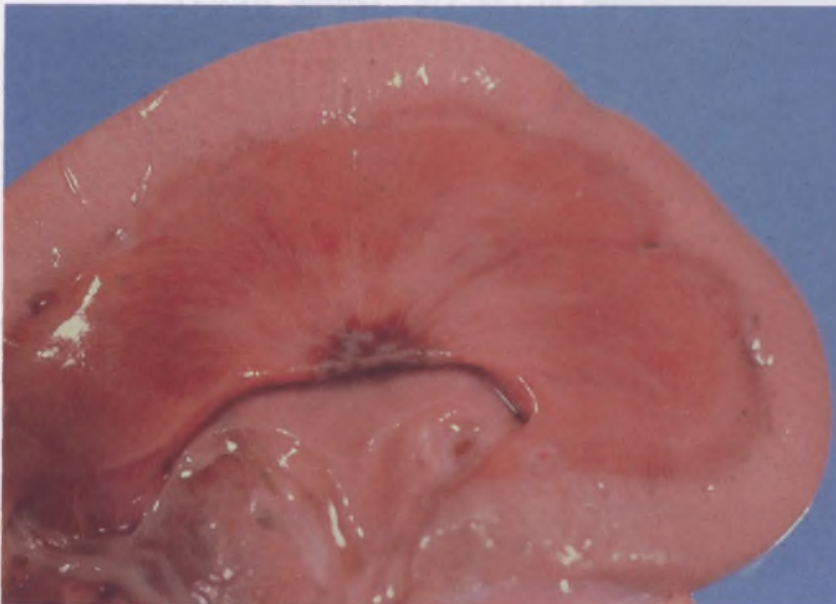
**PLATE 238: ACUTE RENAL
PAPILLARY NECROSIS**

The section through a horse's kidney shows the relative ischemia of the tip of the medulla just under the renal crest and below that the zone of intense congestion. This is a very early lesion of papillary necrosis commonly caused by the excess use of the common nonsteroidal anti-inflammatory drugs. It is usually not a very significant lesion. As prostaglandins are concentrated in this region, the lesion is thought to be related to the metabolism of the drugs with this substance.



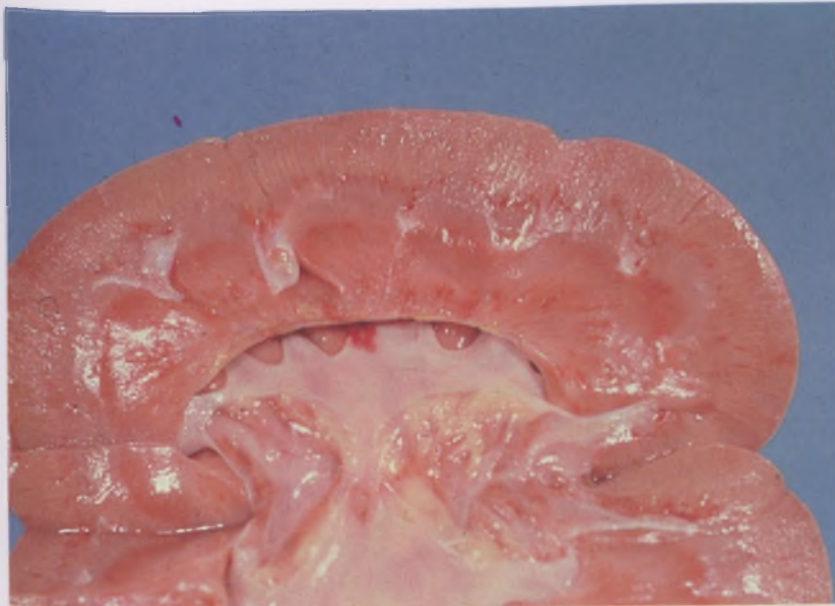
**PLATE 239: ACUTE RENAL
PAPILLARY NECROSIS**

This goat's kidney shows several of the typical pale foci of acute necrosis surrounded by inflammation on the renal crest. The history was that the animal died from renal calculi but as this lesion is not the usual one for obstruction the history was checked further and it was noted that the animal had been treated extensively with a common nonsteroidal anti-inflammatory drug. This lesion is more common in horses probably as these drugs are more commonly used in horses.



**PLATE 240: ACUTE RENAL
PAPILLARY NECROSIS**

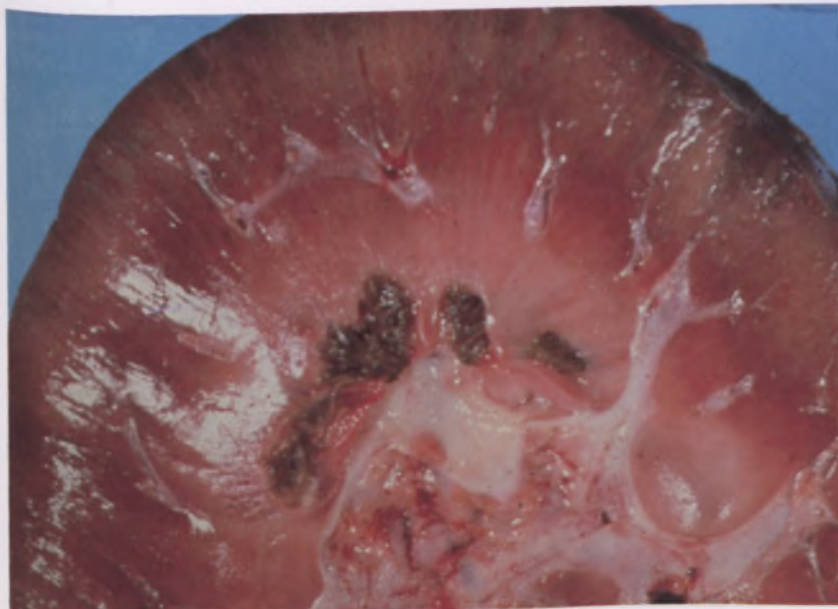This baby llama's kidney shows a classic area of yellow green necrosis surrounded by an irregular zone of congestion and hemorrhage right on the renal crest. This type lesion is commonly seen in several species, especially the cat and horse which are on high levels or prolonged use of nonsteroidal anti-inflammatory drugs. This animal had a broken back and had been treated for some time with all types of drugs including a common nonsteroidal anti-inflammatory for 6 weeks. It is thought that prostaglandins play a role in this because of their normally high concentration in the renal medulla.



Dr. J. Crisman, Cornell, USA

**PLATE 241: SUBACUTE RENAL
PAPILLARY NECROSIS**

The yellow debris along the renal crest of this dog's kidney is necrotic medullary tissue that is in the process of sloughing. A short distance away from the crest is an entire zone of depression with scattered debris still present. This represents a more subacute or even chronic lesion with loss of parenchyma to account for the depressions. This lesion is thought to be but not proven to be related to nonsteroidal anti-inflammatory drug use including aspirin. The necrotic debris that sloughs may be a source of nidal material that calculi may form upon later.



**PLATE 242: CHRONIC RENAL
PAPILLARY NECROSIS**

The three or four dark areas right at and just under the renal crest of this horse's kidney are areas of chronic parenchymal necrosis and sequestration of the necrotic debris. With time this necrotic debris may slough into the pelvis and form the nidus upon which calculi can form. This lesion is related to the use of nonsteroidal anti-inflammatory drugs.

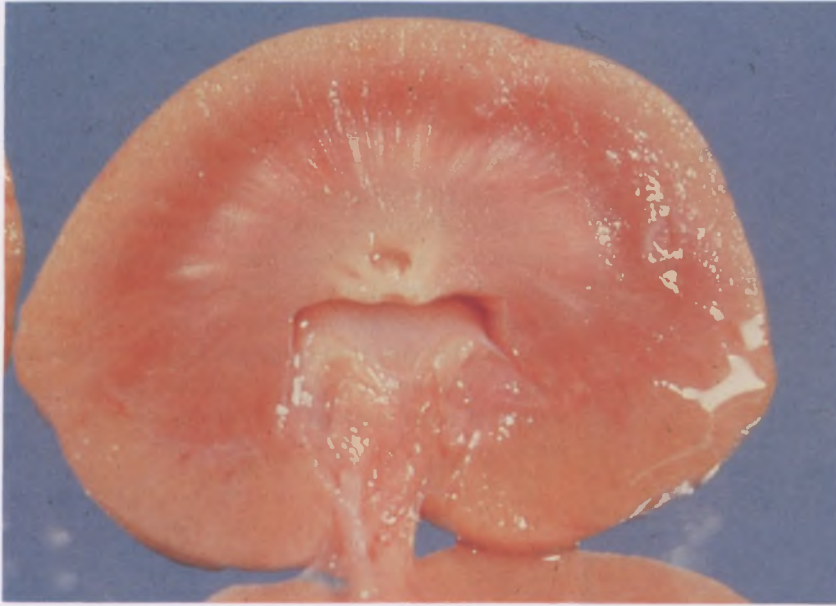

PLATE 243: CHRONIC RENAL PAPILLARY SCARRING

The cat kidney show a distinct depression on the surface of the renal crest with pale scar tissue just beneath it and then a cavity within this scar material. This is considered to be the end result of papillary necrosis from the effect of nonsteroidal anti-inflammatory drugs with aspirin being commonly involved. This is a common problem with humans in certain countries who consume extraordinary amounts of aspirin. A relationship to prostaglandin metabolism in this region of the kidney is to be noted.

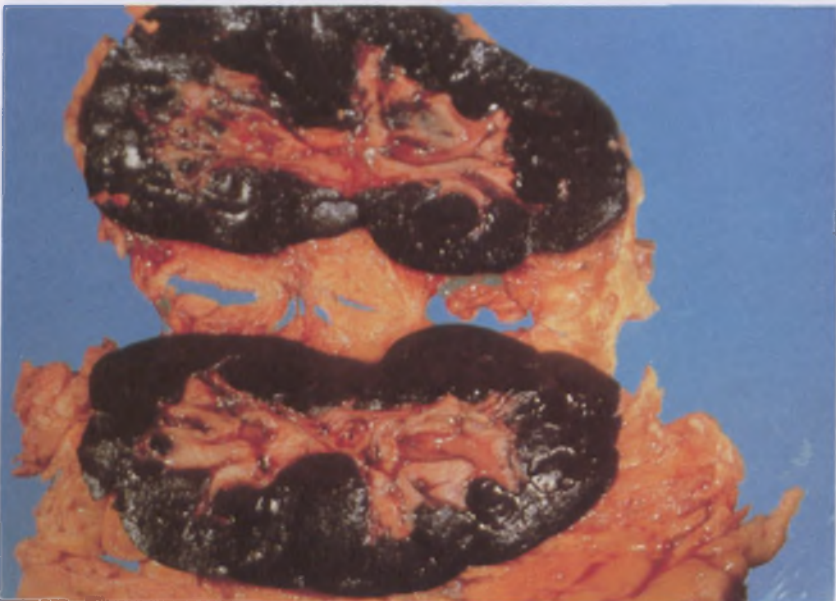
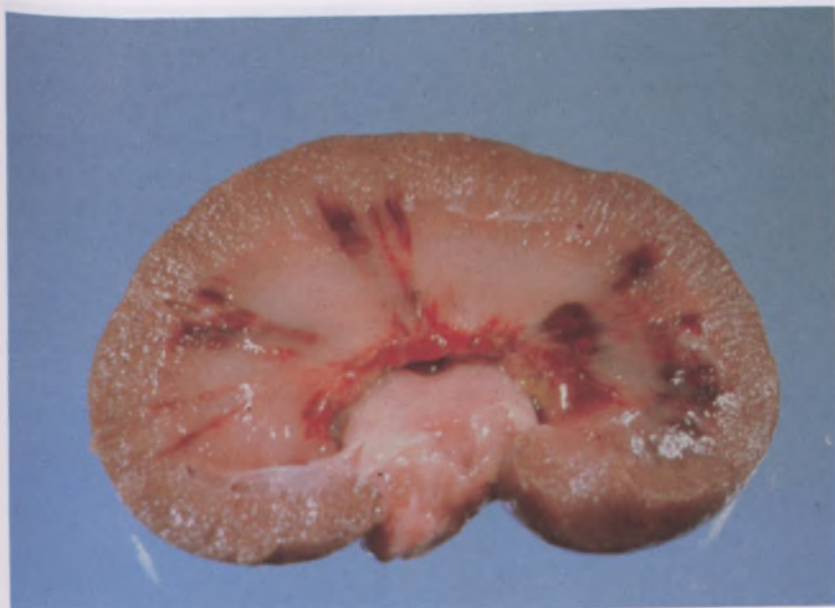
PLATE 244: HEMOGLOBINURIA

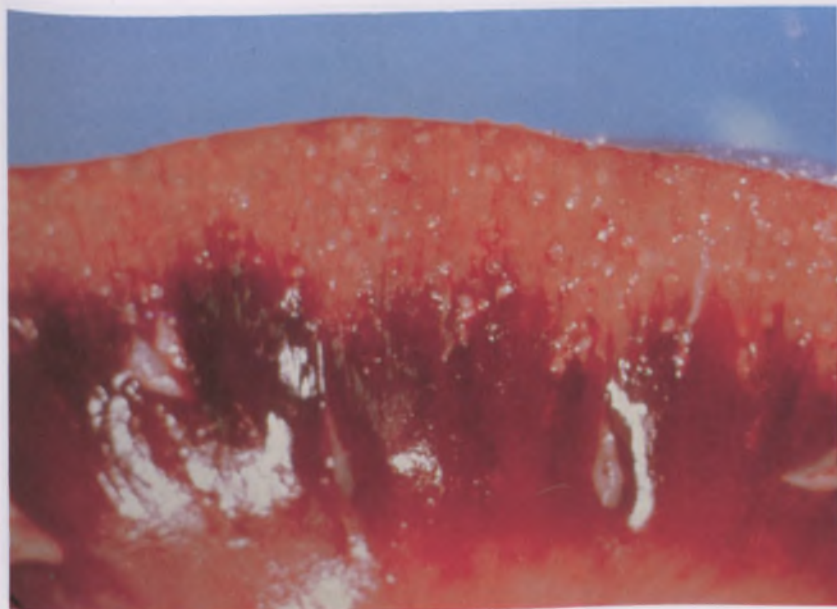This cow's kidney is darkly stained by hemoglobin as a result of hemolysis associated with *Clostridium hemolyticum* infection. The body tissues are also extremely icteric and the urine would be dark red to black. One or more liver infarcts would also be found in this animal which would not be the case if this were Postpartum Hemoglobinuria or from hemorrhage somewhere else in the body.



Dr. J. Crissman, Cornell, USA

**PLATE 245: ACUTE HEMORRHAGIC
PYELONEPHRITIS**

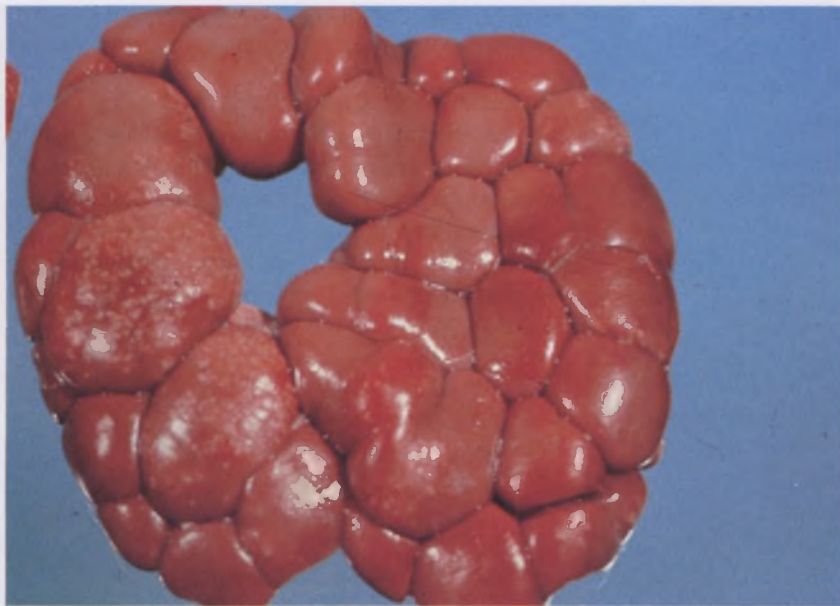The hemorrhagic areas radiating out from the pelvis and the irregular eroded renal crest of the medulla are evidence for an ascending infection from the pelvis and out into the parenchyma. This dog had a suppurative prostatitis which ascended to the kidney. One of several different agents could be causative and only a fresh culture would be definitive.



**PLATE 246: MULTIFOCAL RENAL
ABSCESES OF FOALS**

The multiple 1-3mm pale foci in this foal's kidney, some of which have an inflammatory red border are characteristic of "Sleeper Foals" or "Joint III". These are two of the several common names for the disease in foals caused by *Actinobacillus equuli*. The old name of the disease and the organism was "Shigellosis". This lesion takes a few days to develop so the foal may actually die with just joint infections, or even multifocal lung lesions before this lesion may be seen. This case is odd in that the foal was five months old.

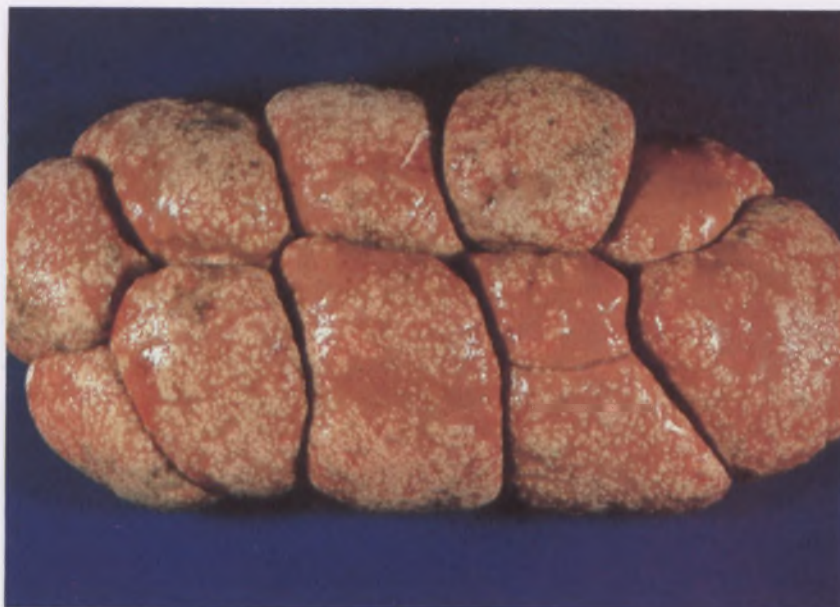Dr. R. Fancisk, Oklahoma, USA



**PLATE 247: ACUTE TO SUBACUTE
PYELONEPHRITIS**

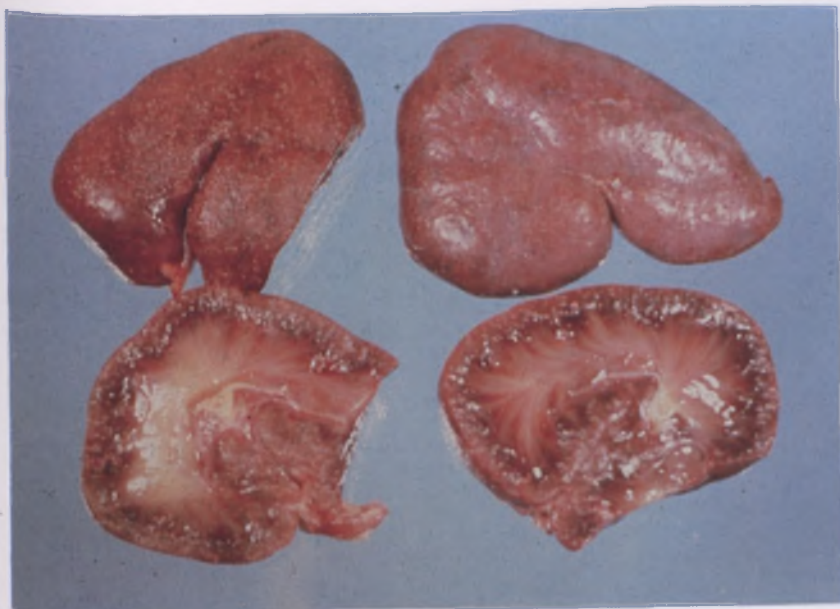
Only about one half of the lobes are affected with 1-3mm abscess foci and some of those that are affected are quite extensively showered with them. This suggests that these lesions have ascended the urinary tract to affect some calyces and associated renal parenchyma more than others. This calf had a well marked urachal infection which spread from an infected umbilicus. One of many different organisms could be causative with *E. coli* or *C. pyogenes* being commonly isolated agents in calves.

Dr. J. G. Green, Cornell, USA



**PLATE 248: SUBACUTE MULTIFOCAL
PYELONEPHRITIS**

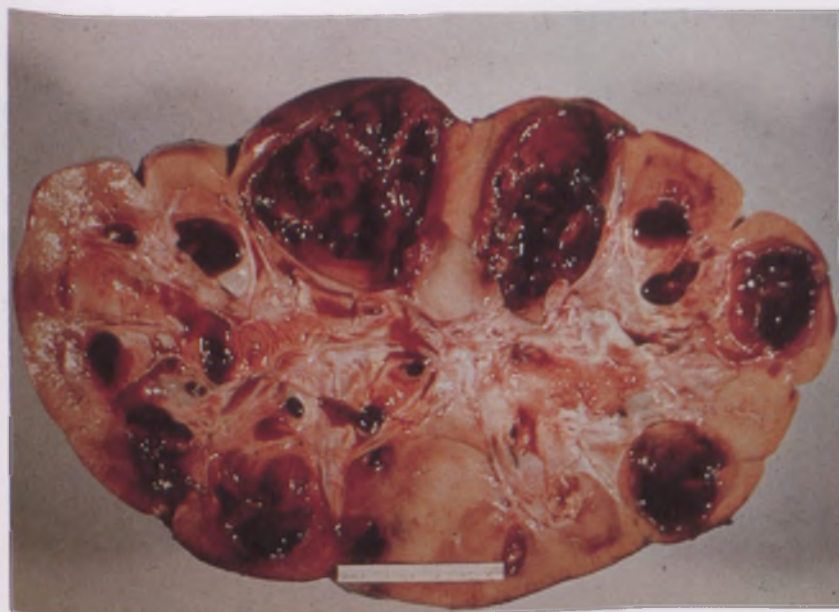The almost complete involvement of several lobes and less involvement of most and only minimal in one all suggest that this is an ascending infection from the lower urinary tract and not descending, that is from a hematogenous spread to the kidney. Any one of many organisms can be causative. This 5 year old cow died from purulent metritis. It is note-worthy but not rare to have no apparent infection in the bladder or ureters of such cases.



**PLATE 249: MULTIFOCAL RENAL
ABSCESSSES**

The many 2-3mm white yellow spots scattered primarily in the cortex are abscesses caused by *Actinobacillus equuli*. This disease in foals is called Joint Ill or Sleeper Foals. An older name for the disease which is still used quite commonly is "Shigellosis." The organisms often literally fill up the glomeruli histologically. This renal lesion may be found almost at birth in some affected foals suggesting prepartum infection.

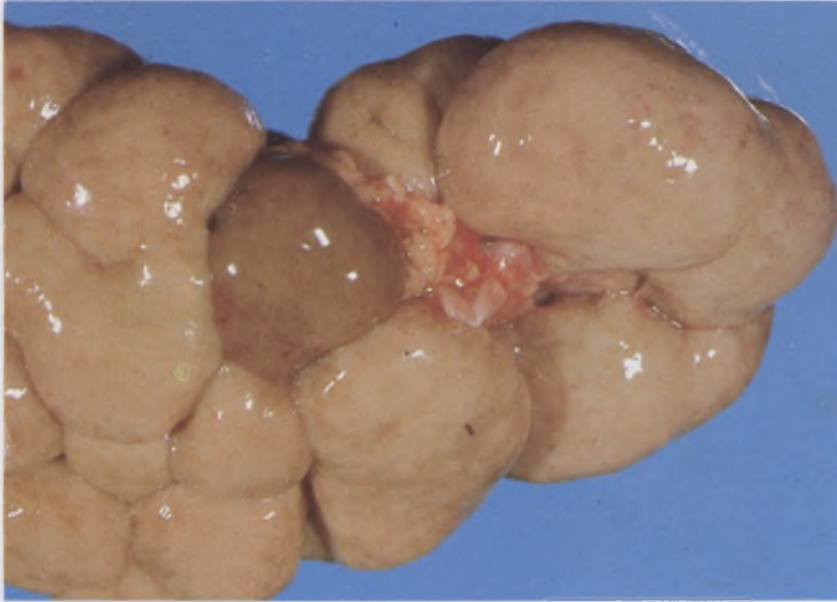
Dr. C. J. Eric, Texas, A&M



**PLATE 250: CHRONIC ACTIVE
PYELONEPHRITIS**

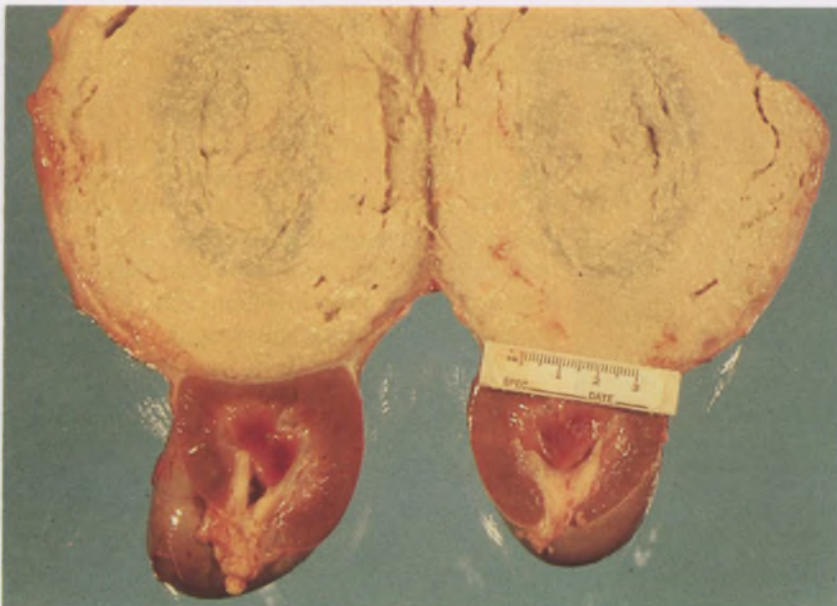
This shows the calyx of almost every lobe to be dilated and filled with necrotic debris in a mature cow. A classical uriniferous odor is usually noted in these cases. They are usually considered to be caused by an ascending infection of *Corynebacterium renale* but there are others who consider it a descending type infection; that it arrived at the kidney by hematogenous spread.

Dr. R. Panciera, Oklahoma, USA



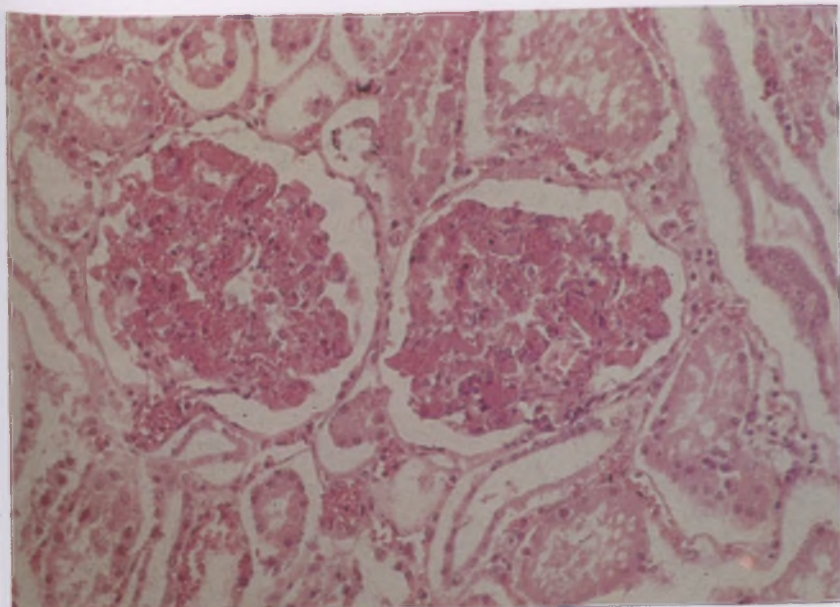
**PLATE 251: CHRONIC
PYELONEPHRITIS**

Most of the lobes of this calf are affected with chronic scarring and mononuclear cell infiltrates with the exception of the one lobe which appears almost normal. One can expect this distribution of lesions in ascending infections whereas descending infections from a hematogenous spread to the kidney would more likely involve each lobe and not leave one unaffected. Any one of many organisms could cause this in a young calf.



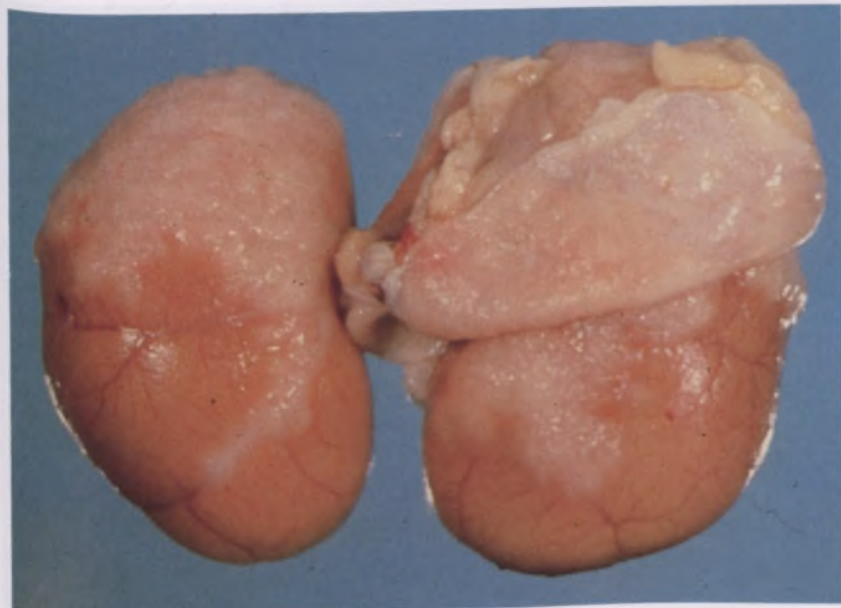**PLATE 252: CASEOUS
LYMPHADENITIS**

In the subcapsular region of this lamb's kidney is a typical concentrically laminated, dry, thin walled abscess caused by *Corynebacterium pseudotuberculosis* (*C. ovis*). These may be found in almost any node in a sheep, but especially in those draining skin affected by shearing wounds. They may be found in other nodes and some appear to be associated with nodular worm lesions.

**PLATE 253: GLOMERULAR THROMBI**

In each glomerus there are several, linear, hyaline thrombi scattered in the glomerular capillaries. These are considered by some to be quite characteristic for cases of Swine Erysipelas. They may represent a lesion of Disseminated Intravascular Coagulation but the blood parameters to make this diagnosis have not been measured in such cases.

Dr. C. I. Liu, Taiwan, ROC

**PLATE 254: RENAL CAPSULAR GRANULATION TISSUE OF FIP**

The renal capsule is pulled off part of the kidney and shows the marked granulation tissue associated with the vasculitis caused by the Feline Infectious Peritonitis virus. It covers a portion of one side of the cortex and projects characteristically in finger like fashion along the renal cortical vessels. These finger like projections along the vessels help differentiate this from some forms of Lymphosarcoma in the cat which will also grow out and form neoplastic adhesions to the capsule.

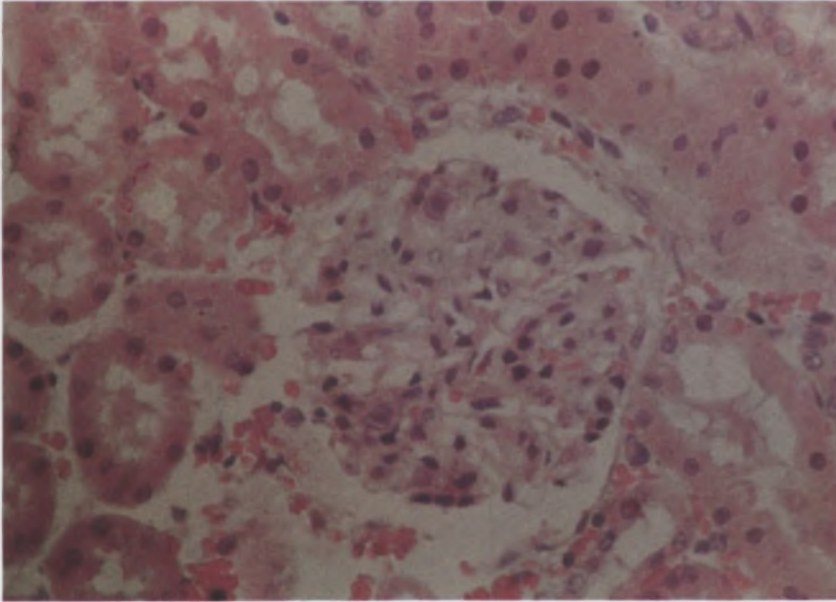


PLATE 255: GLOMERULAR INCLUSION BODIES OF ICH

This glomerulus in a dog shows three Inclusion Bodies of Infectious Canine Hepatitis (ICH) a viral disease with major lesions usually in the liver. These virus Inclusion Bodies are found in liver cord cells and in the nuclei of endothelial cells all over the body as in this glomerulus. In some cases of ICH one may only find them in this location, despite extensive search elsewhere.

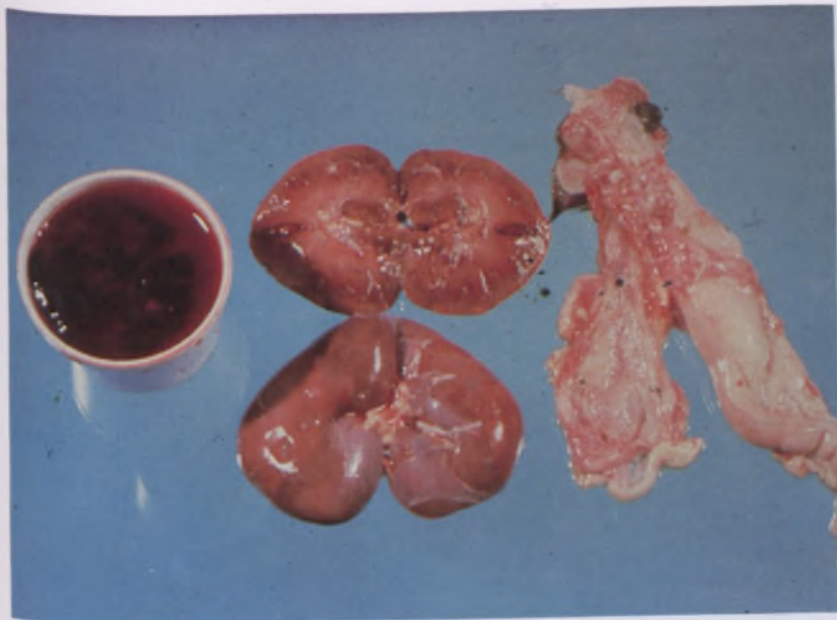
Dr. C. I. Liu, Taiwan, ROC

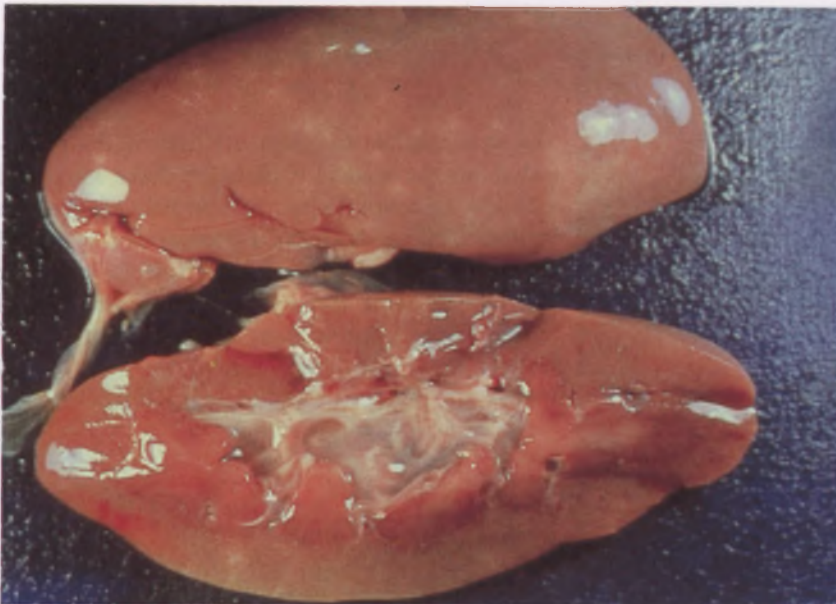

PLATE 256: MULTIFOCAL GRANULOMATOUS NEPHRITIS

The many pale foci scattered in this pig kidney are histologically multifocal granulomatous foci associated with *Toxoplasma gondii* organisms. This lesion is not as common as the diffuse pneumonia lesion in pigs with Toxoplasmosis. Other infectious agents either viral, protozoal, bacterial and even parasitic can make similar lesions.

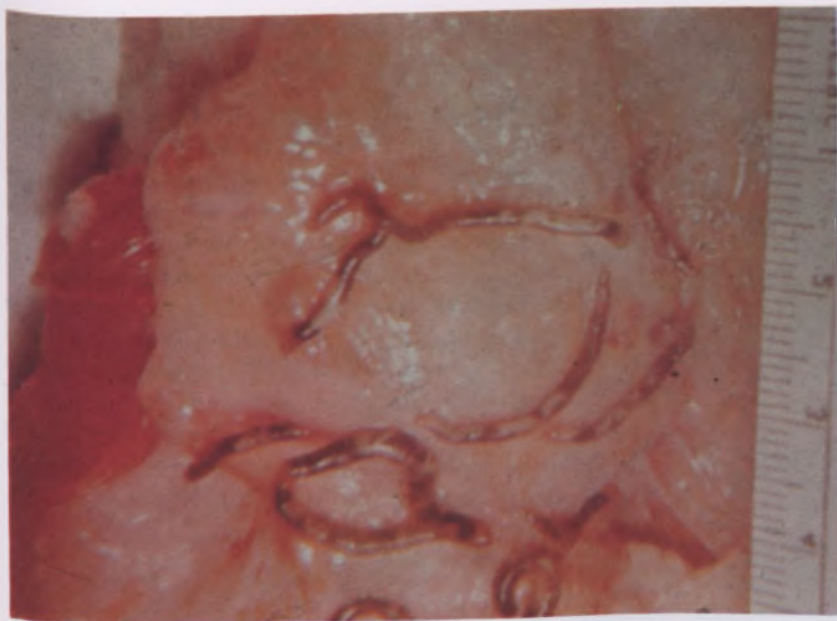Dr. T.H. Wang, Taiwan, ROC



Dr. J. Georgi, Cornell, USA

**PLATE 257: RENAL HEMORRHAGE
WITH HEMATURIA**

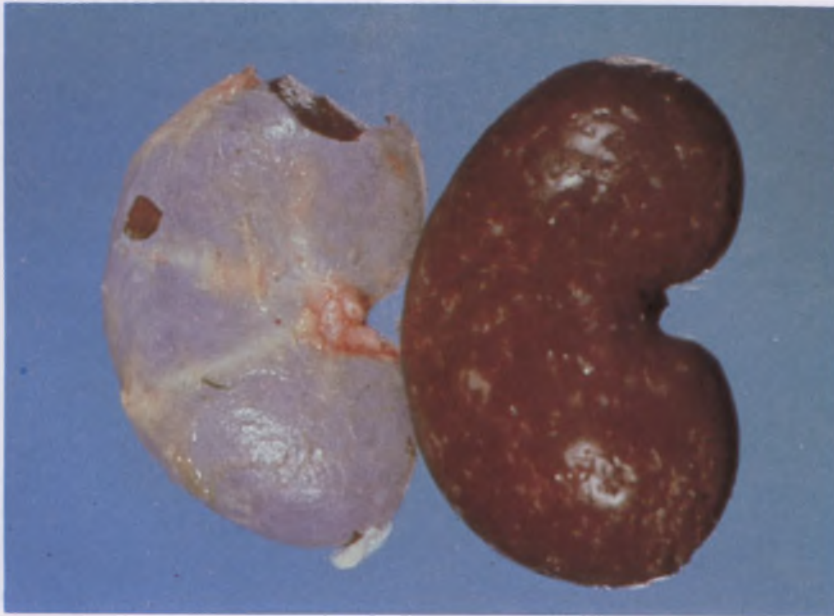
The cup of blood came from the foal's bladder. It had drained down the ureter from the hemorrhagic lesion in the kidney parenchyma caused by vascular damage from migrating *Strongylus vulgaris* larvae. This was the actual cause of death in the foal.



Dr. H. Olander, Purdue, USA

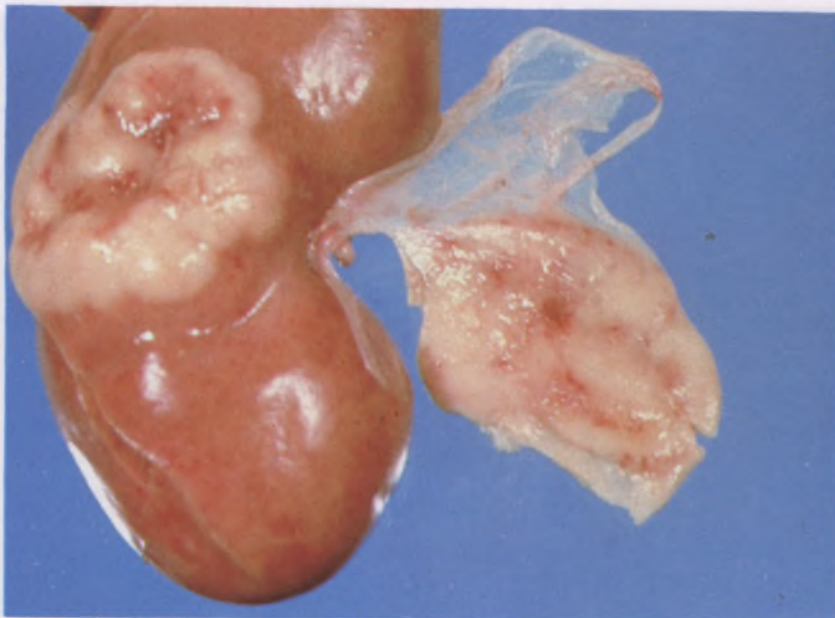PLATE 258: STEPHANURUS DENTATUS

These 2-3cm parasites are adherent to the renal pelvic mucosa although they may be found in many tissues. They do much damage to the liver as well. They pass eggs out through the ureter.



**PLATE 259: RENAL CORTICAL
PARASITE SCARS**

The kidney from one dog is shown; one half has its capsule still on and the other peeled off. The multiple grey spots of parasite migration tracts are best demonstrated by capsule removal. Ascarids are common culprits but others such as hookworms can also cause the lesion.



**PLATE 260: FOCAL RENAL
LYMPHOSARCOMA**

The capsule with attached tissue has been pulled from the dog's kidney revealing an underlying roughened, raised, umbilicated mass consisting histologically of neoplastic lymphocytes. The capsular adhesions of these tumors are not too frequent but do happen often enough in any species. In cats, the lesion may be that of Feline Infectious Peritonitis. Capsular adhesions in most renal disease is relatively rare. The appearance of the renal lesion grossly or microscopically in cases of Lymphosarcoma does not aid one in differentiating its place of origin. Only by histological examination can one be sure of the type of tumor present. They are rarely diagnostic grossly.

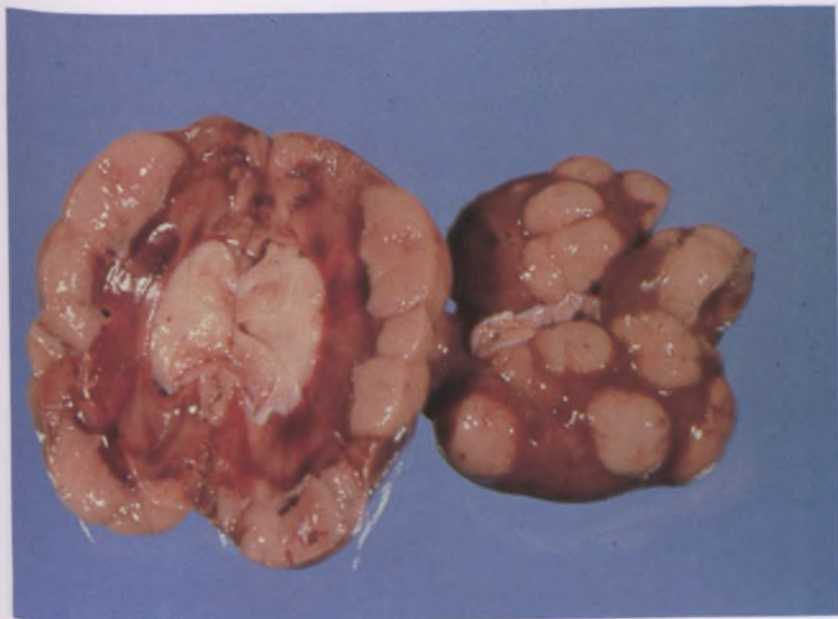


PLATE 261: MULTIFOCAL RENAL LYMPHOSARCOMA

These fleshy appearing masses in this dog's cortex primarily are nodules of neoplastic lymphocytes. Impression smears or histological sections are needed to be definitive.

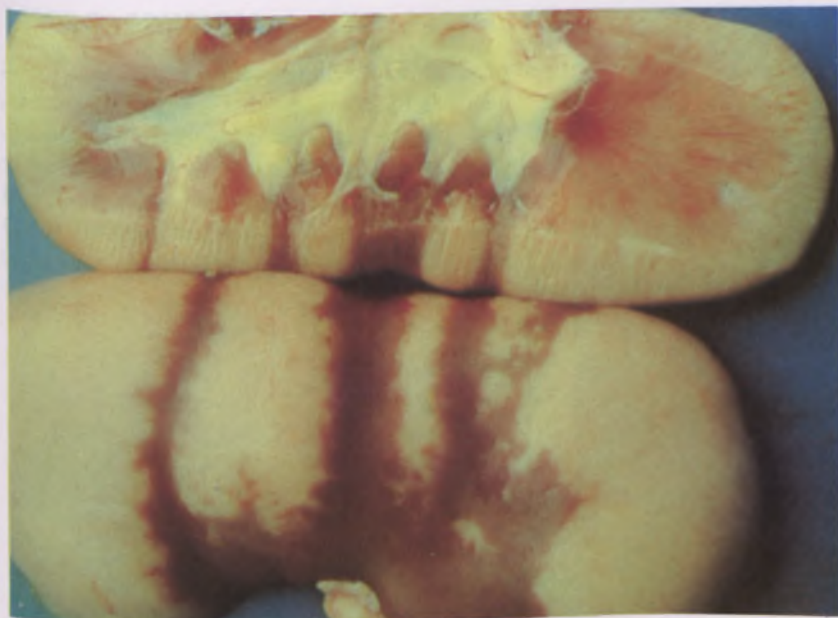


PLATE 262: RENAL LYMPHOSARCOMA

The brown red streaks in this kidney are the essentially normal areas while the swollen pale areas are diffusely infiltrated with neoplastic lymphocytes. The embryonal nephroma is by far the pig's most common renal tumor in general, but lymphosarcoma is probably second on the list.

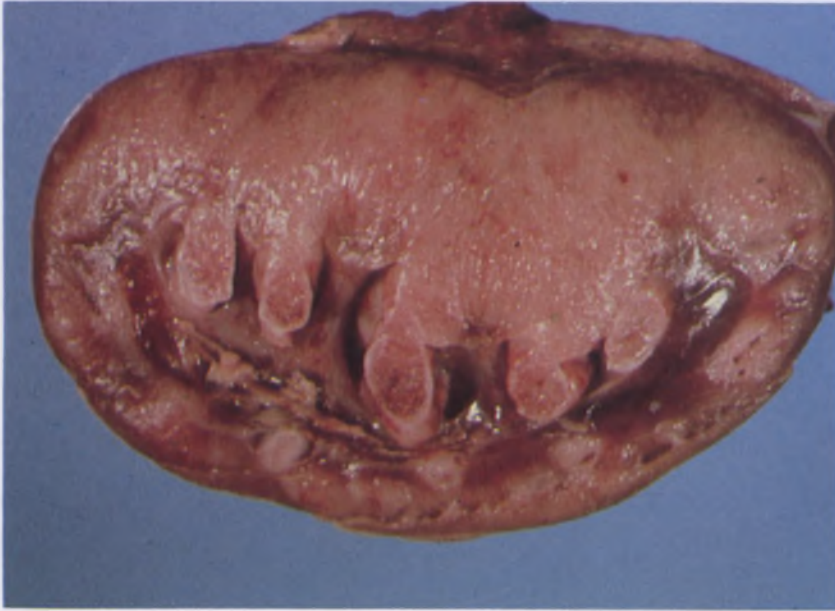

PLATE 263: RENAL LYMPHOSARCOMA

This dog's kidney was massively enlarged to 3-4 times normal with this neoplastic invasion of the parenchyma by lymphocytes. This is one of many ways this type tumor presents itself. The opposite kidney was normal.

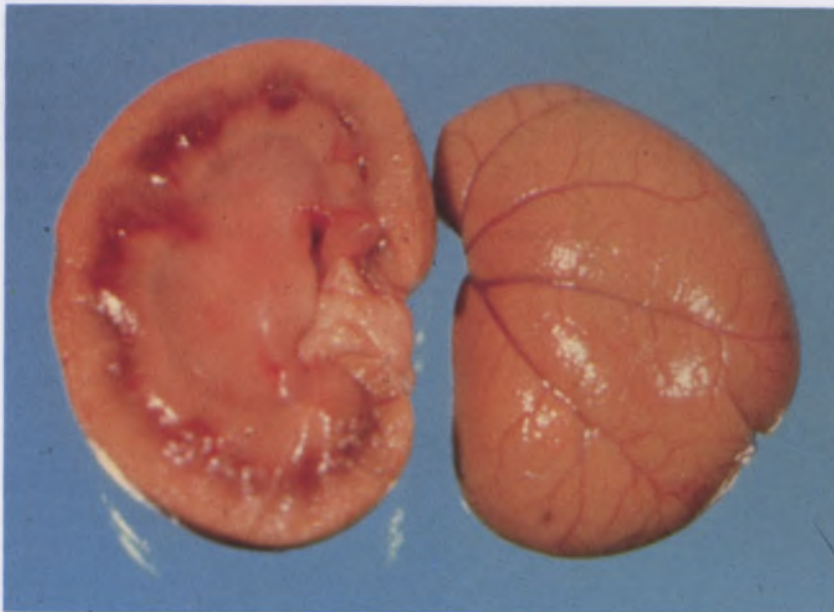

PLATE 264: RENAL LYMPHOSARCOMA

The pronounced swelling of this cat's renal medulla, as evidenced by the highlights on the cut surface, is all that suggests a lesion is present in the kidney. Grossly it was thought that the cat had Lower Nephron Nephrosis, as it was in renal failure, and the lesion was so localized, but histologically it was a marked invasion of the medulla by neoplastic lymphocytes.

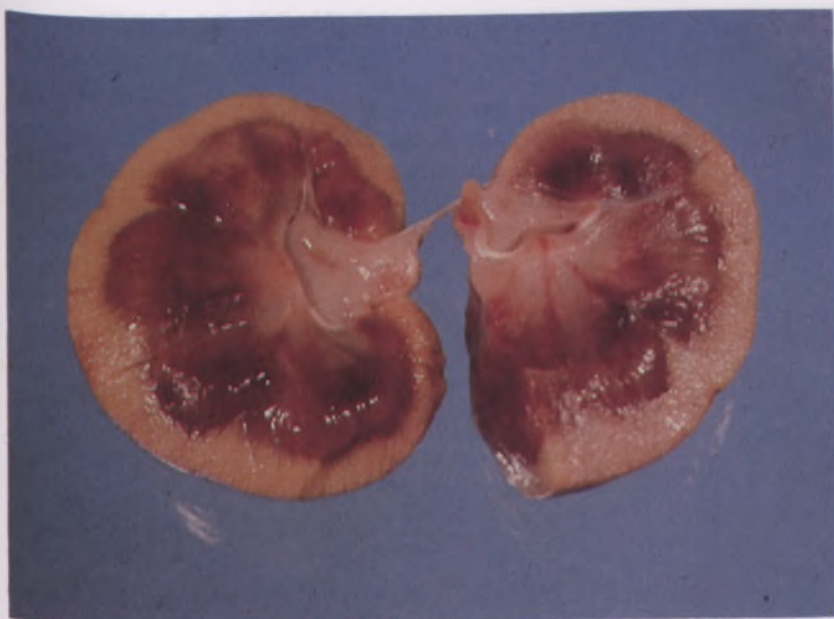


PLATE 265: RENAL MEDULLARY LYMPHOSARCOMA

The hemorrhagic elevations in this cat's medulla which are made more visible by the highlights, are massive infiltrations of the medulla by neoplastic lymphocytes. At first, the location of the lesion suggested to the pathologist that this could be Lower Nephron Nephrosis as no discrete masses were seen here or elsewhere in the body.

Dr. J. Rooney, Pennsylvania, USA

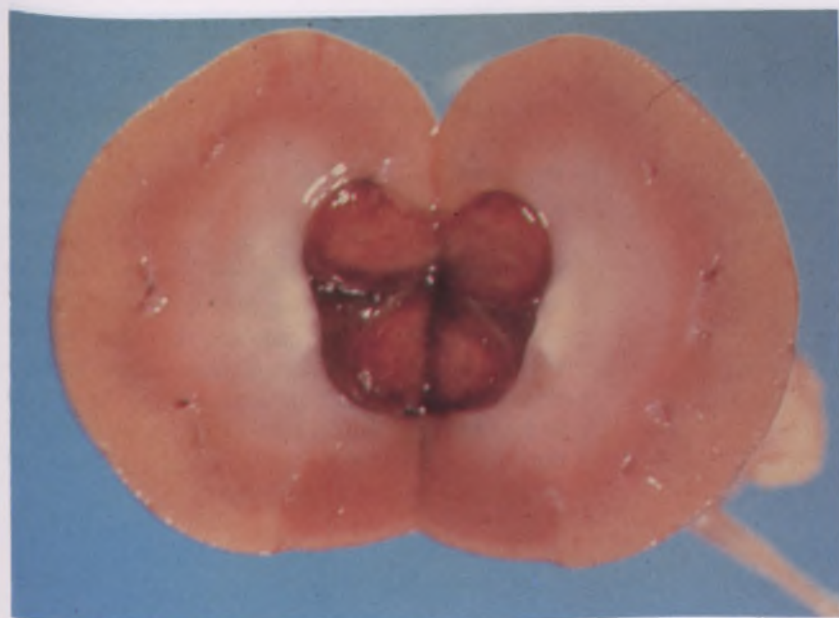


PLATE 266: MYELOPROLIFERATIVE DISEASE

The dark red tissue closely surrounding the renal pelvis and ureter of this cat is neoplastic myeloproliferative tissue. This is an odd location for this tissue which is usually recognized for its splenic and liver involvement.

Dr. R. M. Lewis, Cornell, USA

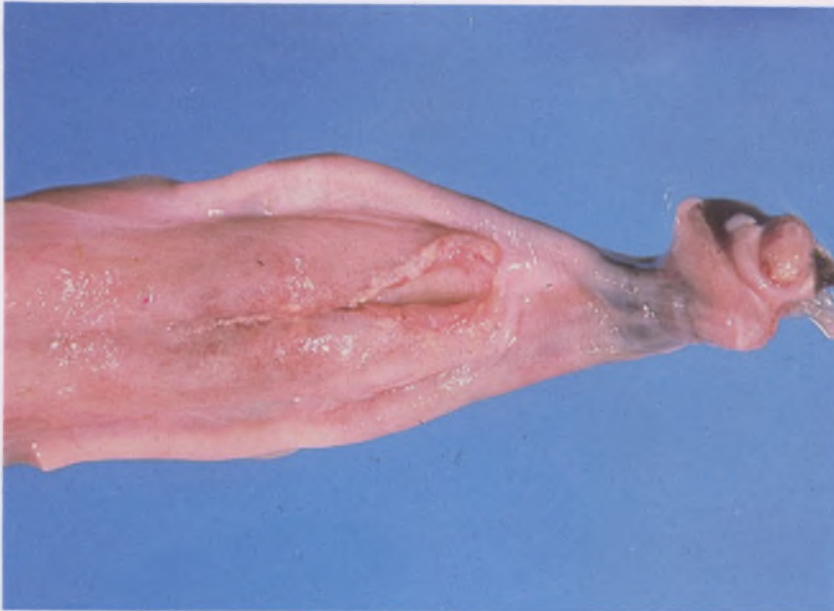


PLATE 267: URINARY BLADDER RUPTURE

The free end stump in this picture is the cut off umbilicus at the cranial end of this foal's bladder. It has a dark zone at its base which is pseudomelanosis. The two rounded edges of this bladder are the remnants of the umbilical arteries which will make up the round ligaments of the bladder. Between these two rounded edges the urinary bladder itself has ruptured with a little hemorrhage and fibrin still attached to the serosa. It is the opinion of some that this may be related to a malformation in the smooth muscle in the bladder wall. This occurs more often in foals than other species.

Dr. J. Rooney, Pennsylvania, USA

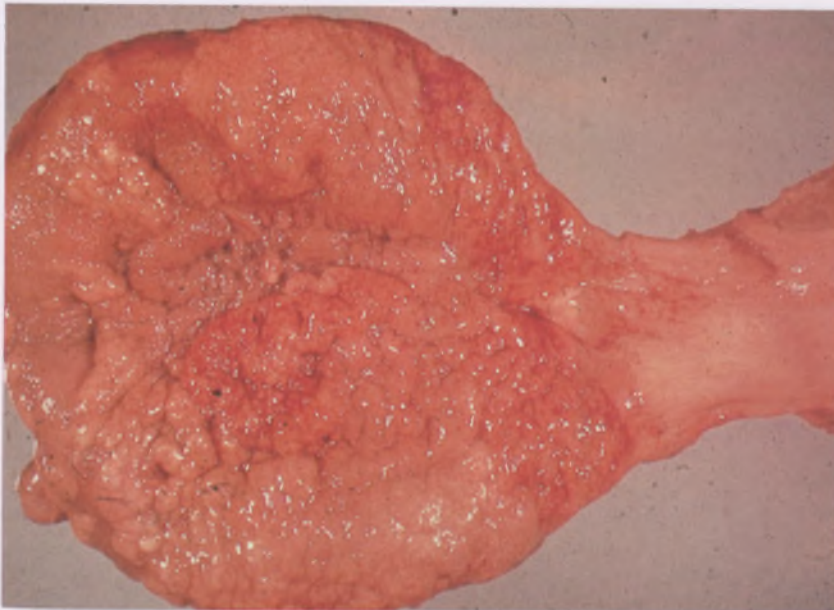
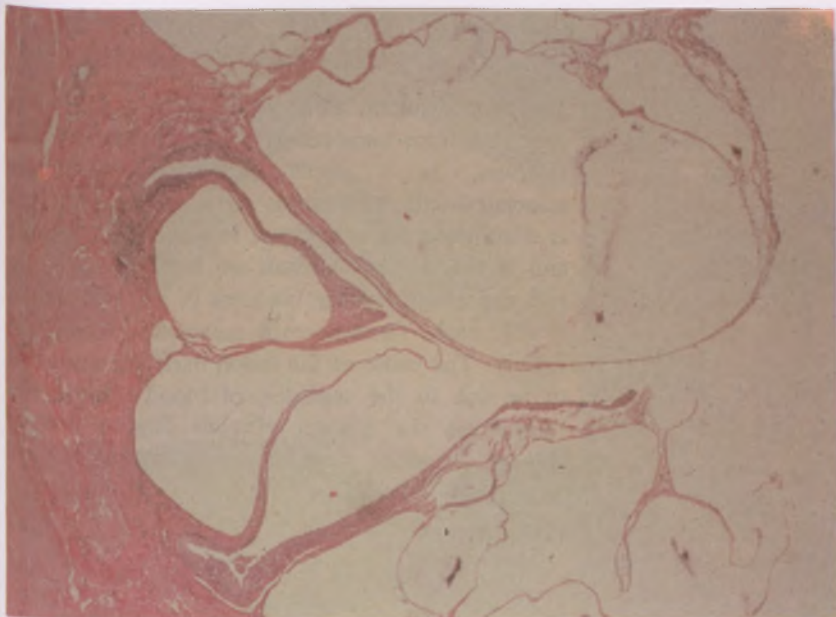


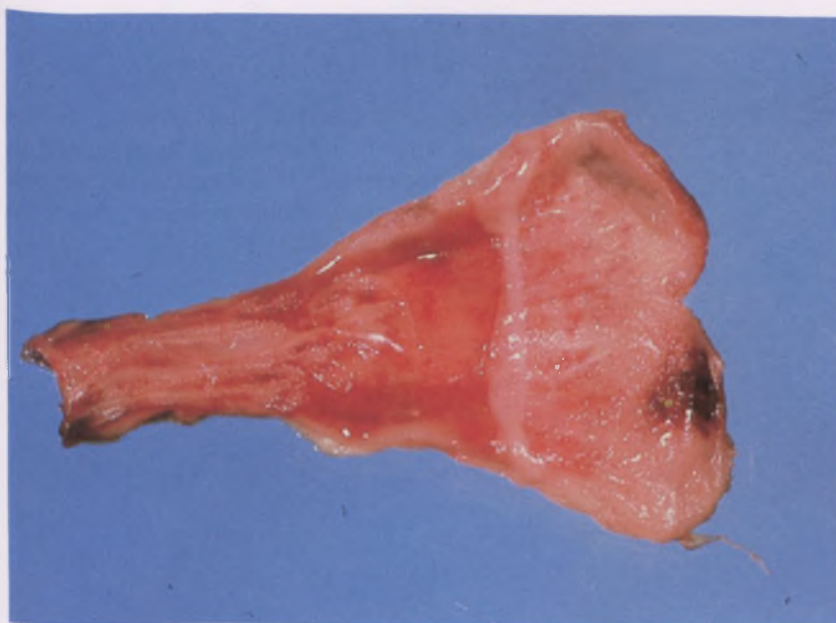
PLATE 268: URINARY BLADDER EMPHYSEMA

The cow's bladder shown here has almost its total surface elevated by gas bubbles called Cystic Emphysematosa or Emphysema of the Bladder. It was caused by the use of intravenous glucose therapy for milk fever; in this case the sugar that was put out in the urine was absorbed by the mucosa and broken down in the bladder wall by tissue enzymes. This can also be seen in the abomasum of calves given high sugar content electrolytes by mouth or intravenously. It is seen in dogs and man with Diabetes Mellitus probably for the same reason, although most of the literature says its due to cystitis.



**PLATE 269: URINARY BLADDER
EMPHYSEMA**

The large clear spaces in the mucosa and submucosa of this dog's bladder are gas bubbles associated with Urinary Bladder Emphysema. This is caused by the absorption and enzymatic breakdown of glucose in the wall, as the result of Diabetes Mellitus. It can also be seen in cattle within hours of being given glucose intravenously. The few inflammatory cells, also present in this case, have been the reason that many believed the gas bubbles were secondary to a cystitis.



**PLATE 270: TRAUMATIC MUCOSAL
TEARING**

This dog had been hit by a car, apparently when its bladder was full as the mucosa has been torn off in a relatively straight line near the trigone and pulled toward the fundus. The fundus also has a dark red area where a perforation of the bladder occurred. The underlying submucosa is markedly congested where the mucosa pulled off.

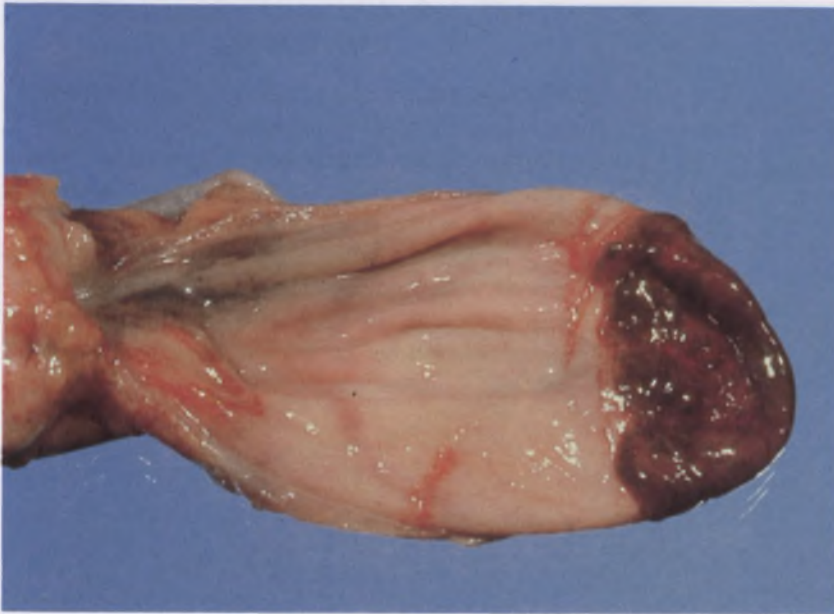

PLATE 271: FUNDIC NECROSIS OF THE BLADDER

The fundic region alone of this dog's bladder is dark red from hemorrhage and necrosis, Pressure Necrosis, as a result of urinary retention associated with a traumatic vertebral fracture. This is a common enough sequel to vertebral fractures and is the reason clinicians are wary of palpating and expressing urinary bladders in animals with a broken back. These necrotic areas often mineralize rapidly. The cause of the lesion itself is considered to be due to the cessation of blood flow to the fundus, as the bladder distends due to loss of normal excretory function owing to spinal cord damage.

Dr. J. Romney, Pennsylvania, U.S.A.

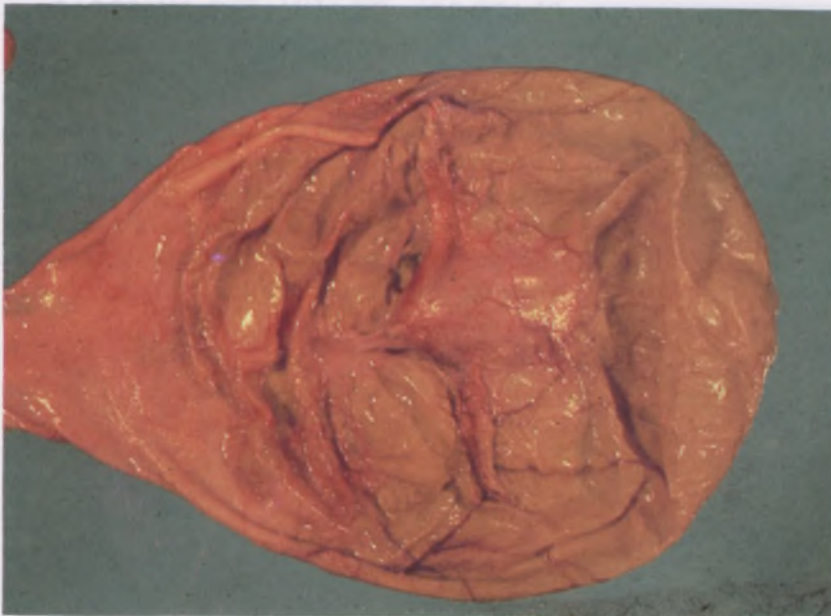
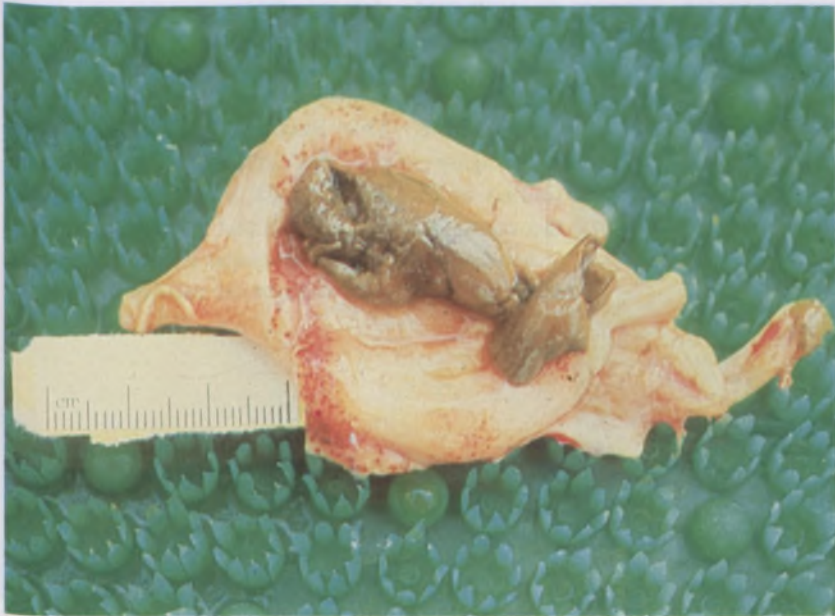
PLATE 272: PRESSURE NECROSIS WITH MINERALIZATION

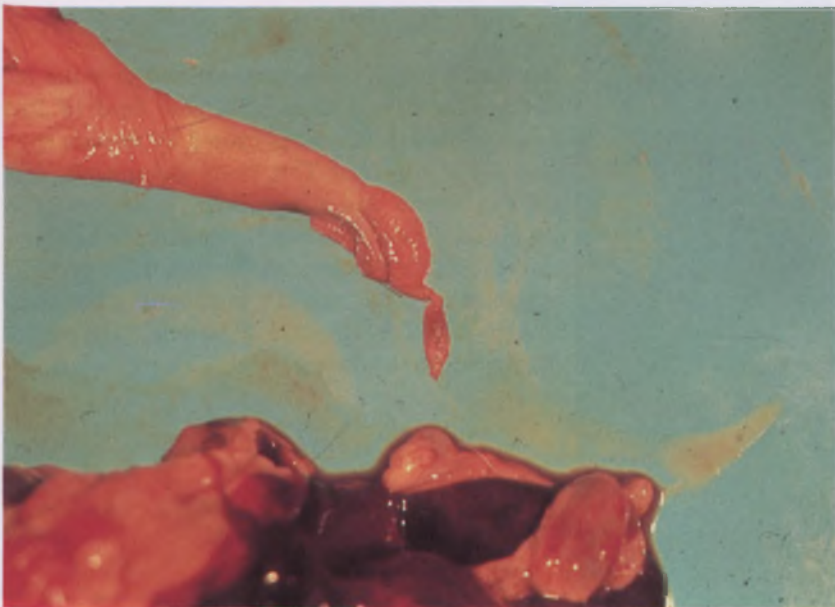The major portion of this bladder especially the fundus is yellow and has a crinkled appearance. This is Pressure Necrosis with Mineralization as the result of this foal having a fractured lumbar vertebra from a vitamin/mineral imbalance.



**PLATE 273: URINARY BLADDER
BLOOD CLOTS**

The large green friable masses in the urinary bladder of this pig are blood clots partially acted upon by urine. The blood clots are the result of renal parenchymal hemorrhage caused by a Vitamin K deficiency brought about by prolonged storage of feed that had Vitamin K added to it. The problem was solved by the addition of Vitamin K to the diet. Excluding trauma, hemorrhages into or around the kidney are one of the first places that they are found in many of the bleeding diseases.

Dr. C. F. Fox, Fairport, N.Y.



**PLATE 274: PROCESSUS URETHRA
CALCULUS**

The distinct oval mass in the tip of this goat's processus urethra is a Urinary Calculus which it caused the animal death by obstruction with subsequent urinary bladder rupture. Sometimes only a fibrin clump can be the obstructing material. It is surprising that there is not enough pressure in the bladder and related structures to force urine past this obstruction, or cause a life saving rupture in this location.

Dr. E. Tigo, Mexico



**PLATE 275: URINARY BLADDER
CALCULUS**

Calculi can be of many sizes and shapes and most are multiple. This Bladder Calculus in a horse is roughly 8x12 cm and was an incidental finding in the horse. There is a great variation in the composition of Calculi and a chemical analysis is usually indicated. The cause is not so easy to ascertain and dietary changes are usually in order.

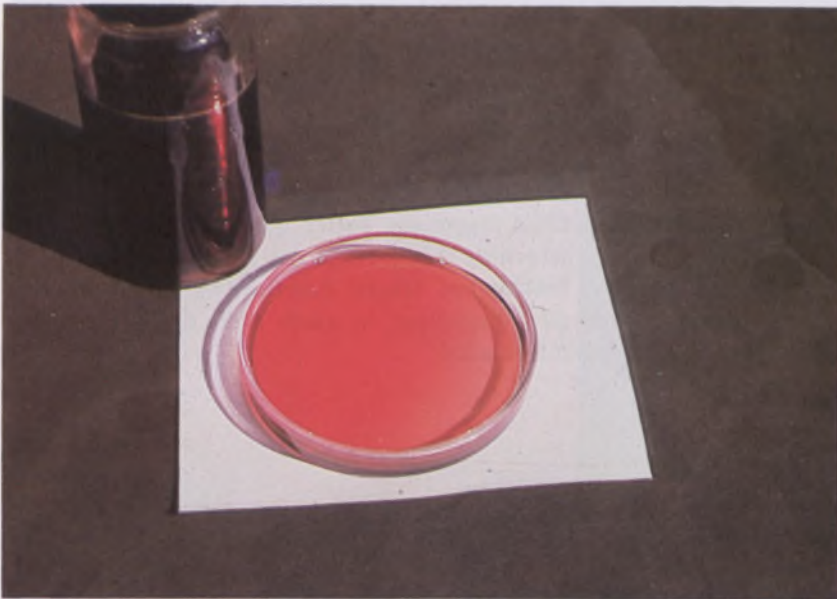
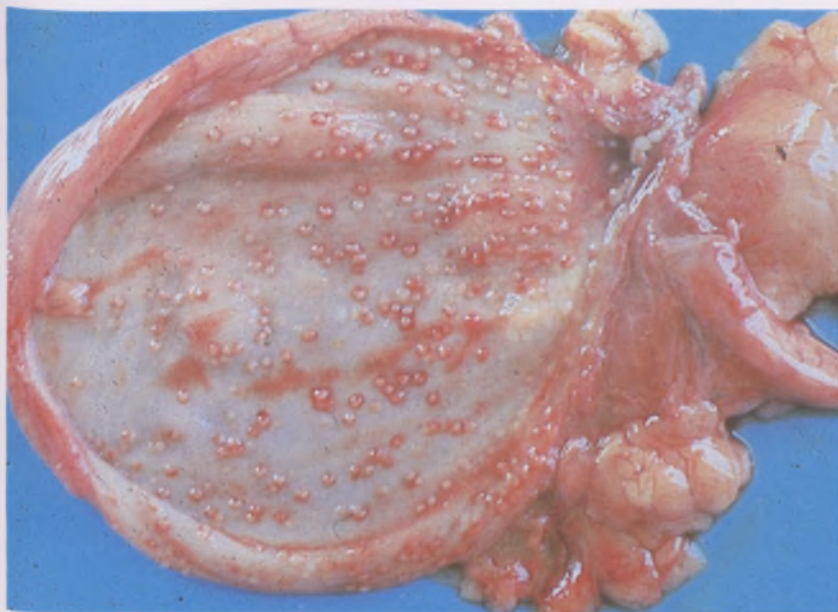


PLATE 276: RED WATER

The Red Water in the jar and petrie dish is the red hemoglobin stained urine of a cow dead of Red Water or Bovine Babesiosis caused by *Babesia* spp., probably *B. bigemina*. This, along with anemia, dark kidneys, icterus and a large pulpy spleen are quite diagnostic. Blood smears are necessary. In one large outbreak studied in Mexico, we found the problem was caused by the animal's premunity stage being broken down by massive antibiotic therapy for another suspected disease.

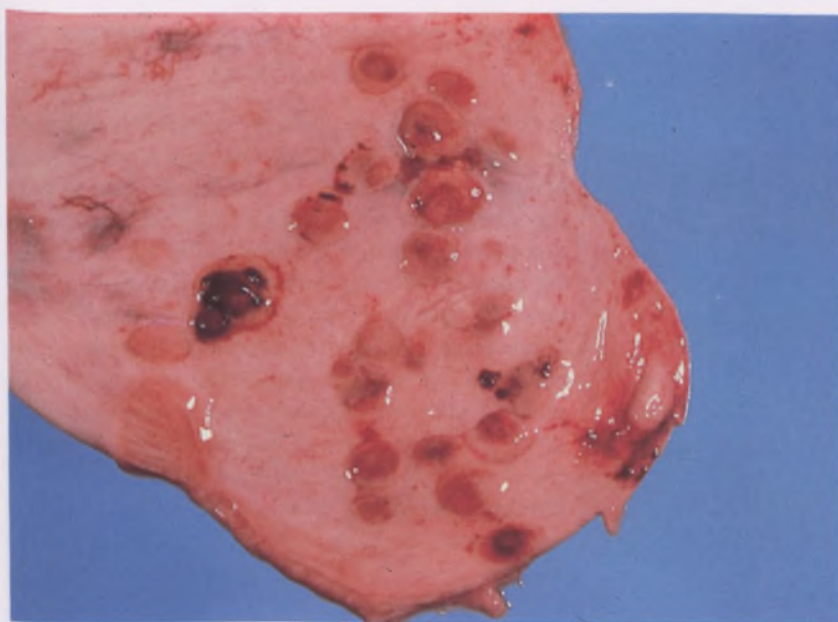
Dr. E. Trigo, Mexico



**PLATE 277: CHRONIC LYMPHOID
CYSTITIS**

The large number of relatively uniform granules in the mucosa of this dog's bladder are lymphoid follicles and the condition is called Chronic Lymphoid Cystitis. Its cause is unknown and most cases are only incidental findings at the necropsy table. They probably represent a sequel to a chronic infectious cystitis.

Dr. C. I. Liu, Taiwan, ROC



**PLATE 278: URINARY BLADDER
(LYMPHOSARCOMA)
NEOPLASIA**

The multiple plaques in this mature cow's urinary bladder mucosa are masses of Lymphosarcoma. The cow had typical lymphoid tumor masses elsewhere. Lymphosarcomas may be seen in this location but they are usually pale, flesh colored and not hemorrhagic as these are. Bracken Fern Poisoning, out of context, could also be considered here.

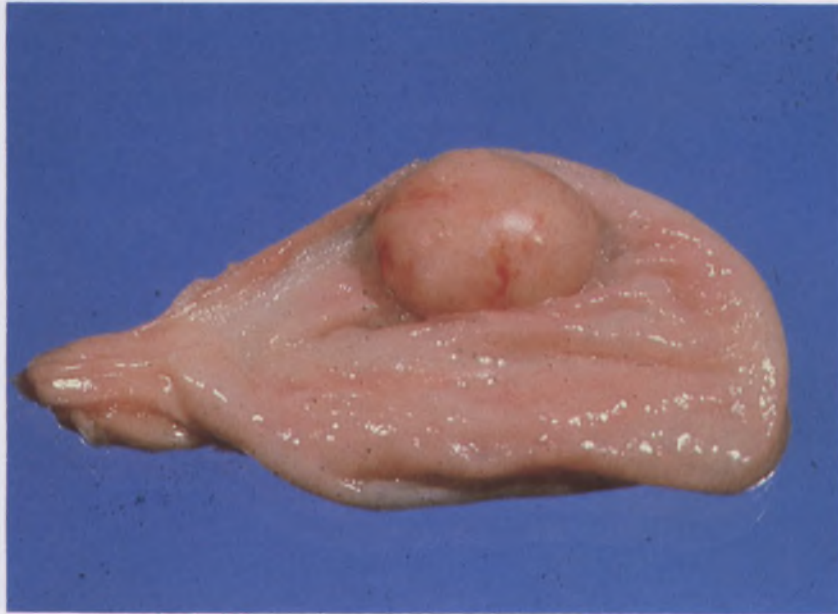

PLATE 279: SOLITARY MAST CELL TUMOR

The single round mass in the submucosa of this cat's urinary bladder is a Solitary Mast Cell Tumor. The skin form of Mast Cell Tumors are often multiple in cats but when in the internal organs, especially intestine, it is often solitary at least for the primary site. It may also only affect the spleen or even a single lymph node. Even histologically it is not always easy to be positive of the diagnosis and smear preparations may be quite helpful.

Dr. C. A. Linn, Taiwan, ROC

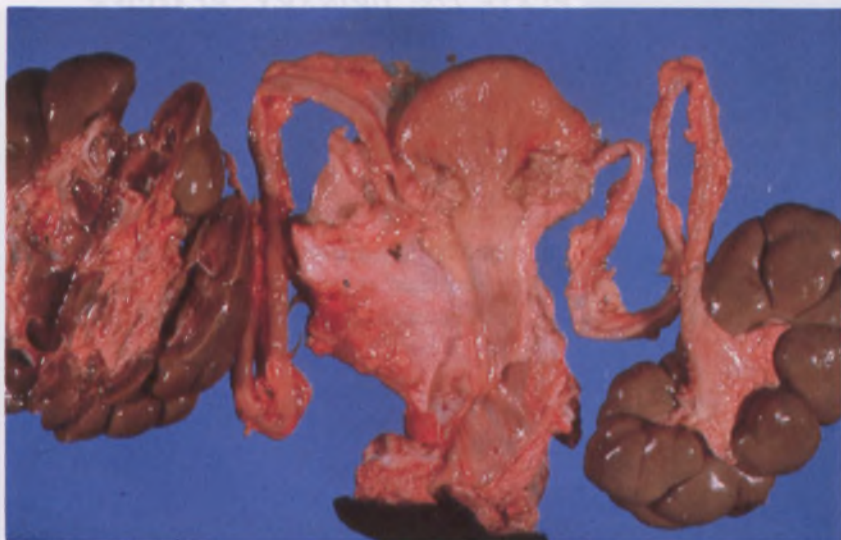
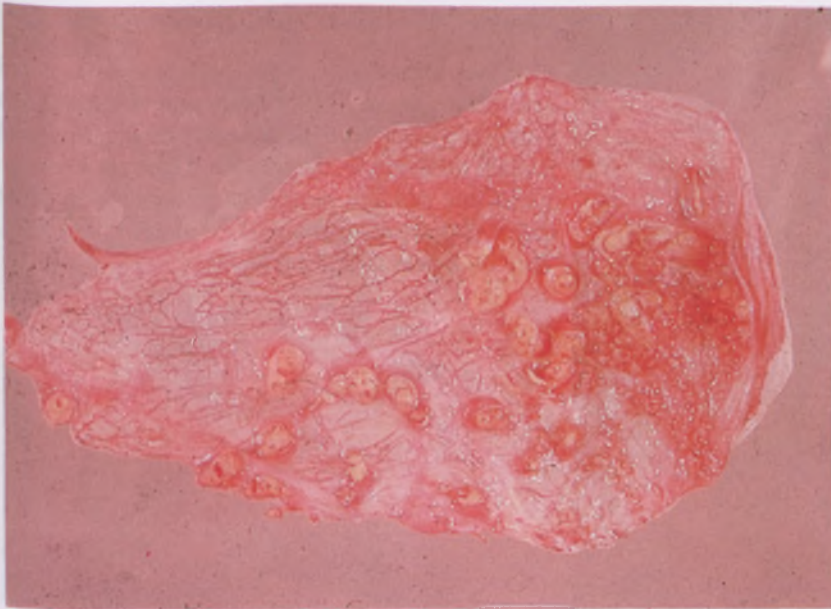


PLATE 280: BILATERAL URINARY PAPILOMAS

Both kidneys of this adult cow are slightly enlarged, and dilated calyces can be noted on the one which is opened. Both ureters are moderately dilated with the one going to the unopened kidney having several small dilated saccules along its length. At the entrance of each ureter to the bladder is a small nest of papillary projections, Fibropapillomas. These caused the Hydroureters and Hydronephrosis but what caused the papillomas is unknown. In other locations it is known that a virus can cause them. Bracken Fern, the cause of Enzootic Hematuria can cause multiple tumor masses of various types in the urinary bladder, but they are usually not in such a specific location in the bladder.

Dr. E. Trigo, Mexico



**PLATE 281: HYPERKERATOTIC
PLACENTAL PLAQUES**

The multiple, slightly coiled yellow, dimpled nodules on the placenta from a sheep are the commonly found Hyperkeratotic Plaques seen in sheep, cattle and other animals. They are almost considered common enough to be "normal". The neophyte however tends to give them undue significance. Histologically, they are just islands of stratified squamous epithelial cells producing large amounts of keratin.

Dr. S. J. Robert, Vermont, USA

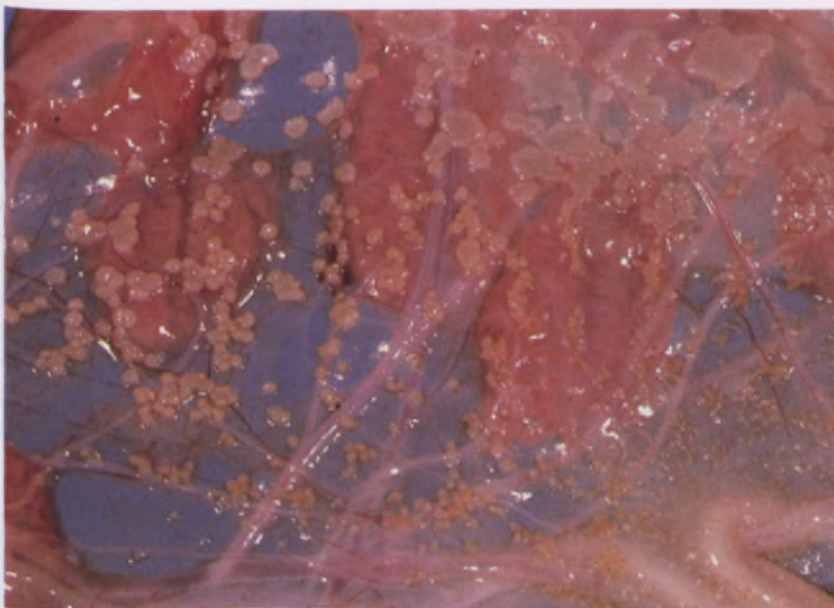


PLATE 282: EPITHELIAL PLAQUES

This cow's amnion has many pale white to slightly yellow plaques on its surface. These are Epithelial Plaques which are commonly seen on the placental tissues of cattle, sheep and other animals. They are not significant except for those who misinterpret them. The slightly yellow color of some is probably slight hyperkeratosis of these Stratified Squamous Epithelial plaques.

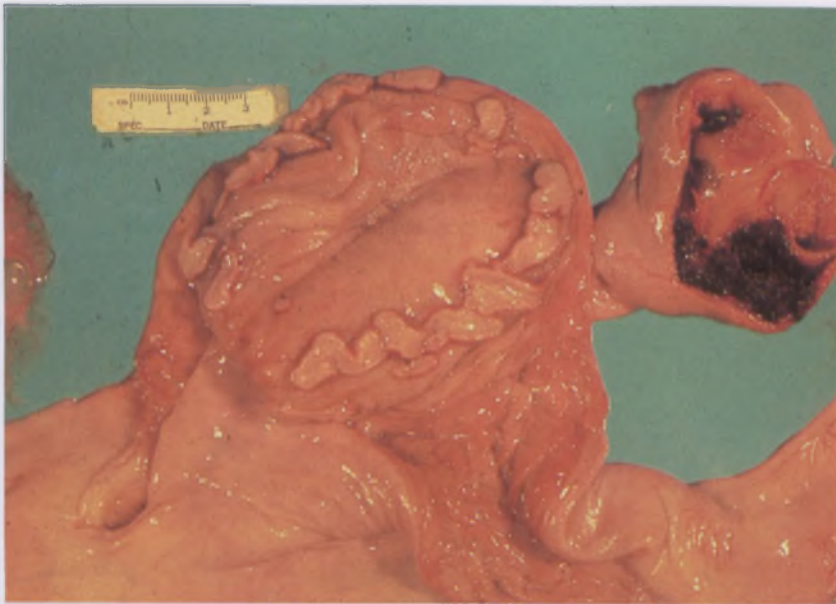


PLATE 283: ENDOMETRIAL CUPS

The two organs shown cut open are a large but essentially normal bloody ovary and the uterus of a 3 year old mare. Note the ring of pale slightly raised plaques attached to the mucosa. These are Endometrial Cups and are normal structures in the horse uterus that appear at about 45-60 days of pregnancy. They disappear at 150 days or so.

Dr. J. Robert Vennart, DVM

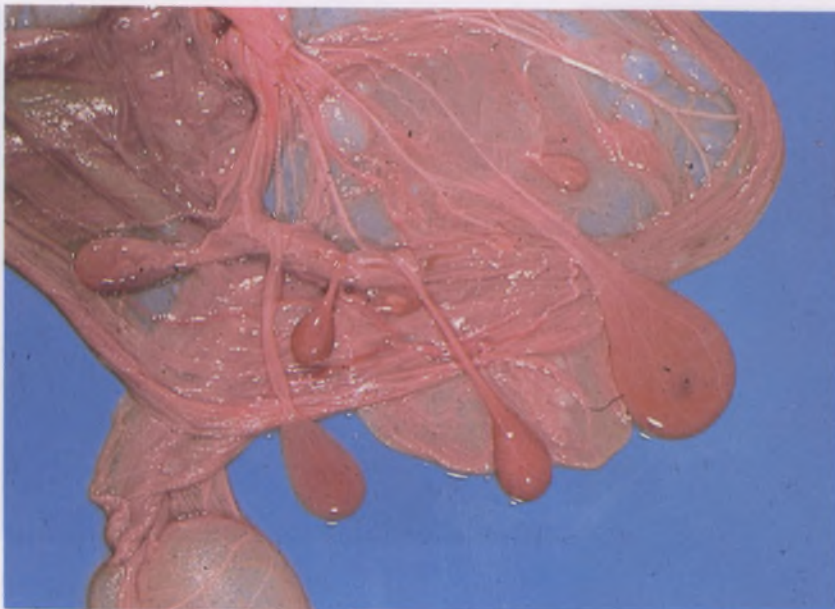


PLATE 284: ENDOMETRIAL GLAND CYSTS

These elongated pedunculated sacs, on the allantois of this horse's placenta, are thought to have their proximal portions located over the endometrial cup areas of the uterus proper. When the cups regress normally, they leave a small surface without placental villae in which some fluid, uterine milk, accumulates. By gravity this material helps form these pedunculated sacs called Endometrial Gland Sacs. It is also suggested that the material in these cysts may inspissate and break out of the cysts, if the cysts twist off, to become a Hippomane. This is not a widely accepted theory.

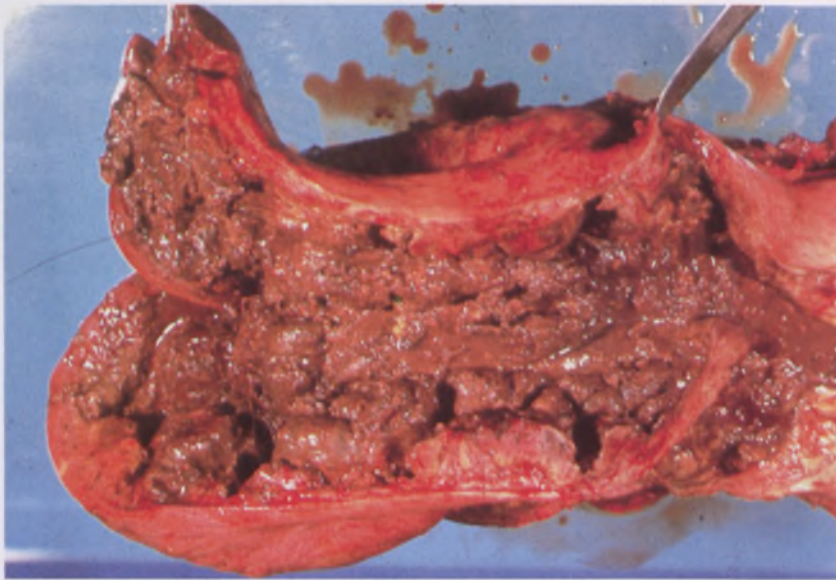


PLATE 287: ACUTE SEPTIC METRITIS

The dark, extremely foul smelling, necrotic appearing mucosa of this cow's uterus can almost be considered to be gangrenous in this severe case of Septic Metritis. The gas produced in the tissues was suspected of being caused by *Clostridium* spp. although no growth was obtained on culture. It is thought that the calf's foot penetrated the myometrium and the entire area became contaminated at parturition.

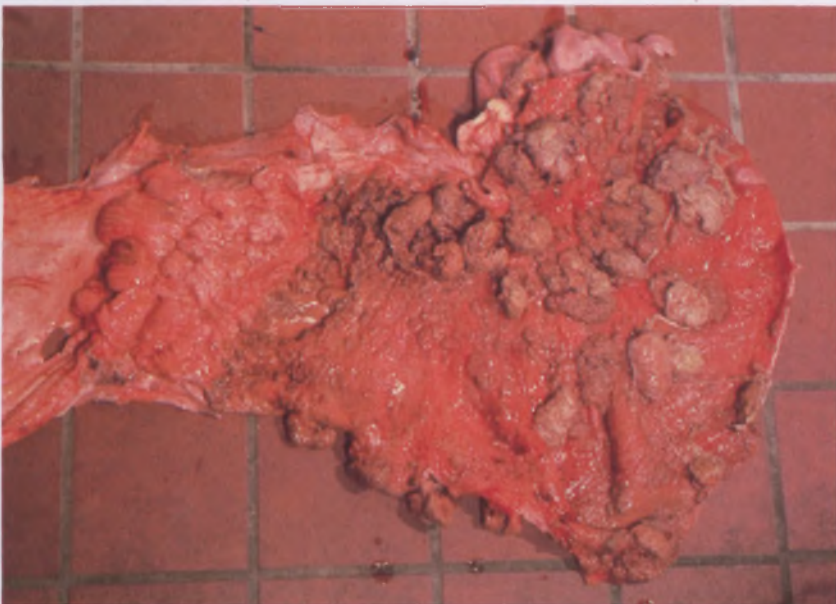

PLATE 288: CHRONIC SUPPURATIVE BACTERIAL (*BACILLUS CEREUS*) ENDOMETRITIS

This is an opened uterus from a cow showing a well marked Chronic Endometritis, as evidenced by the shreds of retained placenta, congestion, and roughened, coarsely granular mucosa. Although not considered an important pathogen, *Bacillus cereus* is well known to cause this type of lesion as it did in this case.

Dr. D. Cordes, New Zealand

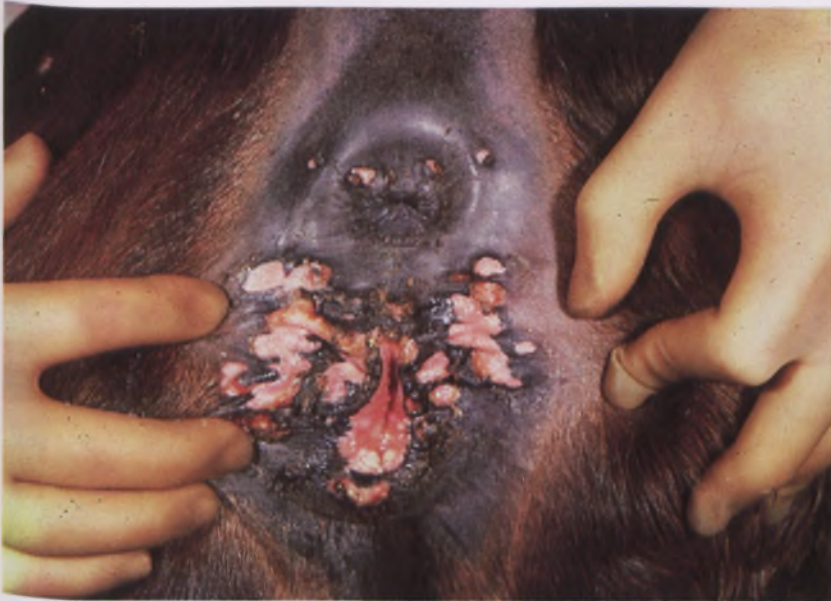

PLATE 289: COITAL EXANTHEMA OF HORSES

The typical ulcers and scabs around the vulva and anus of this pony are the typical lesions of Coital Exanthema caused by a virus. It also affects the penis and prepuce of the male.

Dr. F. Spangenberg, Virginia, USA

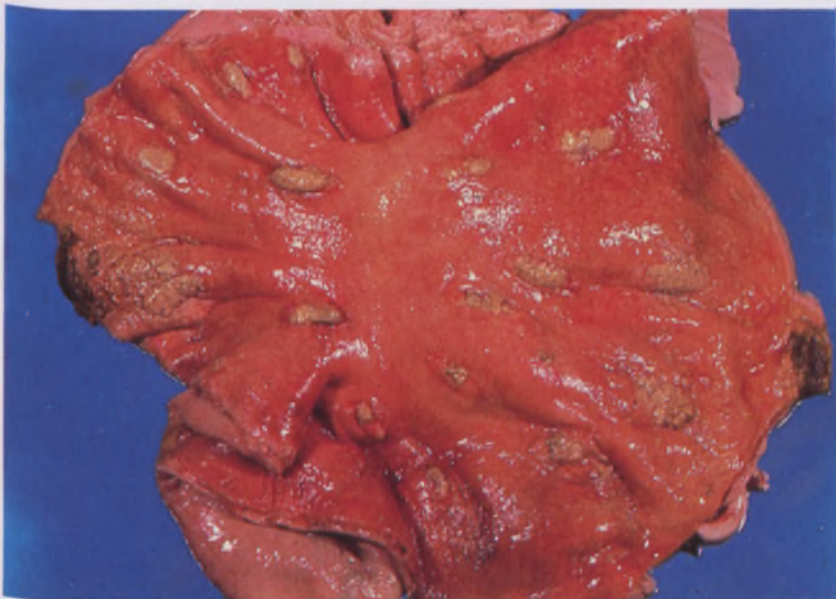


PLATE 290: MYCOTIC (ASPERGILLUS SPP.) METRITIS

The major portion of this uterine mucosa is congested and the caruncles are atrophic from normal involution, but on both sides at its widest opened area there is yellow and black necrotic debris attached that looks somewhat like the caruncles. Some orange debris is attached to several caruncles also. This debris is evidence for Mycotic Metritis in those areas. Abortions due to molds especially *Aspergillus* spp., *Mucor* spp. and *Mortierella* spp. are common in the world with a major portion of the placenta involved, but it is rare to find a mycotic lesion in the uterus proper.

Dr. K. McEntee, Illinois, USA

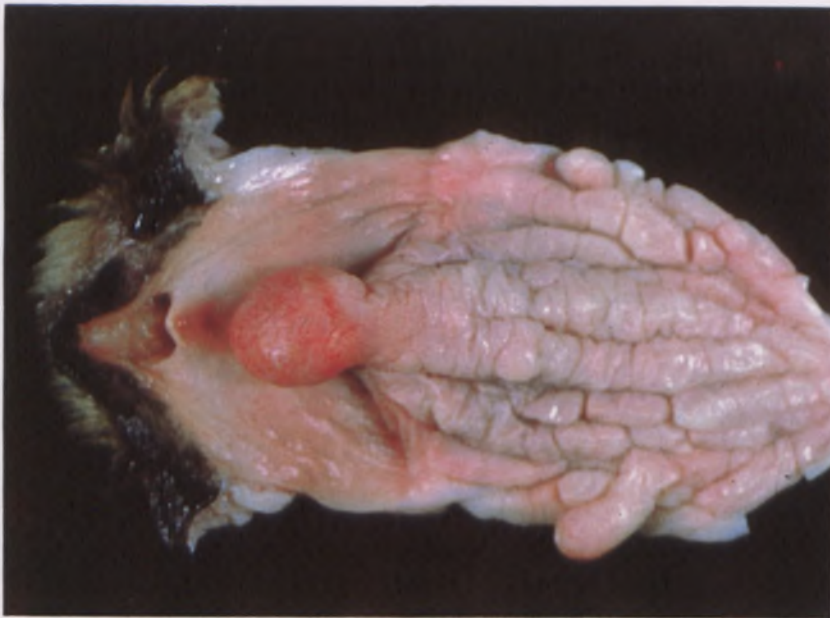

PLATE 291: FIBROMATOUS POLYPS

The multiple linear corrugated folds of this old dog's vagina is a normal aging change but the two finger like projections from the mucosa, one of which is redder than the other, are Fibromatous Polyps. These are quite common in older dogs and only histological examination can differentiate them from neoplastic polyps such as Leiomyomas or Fibromas.

Dr. P. Sponmenberg, Virginia, USA

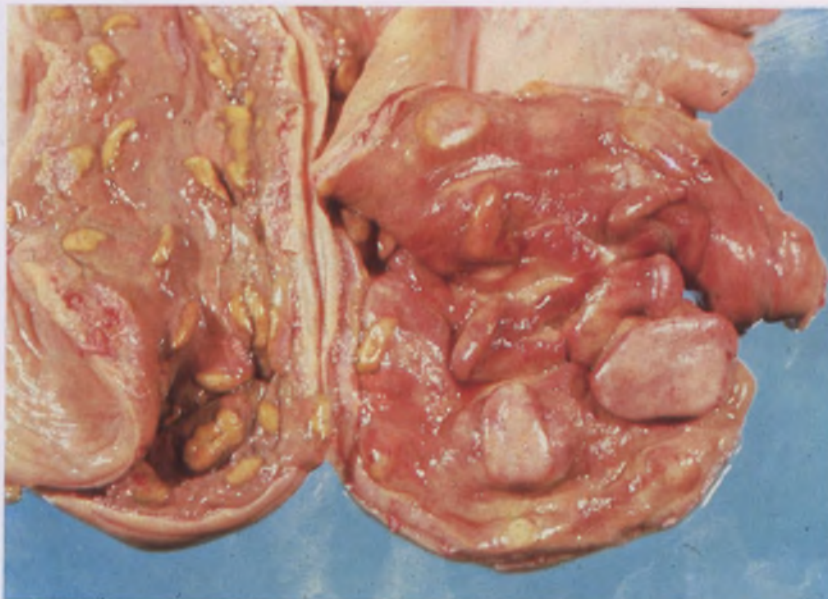


PLATE 292: LYMPHOSARCOMA

For the most part the caruncles and mucosa of one of the uterine horns in this cow uterus is essentially normal. The other horn however has several markedly enlarged caruncles and thickened patches of mucosa. This thickening is due to the invasion of neoplastic lymphocytes in this disease, Lymphosarcoma. It is interesting to note that pregnant cattle often have the lymphoid neoplasm in the nonpregnant horn. However explanation eludes us, as now and then the tumor is in both horns when the cow is pregnant.

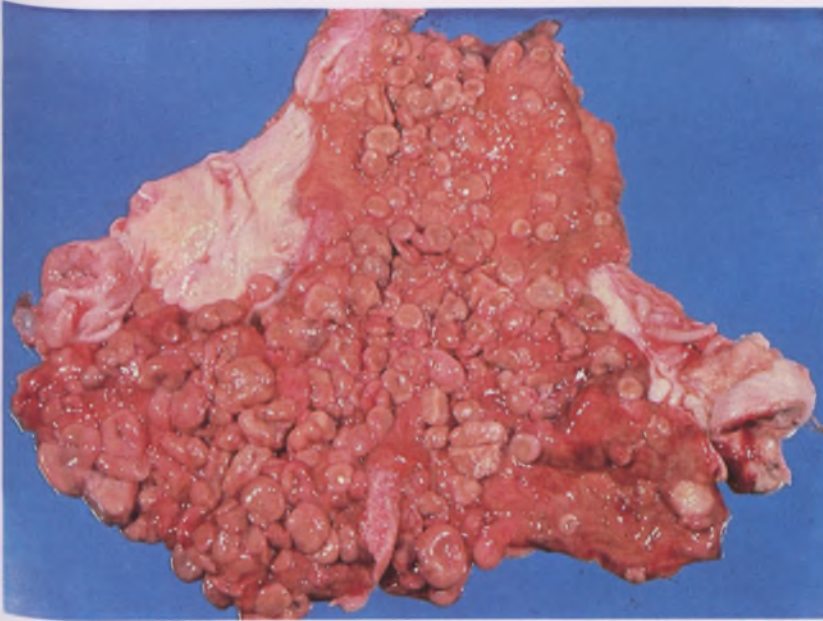


PLATE 293: LYMPHOSARCOMA

One's first glance at this horse uterus should make one think these are normal caruncles, but as a horse has diffuse placentation it is not likely to be these. This is a case of Lymphosarcoma of the uterus, and all those pale nodules are neoplastic masses.



PLATE 294: SQUAMOUS CELL CARCINOMA

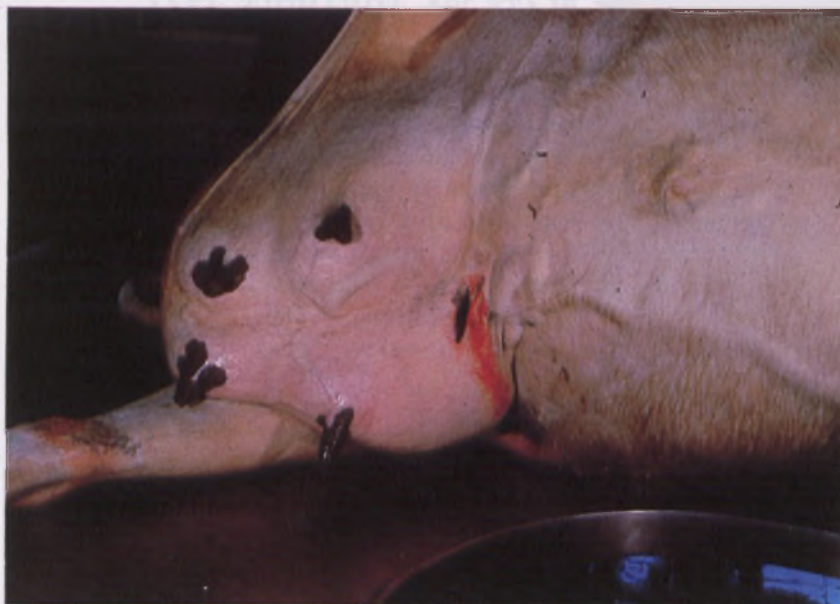The large blackened masses from the vulva of these two sheep are Squamous Cell Carcinomas which have been covered with a fly repellent. These malignant neoplasms had been seen in epidemic proportions in several flocks in South Africa and the thought at that time was that they were genetically related problems. The cause has not been fully explained. They have been found on the neck of sheep in New York State.



Dr. D. Scott, Cornell, USA

**PLATE 295: TRANSMISSIBLE
VENEREAL TUMOR**

The large massive protrusion of the vulva in this dog is the result of a Transmissible Venereal Tumor located in the vaginal wall. These tumors are also common on the external genitalia of male dogs and even on their noses for obvious reasons. Most of these spontaneously regress.



Dr. K. Braun, Florida, USA

PLATE 296: EXSANGUINATION

This cow bled to death, Exsanguination as the result of a short sharp stick she had stepped on springing up and stabbing her in this region. It penetrated the skin and severed one of her major cranial mammary veins.



**PLATE 297: MAMMARY GLAND
HEMATOMA**

This cow was weak and anemic as a result of the blood seen here between the halves of the mammary gland. This Mammary Hematoma is usually the result of a pendulous udder that traumatically tears one of the major vessels between the halves, allowing the fatal hemorrhage.

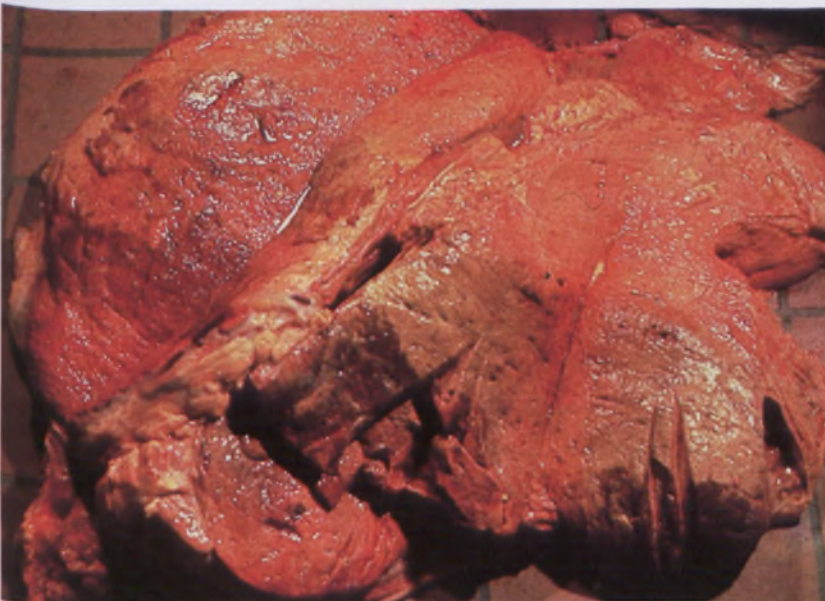

PLATE 298: ACUTE SEPTIC MASTITIS

Two of the four quarters of this cow's mammary gland are darker than normal and one has a definite green discoloration on part of its exposed surface. This is the result of Acute Septic Mastitis and can be caused by a number of organisms including *Escherichia coli*, *Staphylococcus* spp. and *Clostridium* spp. When first removed from the carcass or when the mammary gland is cut open the organ may just appear congested, but when left exposed to the air for a period of time the surface may change to varying shades of dark red black to green as a result of oxidation. Affected glands often have a definite fermentation odor, even without discoloration. The quality of milk in the teat cistern surprisingly is not always abnormal.

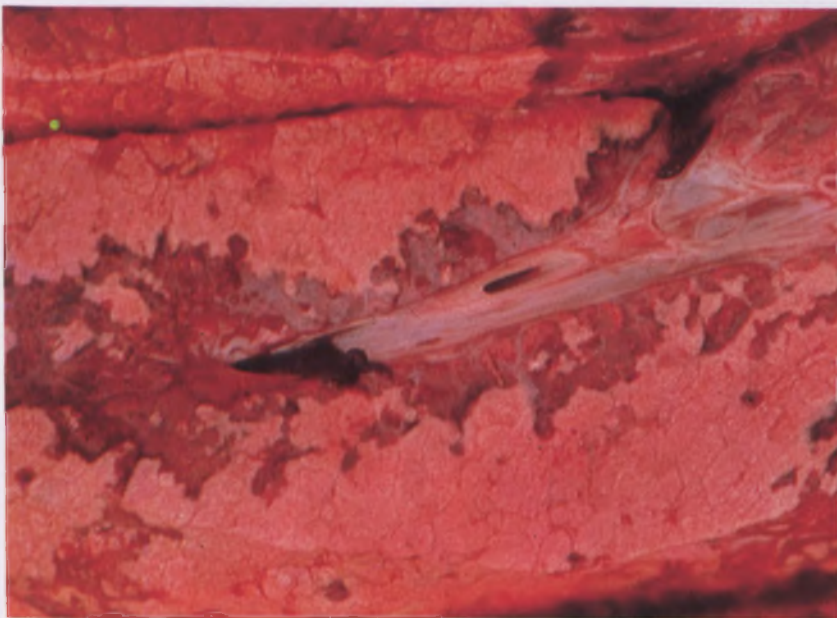


PLATE 299: MAMMARY GLAND INFARCTION

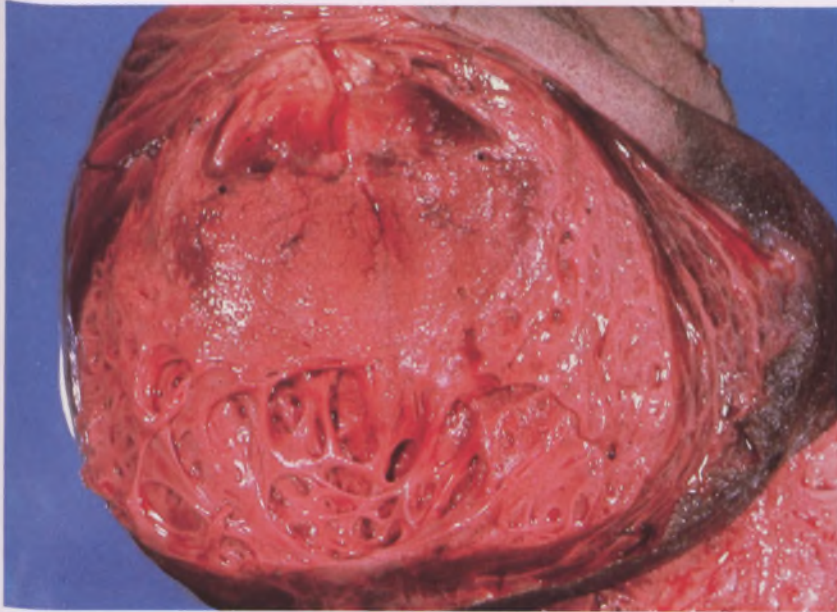
The red colored mammary tissue along the vessel is still viable tissue in this cow, but the pale pink tissue with a greytinged border is necrotic tissue as the result of Chronic Septic Mastitis with Infarction. This is not an uncommon finding in cases of Septic Mastitis no matter what is the causative agent. *Streptococci* spp., *Staphylococci* spp., *Escherichia coli* and *Clostridium* spp. have all been isolated from such cases. Most occur around the time of parturition. It is thought that the infarction is due to a generalized swelling of the mammary gland with vascular cut off. These pale areas are firm and usually dry.

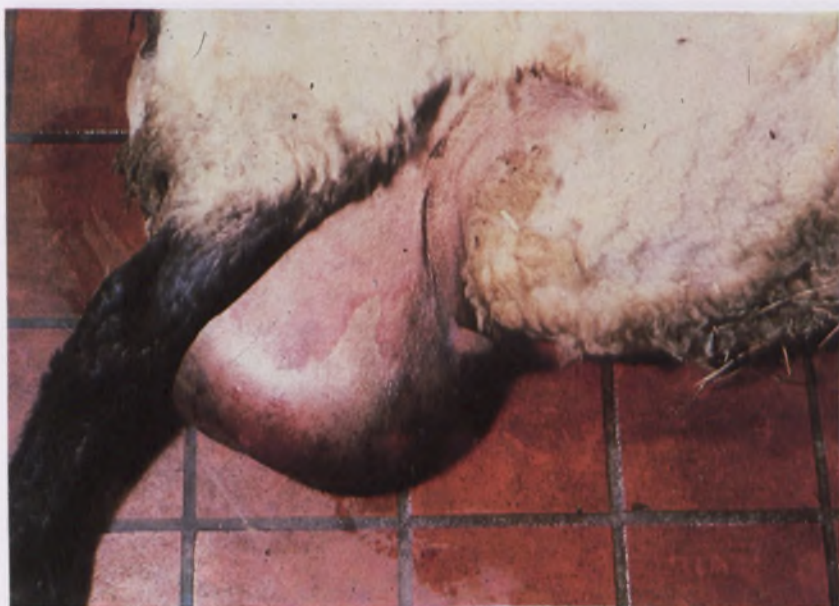

PLATE 300: ACUTE BACTERIAL (PASTEURELLA SPP.) MASTITIS (BLUEBAG)

The enlarged swollen firm half of this sheep's udder has a definite irregular red line of inflammation about half way up its side. With time the ventral half of this side of the udder may slough off as a result of the gangrene in the udder. This is a case of Bluebag caused usually by *Pasteurella* spp. This is a common form of mastitis in sheep and usually is associated with parturition.

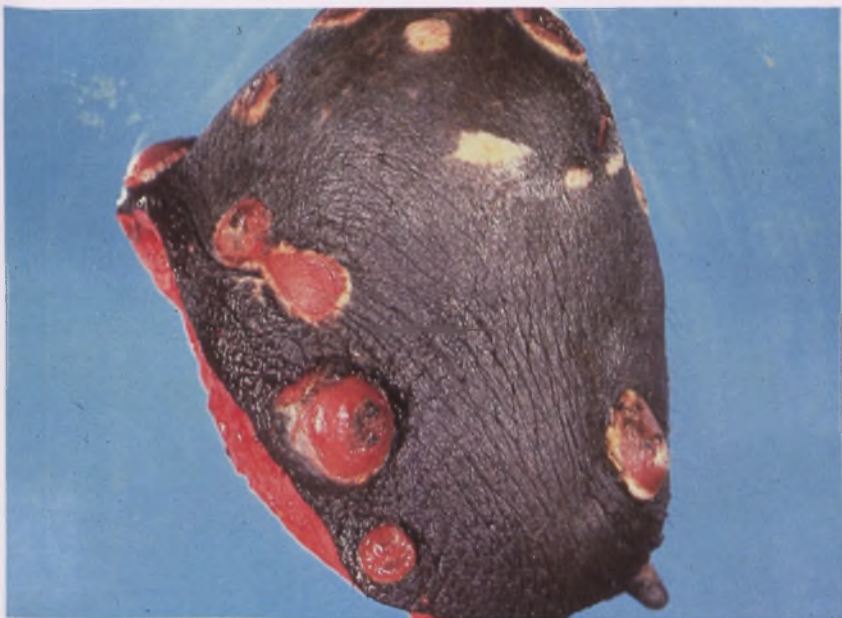Dr. Brannon, Cornell, USA



**PLATE 301: ACUTE SEPTIC MASTITIS
(BLUEBAG)**

The dull red appearance of the parenchyma of this mammary gland in a sheep is characteristic for Acute Septic Mastitis caused by *Pasteurella* spp., commonly called Bluebag because of its external appearance. The massive edema around the affected area and its fermentation odor are also characteristic.

Dr. F. A. Michel, Texas



**PLATE 302: CHRONIC GRANULOMA-
TOUS STAPHYLOCOCCAL
MASTITIS**

A single teat is protruding from one edge of this portion of a sow's udder. The other ulcerated nodules and white scars on the surface show various stages, from superficially healed to draining abscesses, in this case of Chronic Granulomatous Staphylococcal Mastitis. Botryomycosis is an older name for this disease that usually affects cattle and other species. *Staphylococcus aureus* is the organism usually isolated.

Dr. F. H. Wu, Taiwan, ROC

Mammary Gland

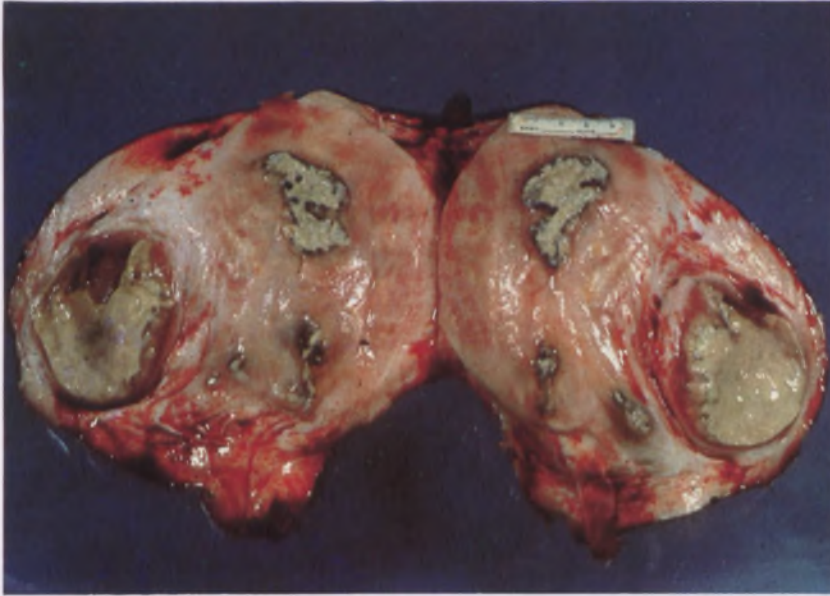


PLATE 303: CHRONIC GRANULOMATOUS STAPHYLOCCUS MASTITIS

The cut section of this sow's portion of mammary gland shows the marked connective tissue production, around the chronic abscessed pockets, caused by *Staphylococcus aureus*. Many of these rupture to the surface to form draining fistulae which take a long time to heal.

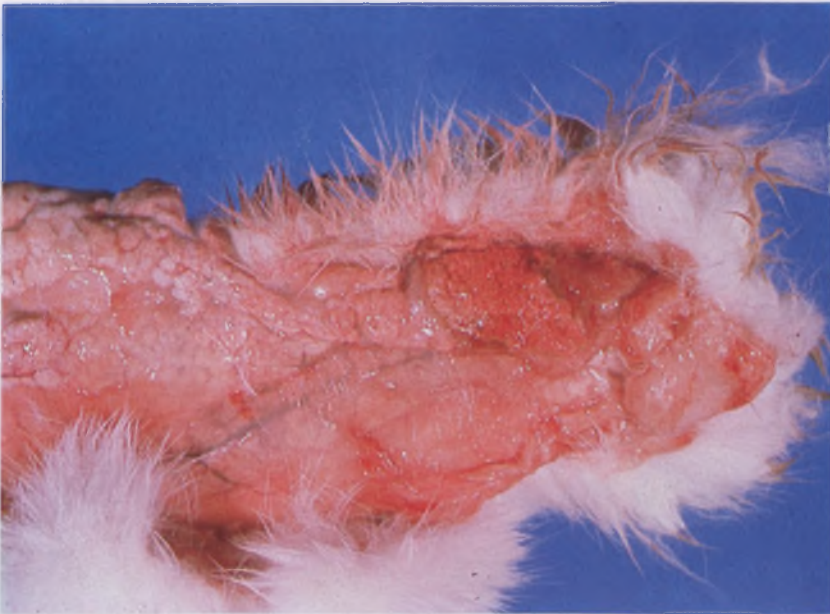

PLATE 304: SUBACUTE SEPTIC MASTITIS

This rabbit's gland is normal for the most part, but one area is discolored pink with marked edema around it and a slightly green tinged zone at its edge. This is an area of Subacute Septic Mastitis and the major central pink area is becoming infarcted. This area of mastitis also had a definite fermentation odor quite similar to that in cattle. Various agents can be obtained from these but *Pasteurella* spp. is often cultured.

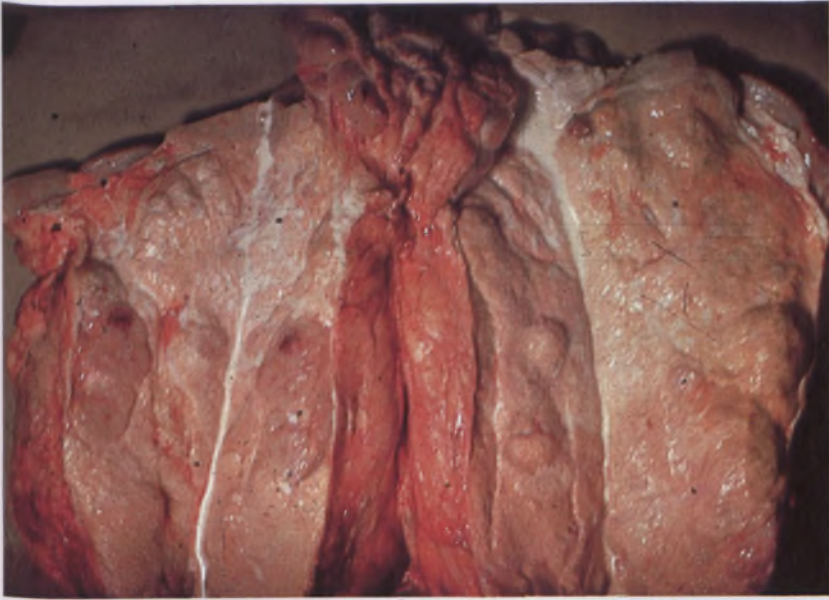


PLATE 305: LYMPHOSARCOMA

The multiple nodules in this cow mammary gland, a few of which have hemorrhages in them, are tumor nodules of Lymphosarcoma. It is comparatively rare for this organ to be affected with tumors in cattle. However, there are cases in which tumor in the cow can be diffusely spread in the mammary gland.

Dr. T. A. Nobel, Isreal

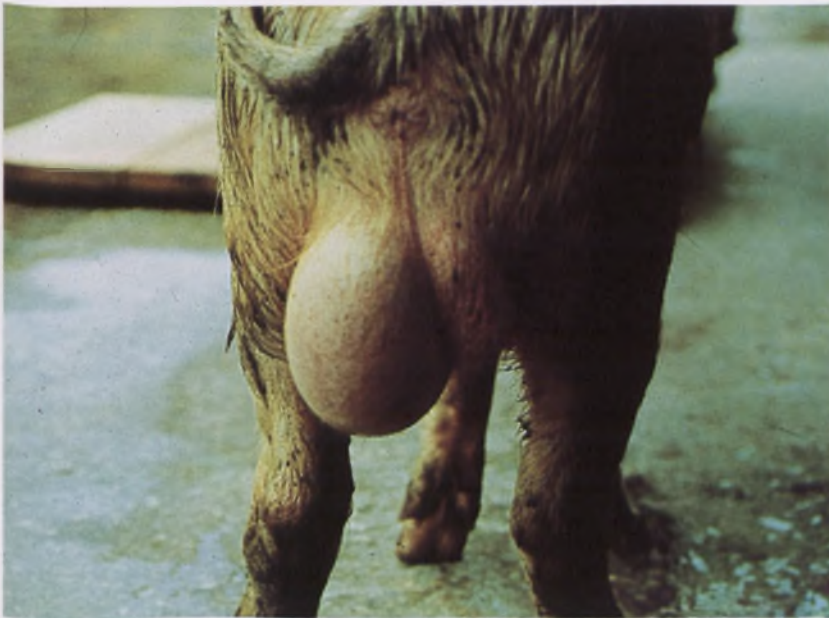

PLATE 306: BRUCELLA ORCHITIS

The one massively enlarged testicle in this boar is the result of Brucella Orchitis caused by *Brucella suis*. One would also have to consider the possibility of several other common pathogens and even an Inguinal Hernia at this stage of examination. Even after opening the infected testicle, culture would be the next step to confirm the diagnosis.

Dr. F. M. Wu, Taiwan, ROC

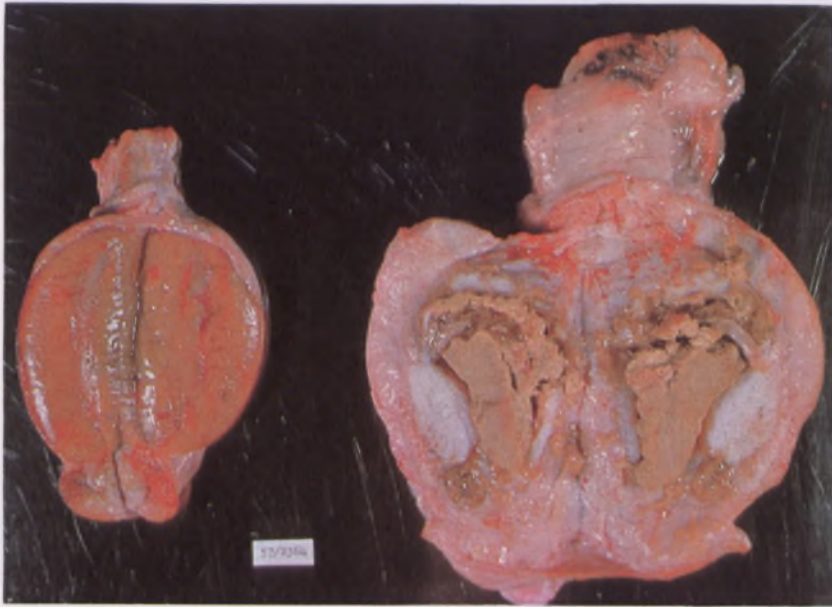

PLATE 307: BRUCELLA ORCHITIS

The tan dried material mixed in with the marked extra connective tissue of this ram's testicle is the result of chronic abscess formation caused by *Brucella ovis*. Other organisms can cause this but one should always consider this organism in any outbreak.

Dr. D. Dodd, Illinois, USA

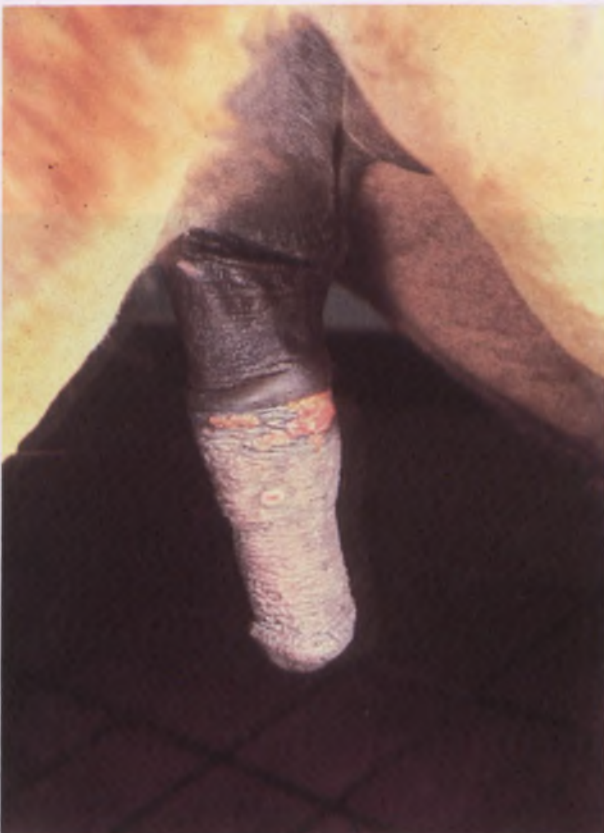

PLATE 308: COITAL EXANTHEMA OF HORSES

The well marked ulcers on the penis of this pony are the classical lesions seen in this disease. This relatively new viral disease is causing problems on many stud farms and affects females as well.

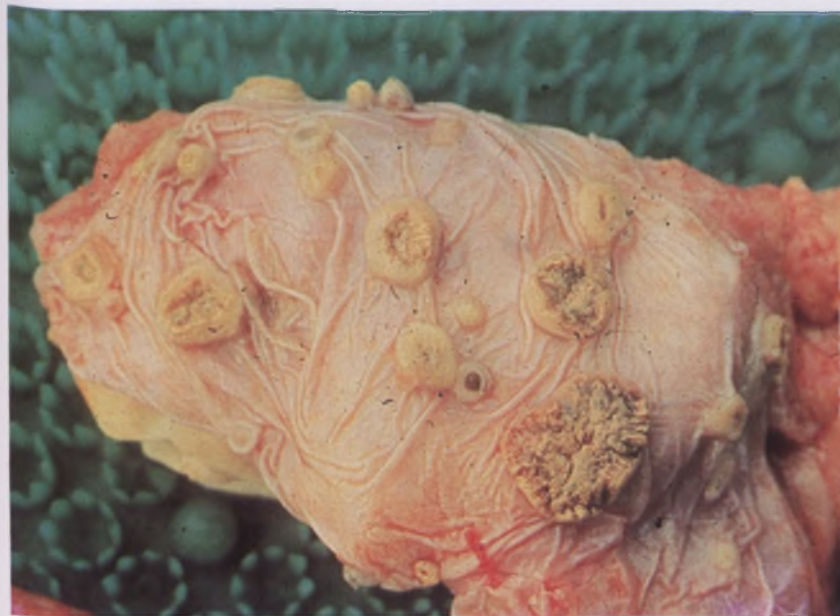

PLATE 309: MYCOTIC PREPUCITIS

The classical umbilicated circular plaques are caused by a mycotic infection on this prepuce of a young pig. It is not an uncommon lesion, but it is seldom identified as the prepuce is not always cut open during a necropsy. No agent was cultured from this case.

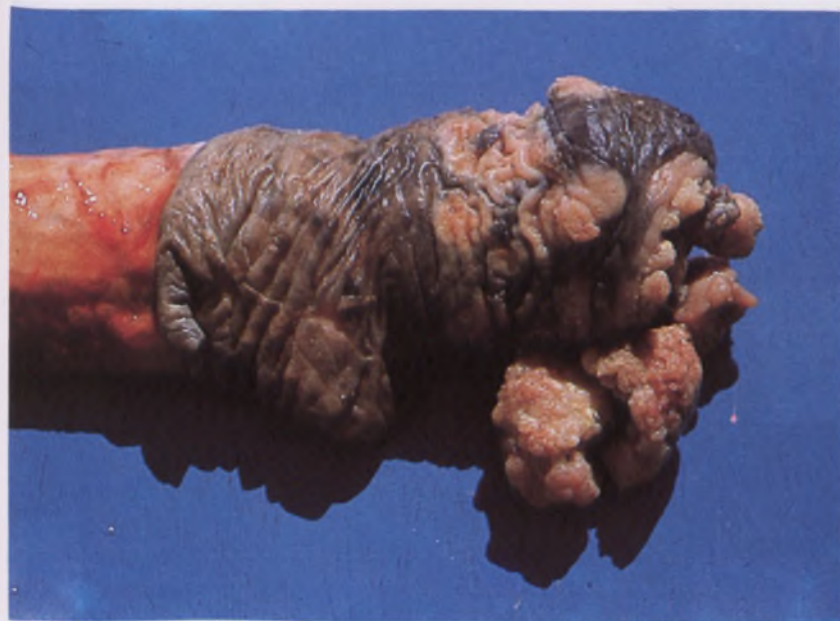
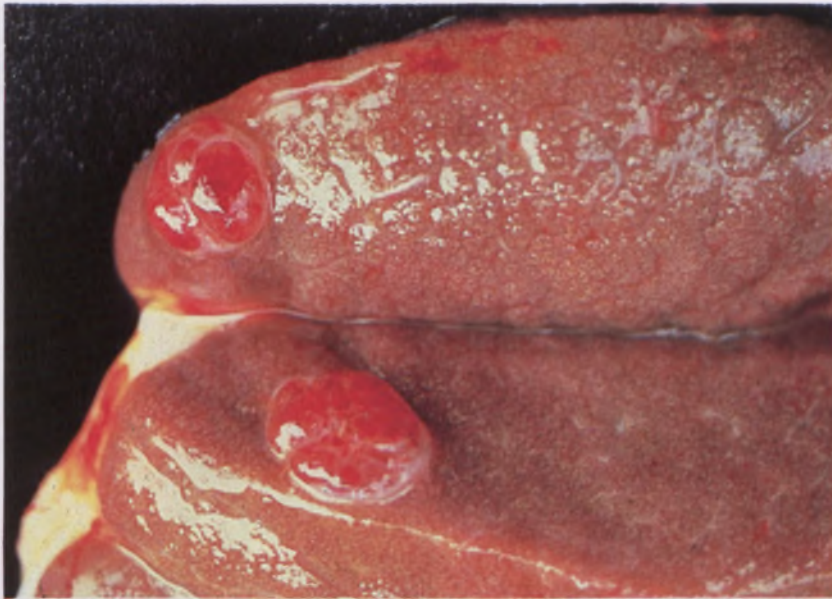
PLATE 310: SQUAMOUS CELL CARCINOMA

The irregular fungating masses on this horse's penis are Squamous Cell Carcinomas. These are very malignant and commonly metastasize to regional lymph nodes. Smegma is thought to be carcinogenic under some conditions.



Dr. F. M. Wu, Taiwan ROC

PLATE 311: INTERSTITIAL CELL TUMOR

The well rounded bulging mass with hemorrhage in it and surrounded by a thin connective tissue capsule, is an Interstitial Cell Tumor in this boar. It is the most common testicular tumor in boars of Taiwan. It is bloodier and softer than Sertoli Cell Tumors. It was recently found in 3 of 19 boars 3½ to 4 yrs. of age.

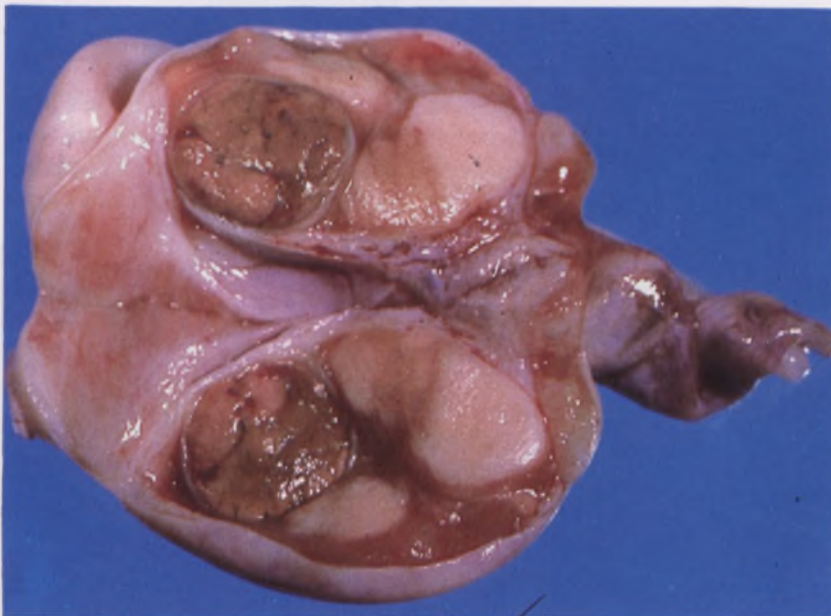


PLATE 312: SERTOLI CELL AND INTERSTITIAL CELL TUMORS

This dog's testicle has been cut in half to show two pale, firm and slightly elongated masses, and a single more fleshy mass with a round outline and a thin rim of connective tissue. This latter rounded mass is soft and yellow tan which is characteristic of an Interstitial Cell Tumor. The former two grey masses are grey and firm. These two masses are characteristic of Sertoli Cell Tumors. The third common tumor of the dog is the Seminoma which is not shown but it is characteristically pale and soft. While some hormonal activity has been ascribed to these tumors by different researchers, it is only the Sertoli Cell Tumor that consistently causes feminization in male dogs. Retained testicles (Cryptorchid testicles) are often affected with Sertoli Cell Tumors and only now and then Seminomas.

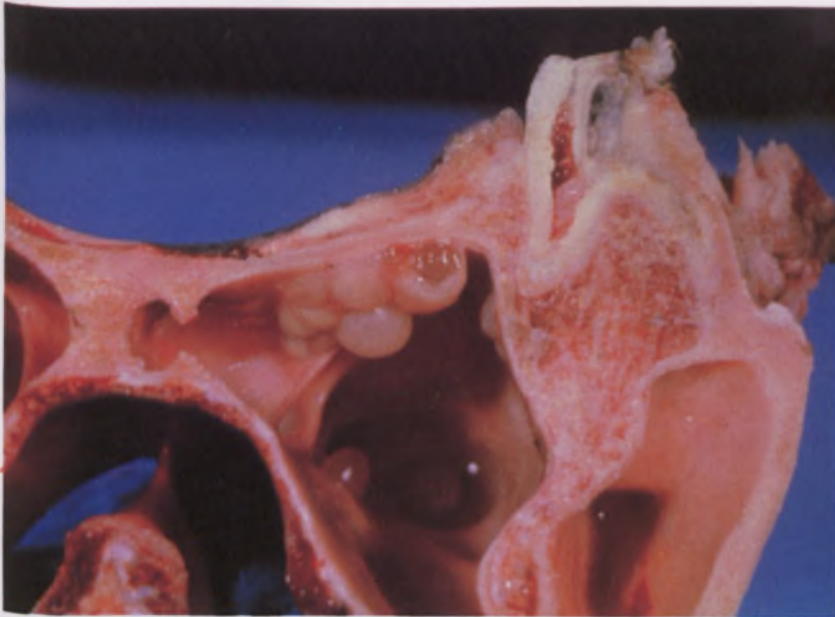

PLATE 313: MUCOUS SINUS CYSTS

The clear fluid filled cysts with a thick but soft cover in this heifer's palatine fossa are common findings, usually in older animals. They have cuboidal epithelial linings histologically and the material filling them is mucus like. The cause is unknown, but probably acquired as they are not found in young animals.

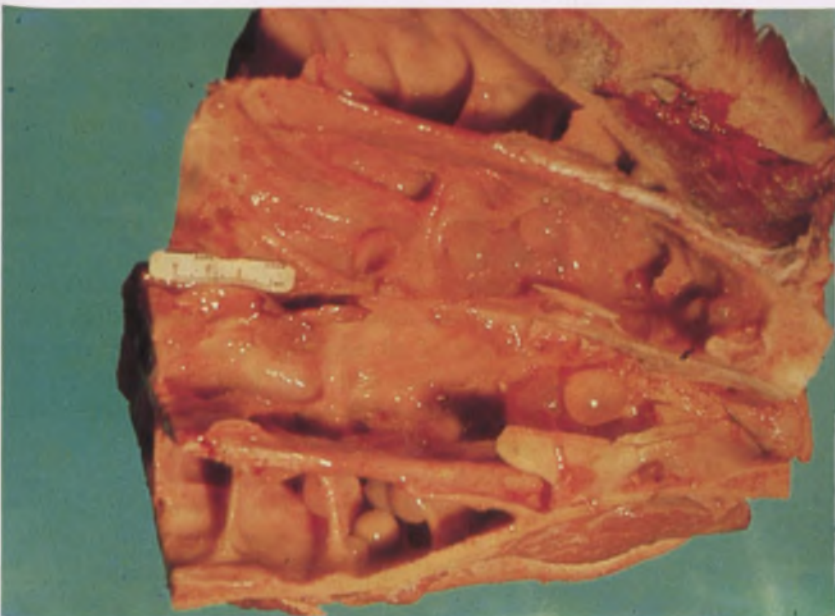


PLATE 314: MUCOUS SINUS CYSTS

This adult bull has numerous mucus filled cysts scattered in the maxillary and palatine sinuses. Their cause is unknown and they have no known clinical significance.

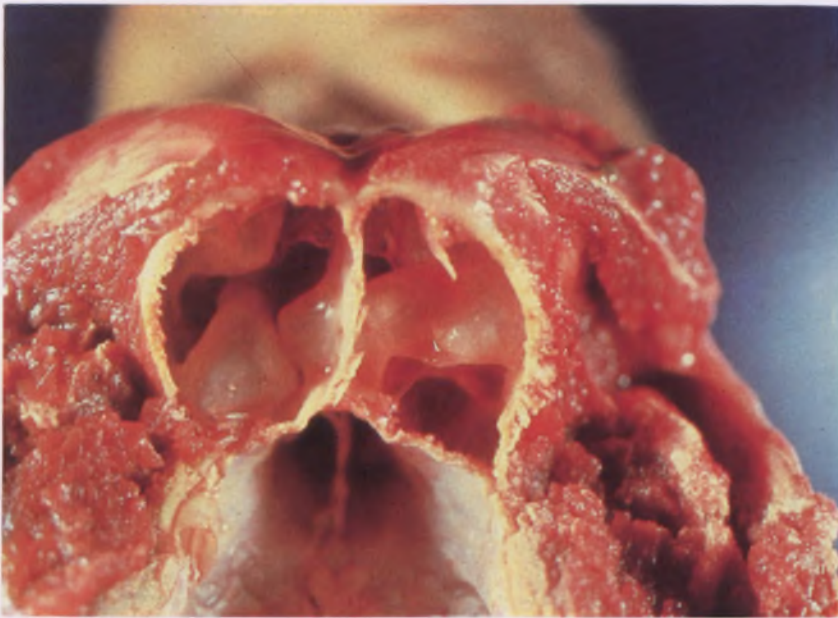


PLATE 315: OSSIFIED SINUS CYSTS

The clear, apparently empty cystic cavities protruding from the sinus walls in this dog's skull are quite common in large breed, mature dogs. They are usually hollow and have a thin plate of bone in their wall. They are usually lined by sinus type epithelium. Their cause is unknown and they have no known clinical importance except as points of confusion radiographically.

Dr. V. Rendano, Cornell, USA




PLATE 316: ATROPHIC RHINITIS

The 66 pig snouts shown here have all been transected at a line level with the lip commissures. They show four cases in which the turbinates are primarily, unilaterally shrunken (atrophic) but the great majority are bilaterally and quite symmetrically atrophic in the ventral turbinates mainly and/or their dorsal turbinates. Only a few are unaffected. These snouts represent a routine, unselected, weeks collection of all necropsy cases from a large pig farm. The fact that only four are unilateral, and that the vast majority are bilateral and symmetrical, suggests that atrophic rhinitis in pigs is more likely a metabolic disease than an infectious one. Certainly the four unilateral cases may be secondarily infected, for example with *Bordetella bronchiseptica*, but it is unlikely that a bacterial disease can make such a vast majority of symmetrical lesions. Dr. Krook's work on this as a nutritional problem is still controversial.

Dr. F. Hsu, Taiwan, ROC

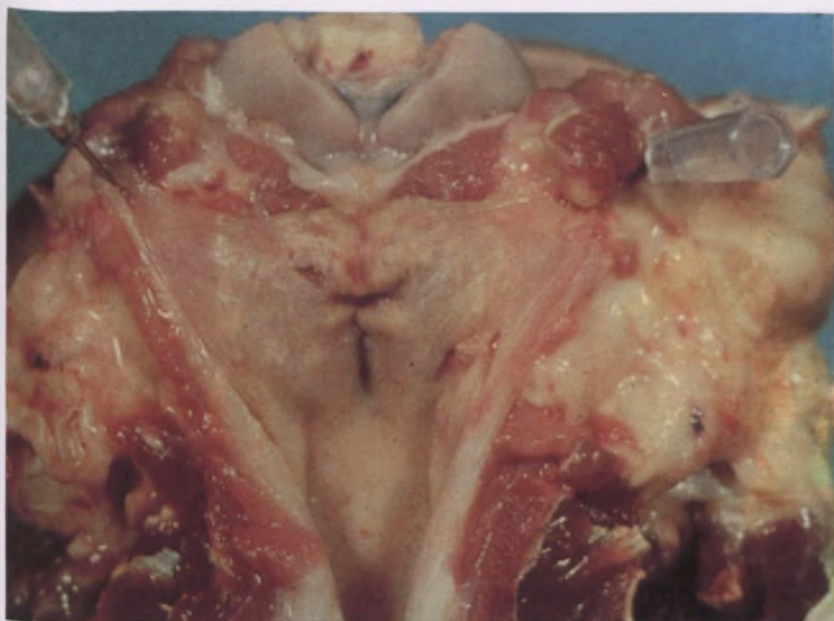


PLATE 317: PHARYNGEAL MINERALIZATION

The midline region is slightly discolored yellow red. The red is hemorrhage and congestion and the yellow areas are foci of mineralization in this dog with renal failure and uremia. The costal pleura, left atrial endocardium, vascular intima, kidney parenchyma and gastric mucosa are other common locations for such mineralization.

Dr. G. Gibson, Cornell, USA

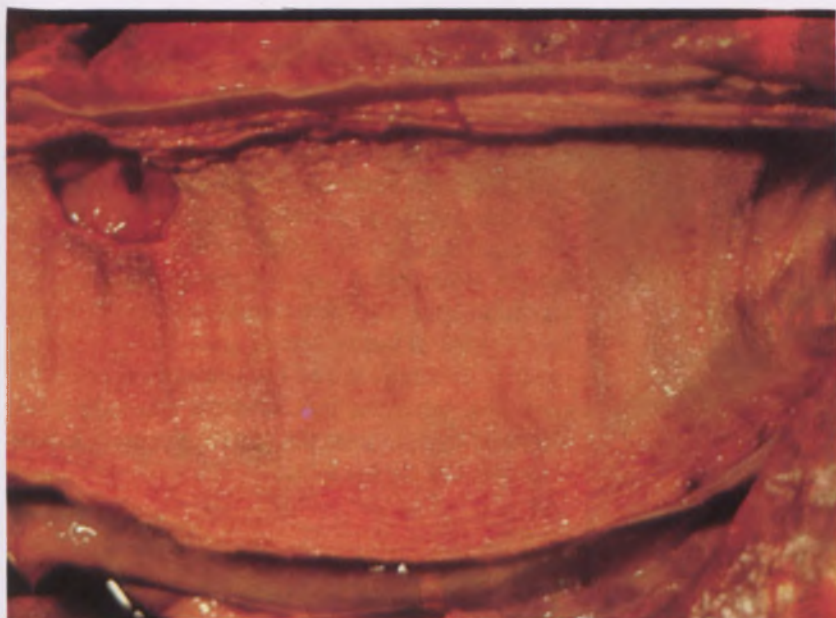
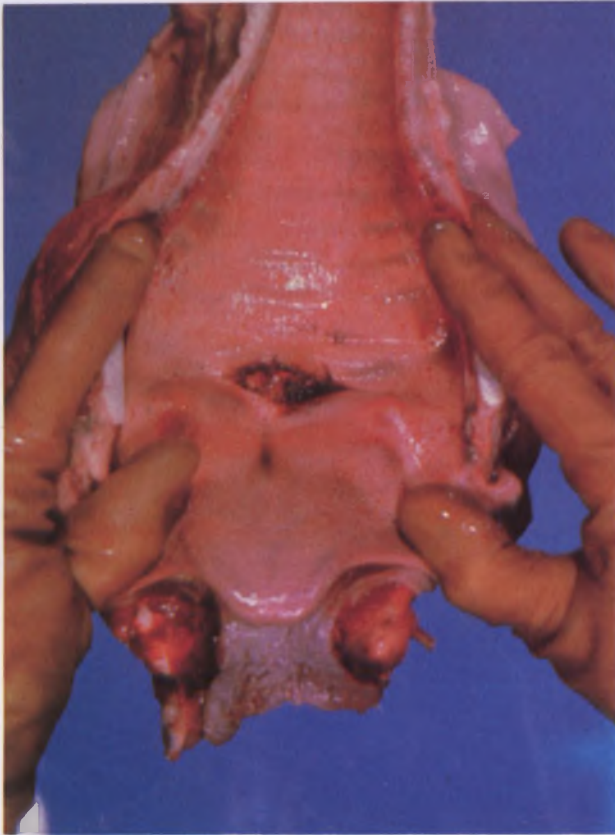

PLATE 318: TRACHEAL MINERALIZATION

The off colored white, finely granular surface of this horse's trachea is the result of marked mineralization. Such a lesion can be caused by excessive Vit. D therapy as in this case and even due to the pseudohyperparathyroidism of certain tumors such as some lymphosarcomas in the horse and anal sac gland adenocarcinomas in dogs.

Dr. B. Cooper, Cornell, USA



Dr. G. Gibson, Cornell, USA

PLATE 319: LARYNGEAL TRAUMA

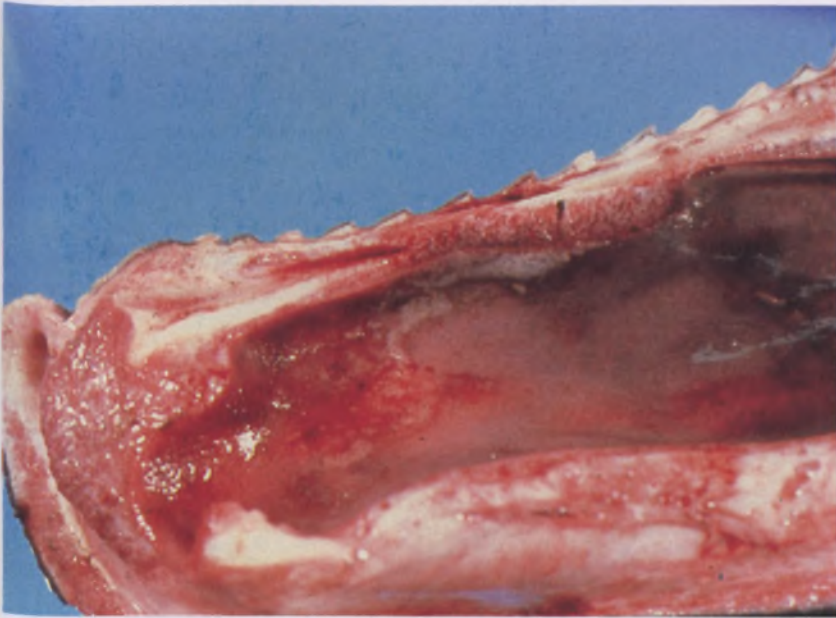
This cow died as the result of a large blood clot over this acute traumatic lesion of the larynx. Her lungs were dark, relatively firm and airless, at least without emphysema. She died of suffocation from laryngeal spasm and a blocked glottis. The actual cause of trauma was undetermined at the necropsy table, but slipping on ice and hitting her throat on a relatively sharp, hard structure is suspected.

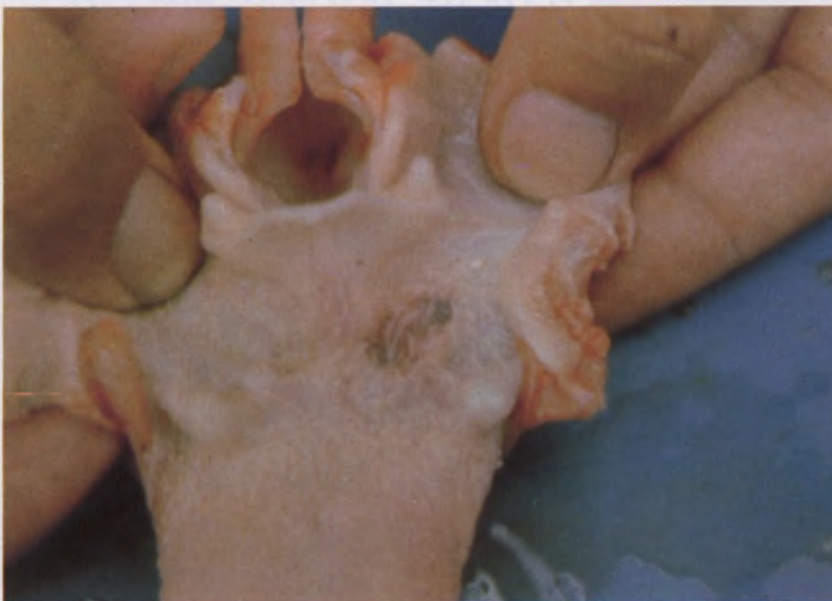

PLATE 320: HEALED ENTRANCE WOUND TRAUMA

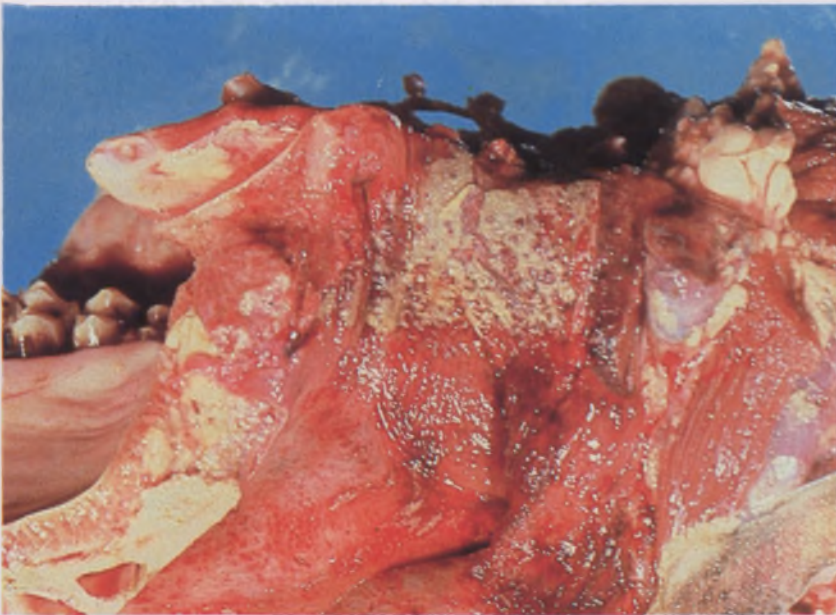The small dark area on one side just under the mucosa of this dog's throat, between the base of the tongue and the epiglottis, marks the entrance point of a fish bone that traveled through the tissues to the spinal cord and paralyzed the dog. In almost any species around this area and just above it are the common sites for penetration of many foreign bodies, such as bones, bits of grass, straw, wood, or needles. The surface site has healed as is often the case. The phlegmon that develops may take a few days and by that time the surface puncture wound may have already healed.

Dr. C. I. Liu, Taiwan, ROC



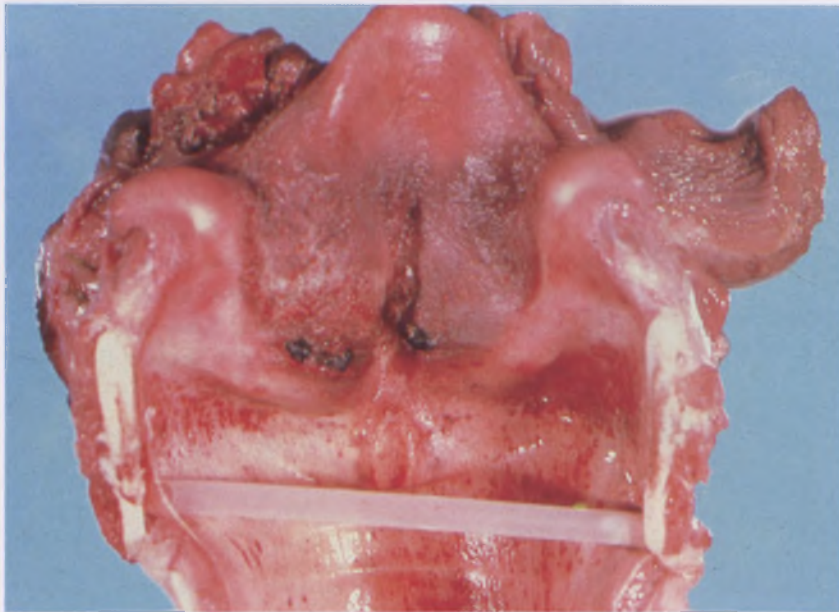
**PLATE 321: TOXIC (ARSENIC)
RHINITIS**

The nasal mucosa of this cow is severely congested with some hemorrhage and fibrinonecrotic debris attached on its more cranial surface. Such diseases as Bovine Virus Diarrhea, Infectious Bovine Rhinotracheitis, Bovine Malignant Catarrh and even Pasteurellosis could be suspected, but as this is the only lesion in the animal the above infectious diagnosis can be eliminated. This is a case of Arsenic Poisoning and this lesion is quite consistent for the diagnosis.



**PLATE 322: FIBRINONECROTIC TOXIC
(ARSENIC) PHARYNGITIS**

The pharyngeal mucosa of this cow is markedly congested and has a definite layer of white fibrinonecrotic debris attached in the region of posterior or caudal nares. This is the result of acute arsenic toxicity that killed a group of cattle which licked boards that had been contaminated from a rusted out container of weedkiller. Bovine Malignant Catarrh and similar diseases could be suspected as well. One wonders about the practicality to analyze this white material for arsenic as it may be eliminated there.



Dr. M. Wolfe, Cornell, USA

**PLATE 323: FIBRINONECROTIC
(TOXIC) LARYNGITIS**

Marked congestion, hemorrhage and necrotic debris is present on the surface of this cow's larynx. This lesion may be seen in Bovine Virus Diarrhea, Rinderpest, and other mucosal type diseases of cattle. However this is one from several cows in an outbreak of Arsenic Poisoning. The cows had a short clinical course including passage of dark watery feces.

Dr. G. Gibson, Cornell, USA



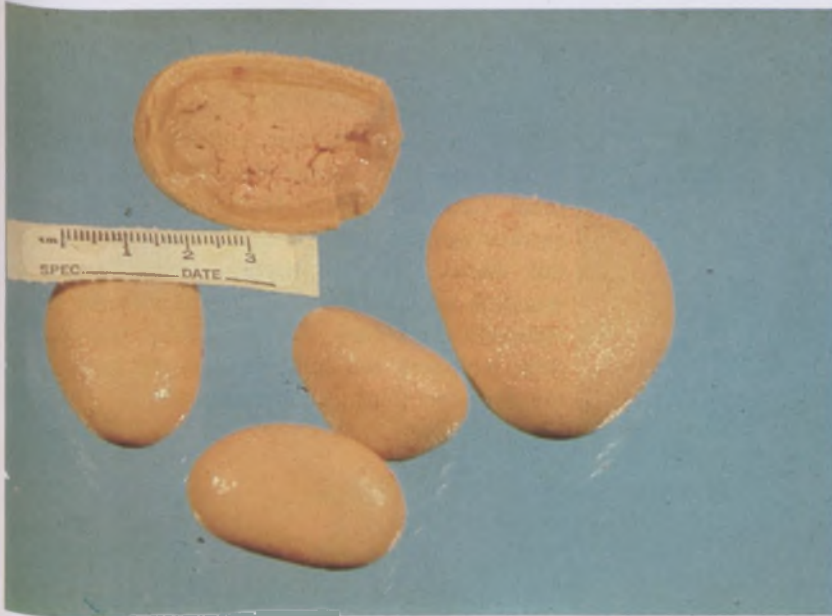Dr. G. Maylin, Cornell, USA

**PLATE 324: ARSENIC POISONING
SOURCE**

The contents of this can was the culprit for killing many cows. It was a water soluble weedkiller containing sodium arsenate which finally rusted out of the can, then spread out, and dried on the stacked boards beneath. The cattle with their penchant for licking salty materials died of Arsenic Poisoning after a clinical course of several days with a black stained diarrhea. The principle lesion in the cattle was severe necrotizing rhinitis and laryngitis.

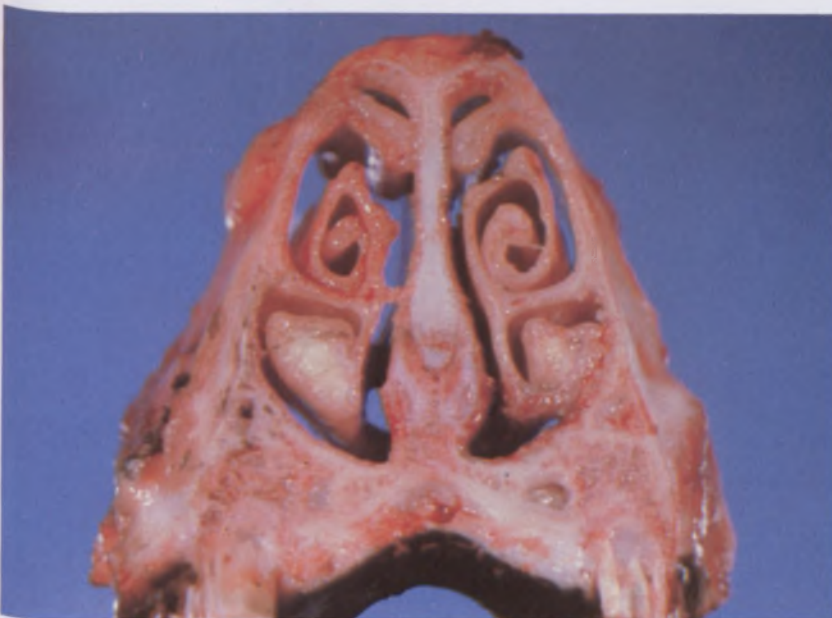**PLATE 325: GUTTERAL POUCH
CALCULI**

These concentrically laminated, firm to hard, roughly rhomboid masses were found free in the guttural pouch of a horse. While these are several centimeters along a side, they can often be much smaller and more rounded. These are inspissated masses of pus, the sequela of a Bacterial Guttural Pouch Infection. This is to be differentiated from the mycotic pouch infection which is usually dorsal and associated with the hyoid joint. *S. equi* or *C. equi* may be isolated from active cases of this type.



**PLATE 326: CHRONIC PURULENT
RHINITIS**

The ventral turbinates of this sheep are filled with a white cheesy pus from which *Corynebacterium pyogenes* was isolated. In sheep such a lesion is most likely associated with a previous nasal grub (*Oestrus ovis*) infection. In rabbits with Snuffles, a disease caused by *Pasteurella* spp., a similar lesion is quite common and even in rabbits or any animal that have a nasal exudate, the location of this lesion may be missed if the skull is not cut in half sagittally.



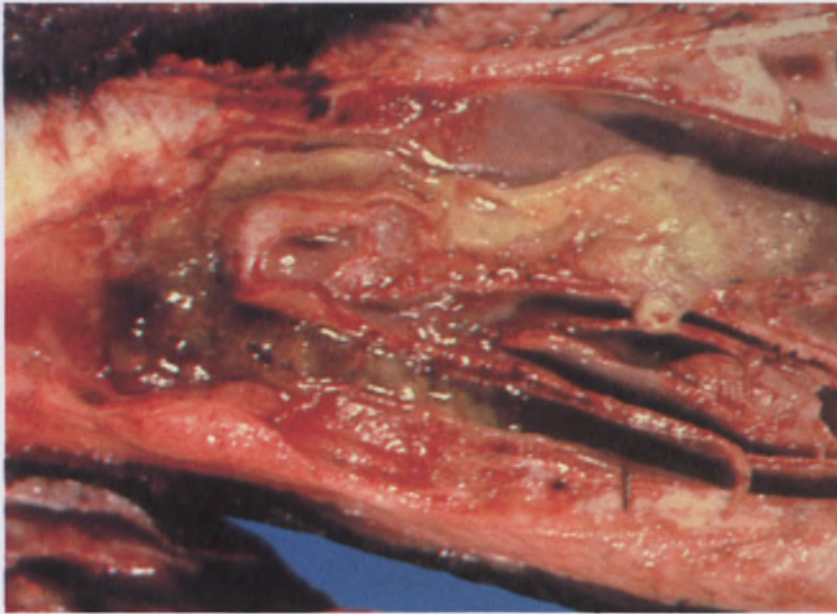


PLATE 327: ACUTE FIBRINONECROTIC RHINITIS

The cranial portion of the nasal cavity shows a marked fibrinonecrotic cast, adherent to the mucosa in this cow with Bovine Malignant Catarrh (Malignant Catarrhal Fever). High fever, keratitis and nervous signs are quite consistent clinical features of this disease. Histologically, a varying degree of vasculitis may be found in all the affected tissue especially the kidney, heart and brain. The perivascular lymphoid cell infiltrate may be so great as to make some think of lymphosarcoma.

Dr. F. Fox, Cornell, USA

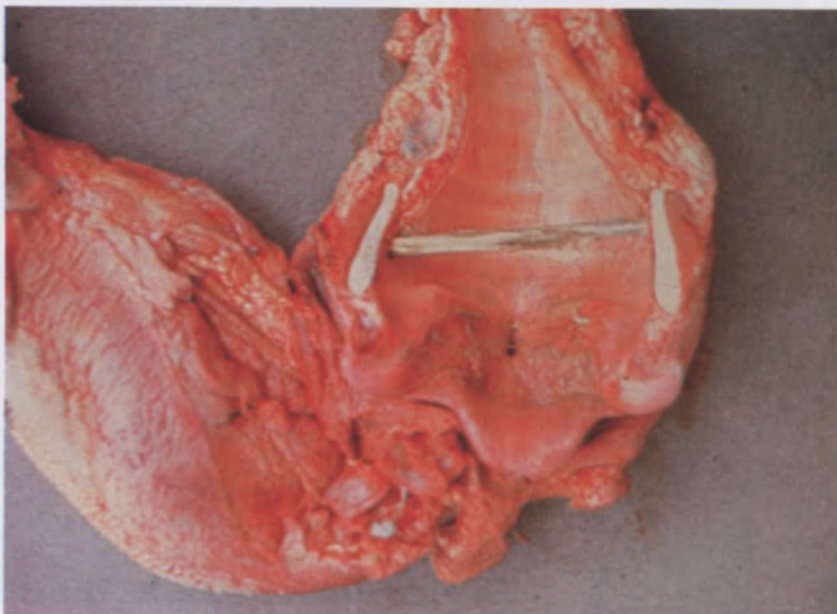
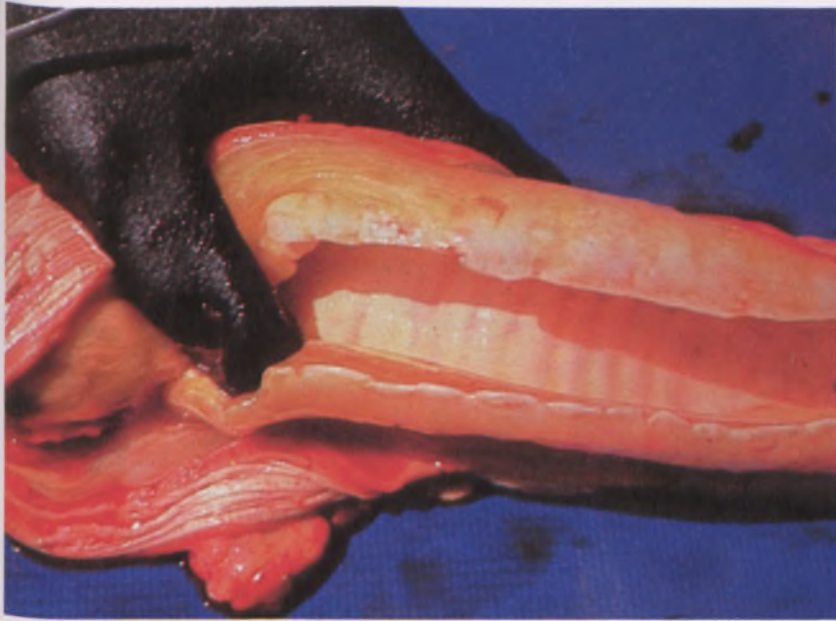
PLATE 328: ACUTE FIBRINONECROTIC LARYNGITIS

The congestion and fibrin deposits on this bull's trachea can be quite diagnostic for Bovine Malignant Catarrh (BMC), when considered along with clinical nervous signs, keratitis and high fever. In an affected bull the scrotum may show a degree of acute dermatitis as well as a cow's, goat's or deer's teats, escutcheon and vulva. An underlying vasculitis may account for these lesions as it does for the often grossly visible linear streaks in the heart of affected animals. The tracheitis alone may be seen in other types of mucosal disease and in arsenic poisoning cases.

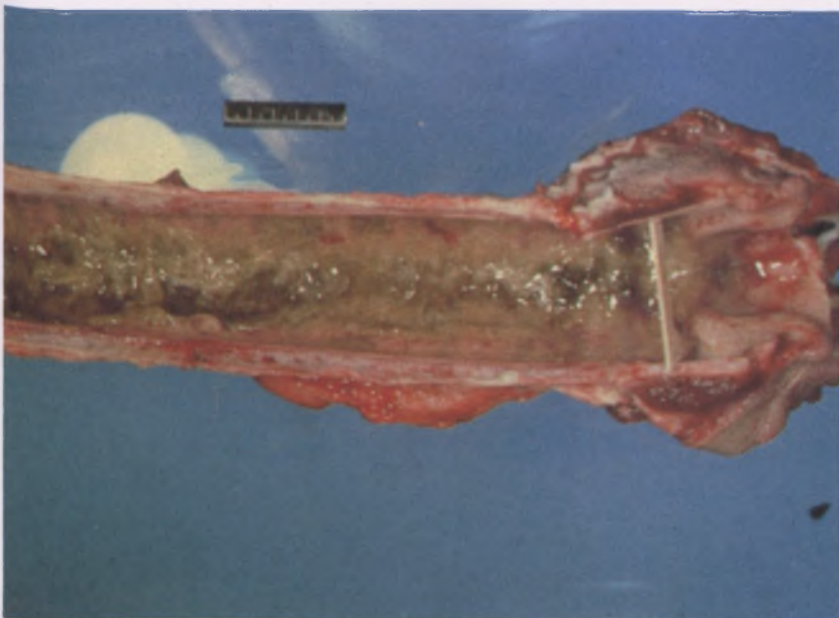
Dr. F. Fox, Cornell, USA



Dr. J. A. W. Coetzer, Onderstepoort, RSA

PLATE 329: TRACHEAL EDEMA

The yellow gelatinous material in the soft tissues just outside the tracheal rings of this horse is due to acute edema. In case of sudden death of horses without a local or other vascular reason for this edema, and in a country where African Horse Sickness occurs, this may be the only lesion to help make the diagnosis of this disease as in this case. In this viral disease edema may be present in any area of the head or thorax.



Dr. R. Gunther, Cornell, USA

PLATE 330: ACUTE FIBRINONECROTIC TRACHEITIS

This severe fibrinonecrotic tracheitis, extending for the entire length of the trachea in this heifer is a prime lesion of Infectious Bovine Rhinotracheitis (IBR). It can also be seen in debilitated animals and in Bovine Virus Diarrhea with secondary mycotic tracheitis. Of the many cattle to die of respiratory disease and be necropsied at the N.Y.S. Veterinary College only three or four have been diagnosed as IBR.

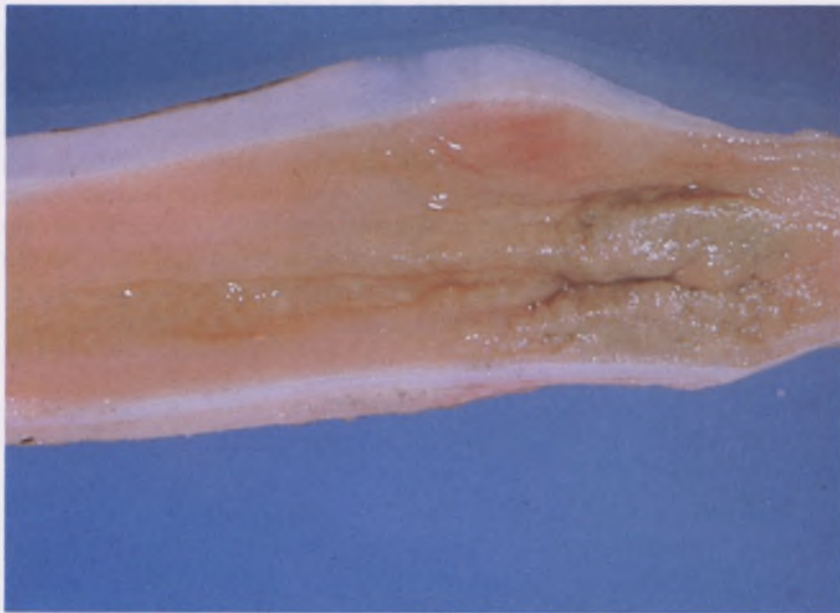


PLATE 331: GRANULOMATOUS RHINITIS

This cranial end of the nasal septum has several slightly roughened, green, granular masses in its mucosa. This is granulomatous inflammation of the mucosa caused by *Helminthosporum* spp. Although this animal was necropsied in N.Y. State, it had been recently shipped from the south. This is mainly a warm climate disease.

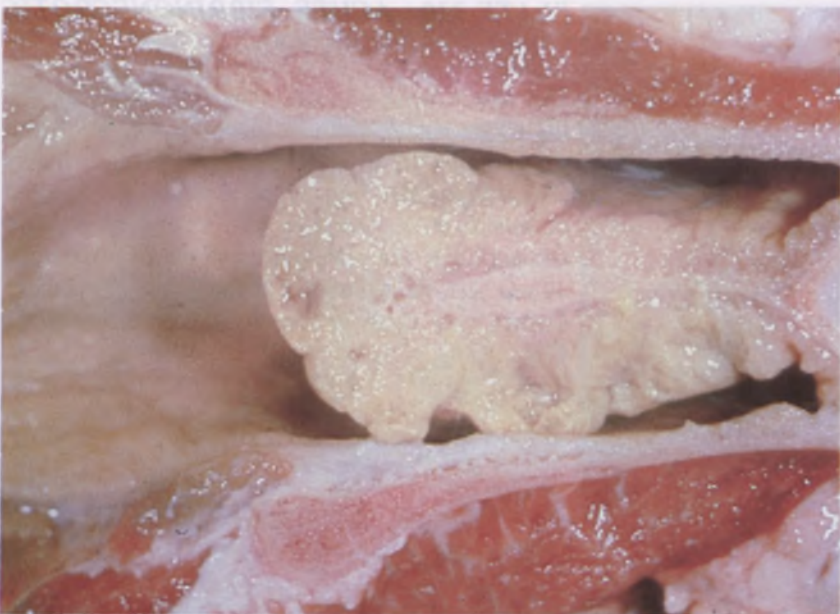
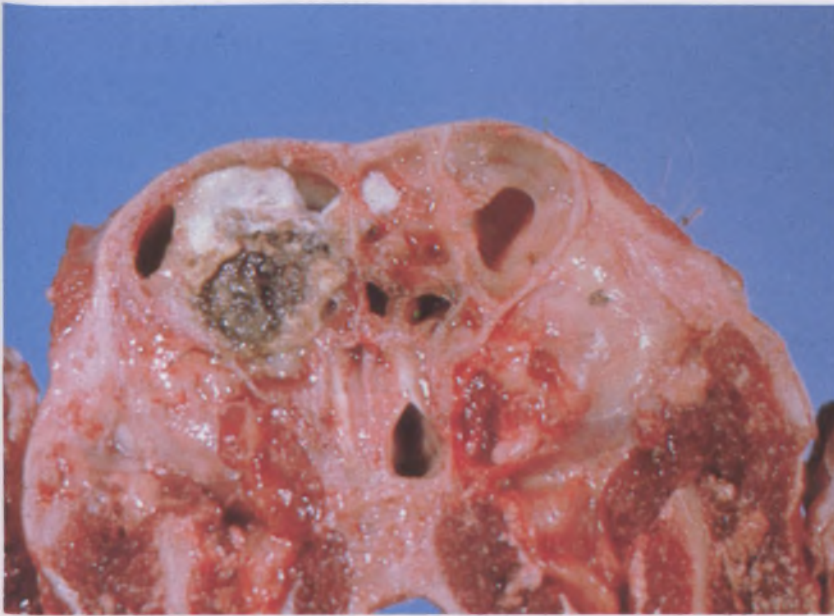
PLATE 332: NASAL GRANULOMA OF CATTLE

The cavity shown is the caudal portion of the nasal cavity, with a thin portion of the caudal aspect of the nasal septum projecting down in the midline. On both sides and the ventral tip of this nasal septum a marked green yellow granulomatous proliferation in the mucosa is to be noted. This is caused by *Helminthosporum* spp.

PLATE 333: MYCOTIC SINUSITIS

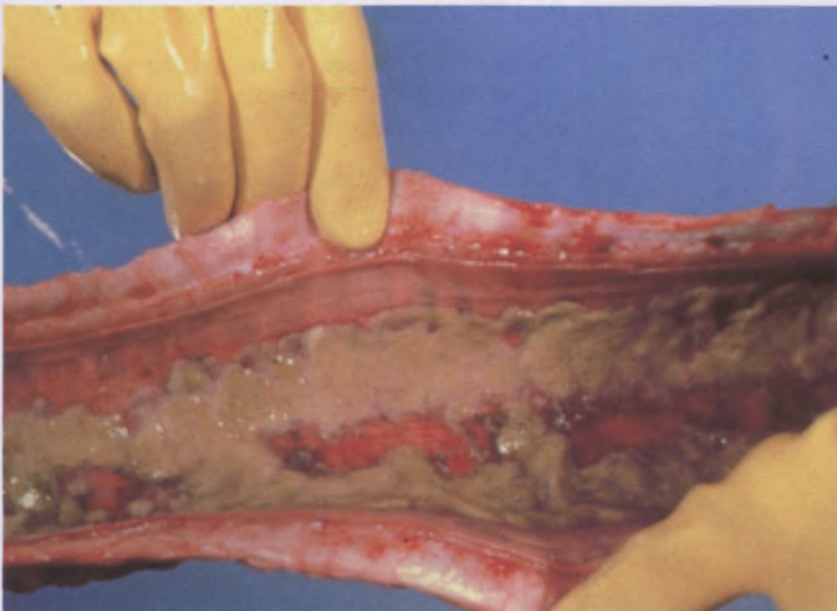The opaque white material above the green amorphous debris is a growth of mold in the sinuses of this dog's nose. The actual underlying problem that allows the mold to develop in this area is unknown, but the dogs will clinically often have some epistaxis and sneezing. *Aspergillus* spp. is often isolated when cultured. Similar lesions can be seen in other species.



A minority of cases may not demonstrate the bone changes

PLATE 334: MYCOTIC TRACHEITIS

The white debris lining a major portion of this trachea can be seen to be rather clearly delineated with almost a border like pattern. This is a growth of mold in the trachea of a cow with Virus Diarrhea. Often mycotic tracheitis, gastritis or enteritis can be found secondary to antibiotic therapy. *Aspergillus* spp. is a commonly isolated mold.



Dr. N. D. ...

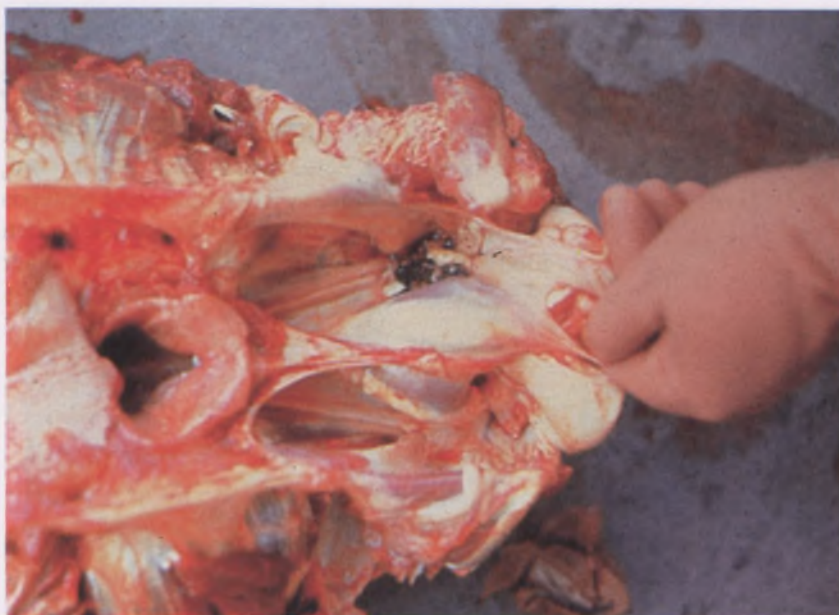

PLATE 335: MYCOTIC GUTTERAL POUCH INFECTION

The left guttural pouch of this horse has a black red mass attached to its roof adjacent to the hyoid petrous temporal bone articulation. This colored mass is a mycotic infection of the guttural pouch. *Aspergillus* spp. may be isolated. One suspected cause for these is that hyoid articular osteoarthritis develops and this becomes secondarily infected with mold. Mold can commonly be isolated from normal guttural pouches so another primary problem must be present such as osteoarthritis, probably traumatic on which the molds can then concentrate and grow. Epistaxis is a common historical clinical event. If animals die from this, usually it is from a mycotically eroded internal carotid artery which runs along this area to the brain. To show the osteoarthritis lesions of the joint the skull has to be boiled out or cleaned off in some other way. A minority of cases may not demonstrate the bone changes.

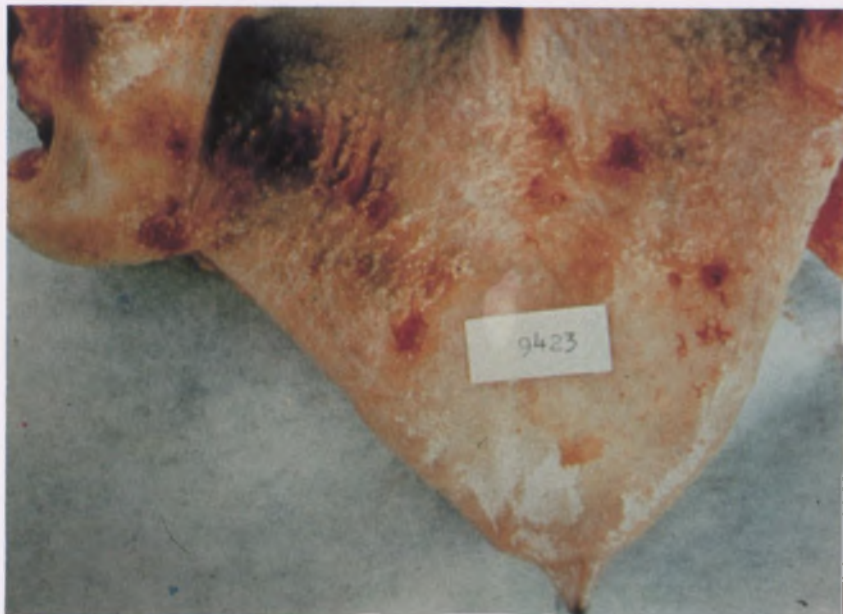
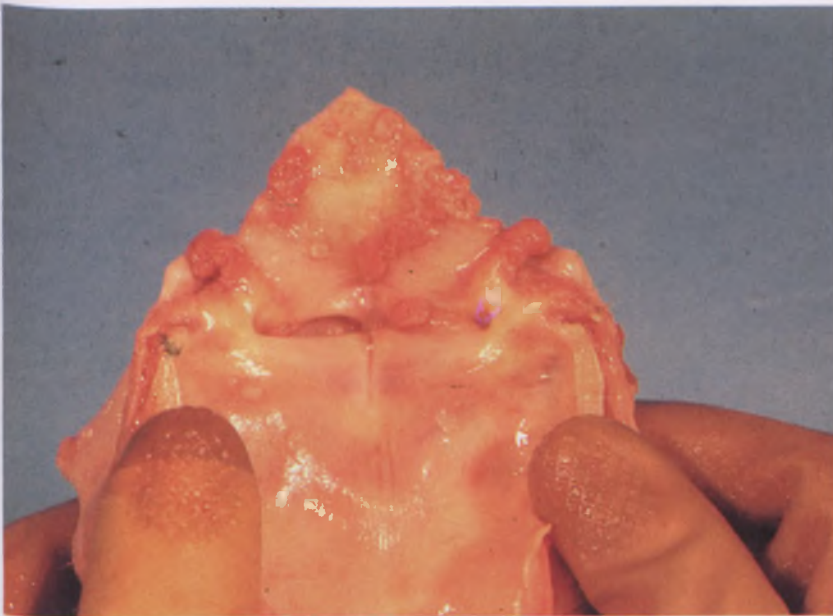

PLATE 336: PARASITIC LARYNGITIS

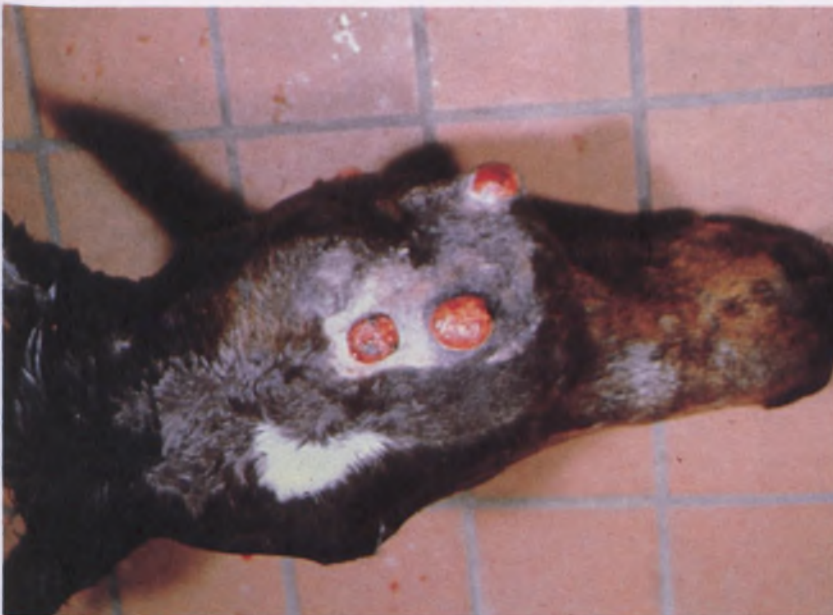The several Y shaped worms on the surface and partially buried in the mucosa of this cow's trachea are *Syngamus laryngeus*.

Dr. C. Bridges, Texas, USA



**PLATE 337: SQUAMOUS CELL
CARCINOMA**

The tonsillar tissue and mucosal surface of this epiglottis and lateral ventricles have been invaded by proliferating islands of neoplastic stratified squamous epithelium. This malignant tumor probably arose from the epithelium of the tonsil itself.



**PLATE 338: SQUAMOUS CELL
CARCINOMA OF THE
SINUS**

The surface view of this surgically prepared horse's head shows several round, reddish proliferating masses. These have all grown rapidly from inside the skull through openings made for biopsy sampling. Again histological studies are needed to identify this.

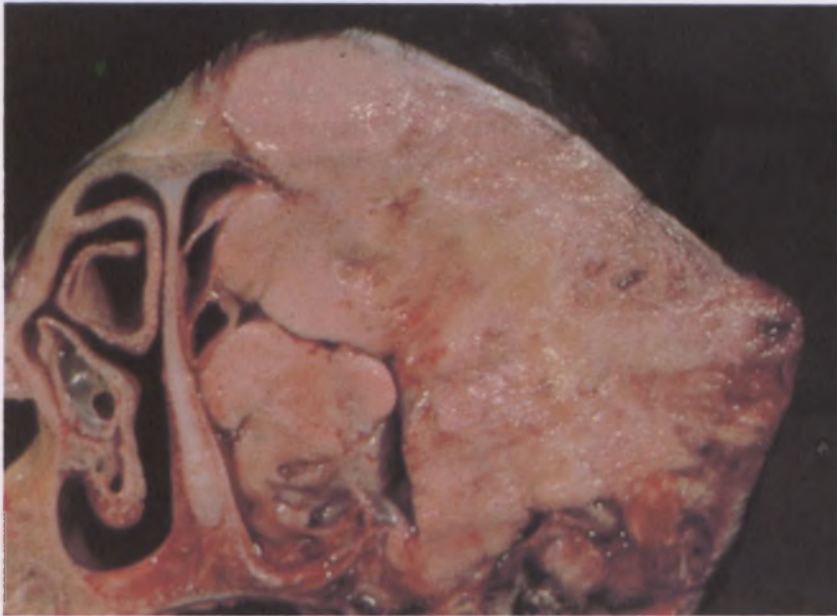

PLATE 339: NASAL CAVITY SQUAMOUS CELL CARCINOMA

The large pale masses in this cross section of a horse's head are Squamous Cell Carcinoma. It is difficult to distinguish this and many other tumors without the aid of a microscope. The bull, cat and dog are also likely animals to have this tumor.

A majority of cases may not demonstrate the bony changes.

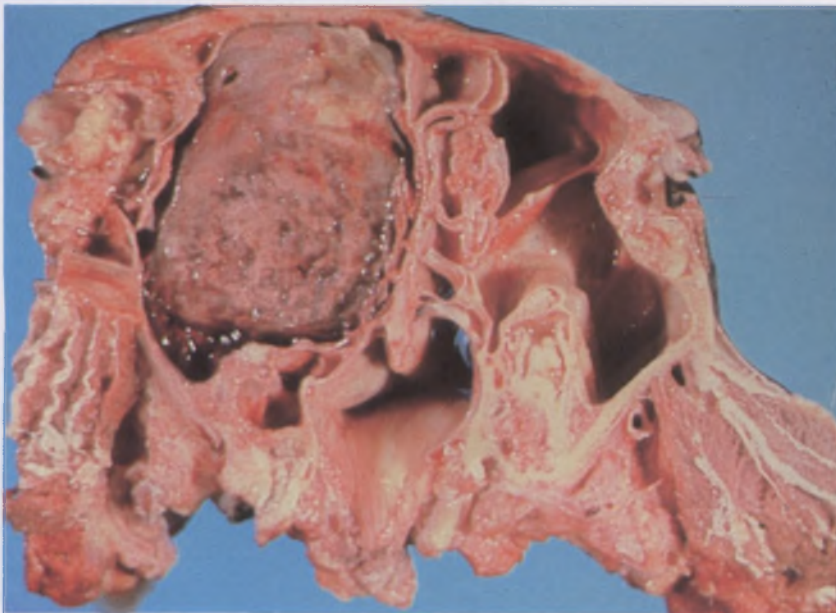


PLATE 340: NASAL CAVITY OSTEOGENIC SARCOMA

This large bloody mass with a yellow area of necrosis in one corner of the mass is quite firm and gritty when cut. It is an Osteogenic Sarcoma in this horse. The firmness and grittiness are quite suggestive of this type tumor but one needs to use the microscope to be sure. These are seen in all animal species. Even though some or a great amount of cartilage may be present in such a tumor, if a more mature neoplastic tissue of the same type is present it should be named by its most mature type neoplastic tissue. In this case, a malignant tumor consisting mostly of cartilage type tissue, but also containing some bony type neoplastic tissue should be called an osteogenic sarcoma not a chondrosarcoma.

Dr. H. Dickink, Kennelplatz 3, 200

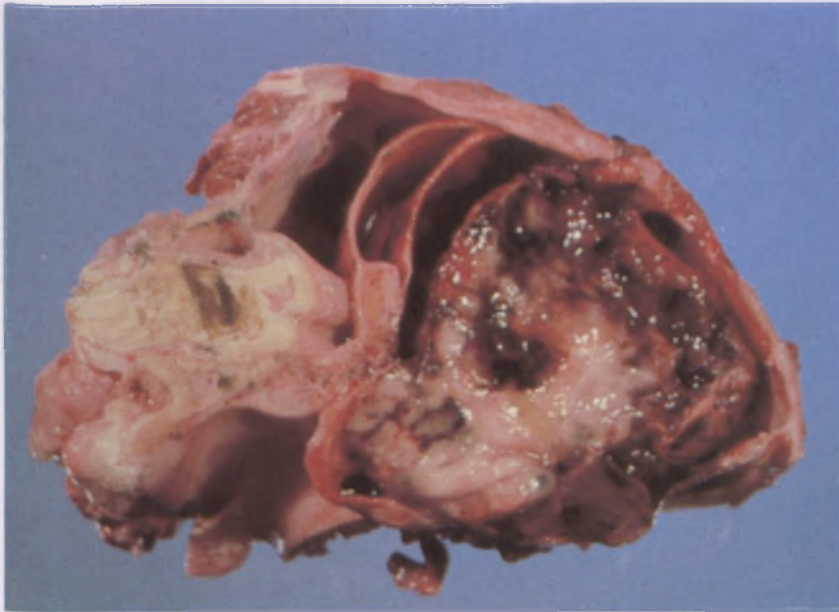


PLATE 341: NASAL CAVITY FIBROSARCOMA

The large bloody mass in the nasal cavity and sinuses of this horse is a Fibrosarcoma. It is a little different from the usually less bloody and more solid Squamous Cell Carcinomas also found in this area, but microscopic examination is usually needed to be definitive. This type tumor can be seen in most animal species.

Dr. F. Fenwick, RSA

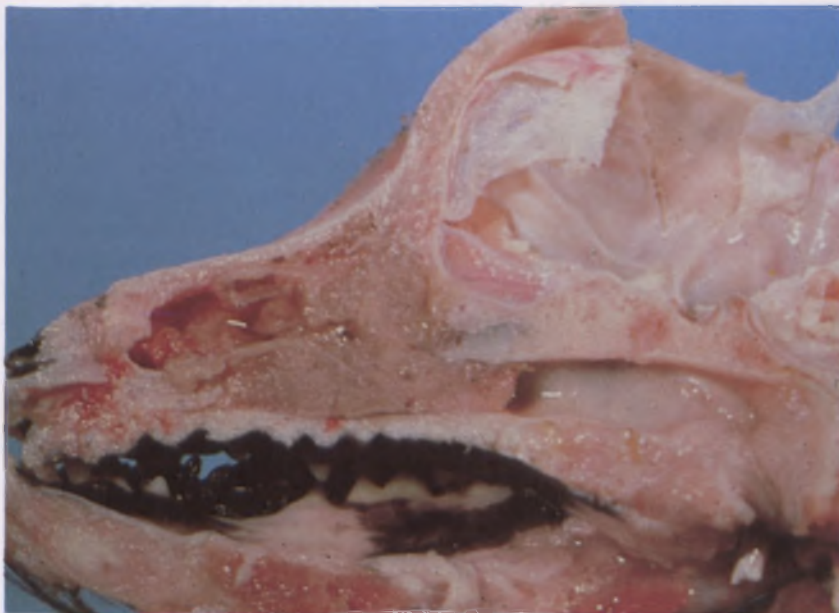

PLATE 342: NASAL ADENOCARCINOMA

The pale mass in this dog's nasal cavity is an Adenocarcinoma probably of nasal gland origin. It has caused some atrophy and curling of the turbinates cranial to it. Out of context, it is difficult to classify these tumors without histological help. The slight shiny mucoid appearance might help in this case. All animal species are subject to this tumor.

Dr. C. I. Liu, TBH&V, RDC

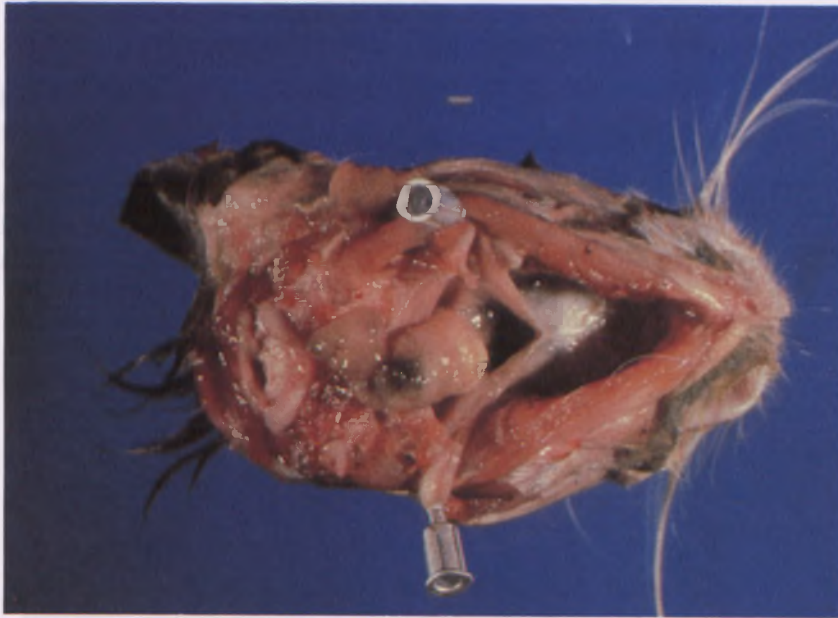


PLATE 343: NASAL POLYP

The elongated, shiny mass protruding into the pharynx of this cat is a Granulomatous Polyp from the inner ear projecting down and out the eustachian tube. They often protrude out through the external ear canal as well. Of clinical importance is that they often recur after incomplete or thought to be complete surgical removal. They have a typical connective tissue core and a more or less complete mucosal lined surface. Their cause is unknown. They have been seen with and without ear mites.

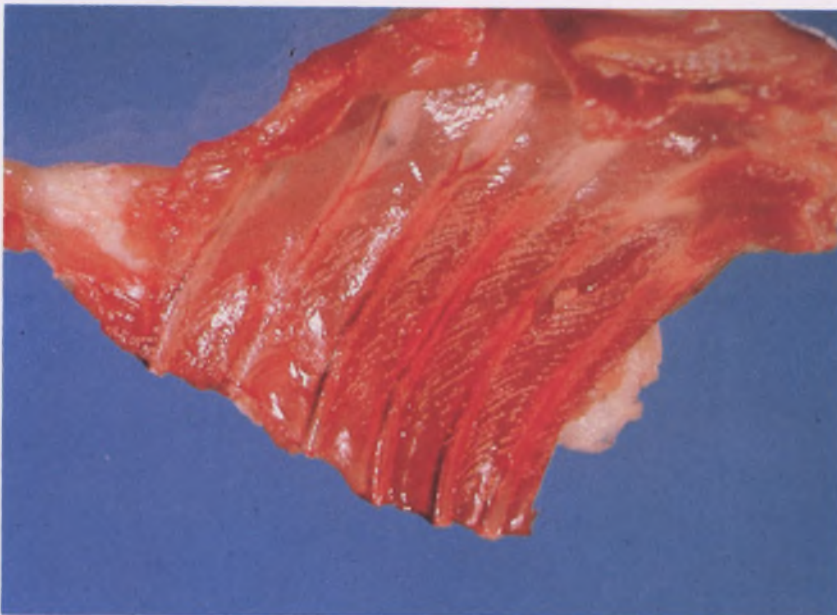
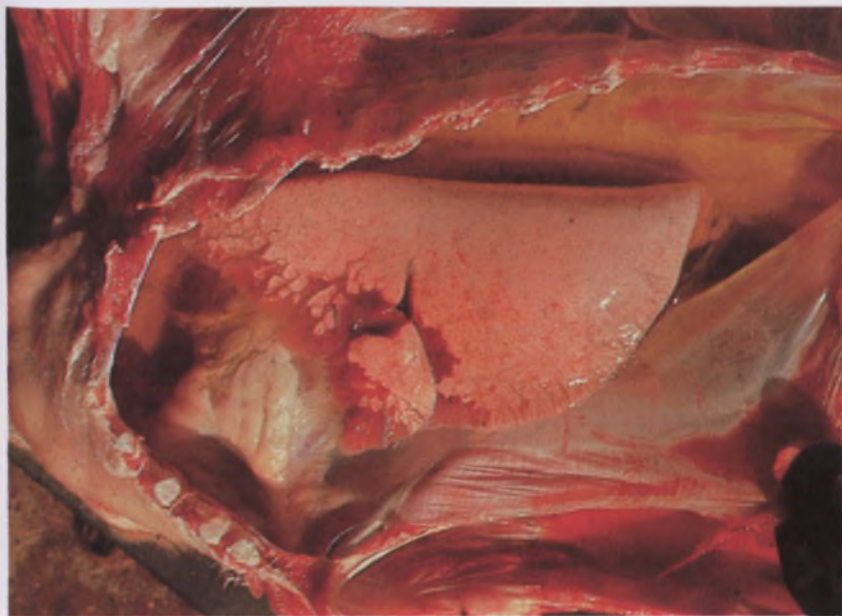


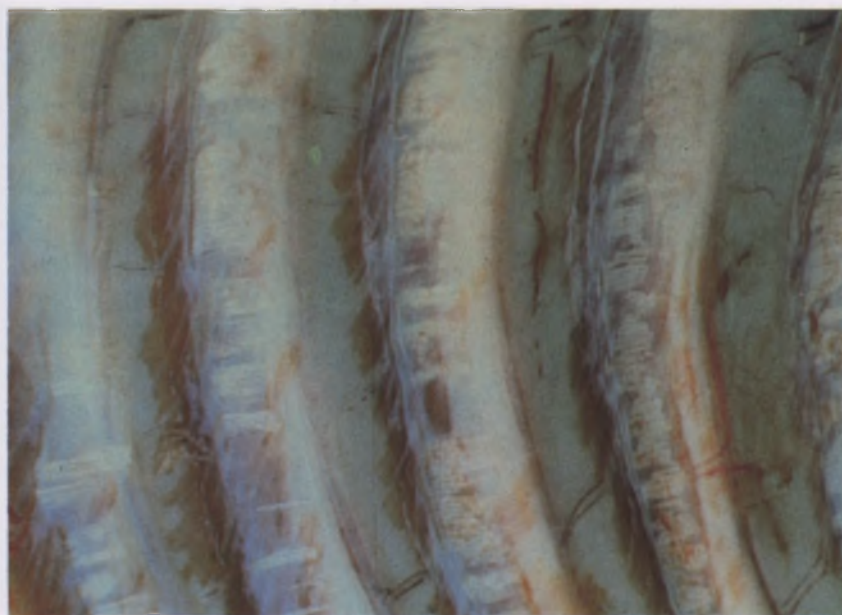PLATE 344: BARBITURATE SALT DEPOSITION

The multiple, tiny, white foci scattered on the pleura of this cat's chest in an area that is slightly more reddened than the surrounding pleura, are foci of barbiturate salt deposition. The reddened area is the result of hemolysis from the material injected into the chest cavity for euthanasia. These salt depositions are sometimes thought to be the mineral of uremic frosting but by smelling the lesion a definite barbiturate, alcohol or medicinal odor can be noticed. This is a typical artefact.

**PLATE 345: HYDROTHORAX**

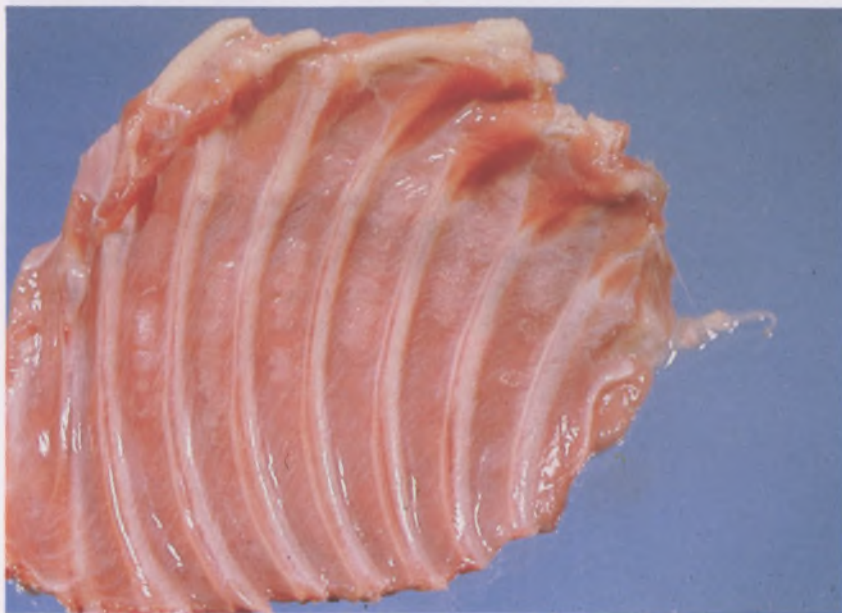
The clear fluid with some fibrin in this sheep's pleural cavity is called Hydrothorax. It is a very good diagnostic lesion, as in this case, of Heart-water, a rickettsial disease caused by *Cowdria ruminantium*. A very unique way to diagnose the disease is to make a squash preparation of the hippocampus to find the organisms in the endothelial cells. The ventral edges of the lungs are dark and devoid of air as a result of Acquired Atelectasis from the pleural fluids. The heart sac is most often filled with excess fluid as well. It was in this case.

Dr. J. A. W. Coetzer D. Sc. (Hons) FRCGS
Dr. P. Pienarr, RSA

**PLATE 346: PLEURAL MINERALIZATION (UREMIC FROSTING)**

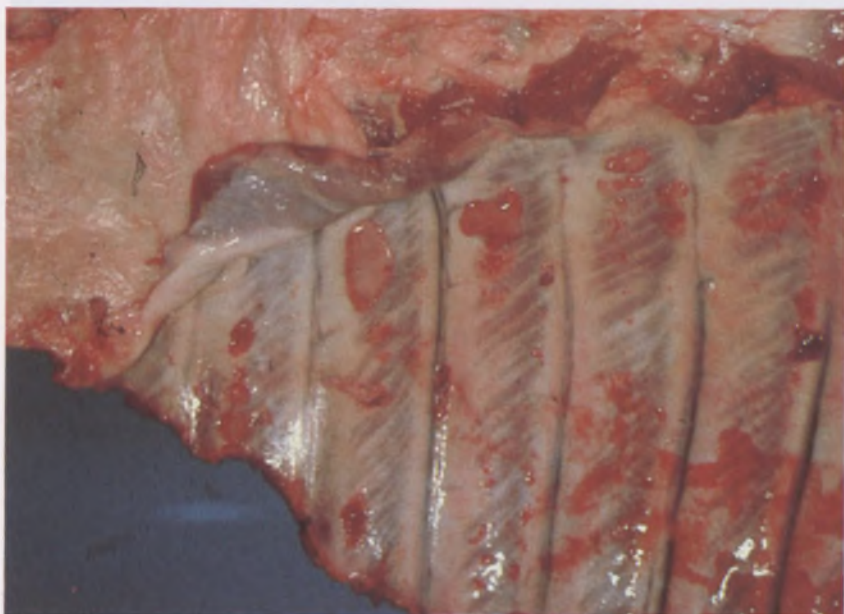The pleura between the ribs of this dog show the well marked, opaque white deposits of calcified material seen in uremia of dogs and cats primarily. It usually begins between the first two ribs and progresses caudally as the severity and duration of renal failure increases. Surprisingly this lesion may not show up for quite some time in animals with obvious renal failure, despite almost complete renal destruction grossly. This is called Uremic Frosting or Uremic Mineralization. A similar deposition of cholesterol may be seen in rabbits on a high cholesterol diet.

Dr. C. I. Liu, Taiwan, ROC



**PLATE 347: PLEURAL
MINERALIZATION**

The pleura between the ribs of this cat with chronic renal disease, has the deposition of calcium which is called Uremic Frosting. Why it is not as opaque white as in most cases is not known, possibly because of less calcium than usual.



**PLATE 348: PLEURAL
LYMPHOSARCOMA**

The distinct, red and pale, slightly elevated, rounded plaques in the pleura near the distal portions of this pig's ribs are multifocal areas of Lymphosarcoma. Although Lymphosarcoma is not very common in pigs, its location in this area is even less common. The red color higher up on the ribs is due to postmortem blood staining. Plaques like this should also make one consider Mesothelioma or even Tuberculosis at first glance.

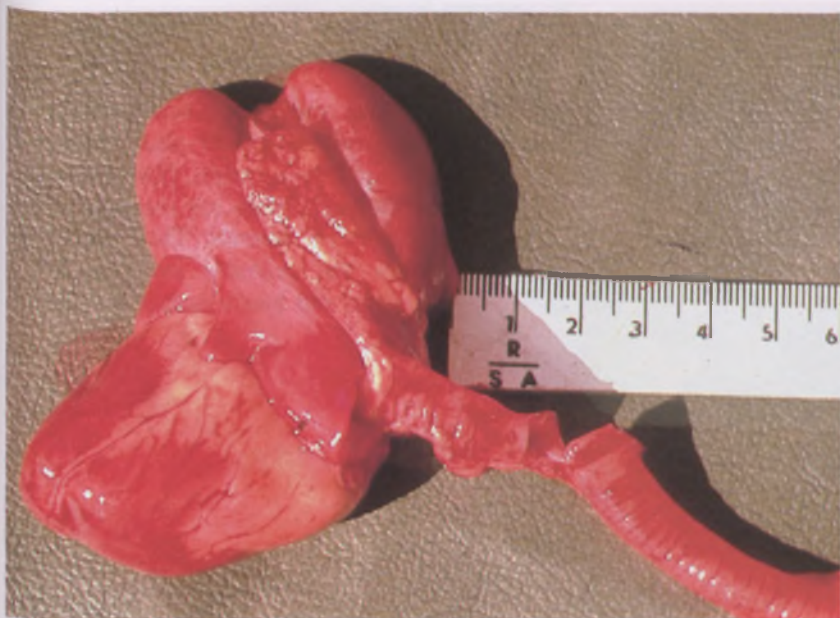

PLATE 349: PULMONARY HYPOPLASIA

This lung and heart came from an aborted lamb and one can see that either the heart is too big for the lungs or the lungs are too small for the heart. This is a case of Wesselbron's Disease, a virus disease related to Rift Valley Fever. The lungs are considered hypoplastic, a condition sometimes associated with Embryonic Brain Damage.

Dr. J.A.W. Coetzer Onderstepoort, RSA

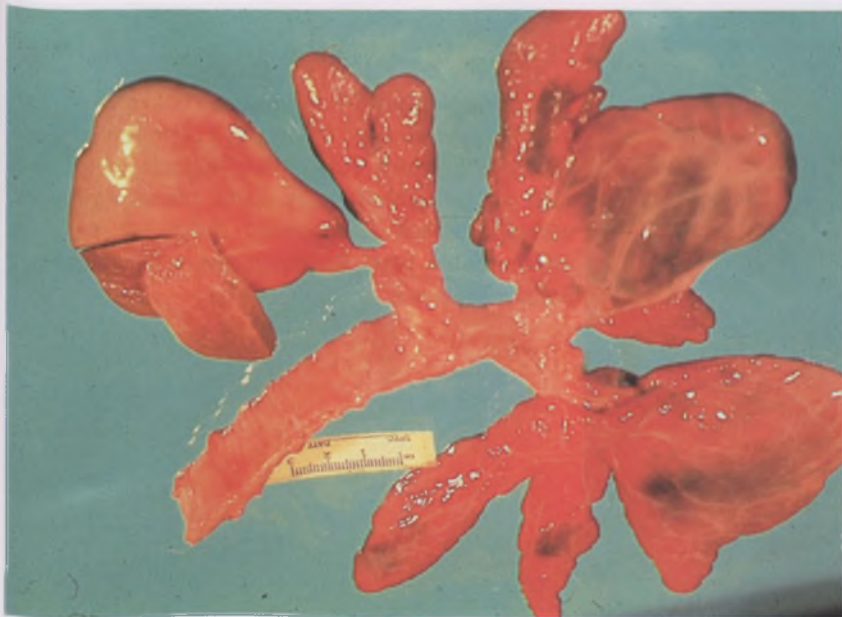


PLATE 350: IN UTERO TORSION OF THE LUNG

The cranial portion of the right cranial lung lobe in this aborted calf is firm, swollen and partially necrotic. It is the result of *in utero* torsion of the lung lobe but its cause is unknown. The rest of the lung is normal for an aborted fetus.

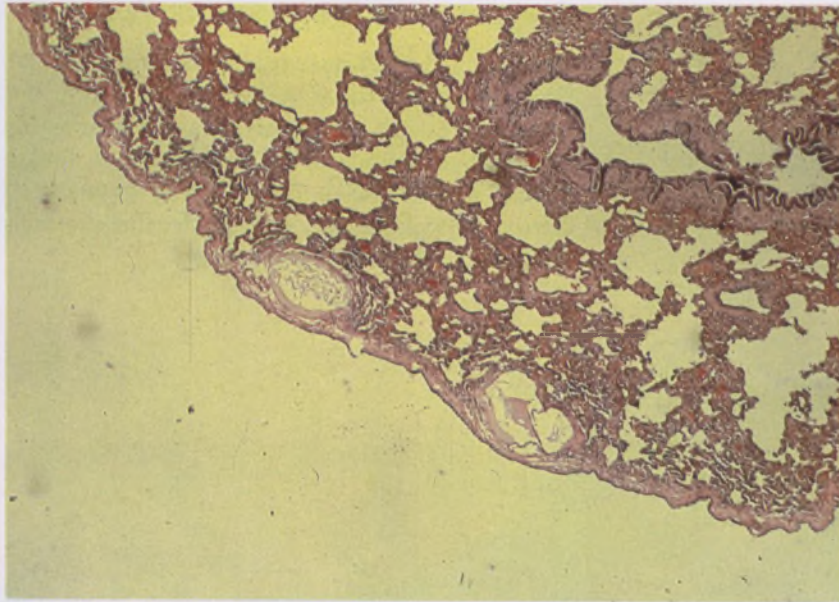


PLATE 351: DILATED SUBPLEURAL LYMPHATICS

The two spaces just under the pleura of this dog's lung contain a small amount of pink amorphous material which probably is lymph. Dilated lymphatic crypts on the lung surface are commonly seen histologically in many animals. They are of no real consequence and probably just represent a congenital defect of the lung's surface lymphatics.

Dr. A. W. Coetzee, Onderstepoort, RSA

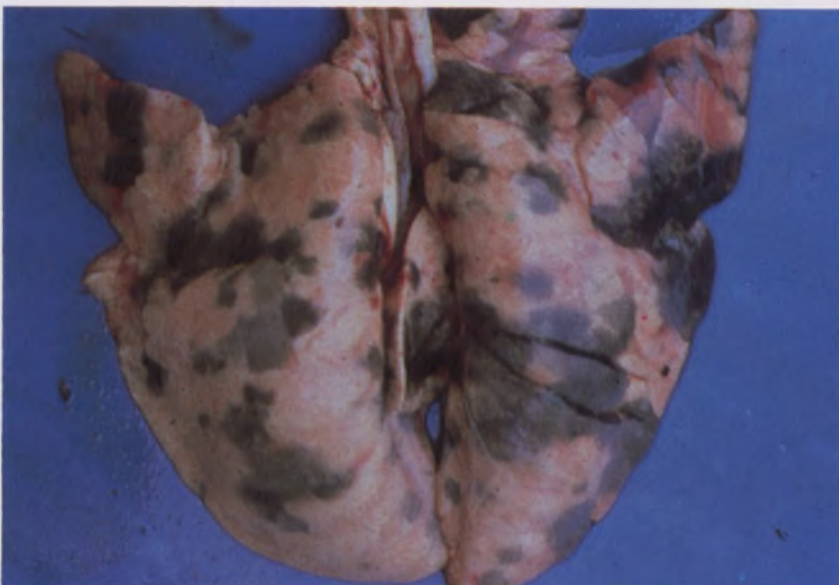
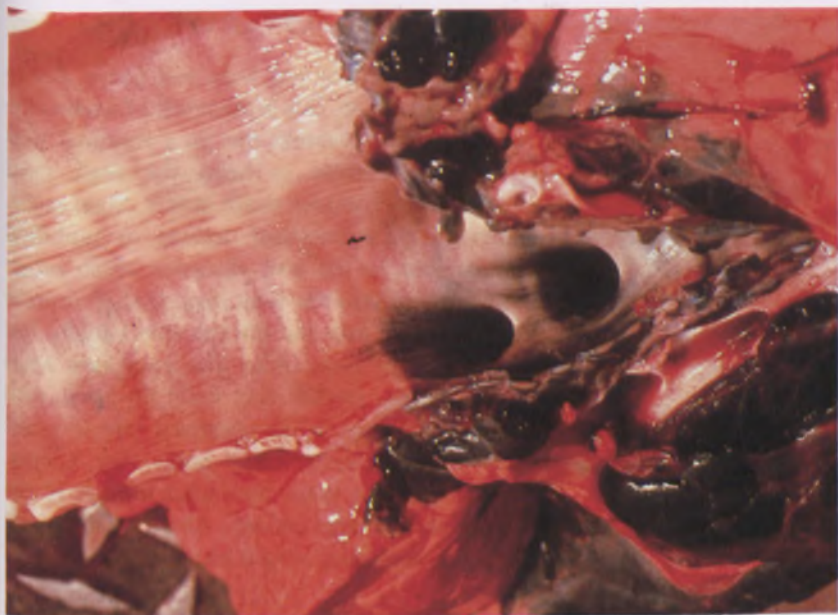

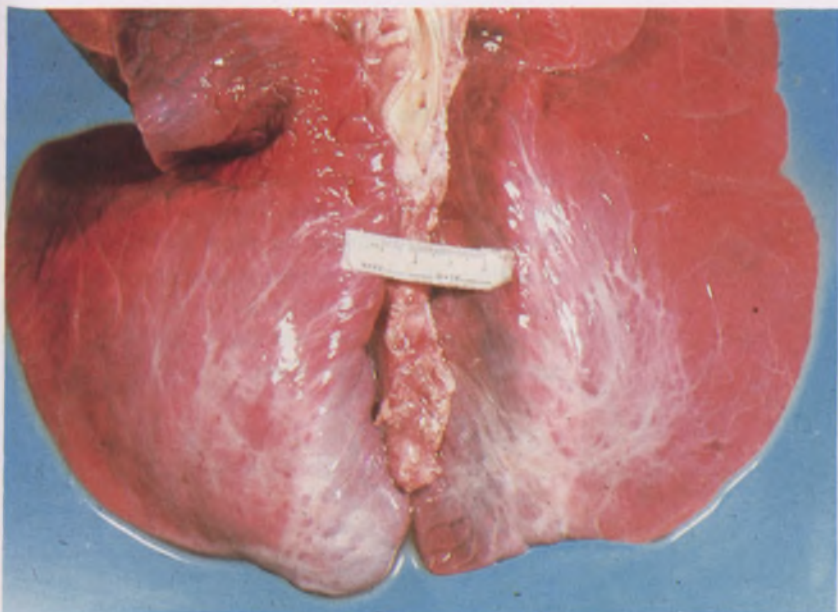
PLATE 352: PULMONARY MELANOSIS

The multiple dark to black areas scattered in this pig's lung are areas of Melanosis, a common congenital finding which may affect many other tissues such as the trachea, heart, aorta, uterus, meninges, uterus, stomach and adrenal glands. It is to be differentiated from fluke pigment and postmortem pseudomelanosis.

**PLATE 353: TRACHEAL MELANOSIS**

The well marked blackening of the trachea and associated lung parenchyma is Congenital Melanosis in this cow. It can affect a multitude of tissues. It must be distinguished from fluke pigment and pseudomelanosis which develops as the result of postmortem decomposition usually associated with the bowel.

Prof. Tustin, Onderstepoort, R.S.A.

**PLATE 354: DIFFUSE PULMONARY CONGESTION**

Just by looking one would not be sure of this diagnosis. The calf had a congenital heart anomaly which caused this diffuse, uniform congestion resulting in the lung being firm, congested and heavy. The pale white irregular thickenings of the visceral pleura on the diaphragmatic lobes are normal increased fibrous areas seen in cattle, sheep and horses primarily.

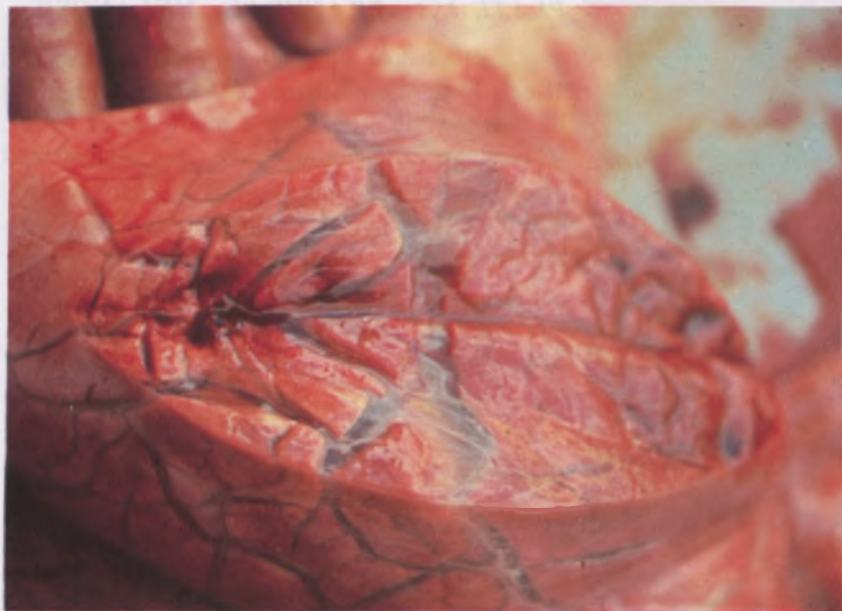


PLATE 355: PULMONARY EDEMA

Grossly this cow lung was large and heavy due to the fluid in the lung. This is the result of an anaphylactoid type lung reaction due to a ruptured liver abscess. This is close to being the single most common cause of sudden death in N.Y. State cattle. Apparently, gastrointestinal lesions or umbilical infections lead to the liver abscesses which subsequently rupture into the vena cava. If they rupture while small they may not kill the cow initially but just sensitize the cow. After the vena cava heals over, the abscess pocket may build up again with a secondary rupture in the sensitized cow to result in this severe overwhelming pulmonary edema. Cattle can also die from the initial rupture if the abscess pocket is large enough. Abscess debris may be found in pulmonary vessels histologically.

Prof. Tustin, Onderstepoort, R.S.A.

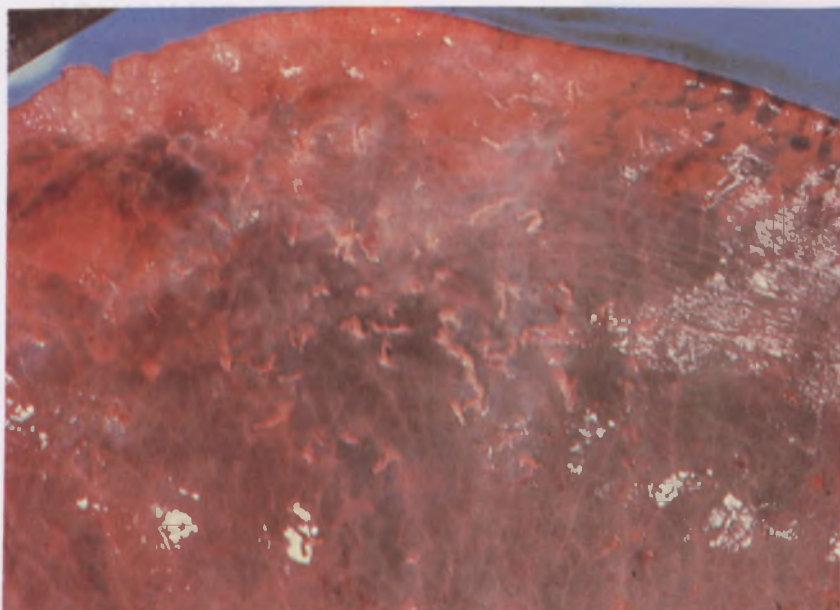
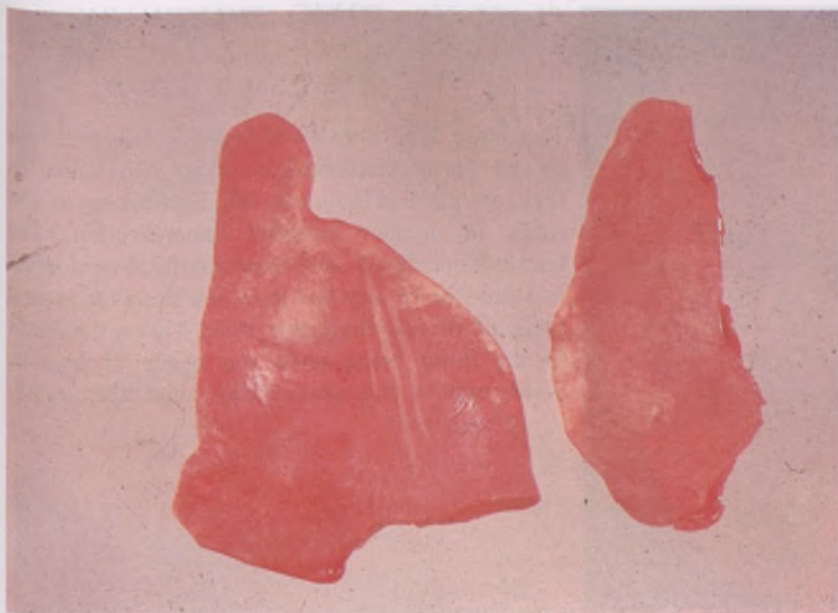


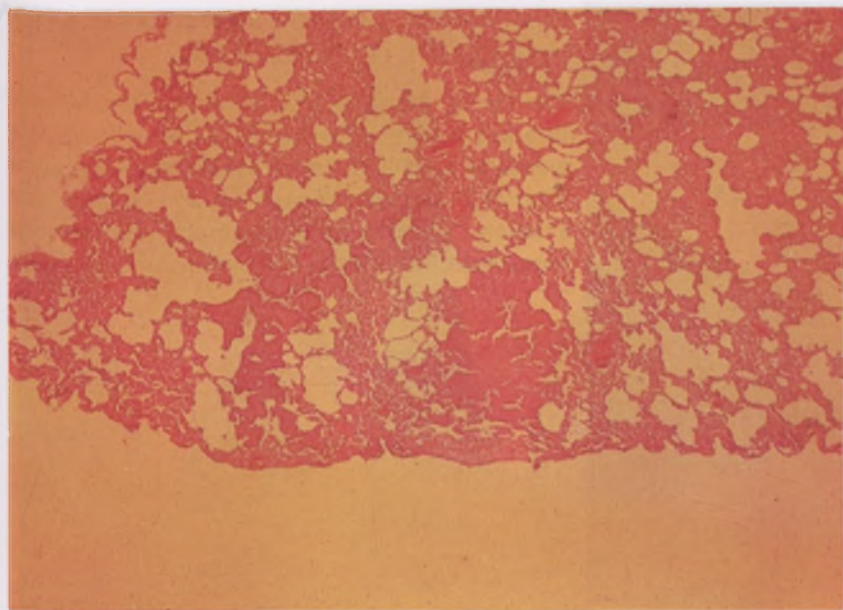
PLATE 356: FIBROUS TAGS OF THE LUNG

These multiple irregular thread like tags attached to this horse lung are small pieces of connective tissue, commonly seen there especially on the ventral half of several lobes. Their cause is unknown. They are quite similar to those on the liver and sometimes the adjacent peritoneum of the diaphragm. They have been thought by some to be caused by parasite migrations, but this is doubtful as these can be seen in newborn foals.



**PLATE 357: FOCAL FIBROSIS OF
THE LUNG**

The several pale streaks and the several pale slightly raised areas on this dog's lung surface are firm and are most common on the surface of the left cranial lung lobes. Their cause is unknown, but it is doubtful if they are related to parasites as some suggest. They are mostly seen in beagle colony type dogs. Histologically they consist of discrete foci of connective tissue, pleural and alveolar lining cell proliferations. It has been seen in the horse.



**PLATE 358: FOCAL FIBROSIS OF
THE LUNG**

This is the microscopic appearance of focal fibrosis seen in dogs and horses. They consist of connective tissue and alveolar lining cell proliferations just under the pleura. Their cause is unknown.

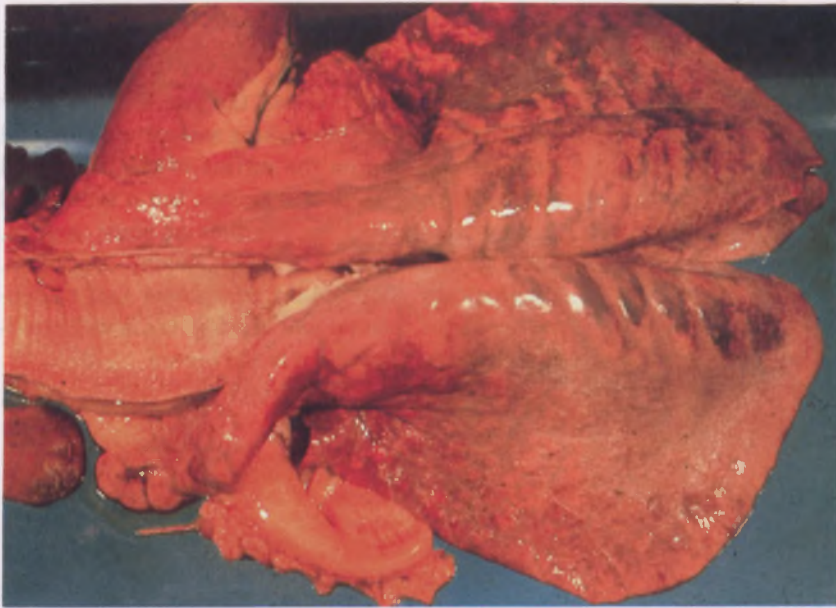


PLATE 359: TOXIC PULMONARY MINERALIZATION (EXCESSIVE VIT. D)

This horse lung shows well marked rib impressions on its dorsal diaphragmatic lobes. On palpation they are firm in between the impressions as the result of distinct localized mineralization. The tracheal mucosa is also mineralized. Several small foci can just be seen and more felt along the ventral edges of the diaphragmatic lobes. This is the result of the horse being given too much Vitamin D. Some tumors and uremia can cause this lesion.

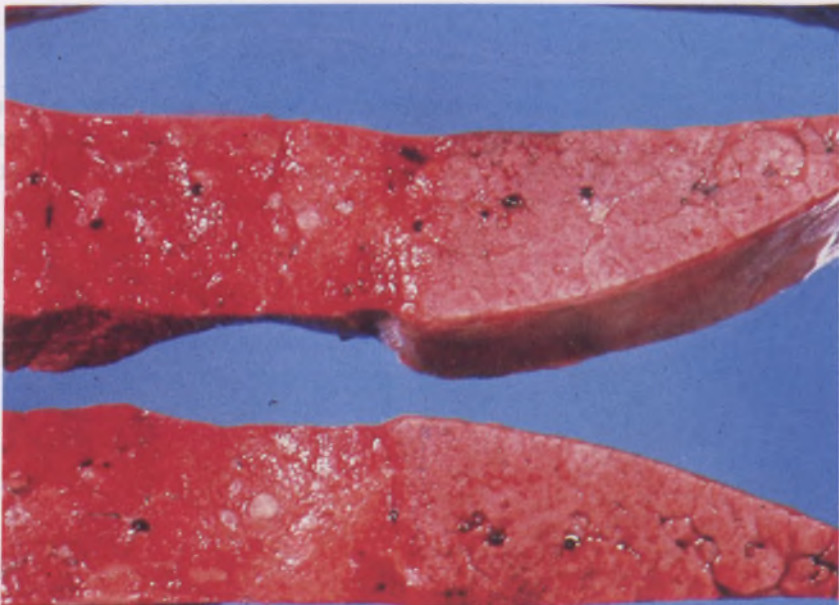


PLATE 360: UREMIC MINERALIZATION OF THE LUNG

The tip of this lung lobe is swollen, slightly dry, firm and is gritty when cut. It is from a horse with uremia as a result of chronic renal disease. Excessive Vitamin D and some tumors can also result in such a lesion. There is some suggestion that vascular impairment helps cause the lesion in these cases.

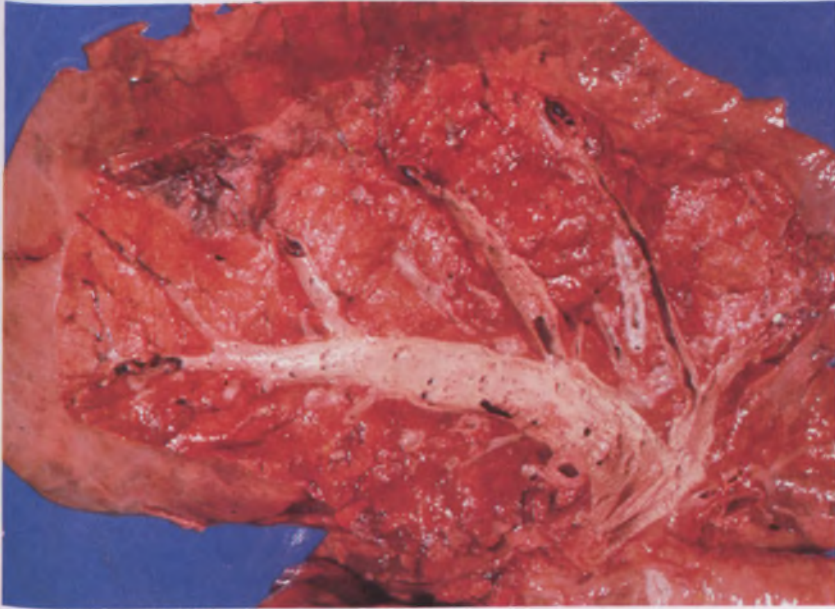


PLATE 361: MULTIPLE PULMONARY ARTERY THROMBOSIS AND MINERALIZATION

The pulmonary artery has been opened on this lung and a top portion removed for photographic purposes. The intima of the first part of the artery is roughly crinkled and opaque white from mineralization. The six lesser branches coming off of it are not mineralized but a definite thrombus is blocking each vessel in this horse's lung as the result of chronic renal failure with uremia. The uniform involvement of these six vessels suggests that the thrombi developed *in situ* and were not embolic. These were palpable thrombi grossly but infarcts were not apparent attesting to the ability of the lung, with its dual blood supply, to resist infarction.

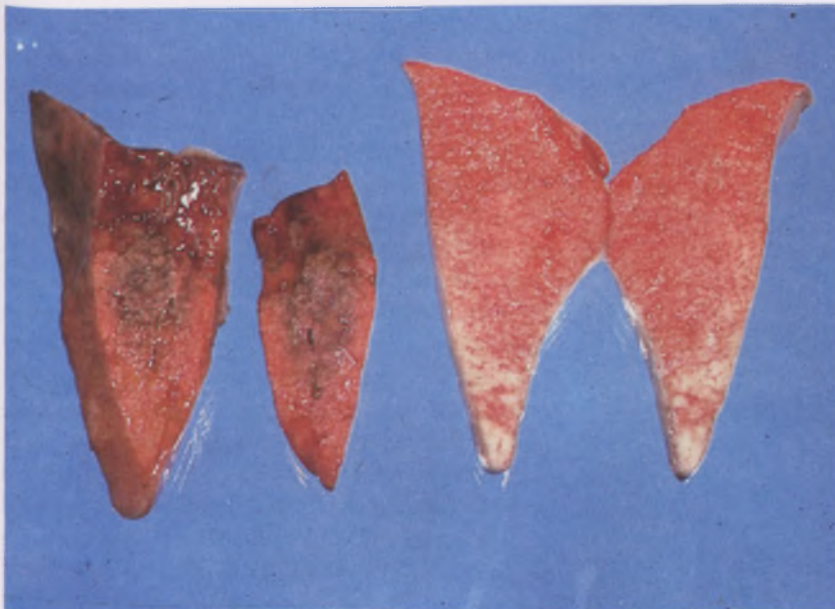

PLATE 362: METABOLIC PULMONARY MINERALIZATION

The two dark pieces of lung are from scattered affected foci of the ventral free edges of the diaphragmatic lobes and the two lighter pieces from the dorsal diaphragmatic lobes. These two areas are the ones most likely to be affected by this uremia, or vitamin D toxicity. In this case, this horse had a myeloproliferative disease which resulted in a metabolic problem called Pseudohyperparathyroidism. This problem has been seen with other tumors such as lymphosarcoma in several species and adenocarcinomas of the anal sac glands of dogs. Some vascular compromise is thought to play a role as to where the mineralization occurs.

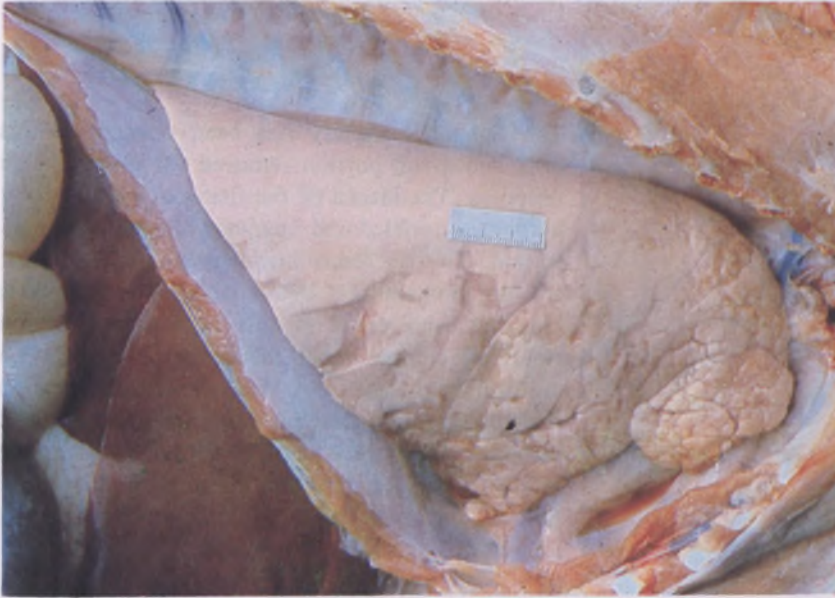
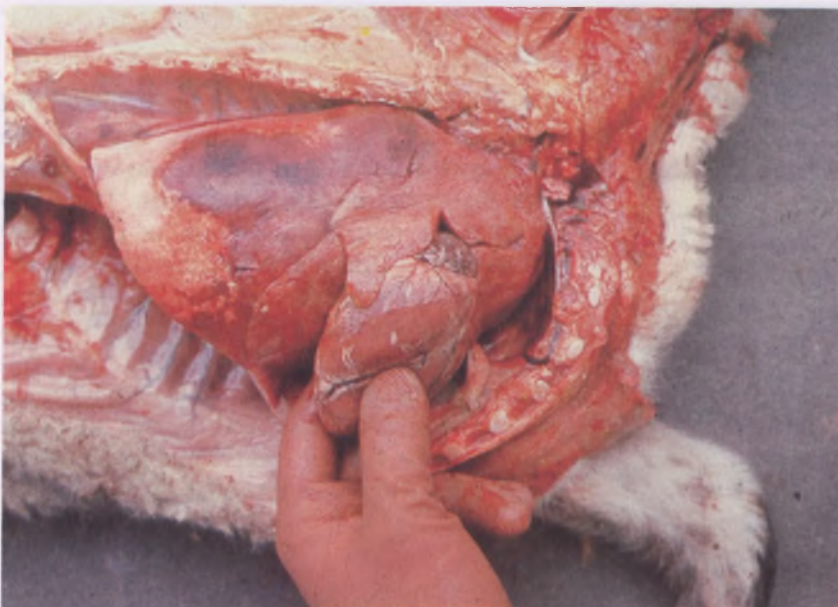


PLATE 363: ANEMIC LUNGS

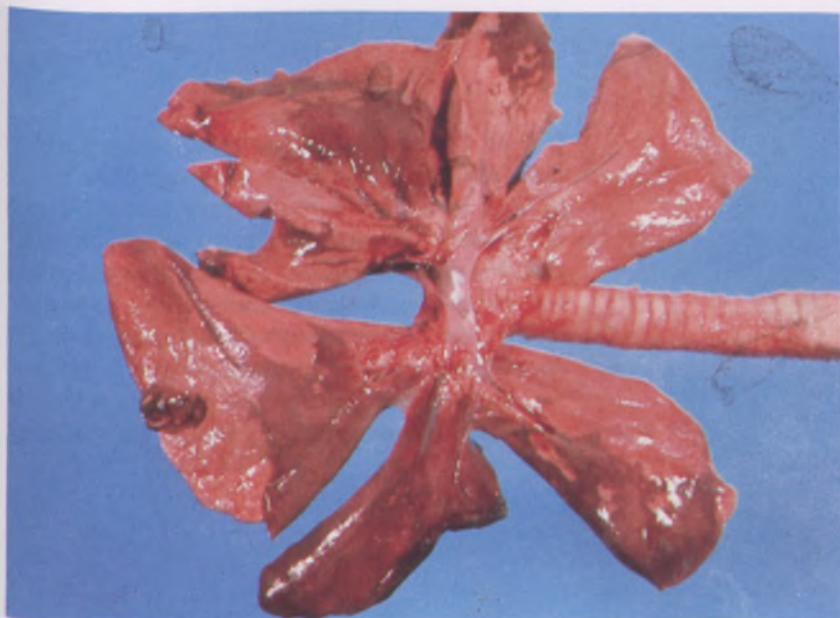
The lung is slightly puffy and very pale. It is normal from a well bled out pig. Just a few slightly depressed areas are seen of incomplete postmortem atelectasis. Lungs like this can be seen in pigs that bled out for any reason including gastric ulcers.

Dr. J. Lay, Cornell, USA

PLATE 364: INHALATION (FOREIGN BODY) PNEUMONIA



The heart is being held up with the thumb pointing to a small focal area of Zenker's necrosis in the myocardium. Over 75% of the lung shown is dark and firm as the result of Inhalation Pneumonia. This was the direct result of Zenker's degeneration of the muscles of deglutition which allowed inhalation of foreign material. This is more common in veal calf operations where commercial milk replacers are lacking in enough Vit. E or Selenium. In lambs, foals or beef calves it usually is due to an Antivitamin E or Selenium factor that probably develops in spoiled or water soaked feed as a result of microbiological production. The Vit. E or Selenium is thought to be still present but just made unavailable to the host by this microbiological product. The suspected agent has not been isolated yet. The suspected feed can still be used if a supplement of Vit. E or Selenium is given to counteract its affect.



Dr. C. Wimberley, Cornell, USA

PLATE 365: ACQUIRED ATELECTASIS

This whole lung from a dog is more collapsed than normal and the scattered darker red foci along with the darker entire left middle lobe are Atelectatic. This lung collapse is due to the presence and rupture of the discrete nodule seen near the edge of the left diaphragmatic lobe. This turned out to be a solitary Mesothelioma which had eroded through the pleura allowing the pneumothorax to develop. Some doubt the tumor's definitive classification.

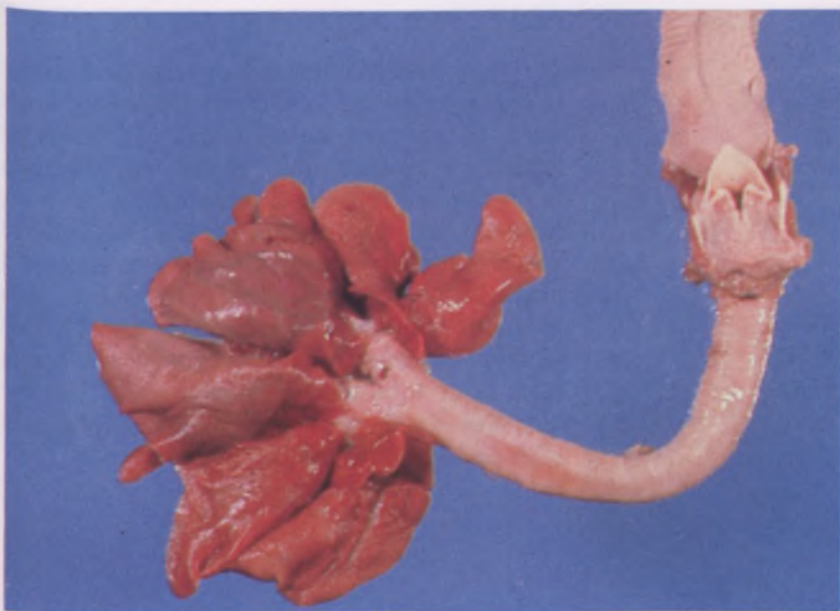


PLATE 366: ANESTHETIC GAS MACHINE ATELECTASIS OF THE LUNG

The tongue and trachea may be too large for this animal or the lungs may be too small. In this case it is an example of the lungs being more collapsed than normal. After seeing several of these in necropsy room cases from dogs, cats, goats and other species, all with the same history, it was decided to name it the above as they were on the gas machine for anesthesia. The lung is more collapsed than is normal for euthanasia cases and even for most acute atelectasis cases. It is thought that after being on the gas machine for a prolonged period, several hours at least, that the metabolizable gas replaces all the air including its 80% nonmetabolizable nitrogen. At the end of surgery, if the lung is not forcefully aerated with air, not just oxygen, then the residual air spaces do not get their 80% nitrogen content. If in this case respirations are weak then the animal will use up the residual space oxygen or other metabolizable gas and die. Commonly, the animal may die for no obvious reason after surgery and this may be the only lesion seen.

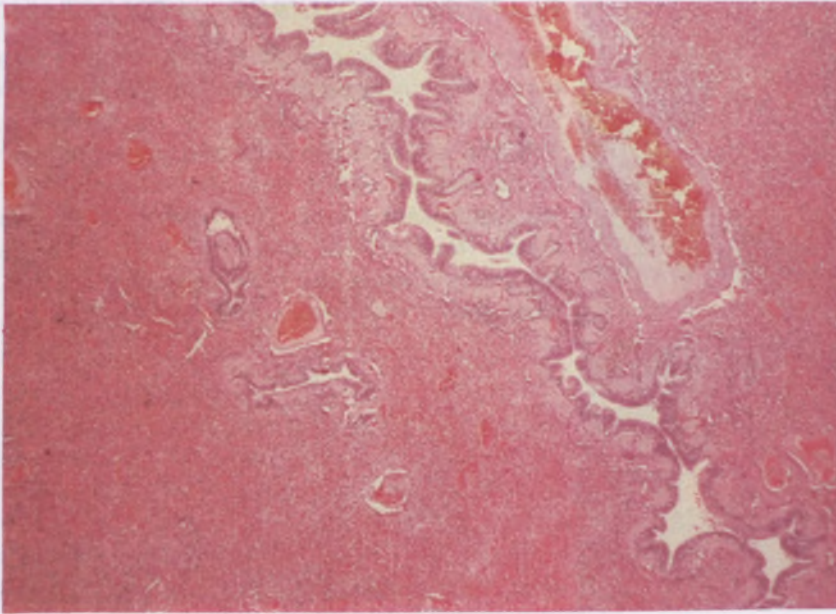


PLATE 367: ANESTHETIC GAS MACHINE ATELECTASIS OF THE LUNG

Out of context, this is just severe collapse of the lung, Atelectasis, and many things can cause it such as fluid or air in the pleural cavity. In this case it is the result of metabolizable gas being completely absorbed from the residual air space after the animal was on an anesthetic gas machine long enough to replace the 80% nonmetabolizable nitrogen in the air of these spaces with the metabolizable gas used for anesthesia or even oxygen itself. It is seen in dogs and cats primarily but also in other species.

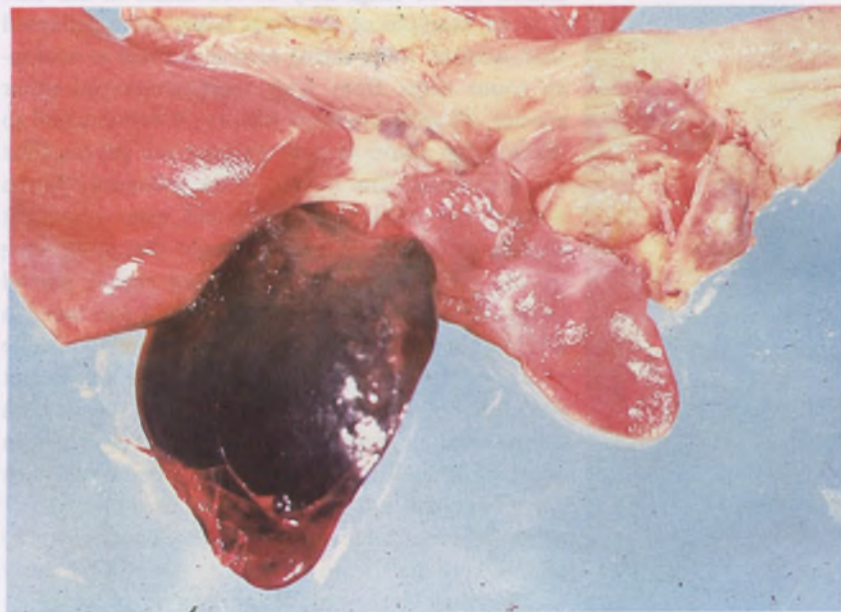
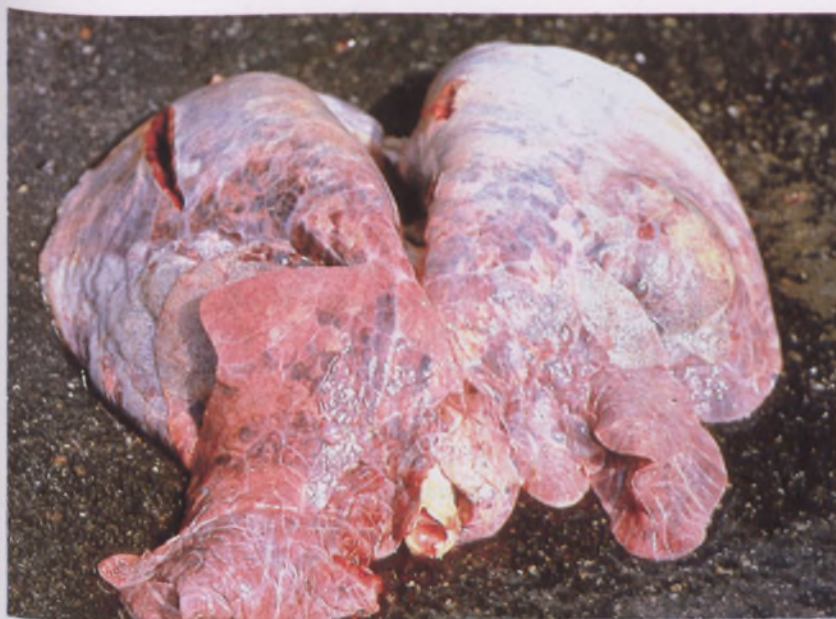

PLATE 368: PULMONIC INFARCTION

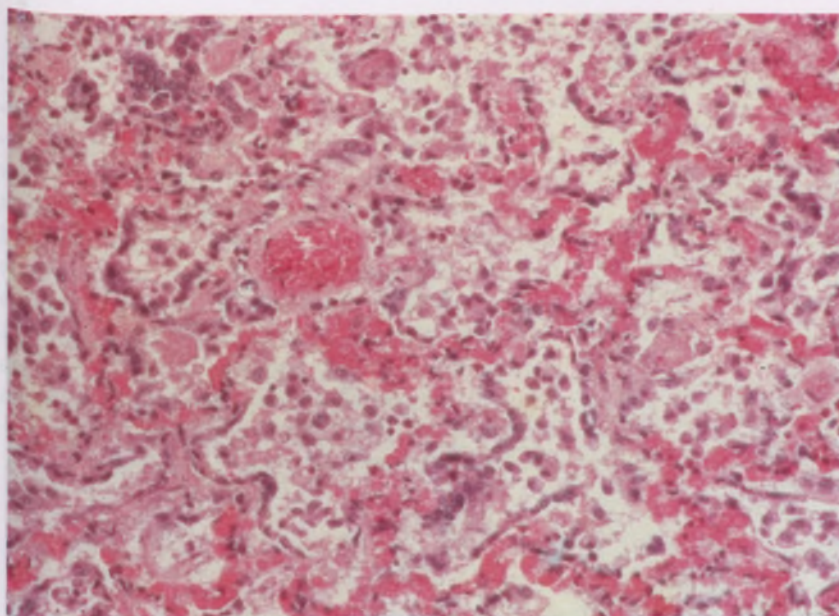
The dark discoloration and swollen, firm nature of the right middle lobe of this dog's lung is the result of the lobe being twisted and becoming infarcted as a result. Most of the time this lesion is the result of trauma, thoracic surgery, or pneumothorax but there are enough cases without the above factors in an animal's history to make it a puzzle as to the cause. The twisting of the lobe results in both blood supplies being compromised so that lung infarction in this type of situation is more likely to occur. It should be noted that the lung does not infarct commonly probably because of its dual blood supply.



Dr. R. M. Kenney, Pennsylvania, USA

**PLATE 369: PROLIFERATIVE
PNEUMONIA**

The lungs of this adult cow are enlarged, heavy and firm where emphysema is not present. It is a diffuse pneumonia and causes an acute dyspnea usually in a few animals but most of the animals affected die. Lesions are not seen elsewhere in the animal except for mediastinal lymph node and subcutaneous emphysema. It is usually noted in cattle 24 hours or so after being changed to a new and better pasture, or after a new green feed is given. It can be reproduced experimentally in cattle by a chemical, DL-tryptophane put into the rumen, and or by the forced inhalation of the higher oxides of nitrogen; naturally it is caused by feeding moldy sweet potatoes or *Crotalaria* seeds, by ingestion of nitrogen rich swine manure with feed and in calves by secondary effect of chronic bronchopneumonia. Paraquat poisoning causes a similar lesion in man. Histologically these are all characterized by the proliferation of the alveolar lining cells with and without hyaline membrane formation. It is treated successfully in most cases by high doses of atropine, $\frac{1}{2}$ to 1 gram per day for 3-4 days, an exceptionally high dose but it works. A similar lesion is seen in goats feeding in limed areas. It is seen in pigs and horses eating moldy sweet potatoes or *Crotalaria spp.* seeds. While many cases have much emphysema as in this case, many have none at all.



**PLATE 370: PROLIFERATIVE
PNEUMONIA**

This histological appearance of Proliferative Pneumonia is quite typical for most cases in cattle and in fact for all species with the lesion. It shows a slight to moderate proliferation of alveolar lining cells (Type II Pneumocytes) around most alveoli. Some mononuclear cells and fibrin are in the lumen of the alveoli. The stromal capillaries are congested but there is no appreciable stromal inflammatory response. It is a diffuse lung lesion and not limited to the vicinity of a parasite, foreign body or area of discrete pneumonia, for if this reaction was so limited it should be called an Adenomatoid reaction. Fetalization is another term used for this alveolar lining cell proliferation.

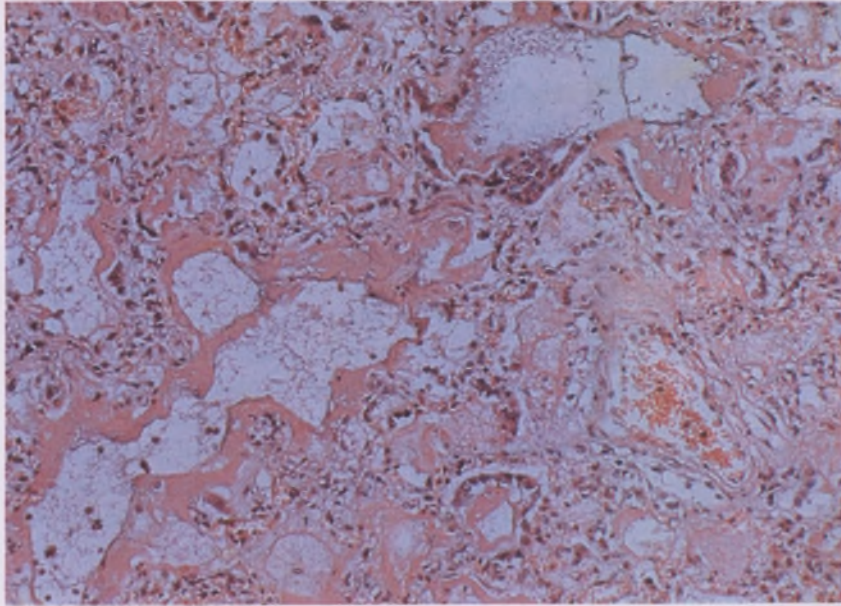


PLATE 371: HYALINE MEMBRANE FORMATION

This is an early lesion of Proliferative Pneumonia and consists primarily of a scattered mononuclear cell increase and the formation of a pink fibrillar material called Hyaline Membrane. It is not seen in all cases, probably in only 50% of the cases, or less. These cases are often surprisingly responsive to atropine therapy in massive doses, ½-1 gram per cow for 2-3 days. The exact cause is still not known but a toxic factor is usually involved. Cattle are known to inhale 80% of their eructated rumen gases. It is thought that one way the lesion can occur is when toxic substances are produced in a cow's rumen. It is also thought that in the nonruminant, the elimination of toxic substances via the lungs may also play a role, as in Moldy Sweet Potato poisoning in pigs. It is also thought that Hyaline Membrane disease in children would benefit from high doses of atropine.

Similar lesion in man. Histologically there are all characterized by the proliferation of the alveolar lining cells with and without hyaline membrane formation. It is treated successfully in most cases by high doses of atropine, ½ to 1 gram per day for 2-4 days, an exceptionally high dose but it works. A similar lesion is seen in goats feeding in limited areas. It is seen in pigs and horses eating moldy sweet potatoes or Cornish pig roots. With many cases have been reported as in this case many

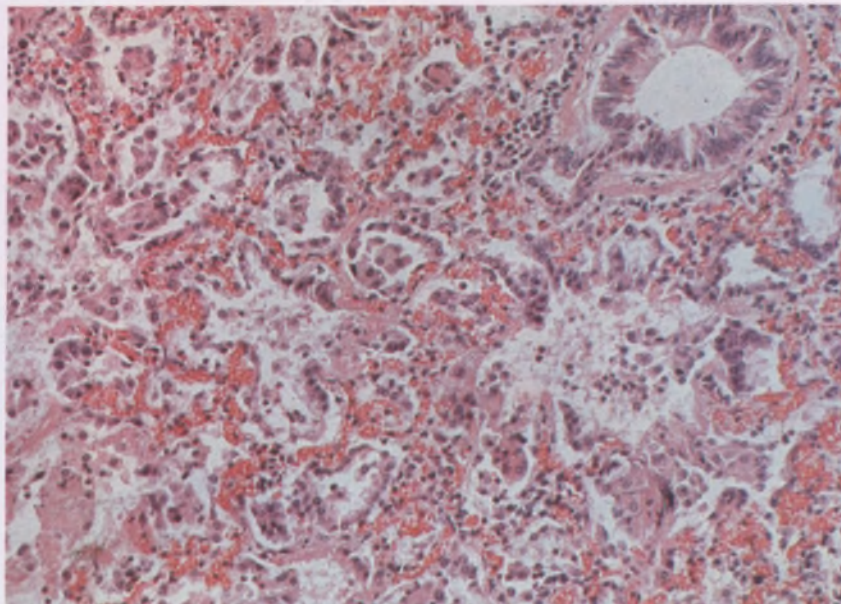


PLATE 372: PROLIFERATIVE PNEUMONIA

This is a more chronic case of Proliferative Pneumonia showing the marked alveolar lining cell proliferation that typifies the disease. Its glandular appearance once allowed one author to call it Adenomatosis but this term was already preempted for a specific virus disease of sheep with the same lesion. Another commonly used name for the disease is Atypical Interstitial Pneumonia, but it is very typical grossly and microscopically and is primarily an alveolar lining cell reaction not an interstitial one. *Perilla* spp., a common fern in some areas is also a suspected cause of this disease.

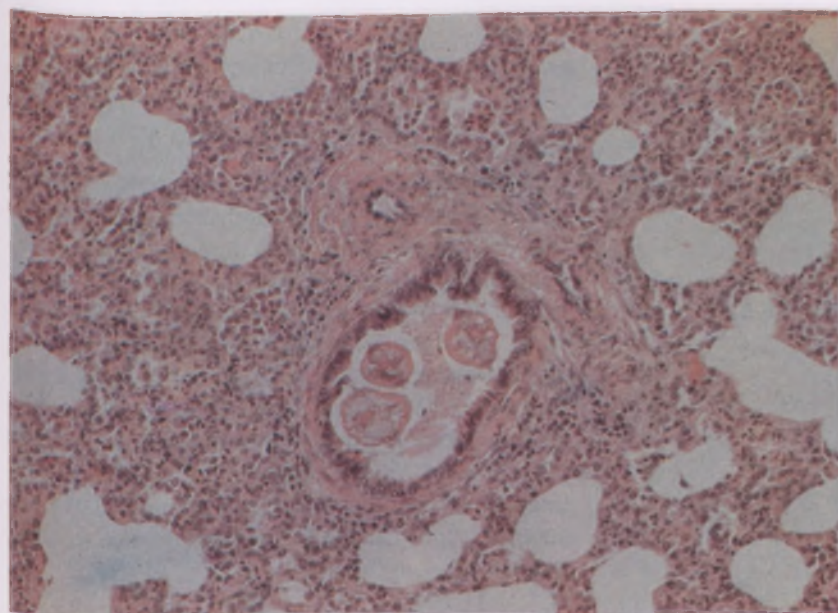
Dr. R. J. Panciera, Oklahoma, USA



**PLATE 373: PROLIFERATIVE
PNEUMONIA (SWINE
MANURE RELATED)**

This is a young adult cow's lung which is diffusely enlarged, firm, wet and heavy. Most of this herd of young heifers were affected almost at the same time, and after several died the farmer had the remainder slaughtered. The airways were washed out, and numerous larvae, most with lateral alae were obtained. These were identified as ascarid larvae. In the few scattered outbreaks over the U.S. all have been associated with young cattle eating swine feces, the probable source of the nitrogen suspected to be causative. Histologically a typical proliferation of alveolar lining cells can be seen in these lungs and in addition, in cases of Proliferative Pneumonia associated with the animals eating swine feces, as in this case, ascarid larvae can be found in the tissues.

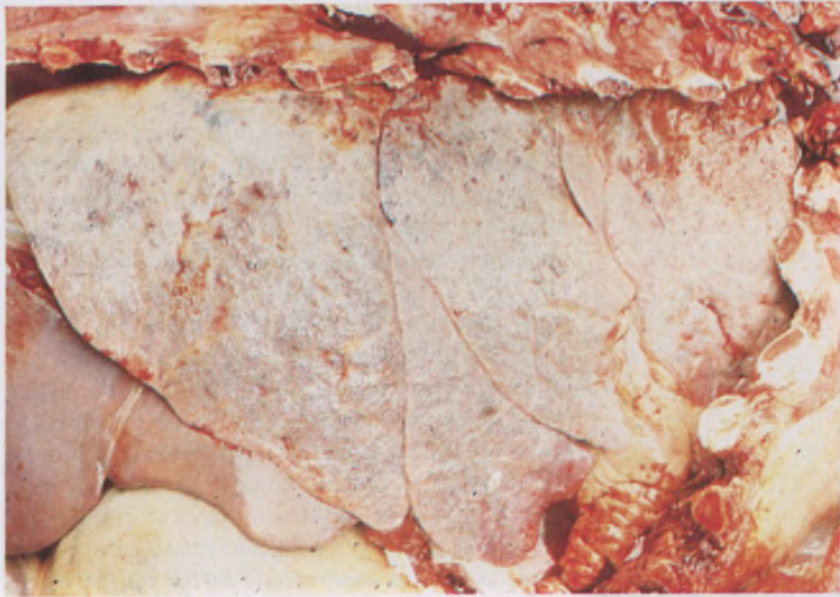
Dr. H. S. Smith, Georgia, USA



**PLATE 374: PROLIFERATIVE
PNEUMONIA (SWINE
MANURE RELATED)**

Scattered well marked Proliferative Pneumonia can be seen around this bronchiole of a cow. Three cross sections of swine ascarid larvae can also be seen in the airways themselves. This is an example of the Proliferative Pneumonia that young cattle usually get by eating pig manure for their source of nitrogen, which probably plays an important etiological role in some cases of this disease. It is not the worms themselves that cause it, they are just an indicator that the cattle have eaten swine manure. These worms will not mature in the cattle.

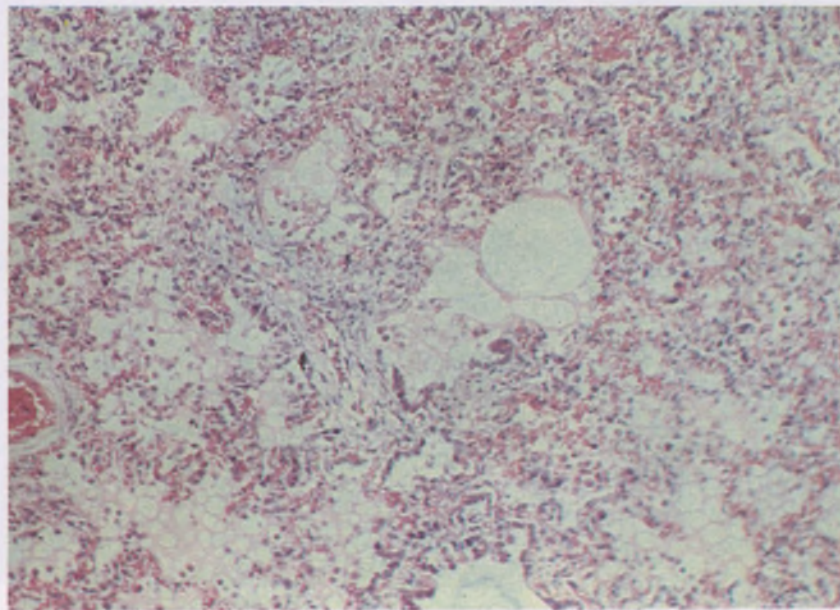
Dr. J. Peckham, Georgia, USA



Dr. C. I. Liu, Taiwan, ROC

**PLATE 375: PROLIFERATIVE
PNEUMONIA-MOLDY
SWEET POTATO (IPEMEANOL
RELATED**

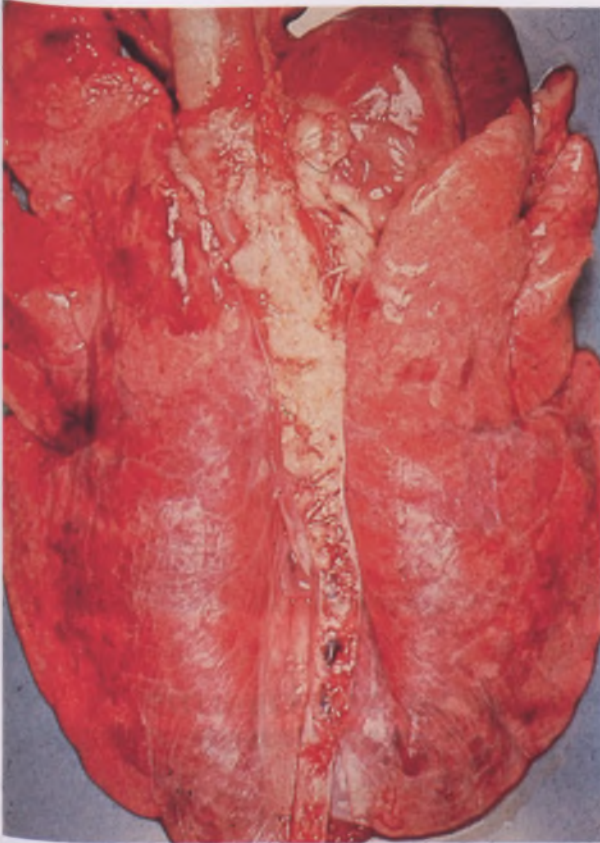
This diffusely emphysematous lung is firm, wet and heavy, it is from one of a group of cattle in Southern Taiwan that ate moldy sweet potatoes. Histologically it is an acute Proliferative Pneumonia. The original work on this problem involved pigs in the southern U.S. An active ingredient called Ipemeanol was isolated from the mold growing on moldy sweet potatoes. It has subsequently been shown that the material if eaten or injected intravenously will cause the lung lesion in swine, cattle and horses. This suggests that the lesion may indeed be caused by eructation with subsequent inhalation at least in the ruminant, but that in nonruminants as well as ruminants themselves it may be caused by the elimination of this substance through the lungs.



Dr. C. I. Liu, Taiwan, ROC

**PLATE 376: PROLIFERATIVE
PNEUMONIA-MOLDY
SWEET POTATO (IPEMEANOL
RELATED**

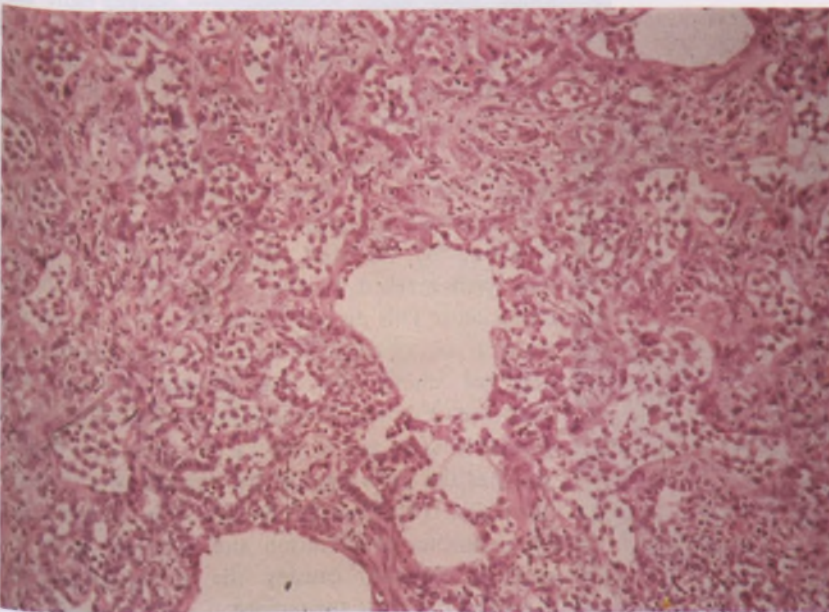
This histological section shows early alveolar lining cell proliferation which is the hallmark of Proliferative Pneumonia. Also seen are mononuclear inflammatory cells and edema in the alveoli. This is from a cow dying of the disease after eating moldy sweet potatoes. It has been shown that certain molds growing on sweet potatoes can produce a substance called Ipemeanol which is the toxic principle. This material if given intravenously to pigs and other species will also cause the above lesion suggesting that it is toxic when it is eliminated via the lungs. Atropine in large doses is the recommended treatment.



Dr. H. Seibold, Georgia, USA

**PLATE 377: PROLIFERATIVE
PNEUMONIA (*CROTALARIA*
SPP. RELATED)**

The lung in this pig is diffusely firm, heavy and wet. Histologically it shows the typical alveolar lining cell proliferation that characterizes Proliferative Pneumonia. This has been caused by the swine eating the seeds of *Crotalaria* spp. These often get mixed with and ground up in feed, or the pigs may eat them themselves when on *Crotalaria* spp. fields. This type lesion is seen in other species of animals and can be caused by many different chemicals. The higher oxides of nitrogen, DL-tryptophan, Ipemanol from moldy sweet potatoes, and paraquat can all produce similar lesions.



Dr. D. Delahanty, Dr. H. Seibold, Georgia, USA

**PLATE 378: PROLIFERATIVE
PNEUMONIA (*CROTALARIA*
SPP.)**

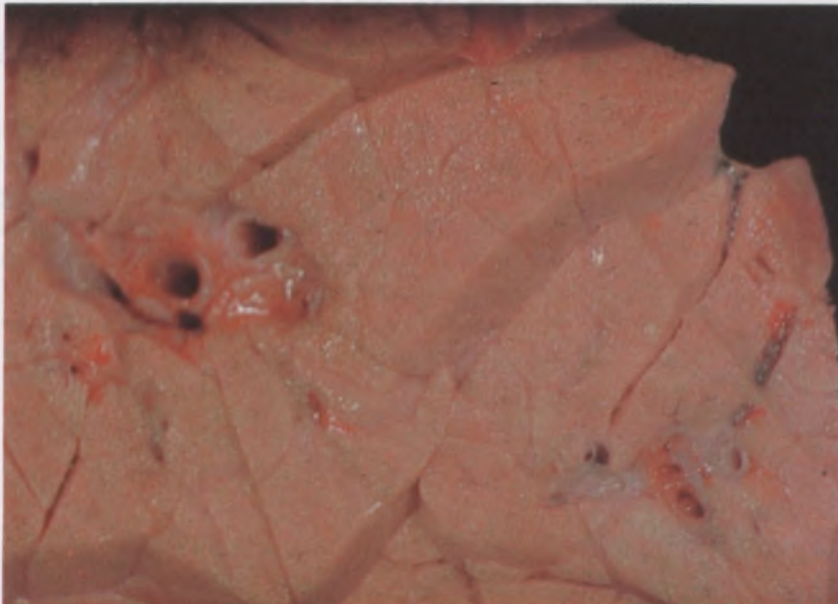
This histological picture shows the well marked proliferation of the alveolar lining cells caused by the toxins associated with *Crotalaria* spp. poisoning in a pig. This can be seen in other species such as the horse and was actually first described as one of the three primary lesions that could be found in horses fed *crotalaria* spp. by Sir Arnold Theiler in Onderstepoort, South Africa.



Dr. H. Seibold, Georgia, USA

PLATE 379: *CROTALARIA* SPP. SEEDS

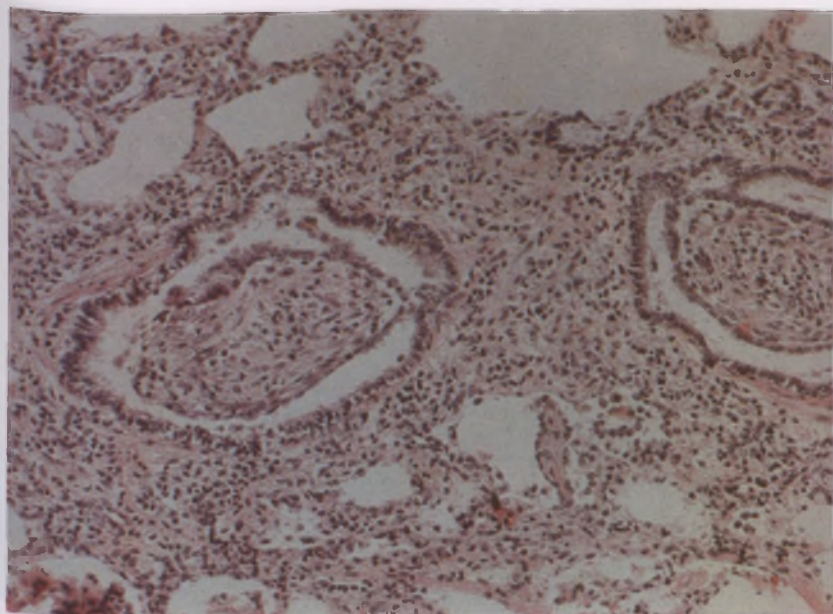
The four smaller kernels beside the large kernel of corn are kernels of *Crotalaria* spp. seeds in various stages of maturity. The consumption of these seeds by pigs and horses can cause Proliferative Pneumonia and in the horse can cause, chronic hepatic cirrhosis and encephalomalacia as well. *Crotalaria spectabilis* is a common cause of the problem but *C. intermedia*, *C. striata*, and *C. lanceolate* may also be involved.



Dr. C. Buergelt, Florida, USA

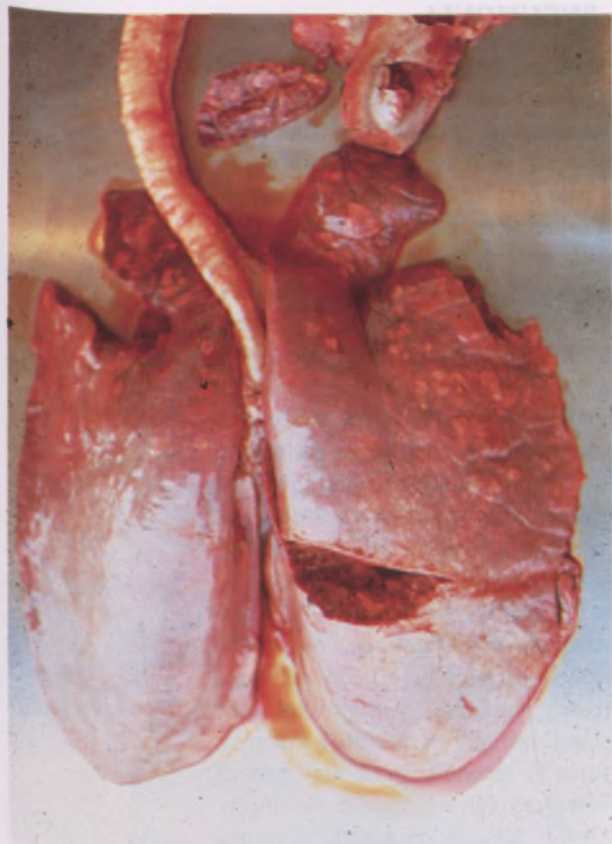
PLATE 380: *BRONCHIOLITIS OBLITERANS FIBROSA*

The light, spongy nature of this cow's lung was diffuse and can be seen in cattle with a history of most of the cows in the barn having an increased respiratory rate and coughing. One or two cows that are let out may develop severe dyspnea. When killed their lungs look like this, large, light and spongy with 1-2mm pale white or grey foci which are barely palpable, scattered throughout the entire lung. Histologically, these are foci of Bronchiolitis Obliterans Fibrosa. These are probably the result of the chronic inhalation of toxic substances that cause Proliferative Pneumonia at higher concentration over a shorter period of time. This is suggested by the fact that many of these lungs have well marked chronic proliferation of alveoli lining cells. This disease affects the majority of the cows in an affected herd. Corticosteroids are the drug of choice for this disease, Bronchiolitis Obliterans Fibrosa. This disease is called Silo Filler's disease in man and is contracted when the farmer breathes the brown gas at the bottom of a recently filled silo. Histologically, the lesion is characterized by a fibrous proliferation and ingrowth into the small bronchioles causing the air retention and therefore the gross appearance.



**PLATE 381: BRONCHIOLITIS
OBLITERANS FIBROSA**

The two small airways have the classical mass of connective tissue growing into them that gives the name to this disease of cattle, Bronchiolitis Obliterans Fibrosa. In man it is called Silo Filler's Disease, and is caused by the farmer inhaling the brown gas, the higher oxides of nitrogen, at the bottom of a freshly filled silo. In the several outbreaks in cattle, the majority of animals in the herd have been affected with a relatively chronic cough and increased respiratory rate. They normally don't die unless exertion causes fatal emphysema. The cattle are usually being fed the last of the silage in a silo or the last of some old hay which suggests a continued long feeding time of that material. Several silos on affected farms have been trench silos which suggested that the actual gas was not present for the cattle to inhale. Thus it was this idea that gave researchers at Cornell the idea that 80% eructated gas from the rumen is inhaled. Corticosteroids are the drugs of choice to prevent the connective tissue proliferation. Taking the cattle off the offending material will stop the problem. A similar but focal lesion can be seen around and in areas of pneumonia of many types.



**PLATE 382: PROLIFERATIVE
PNEUMONIA IN FOALS**

This lung is from a 6 week old foal. Grossly it is a diffusely firm, wet, heavy lung with emphysematous areas scattered throughout. Histologically the lesion is typical Proliferative Pneumonia. Of the dozen or so cases we've seen in foals, we have no answer as to cause. We are unable to incriminate such known toxic factors as DL-tryptophan, higher oxides of nitrogen, moldy sweet potatoes, *Crotalaria* spp. or paraquat.

Dr. D. Delabanty, Cornell, USA

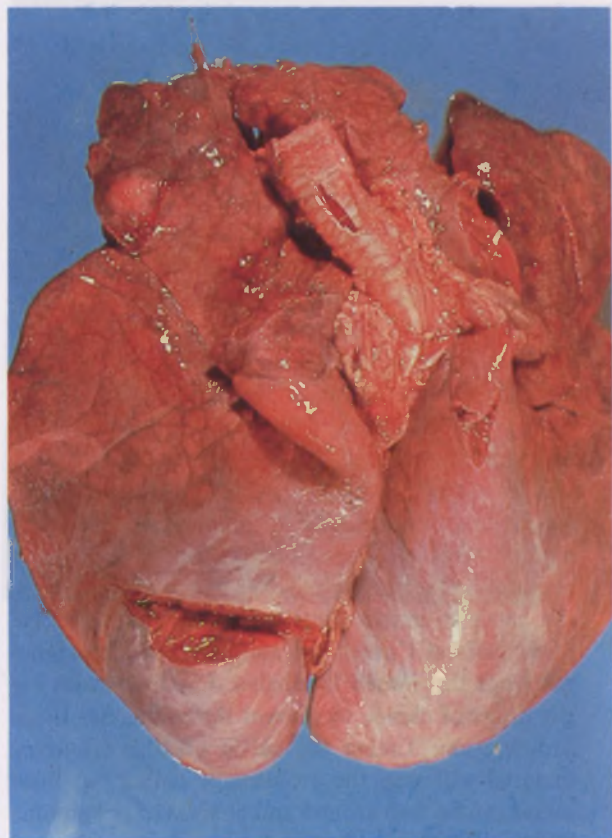

PLATE 383: SECONDARY PROLIFERATIVE PNEUMONIA

The cranioventral lung lobes of this calf are firm and several abscesses with a connective tissue capsules are scattered in these ventral lobes. The rest of the lung is diffusely firm, wet and heavy. This lung represents a chronic, well established, locally extensive pneumonia, Enzootic Pneumonia, in the cranioventral areas and acute Proliferative Pneumonia in the remaining $\frac{3}{4}$ of the lung. This latter type pneumonia is a relatively recently described condition in calves for which no acceptable answer as to cause has been discovered. This Secondary Proliferative Pneumonia is a relatively common disease in areas of intensive veal calf operations and is usually seen to occur in a few calves out of the many that were affected several weeks earlier with Enzootic Calf Pneumonia. It is always secondary to the Enzootic Calf Pneumonia. The histological features are of a classical resolving bronchopneumonia in the cranioventral lung lobes and the typical alveolar lining cell proliferation in the remaining major portion of lungs. Sometimes the Proliferative Pneumonia may only be unilateral.

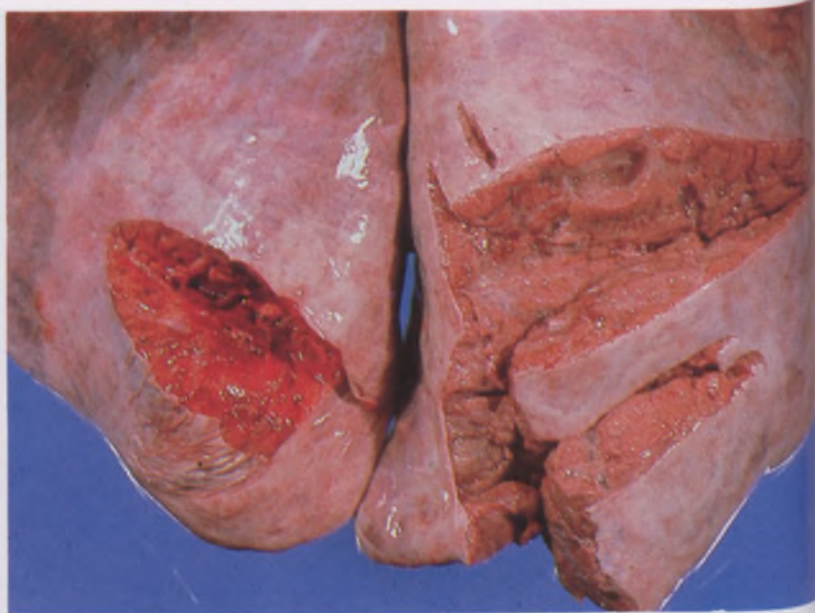

PLATE 384: UNILATERAL SECONDARY PROLIFERATIVE PNEUMONIA

The close up photograph of this calf's diaphragmatic lung lobe shows one side, the normal side, to be slightly smaller and redder than the other which is pale, enlarged, firm and has a more meaty appearance. The pale firm lobe is a classical example of Secondary Proliferative Pneumonia, but it is markedly different in that the lesion is unilateral. Being secondary, the cranial ventral lung lobes, not shown, would of course have a varying extent of chronic Enzootic Pneumonia present. Microscopically both cranial ventral lobes would show classical bronchopneumonic lesions, while the normal diaphragmatic lobe would just be congested, if that, and the diaphragmatic lobe above the affected cranioventral lobes would show the typical alveolar lining cell proliferation of Proliferative Pneumonia. This unique lesion is even more bewildering in that we cannot as yet explain the pathogenesis of Secondary Proliferative Pneumonia. We now have a lesion, seen in 10-20% of these cases, which is only unilateral, a condition even harder to understand. Initially Proliferative Pneumonia was seen primarily in adult cattle and part of its pathogenesis was explained by the possibility that the cow inhales 80% of its eructated rumen gases, but these calves with Secondary Proliferative Pneumonia are not functioning ruminants yet.

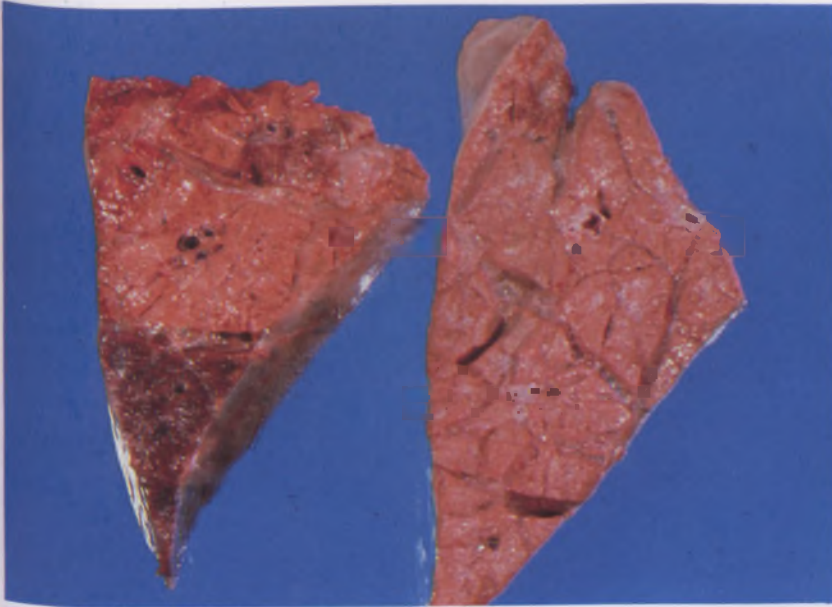

PLATE 385: UNILATERAL SECONDARY PROLIFERATIVE PNEUMONIA

These triangular pieces of calf lung show the gross features of Unilateral Secondary Proliferative Pneumonia. The dark tip of one section is the congestion associated with a resolving chronic Enzootic Pneumonia which involved the cranial ventral portions of both lungs. The area above it is the essentially normal remaining lung of that same side, although it has a single lobule in it of Enzootic Pneumonia. The entire other triangular area of lung is from the other side of the lung. It is firm, heavy and meaty in appearance and affected the whole remaining side above the areas already affected with chronic Enzootic Pneumonia. The cause for the Secondary Proliferative lesion is not known or even understood in a calf and its unilateral nature makes it doubly difficult to understand. A rough estimate of incidence of this relatively new lesion is that Secondary Proliferative Pneumonia is probably seen once in every 30-50 calves with Enzootic Pneumonia and this Unilateral Secondary Pneumonia is seen once in every 10-20 of those in New York State.

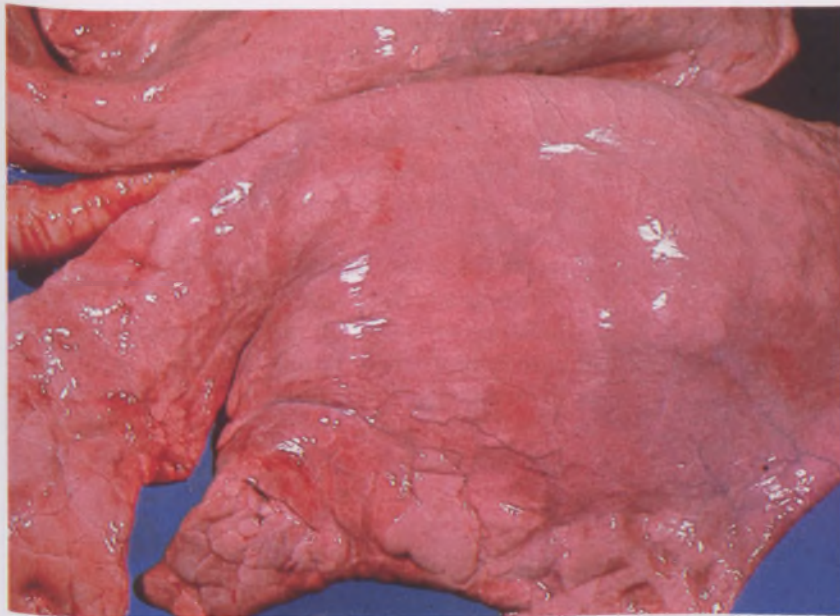

PLATE 386: DIFFUSE ALVEOLAR EMPHYSEMA (HEAVES TYPE I) OF HORSES

This horse's lung is soft, puffy and enlarged. This is a case of the less common form of Heaves and is characterized histologically by a diffuse alveolar emphysema. The horse would probably have a double expiratory effort with a grunt between them for each respiration. In time, a grossly visible heave line just behind the ribs may be seen as a result of muscular hypertrophy. A feed sensitivity is suspect as the cause in most cases. In times past, this Alveolar Emphysema was the most common form of Heaves, but Mucoid Bronchiolitis is probably the more common from now.

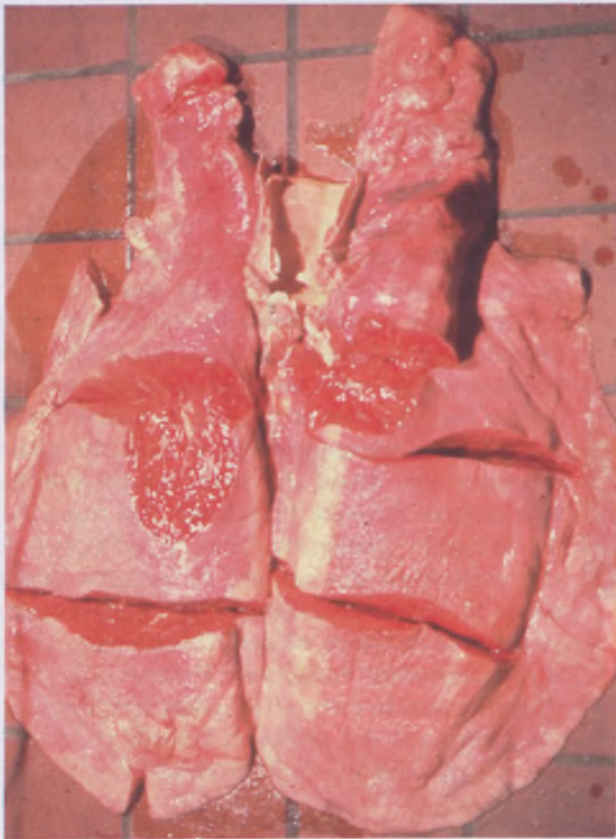


PLATE 387: GENERALIZED MUROID BRONCHIOLITIS (HEAVES TYPE II) OF HORSES

This horse lung is slightly inflated and at first appearance may be almost considered normal, but closer examination would probably reveal a multifocal distribution of 1-3mm, slightly firm, grey nodules throughout the lung. Histologically, these tiny foci are foci of slight to marked inflammation in and around small bronchioles with variable mucus production. Again, an allergic response to some feed is the suspected cause. This is now the most common form of Heaves in N.Y. State.

PLATE 388: UNILATERAL SECONDARY PROLIFERATIVE PNEUMONIA

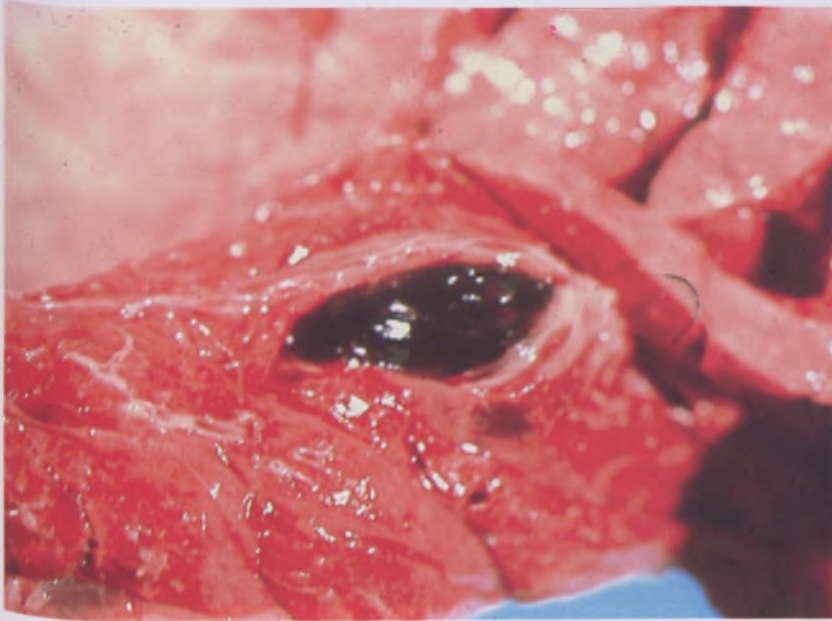
This close up photograph of the surface of the lung shows the white, firm, nodules which are slightly raised and which have a granular appearance. The pale firm nodules are foci of secondary proliferative pneumonia.

PLATE 386: SECONDARY PROLIFERATIVE PNEUMONIA

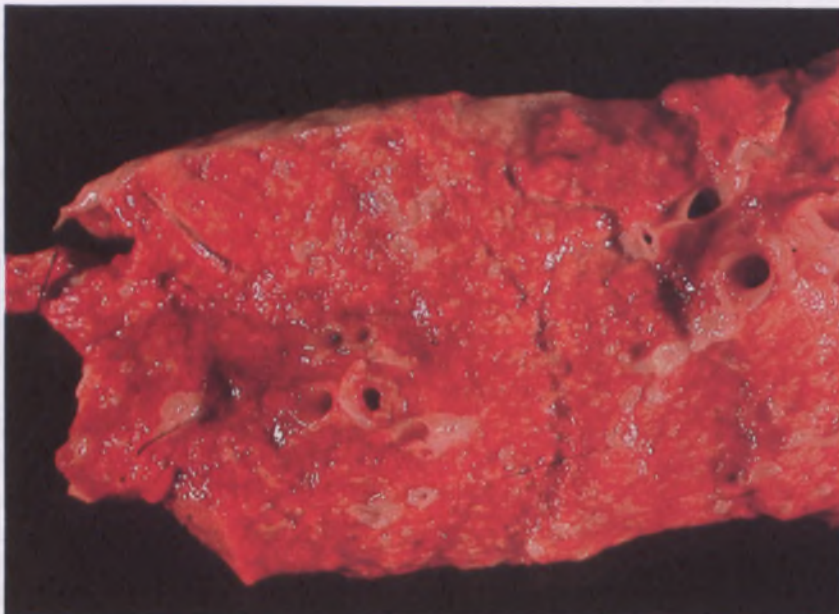

PLATE 388: MUROID BRONCHIOLITIS (HEAVES TYPE II) OF HORSES

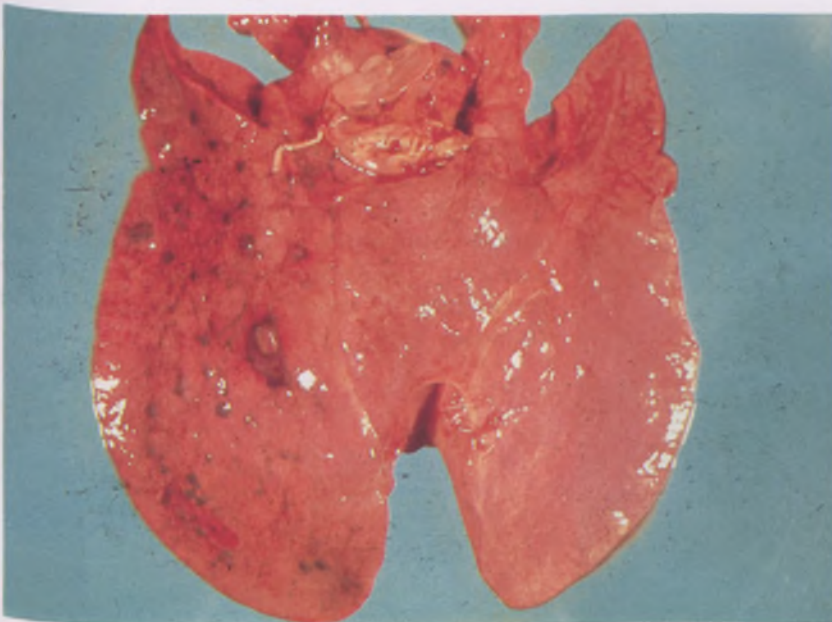
The tiny pale white 1-2mm foci scattered throughout this cut section of horse lung are the multifocal areas of Mucoid Bronchiolitis that characterizes this most common form of Heaves. Its cause is suspected to be a sensitivity to a feed substance. Histologically these areas are characterized by multifocal bronchiolitis of varying degrees with much mucus production in and around most of them. In some, the mucus is plentiful enough to have spilled into alveoli evoking a slight reaction to its presence there.



Dr. P. Frelier, Cornell, USA

PLATE 389: PULMONARY HEMATOMA

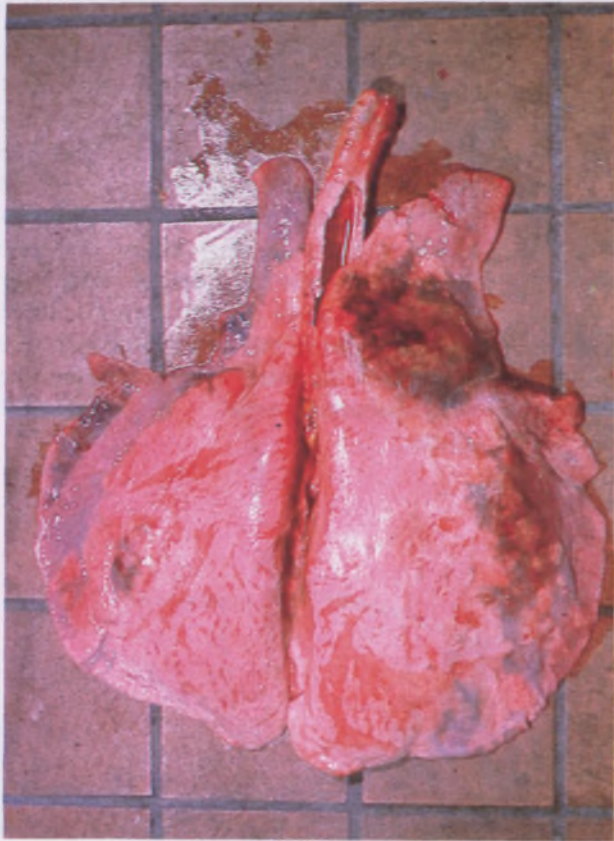
All that is being shown here is a blood clot in the lung parenchyma of a cow, but it had a history of epistaxis, nosebleed. Grossly this lesion was only palpable, not observable from the surface. The history of epistaxis suggested looking further and this lesion which as expected was a ruptured thrombosed branch of the pulmonary artery. This cow also had several liver abscesses, one of which may have ruptured into a small hepatic vein and allowed debris to finally lodge in this area. It was a mycotic lesion, as usual, in the vessel wall that allowed the rupture of the pulmonary vessel.



Dr. R. Lewis, Cornell, USA

PLATE 390: UNILATERAL SUPPURATIVE MULTIFOCAL BRONCHOPNEUMONIA

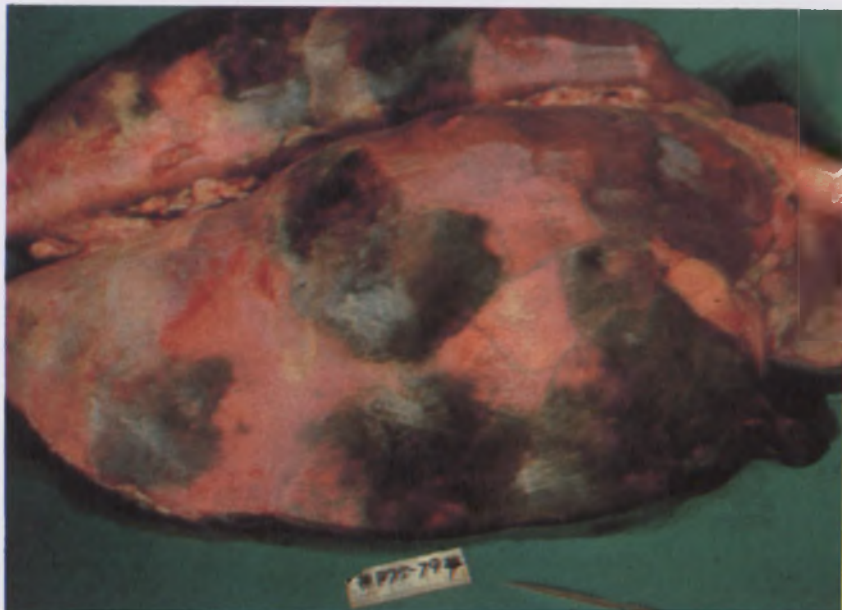The multifocal, raised, dark nodules in the one lung of this foal are abscesses from which pure cultures of *Actinobacillus equuli* were isolated. Its unilateral distribution and the pure cultures obtained, suggest that a sample of *A. equuli* contaminated amniotic fluid or other parturient fluids were inhaled at birth and went down the bronchus. A hematogenous spread should be bilateral. We are not sure of the pathogenesis in this case. Lesions caused by these organisms are usually found in the kidneys or joints.



**PLATE 391: SHIPPING FEVER
PNEUMONIA OF HORSES**

The large, firm, locally extensive, scattered pneumonic foci in the horse lungs shown here are the lesions of Shipping Fever of Horses. This relatively rarely described disease of horses follows shipping of horses over short or long distances. Pure cultures of *Staphylococci* spp. or *Streptococci* spp. are usually isolated. The initial cases brought to our attention were thought to be examples of Inhalation Pneumonia as the lesion is similar. Some collapse of the ventral edge of this horse's lung is seen, this is caused by the pleuritis associated with the pneumonia.

Dr. R. Panciera, Oklahoma, USA



**PLATE 392: HEMOPHILUS PNEUMONIA
OF PIGS**

These locally extensive, multiple areas of pneumonia in this pig's lung are diagnostic and actually pathognomonic for *Hemophilus* spp. pneumonia of pigs. Its fibrinous, bloody, multiple, locally extensive distribution in the lung distinguish these cases from *Pasteurella* spp. (Shipping Fever) pneumonia which is mostly cranioventral and usually less bloody.

Dr. M. Chang, Taiwan, ROC

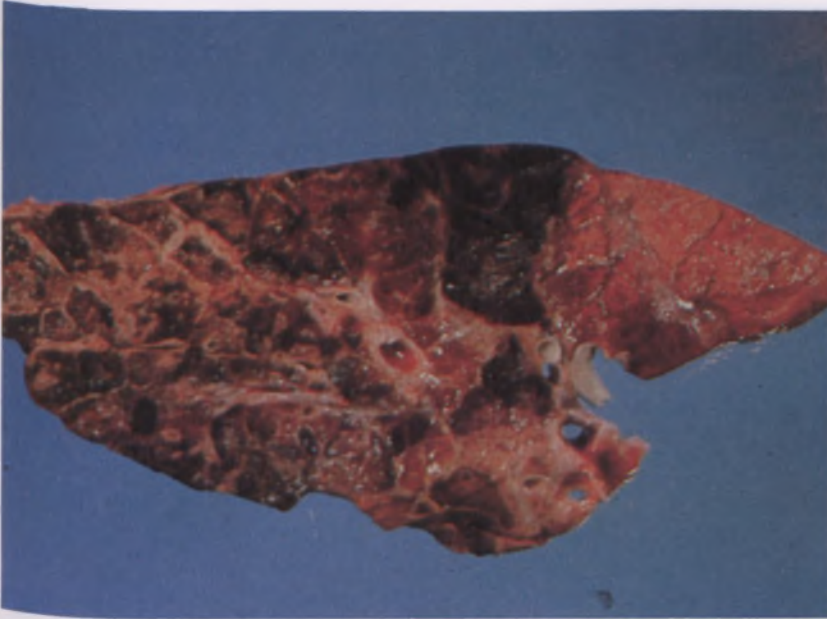

PLATE 393: PASTEURELLA (SHIPPING FEVER) PNEUMONIA

This section of bovine lung from the cranial ventral lung lobes affected with a locally extensive bronchopneumonia is a good example of the acute fibrinous and somewhat hemorrhagic nature of Shipping Fever Pneumonia of cattle. Distinct dry dull areas of necrosis can be seen in the affected areas. These are areas of necrotic lung which may well have sequestered with time. While many believe a virus to be a predeterminant, *Pasteurella multocida* and *Pasteurella hemolytica* are commonly isolated and histological, fluorescent, cultural, acute and convalescent serology examination are usually negative for viruses.

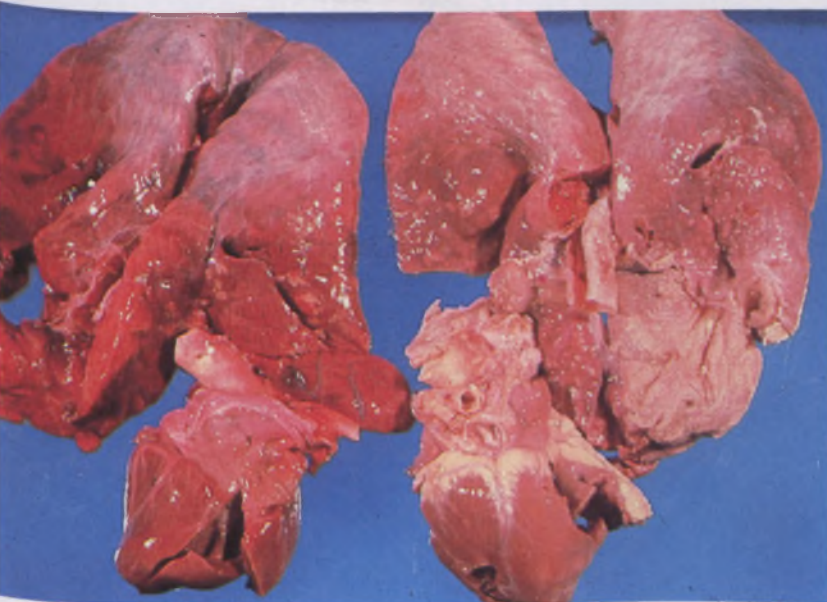

PLATE 394: CHRONIC ENZOOTIC PNEUMONIA OF CALVES WITH AND WITHOUT EMACIATION

Both of these calves' lungs show chronic enzootic pneumonia in the cranial ventral lobes. The slightly larger and paler lung has a large area of chronic abscess formation in its left cranial ventral lobe. The basic reason for showing this picture is to demonstrate that in fact the calf with the most severe pneumonia did not starve as a result for its body fat around the heart and in the coronary grooves are adequate while the less pneumonically affected calf is considered emaciated. A nutritional problem should be considered as a cause for the debilitation of the calf as well.

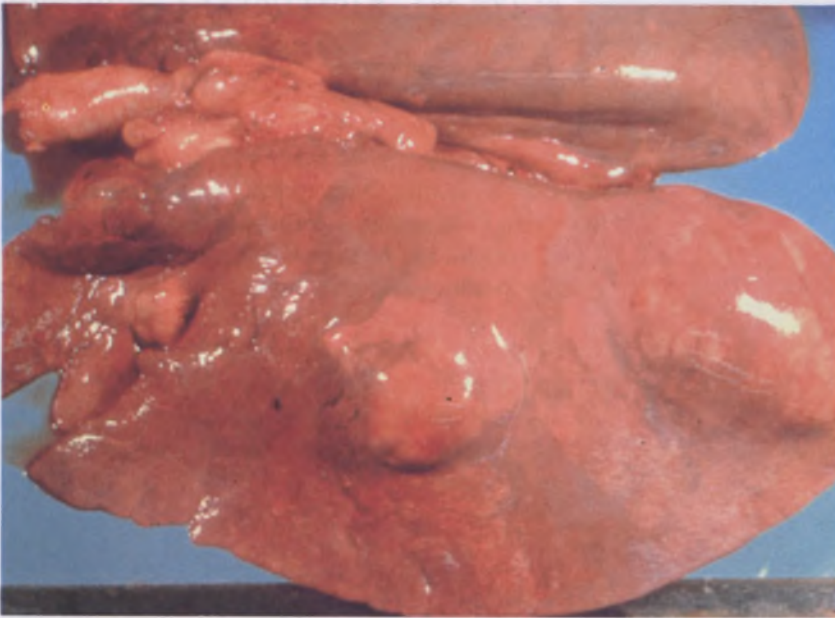

PLATE 395: CHRONIC ABSCESSSED PNEUMONIA WITH SECONDARY PNEUMOCYSTOSIS

Several large masses deeper in the lung are causing bulges on the lung surface. These are *Corynebacterium equi* or *Streptococcus equi* abscesses. If one palpates the rest of the lung however it will feel quite firm throughout. This latter lesion is the result of *Pneumocystis carinii* pneumonia which is often a complicating factor when animals, especially young horses, are immunologically stressed as possibly by these abscess pockets, or in Arab foals, with Combined Immunodeficiency Disease (CID). As in foals this protozoal disease can be seen in other species when their immune competency has been strained.

Dr. R. Fenclov, Oklahoma, USA

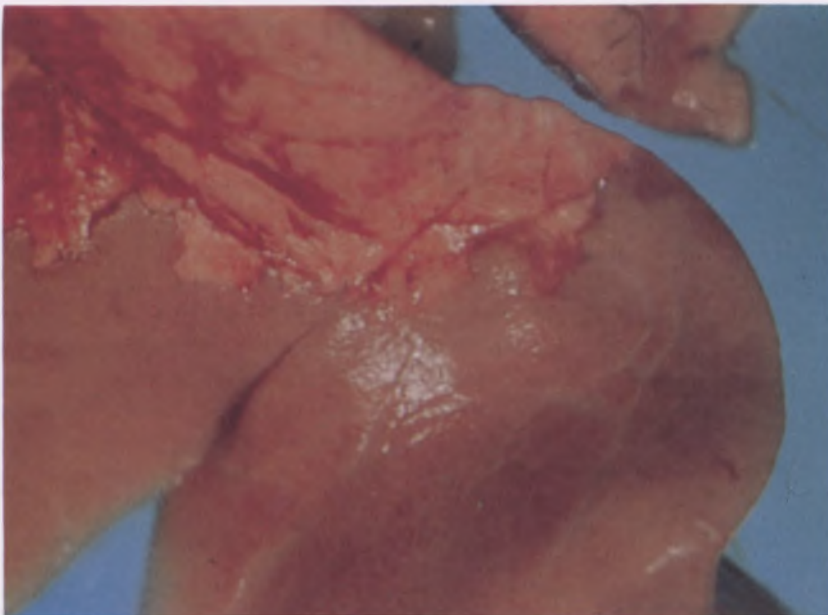
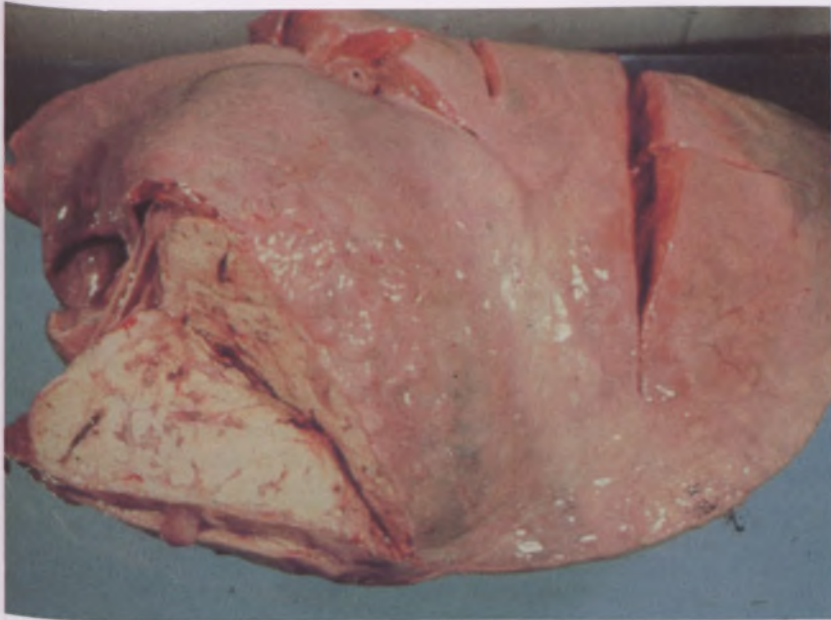


PLATE 396: CHRONIC ENZOOTIC PNEUMONIA OF SHEEP

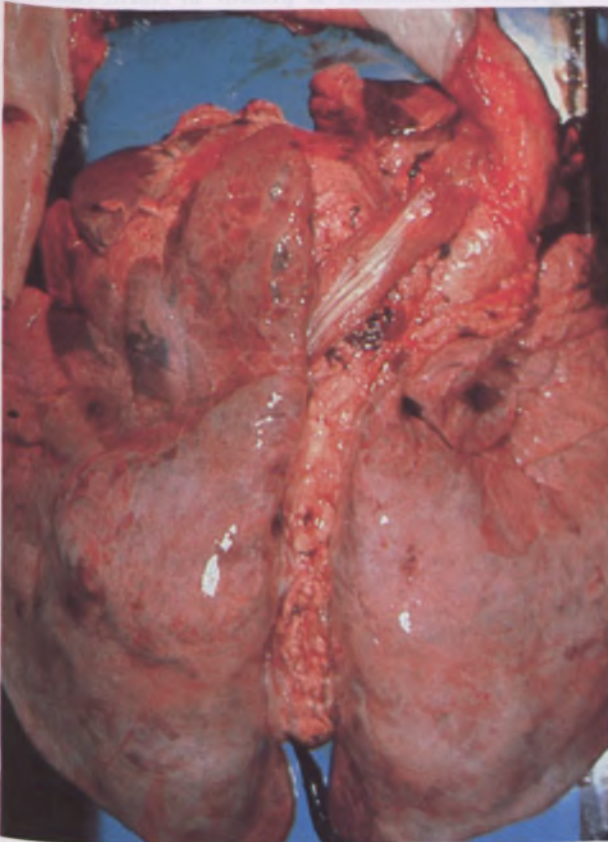
This firm grey lung tissue is limited to the cranial ventral lung lobes of a sheep. It is the grey hepatization stage of Enzootic Pneumonia of sheep, the cause of which is not agreed upon. *Pasteurella* spp. is commonly isolated and many lymphoid foci are to be found scattered in the affected areas in chronic cases. It is distinguished from Marsh's Progressive Pneumonia (Maedi) and Jaagsiekte (Adenomatosis) by this locally extensive pneumonia having a very definite cranial ventral location.

Dr. R. Fenclov, Oklahoma, USA



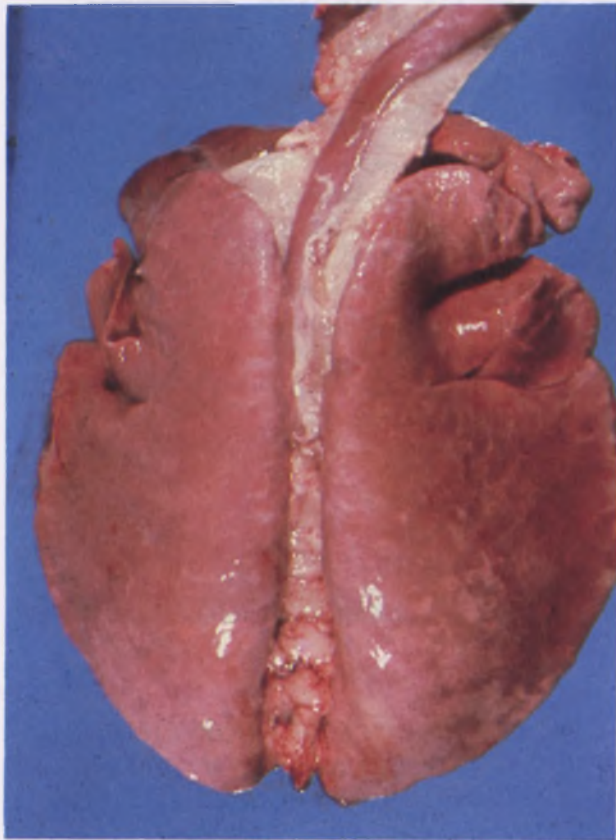
**PLATE 397: CHRONIC BACTERIAL
(*MYCOBACTERIUM SPP.*)
PNEUMONIA**

The cranial third of this horse lung is swollen and hard with excessive connective tissue clumps on its surface. The cut surface of the affected lung as shown is hard and gritty with much mineralized necrotic tissue and connective tissue stroma. Although *Mycobacterium* spp. were not isolated, possibly due to technique, the lesions seen grossly, and the histological findings of typical giant cells and acid fast organisms allowed the presumptive diagnosis of tuberculosis.



**PLATE 398: ACUTE BRONCHOPNEU-
MONIA WITH SECONDARY
EMPHYSEMA**

Although not easily seen because of the marked emphysema, there are numerous areas, especially in the cranioventral regions of bronchopneumonia in this cow's lung, that can be palpated. Histological sections had intranuclear inclusions in the areas of pneumonia and the trachea compatible with Infectious Bovine Rhinotracheitis (IBR). Of all domestic animals, cattle seem to be the most prone to emphysema.



Dr. P. Andersson, Finland

PLATE 399: MARSH'S PROGRESSIVE PNEUMONIA (MAEDI)

Scattered throughout this goat's lung are large, locally extensive areas of pneumonia so much so that a major portion of lung is involved. This disease, more common in sheep, is called Marsh's Progressive Pneumonia or Maedi, a viral disease which for a long time was confused with Adenomatosis (Jaagsiekte) of sheep, which is caused by a different virus. This disease is somewhat similar grossly but histologically this disease has a massive number of lymphoid cell foci in the form of mature follicles scattered in the lung. In addition there may be many areas of type II pneumocyte proliferation forming gland like aggregates but these are in the areas of pneumonia unlike those of Adenomatosis (Jaagsiekte) which are, essentially islands of epithelial proliferation. Thus the proliferating islands next to the areas of pneumonia or for that matter near foreign bodies, parasites, etc., should be called an "Adenomatoid" reaction. Maedi (Marsh's Progressive Pneumonia) is present in North America, Europe and other areas but Jaagsiekte is not in the United States.

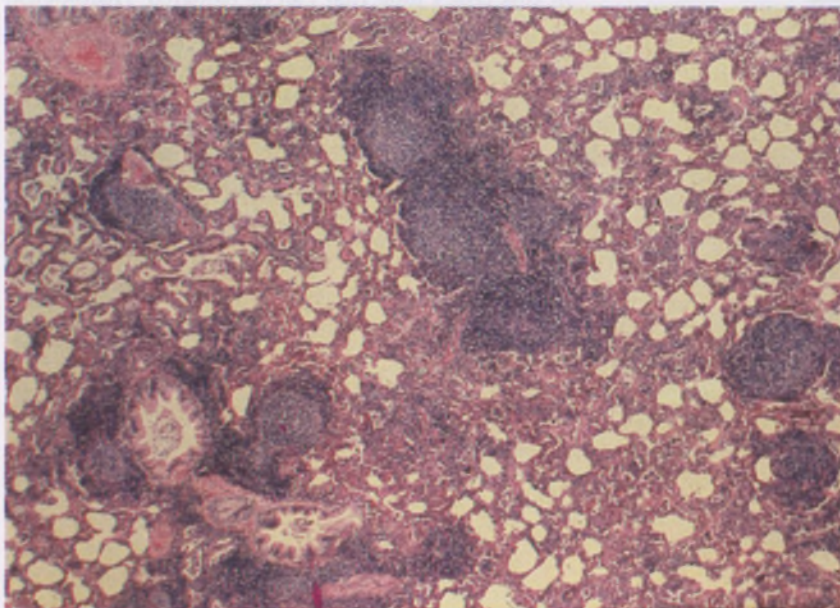
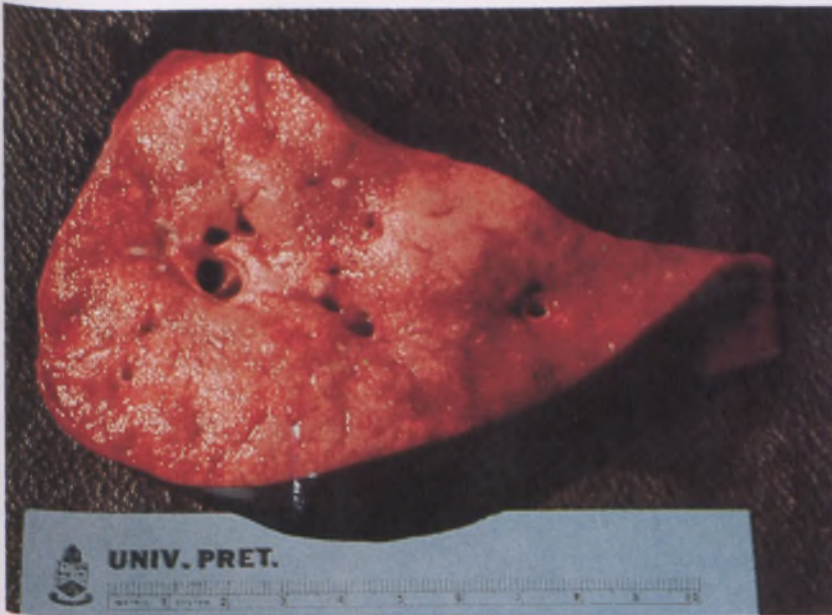

PLATE 400: MAEDI (MARSH'S PROGRESSIVE PNEUMONIA)

The multiple lymphoid follicles present are quite characteristic for Marsh's Progressive Pneumonia (Maedi) in sheep and goats. The lesion of lymphoid follicle production is a rather common one in the sheep's lung following any parenchymal damage so it is not pathognomonic. To make the diagnosis of Maedi the sheep should have a locally extensive pneumonia scattered over a major portion of the lung grossly. Histologically this lesion and some alveolar lining cell proliferation may be seen.

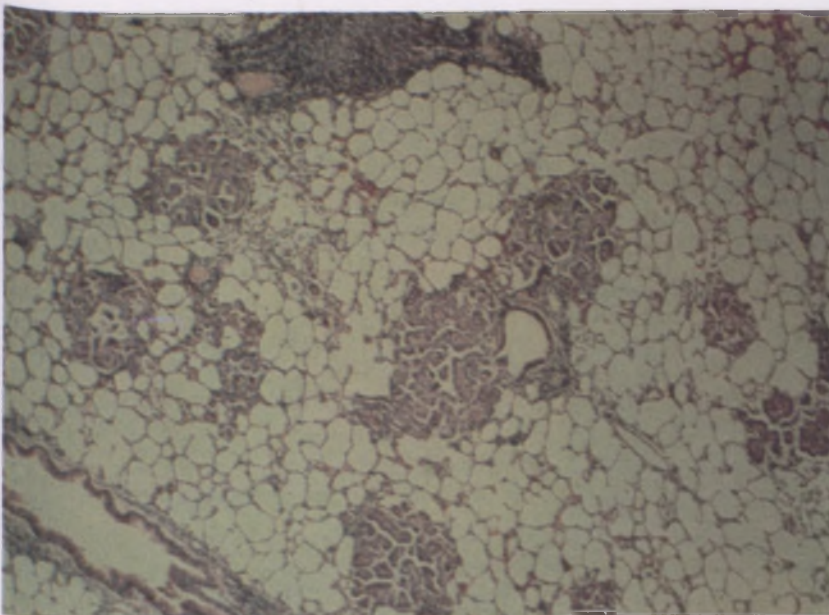
Dr. R. Panciera, Oklahoma, USA



Dr. Pienarr, Onderstepoort, USA

**PLATE 401: JAAGSIEKTE
(ADENOMATOSIS)**

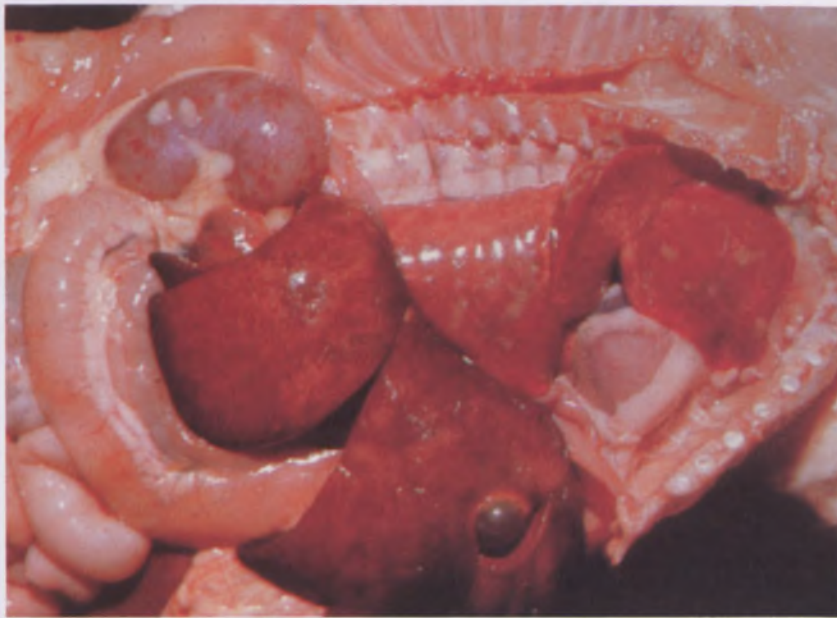
Several large locally extensive areas of pneumonia were scattered in this sheep's lung and this shows a cross section of pale affected areas along with the redder less affected areas. This is a common viral disease of sheep in South Africa and is called Jaagsiekte or Adenomatosis. It is not easily differentiated from Marsh's Progressive Pneumonia (Maedi), another viral disease, which occurs in the United States while this one does not.



Dr. T. A. Nobel, Isreal and Dr. R. Panciera, Oklahoma, USA

**PLATE 402: ADENOMATOSIS
(JAAGSIEKTE)**

This histological section of lung shows a normal bronchiole at one corner and a well marked lymphoid nodule near a pulmonary vessel. Scattered in the alveoli and adjacent to a smaller bronchial in the middle of the picture are well marked islands of proliferating alveolar lining cells, type II pneumocytes. These lining cell proliferations are forming gland like structures which are the basis for the name Adenomatosis. It is considered that this is a viral induced malignant neoplasm, and metastases have been found in regional nodes and even in other nonthoracic tissues.

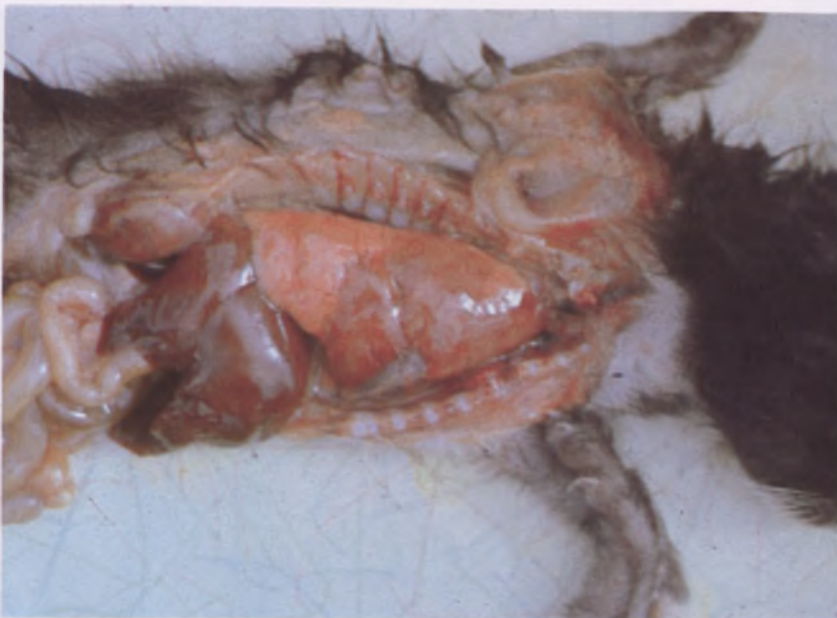

**PLATE 403: CANINE VIRAL
(HERPES VIRUS) PNEUMO-
NIA AND HEPATITIS**

The petechial hemorrhages in the kidney are quite diagnostic in this puppy. The focal necrosis in the liver and lung are also helpful in making the diagnosis. This Herpesvirus infection of dogs was initially called Carmichael Virus infection. The intranuclear inclusions in the areas of focal necrosis, especially in the adrenal fixed in hard (acid) fixatives are diagnostic. Keeping the environmental temperature up is one way of controlling the disease clinically. Some cases of cerebellar hypoplasia in dogs are thought to be due to this virus.

Dr. L. Carmicheal, Cornell, USA

Dr. P. Anderson, Finland



**PLATE 404: VIRAL (HERPES VIRUS)
PNEUMONIA**

The cranioventral half of this kitten's lung is dark and firm. Four kittens in the litter of seven were affected with similar lesions. Histologically the bronchopneumonia present was a necrotizing one with many intranuclear inclusion bodies.

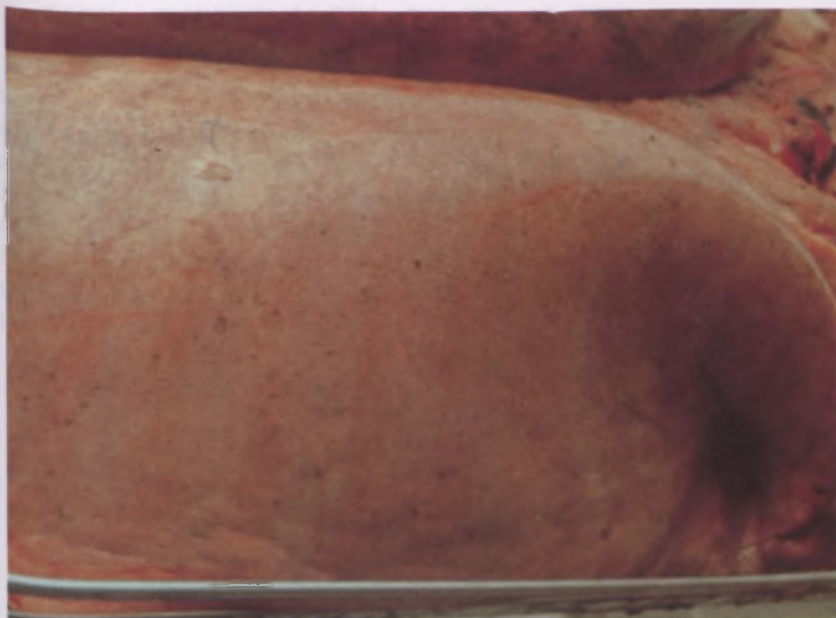

PLATE 405: EQUINE INFECTIOUS ANEMIA

This large tannish lung is from a horse with Equine Infectious Anemia (EIA). The enlargement is from pulmonary edema, but the tan appearance is from several episodes of hemolysis with pulmonic macrophages picking up the hemolyzed blood pigment. This is somewhat akin to a heart failure lung associated with chronic blood stasis in the lung from the heart lesion, with breakdown of the blood and subsequent phagocytosis and storage by lung macrophages.

Dr. M. Kemen, Cornell, USA

PLATE 408: VIRAL (EQUINE VIRUS
ABORTION) PNEUMONIA
In this diffusely congested, firm, swollen lung one
can clearly make out the rib impressions on the
surface. The loss was scored in the last few
months of gestation. Typical herpes inclusion
bodies are found in the nuclei of the pneumocytes.

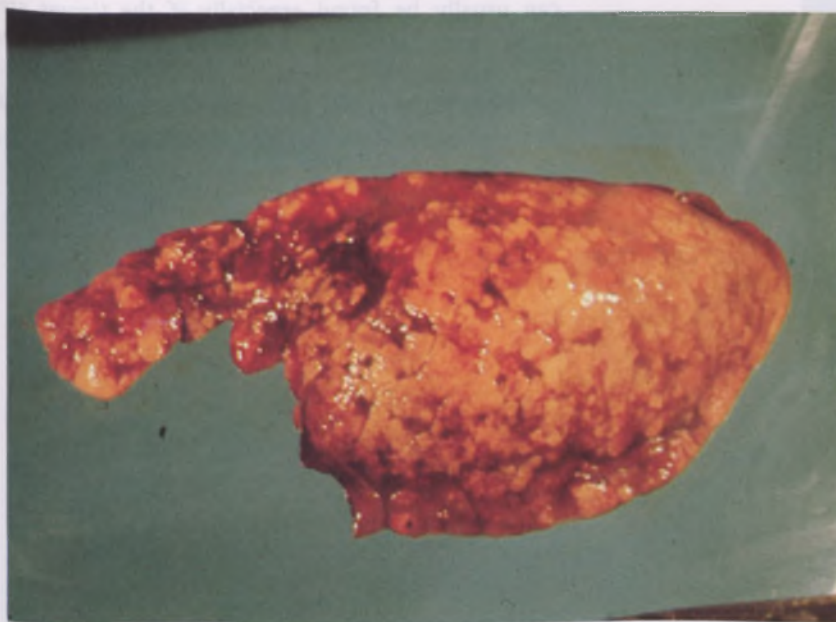


PLATE 406: ADENOVIRUS PNEUMONIA

The multiple firm areas scattered among moderate emphysematous areas are the result of bronchopneumonia caused by an Equine Adenovirus. This is usually seen in young horses and the pneumonia is characterized histologically with intranuclear inclusion bodies in areas of a necrotizing bronchopneumonia. Lesions have not been found in other tissues as one would expect with herpes viruses and this lung lesion is more locally extensive than diffuse as it is with herpesvirus.

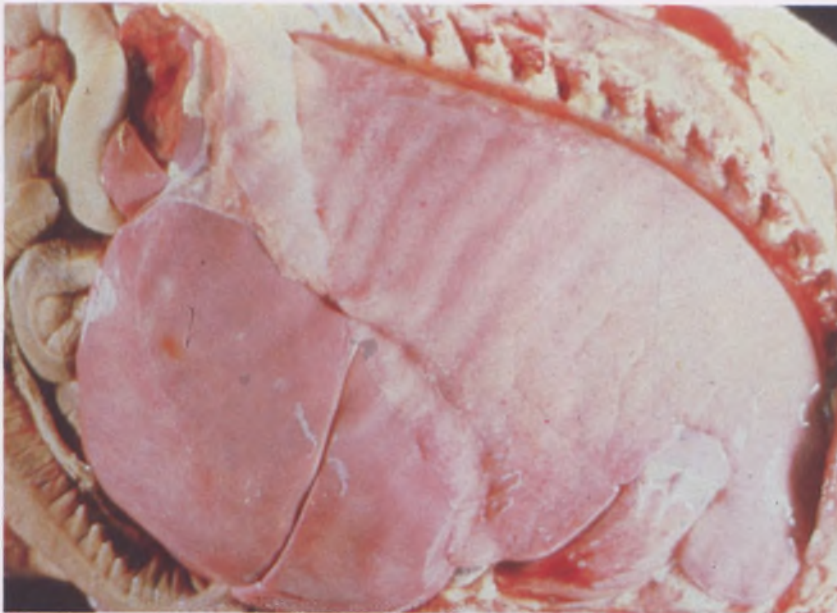


PLATE 407: VIRAL (EQUINE VIRUS ABORTION) PNEUMONIA

The lung lesion in this aborted foal is a diffuse one and characteristic rib impressions are seen on the enlarged firm lung. The foal was aborted, as is usually the case, during the last three months of gestation. Sometimes multifocal necrotic foci can be seen grossly in the lung, liver, kidneys and adrenals. Typical intranuclear inclusion may be found in all the necrotic foci and especially in the adrenal glands.

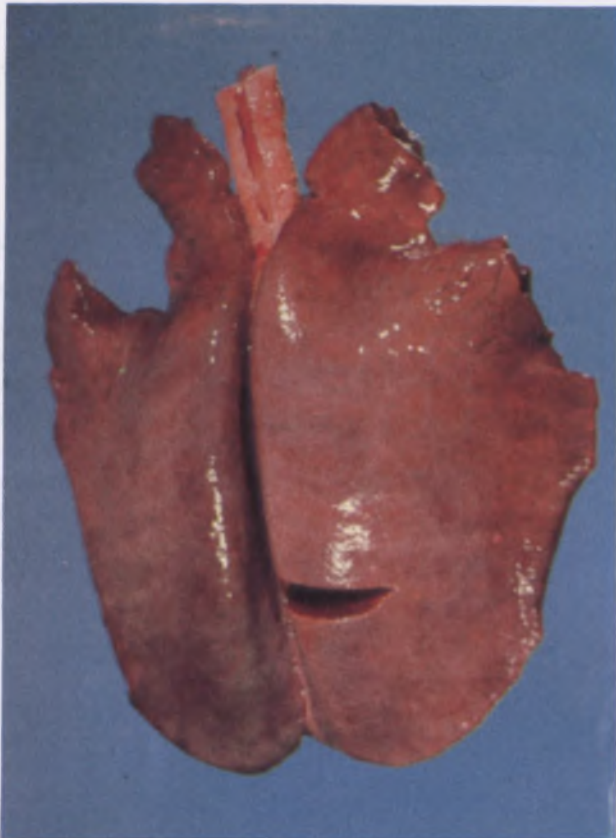


PLATE 408: VIRAL (EQUINE VIRUS ABORTION) PNEUMONIA

In this diffusely congested, firm, swollen lung one can barely make out the rib impressions on its surface. This foal was aborted in the last fewall months of gestation. Typical herpes inclusions can usually be found especially if the tissues are fixed in an acid (hard) fixative such as Bouin's or Zenker's. The adrenals in all herpesvirus infections are likely places to look for the focal necrosis and inclusions as well as the liver, kidney and lungs.

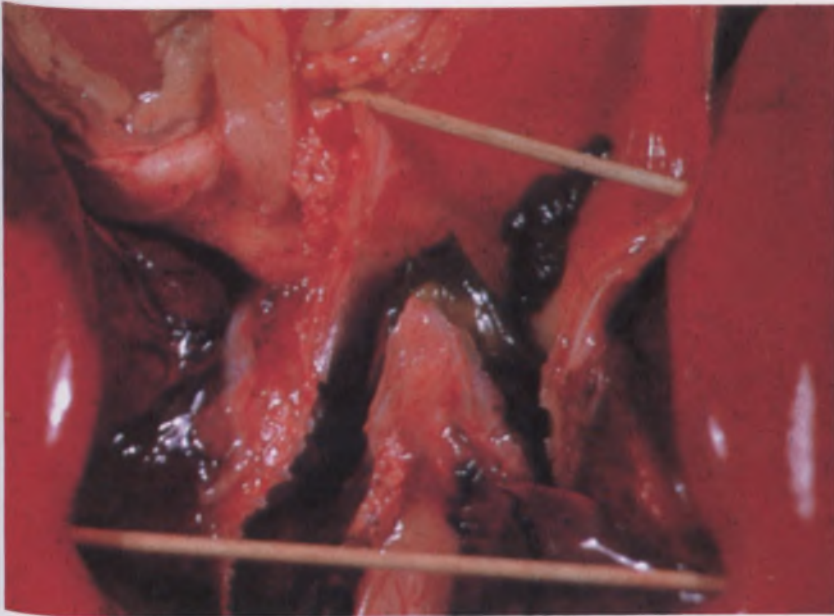


PLATE 409: TRACHEAL MECONIUM PLUG

The dark green yellow mass at the bifurcation of the trachea in this aborted foal is a plug of meconium inhaled from the amniotic fluid. It is quite diagnostic for Equine Virus Abortion when found but it is not very common.

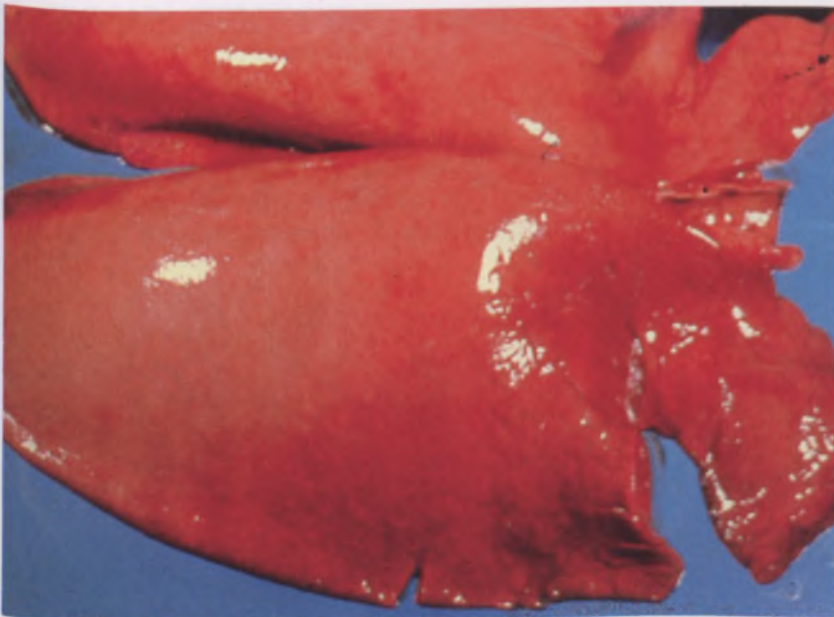
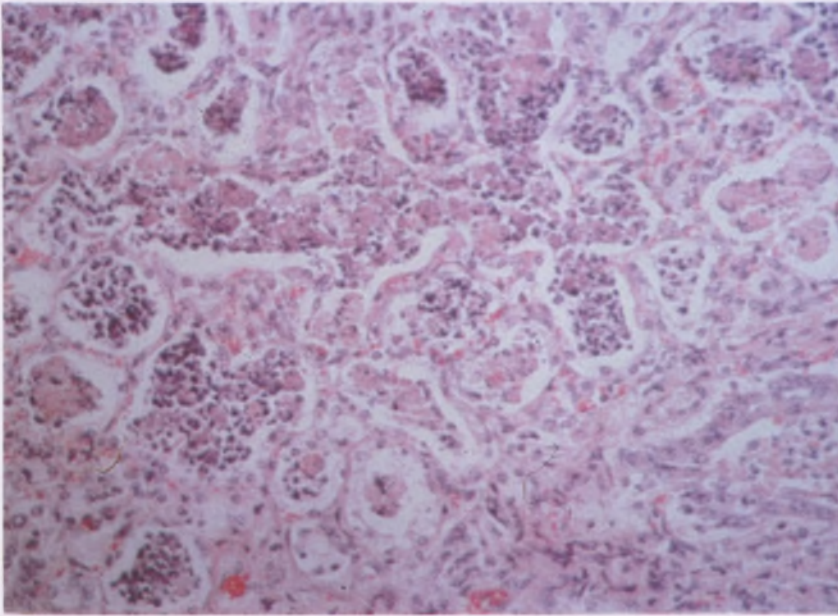


PLATE 410: PROTOZOAL (*PNEUMOCYSTIS CARINII*) PNEUMONIA

The foal lungs presented here are almost diffusely and uniformly firm. This is an Arab foal with Combined Immunodeficiency Disease complicated by secondary *Pneumocystis carinii* infection. In man, rats and goats with other chronic disease, or on drugs such as cytotoxic drugs for cancer therapy, this secondary protozoal disease is often the cause of death.



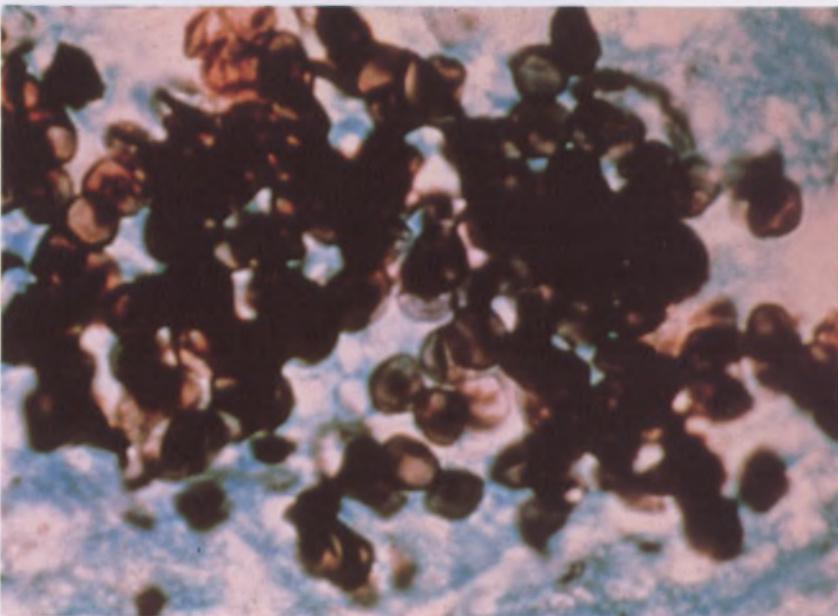
**PLATE 411: *PNEUMOCYSTIS CARINII*
PNEUMONIA**

Alveoli are filled with some neutrophils and amorphous pink, slightly granular, debris which is a hallmark for *Pneumocystis carinii* lung infection in most species. A silver stain is necessary to elucidate them in sections.



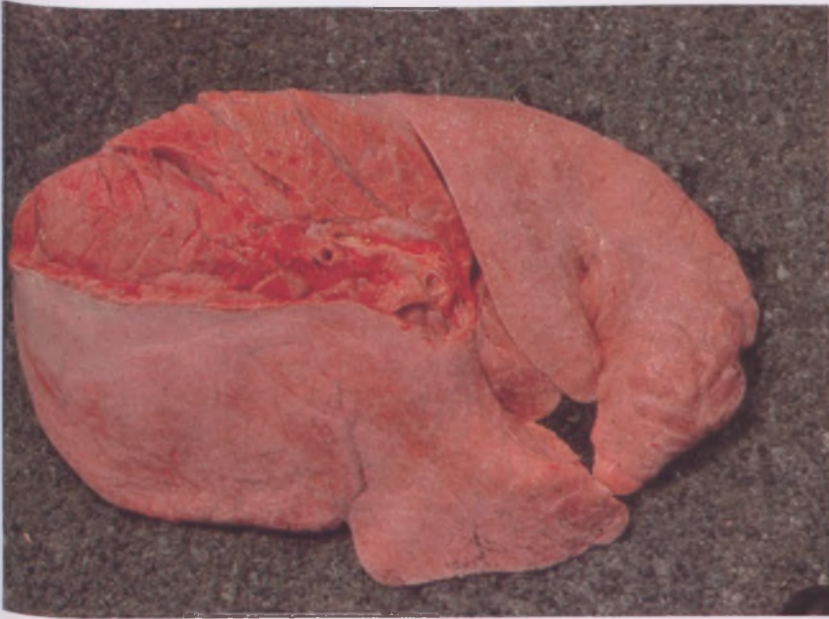
**PLATE 408: VIRAL (EQUINE VIRUS
ABORTION) PNEUMONIA**

In this diffusely congested, firm, swollen lung one can barely make out the ill impressions on the surface. This foal was aborted in the last few months of gestation. Typical lesions included



**PLATE 412: *PNEUMOCYSTIS CARINII*
PNEUMONIA**

The content of approximately two alveoli from a man are shown here and it consists of numerous, black, silver stained, roughly oval *Pneumocystis carinii*, the protozoal cause of this pneumonia in immunologically stressed individuals.



**PLATE 413: MULTIFOCAL MYCOTIC
(FARMER'S LUNG)
PNEUMONIA**

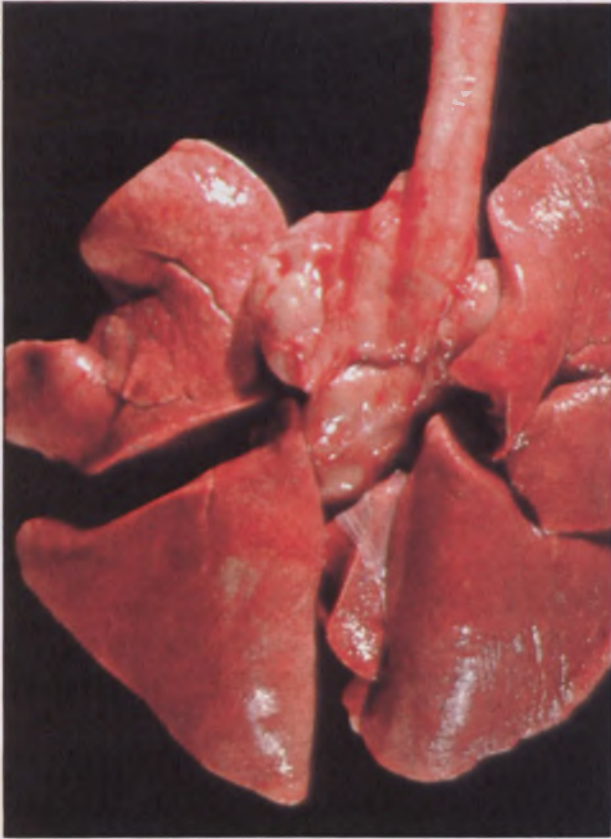
The lungs are from a cow in a herd of 43 head, most of which, had a severe hacking cough which developed over several months. They had been eating a white, extensively moldy silage. Most of the cows recovered when the silage was removed from their daily feed supply. The lungs of the few cows killed to investigate the disease were enlarged slightly with emphysema and 1-2mm firm, pale foci were diffusely scattered in the parenchyma. On microscopic examination, the small nodules were classical granulomas with bits and pieces of mold in the center of a few of these granulomas which were tentatively thought to be *Polymicrosporium* spp. The cultures obtained from the moldy silage were not definitive. It is thought that other molds or their products could also be involved. To reiterate, these are granulomatous lesions of a chronic nature and the gross lesion is multifocal.

Dr. J. Roth, Oklahoma, USA



PLATE 414: MOLDY SILAGE

This is a picture of the moldy silage that was the apparent cause of Farmer's Lung in a group of cattle being fed the silage. The respiratory problem stopped when feeding of this material stopped. The gross lesion was a scattering of 1-3mm. granulomas throughout the lung which histologically had tiny pieces of mold in only a few of the granulomas.



Dr. L, Roth, Oklahoma, USA

PLATE 415: DIFFUSE GRANULOMATOUS MYCOTIC (BLASTOMYCES DERMATITIDIS) PNEUMONIA

The lung of this dog is slightly firmer than normal with scattered pale foci throughout. The bronchial lymph nodes are enlarged over 10 times. Large numbers of *Blastomyces dermatitidis* were found in the diffuse granulomatous pneumonic areas and the bronchial lymph nodes. It is suggested that the enlarged nodes may help differentiate this disease grossly from Histoplasmosis or even Toxoplasmosis.

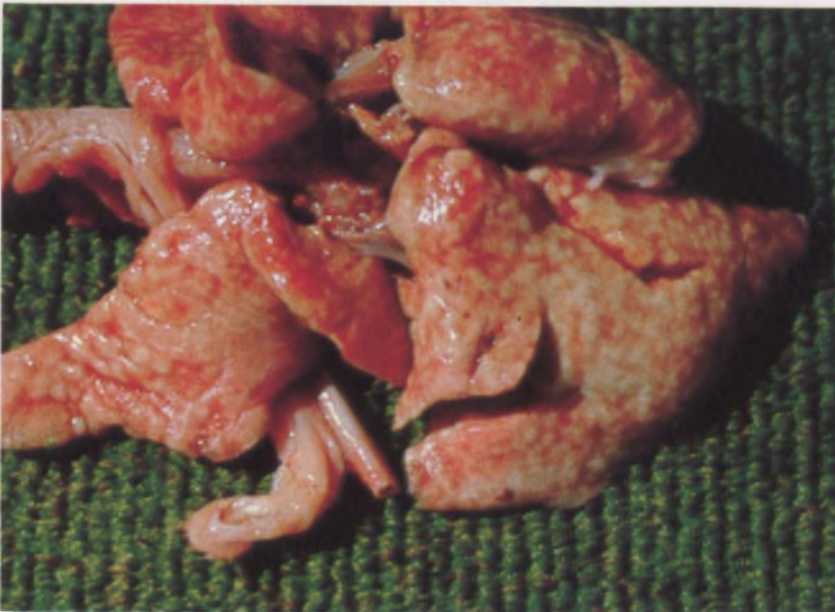

PLATE 416: MYCOTIC (HISTOPLASMA CAPSULATUM) PNEUMONIA

Multiple, pale, several mm, slightly firm foci are scattered throughout this cat's lung. Lymph nodes were not remarkable grossly. Histological study revealed *Histoplasma capsulatum* in the many mycotic granulomas.

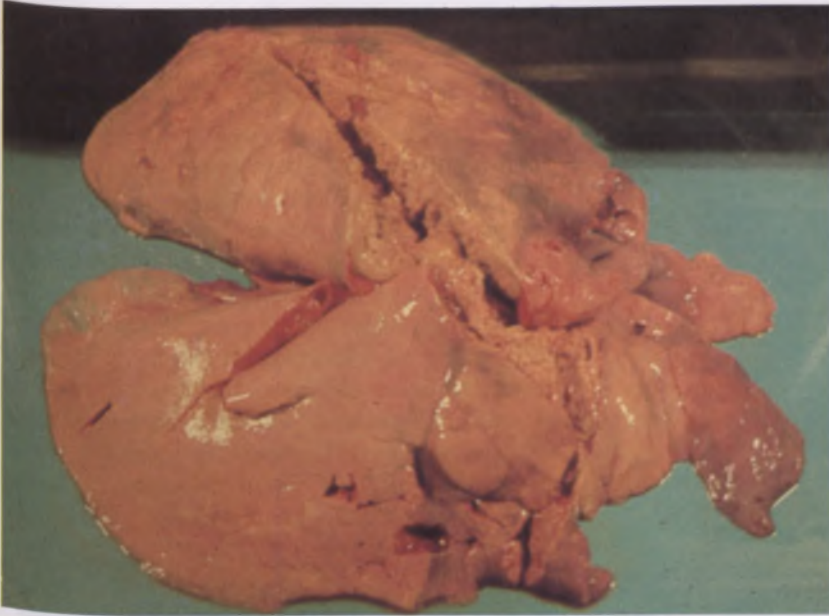


PLATE 417: MYCOTIC (*HISTOPLASMA* SPP.) PNEUMONIA

The horse's lung shown has large locally extensive areas of firm, yellow purulent pneumonia scattered throughout. Around the areas of pneumonia absence of appreciable inflammation was noted. Histologically large numbers of *Histoplasma* spp. were found in these areas.

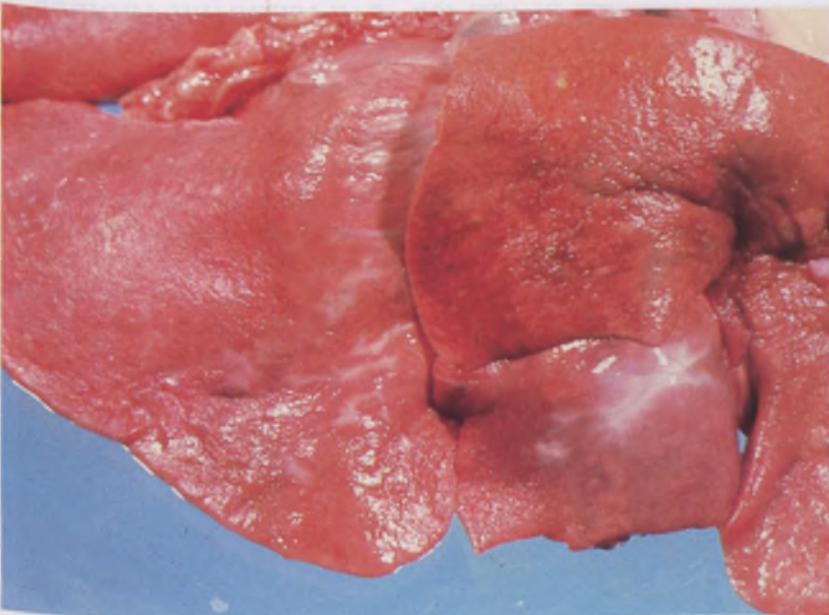
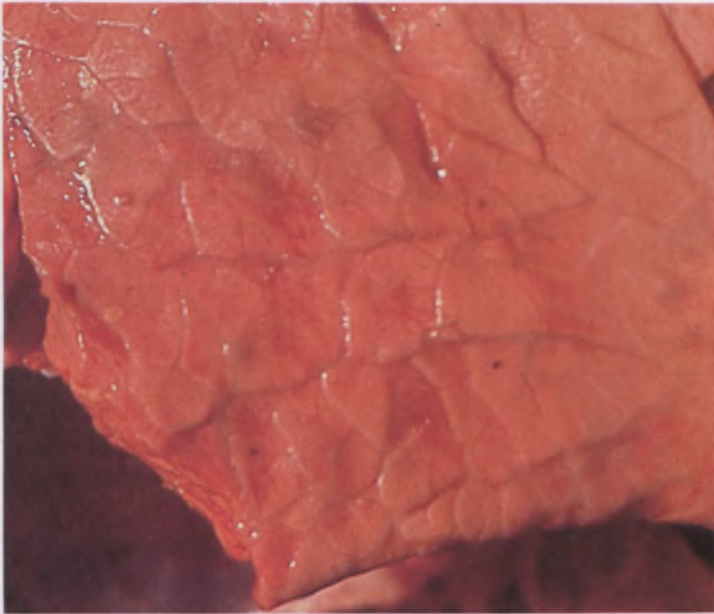


PLATE 418: PULMONIC SCARRING AND FOCAL CHRONIC PASSIVE CONGESTION

The several opaque white areas on the lung surface of this dog are areas of fibrosis and have the same cause as the overall brown red lung surface. These areas and the color is the result of vascular compromise with blood breakdown and stasis because of vascular thrombosis and embolism. The dog had heartworms, *Dirofilaria immitis*, and parts or all of some parasites blocked the vessels to these areas. Apparently it was temporary for the large tan lobe as it was not infarcted at necropsy.



Dr. F. Fox, Cornell, USA

PLATE 419: POST FOGGING PNEUMONITIS OF CATTLE

This portion of lung from a cow shows many scattered firm, slightly green 3-4mm nodules throughout the lungs. On exposure to air they turn yellow with time. Many Jersey cows in the herd showed an acute slight to moderate respiratory distress problem with a drop in milk production after being sprayed around the face and head for flies with insecticide before being let out to pasture daily. In several, necropsied for diagnostic purposes, the above lesion was seen. Histologically sections of dead parasites were seen in these lesions along with lungworms in the major airways. They were all identified as *Dictyocaulus viviparus*. The larvae were apparently killed in the tissues by the cows inhaling the insecticide.

Dr. L. Roth, Oklahoma, USA

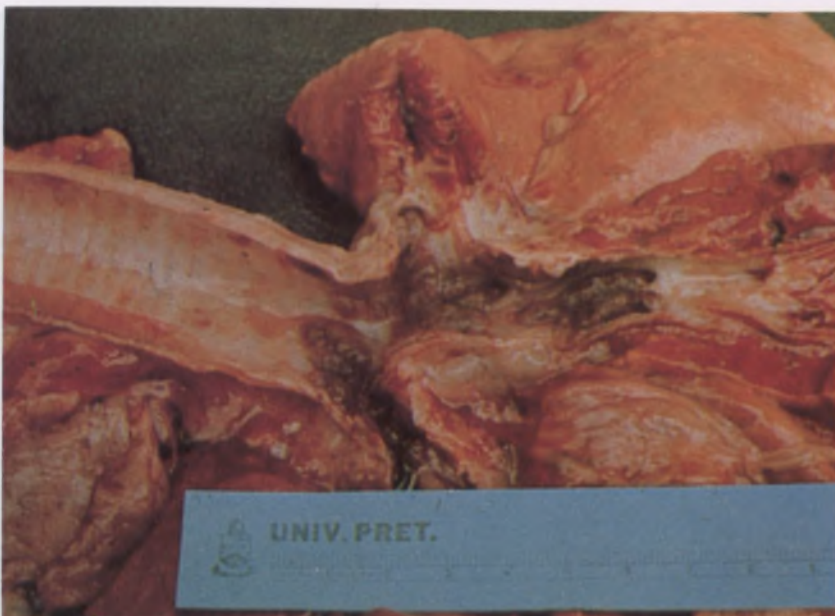
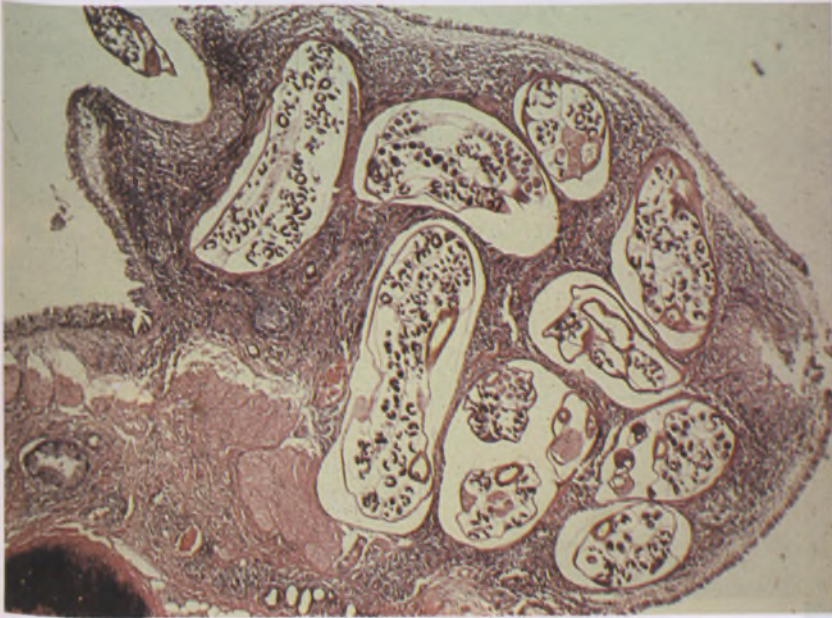
PLATE 420: PARASITIC (*FILAROIDES OSLERI*) TRACHEOBRONCHITIS

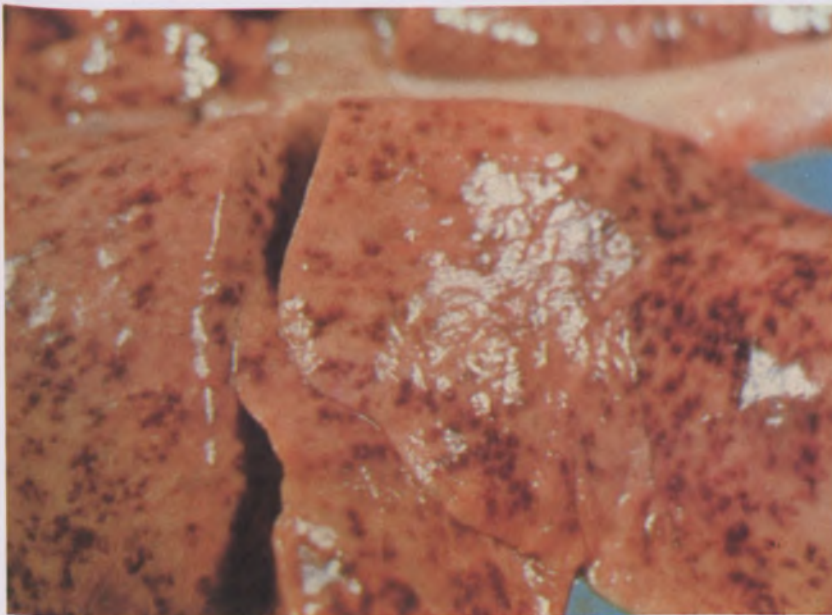
The distinct brown masses attached at the bifurcation of the trachea and down the bronchi are granulomatous brood pouches caused by *Filaroides osleri*. These are extremely common in dogs in South Africa but are found pretty much worldwide. Although related to, it is not the same as *Filaroides hirthi* which inhabits the lung proper.

Dr. J. Georgi, Cornell, USA



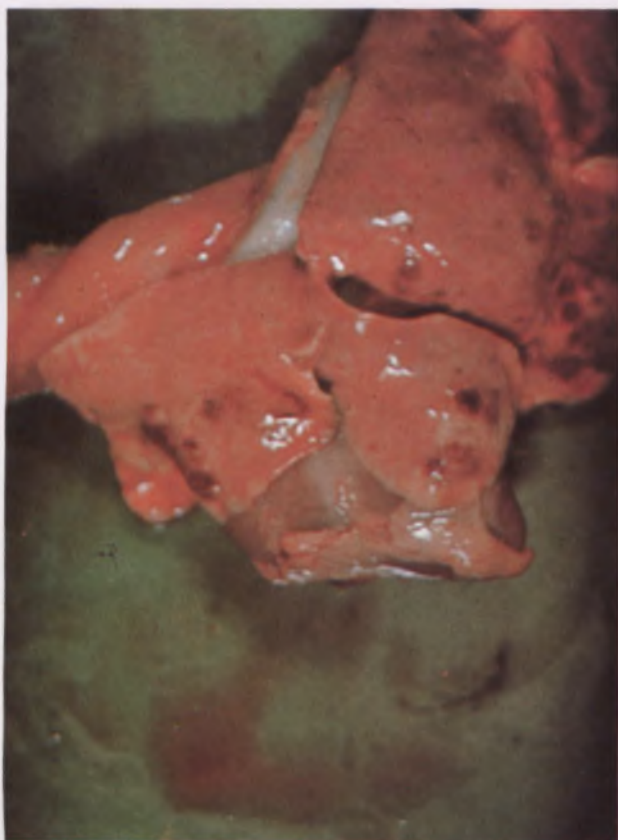
**PLATE 421: VERMINOUS (FILAROIDES OSLERI)
TRACHEOBRONCHITIS**

This is the microscopic appearance of the *Filaroides osleri* brood pouch embedded in the mucosa of the distal trachea. Several cross sections of coiled worms can be seen.



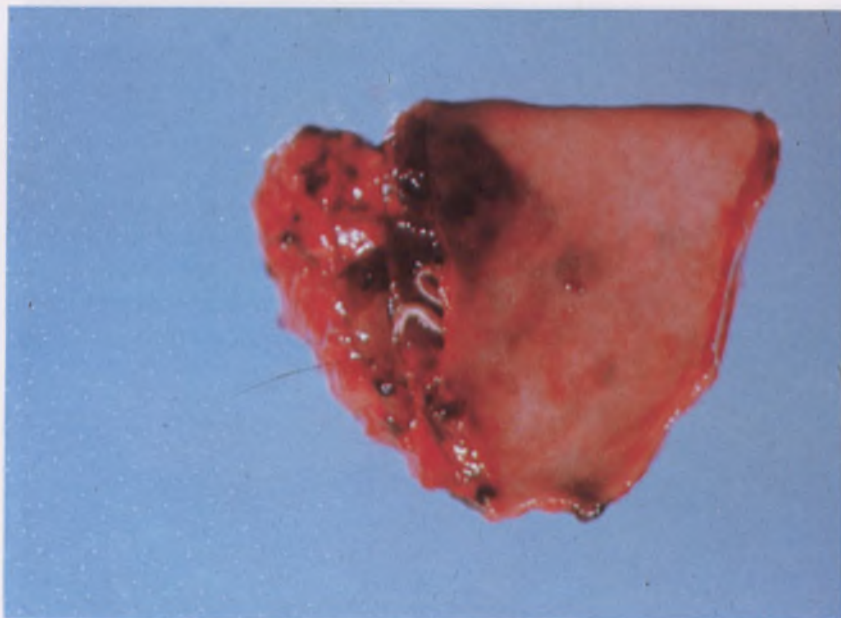
**PLATE 422: EXPERIMENTAL CANINE
VERMINOUS (FILAROIDES HIRTHI) PNEUMONIA**

The large number of petechiae are the result of local inflammation in the parenchyma as the result of an experimental infection with the dog lungworm, *Filaroides hirthi*. This is to be differentiated from *Filaroides osleri* which forms brood nodules in the tracheal and bronchial mucosa. The natural lesion in dogs is very difficult to see grossly and is usually picked up microscopically.



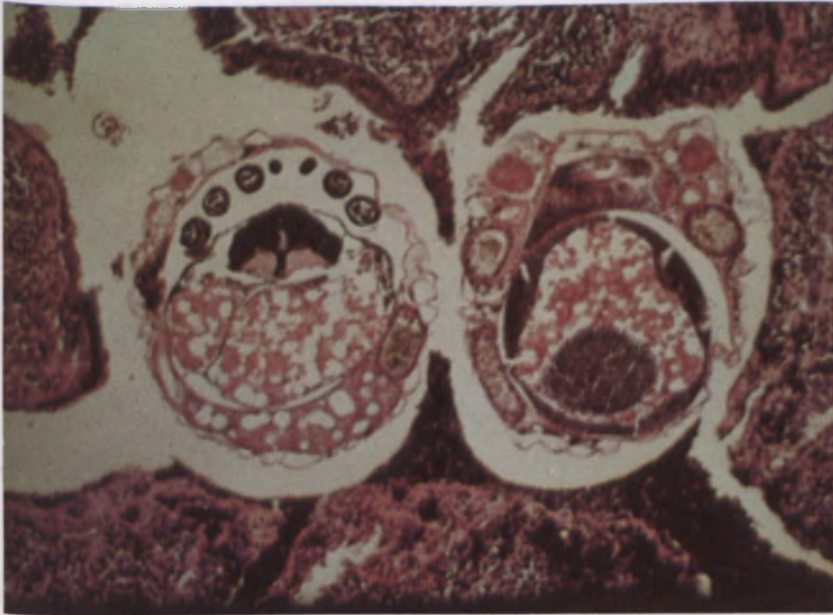
**PLATE 423: MULTIFOCAL PARASITIC
(STRONGYLOIDES CANIS)
PNEUMONIA**

The dozen or so dark red, slightly swollen areas scattered in this dog's lung lobes are the result of the migration of *Strongyloides canis* larvae. They could just as well have been caused by ascarid migration.



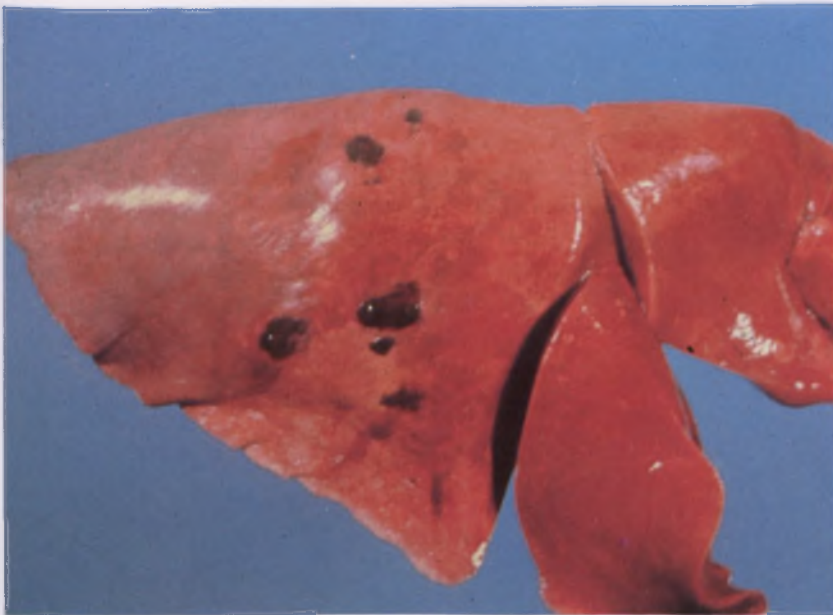
**PLATE 424: FOCAL PARASITIC
(STRONGYLUS SPP.)
PNEUMONIA**

This is a portion of lung with the larval form of *Strongylus edentatus* in an area of acute hemorrhagic inflammation. These parasites are the most commonly aberrant strongyles in migration, and can be seen in other tissues as well as in their more normal migratory route via the retroperitoneum especially around the kidneys.



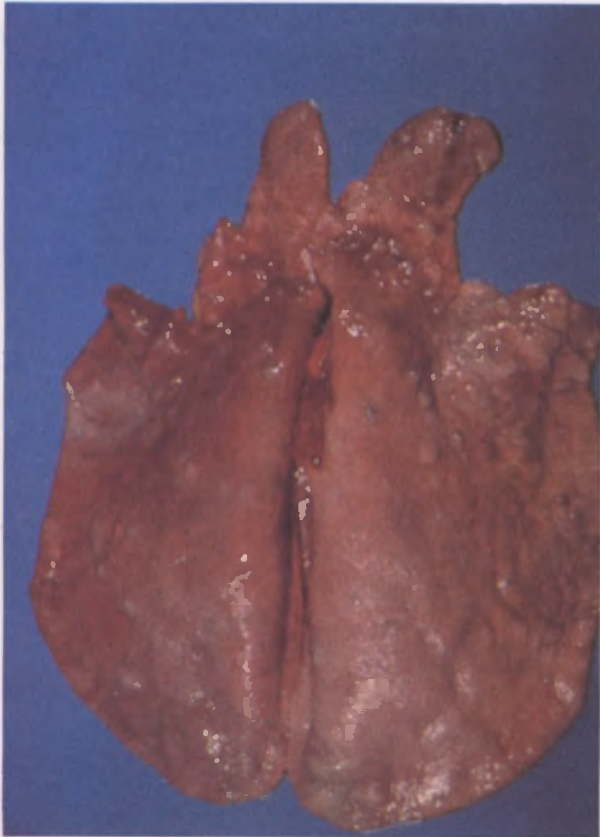**PLATE 425: BRONCHOPULMONARY
ACARIASIS (PNEUMO-
NYSSUS SIMICOLA)**

Airway parasites are of several kinds. The two shown here are actually cross sections of arthropods (=jointed legs) in the bronchiole of a rhesus monkey. The brown black pigment in the tissue around these parasites is also characteristic. The life cycle of these lung mites, *Pneumonyssus simicola*, is unknown but it is a very common finding. Brownish black pigment in the lung or any tissue should make one also consider the presence of flukes.



**PLATE 426: MULTIFOCAL PARASITIC
(FASCIOLOIDES MAGNA)
PNEUMONIA**

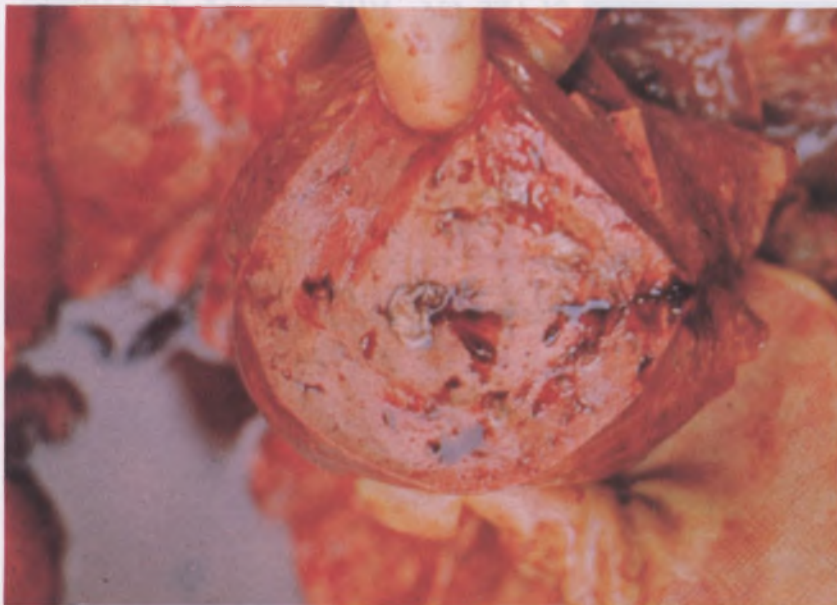The several black areas, three of which are slightly raised, are pigmented areas of fluke infection in the lung. Out of context, they could be one of several flukes even *Paragonimus kellicotti* in the dog as it is characteristic for many flukes to be associated with a blackish pigment. In this case they are due to wandering *Fascioloides magna*, the large liver fluke, in a sheep.



Dr. R. Hillman, Cornell, USA

**PLATE 427: MULTIFOCAL PARASITIC
(*STRONGYLUS EDENTATUS*) PNEUMONIA**

Multiple grey to yellow, raised nodules can be seen on the surface of this horse lung. They are also scattered deep in the parenchyma and may be in other tissues as well. These are caused by the aberrant migration of *Strongylus edentatus* larvae. Other strongyles can cause these.



**PLATE 428: PARASITIC PULMONARY
EMBOLISM AND
THROMBOSIS**

A portion of dog's lung has been cut open to reveal a vessel near the center filled with a clump of dead heartworms, *Dirofilaria immitis* and several smaller vessels nearby filled with thrombotic debris. This was the result of treatment which killed the worms in the heart which then embolized to the lung as dead parasitic emboli. The thrombi in nearby vessels may have reached the lung as emboli from the heart or they could have formed *in situ*.

Dr. C. I. Liu, Taiwan, ROC

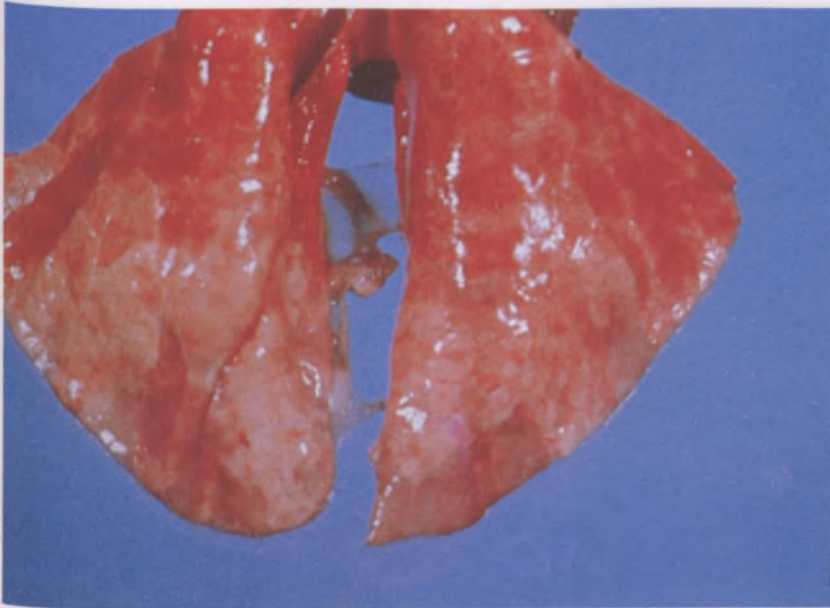


PLATE 429: VERMINOUS (*METASTRONGYLUS* SPP.) PNEUMONIA

The blue tinged square or rectangular areas along the edges of the diaphragmatic lung lobes are focal areas of bronchopneumonia caused by the presence of lungworms, *Metastrongylus* spp. blocking the distal small airways of these areas with mucus and other debris. This is the same lesion and same location as for *Dictyocaulus* spp. in horse, cattle and sheep as all of these parasites live in the major bronchi of the caudal diaphragmatic lobes. When the worms are found elsewhere, especially without any reaction, it is usually because of postmortem migration.

Dr. F. Meeker, Cornell, USA

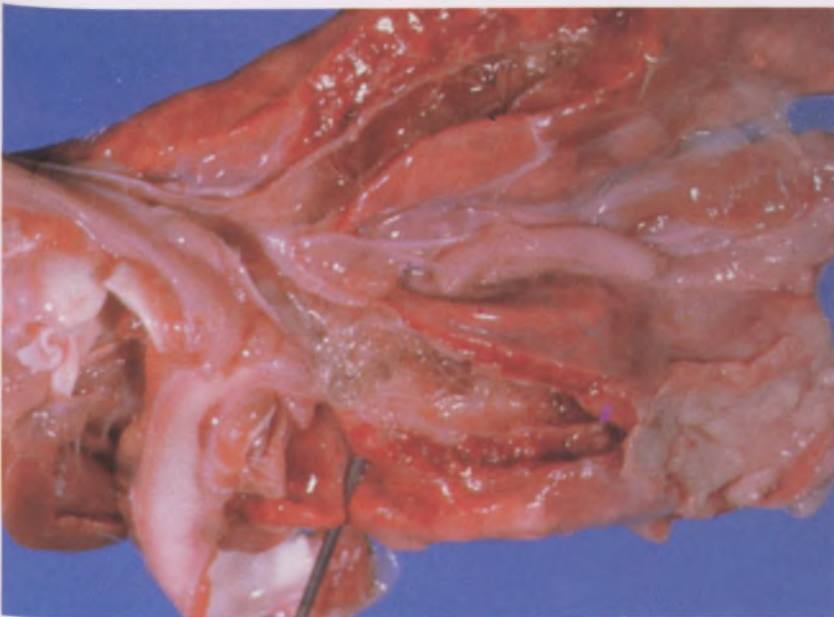


PLATE 430: VERMINOUS (*METASTRONGYLUS* SPP.) BRONCHITIS

The numerous thin white worms in the airway of this pig's lung are *Metastrongylus* spp. They live in the airways, primarily of the diaphragmatic lobes, and damage is done by blocking the distal smaller airways. A rather large number of these worms may be present in animals without clinical signs except for an occasional cough.

Dr. B. Cooper, Cornell, USA

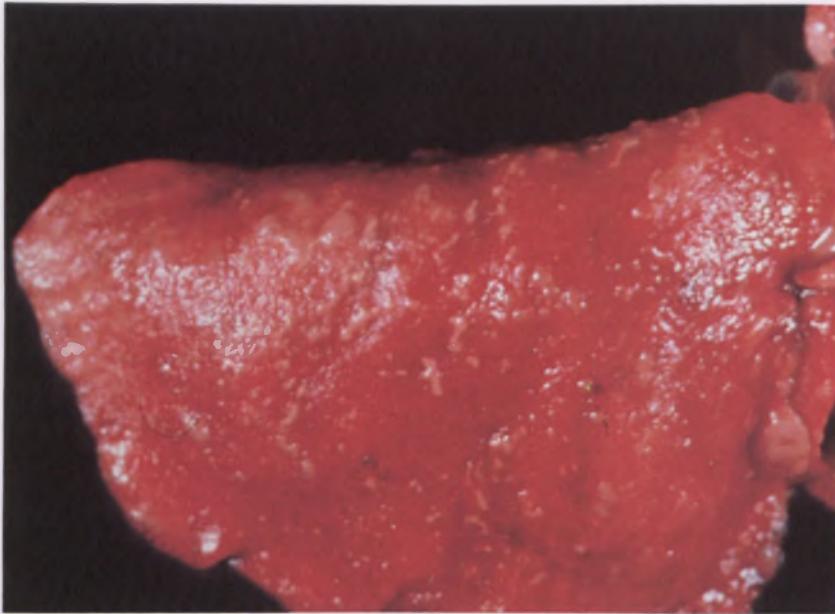

PLATE 431: VERMINOUS (*AELURO-STRONGYLUS ABSTRUSUS*) PNEUMONIA

The multiple pale, firm, white foci in this not bled out cat's lung are granulomas, caused by *Aelurostrongylus abstrusus*, the common cat lungworm. These have coiled developing larvae, eggs and debris in them histologically. Of note is that some of these are slightly elongated. Occasionally one can find the black adult worm grossly under the pleura of the lung proper. One has to distinguish these pale foci from the common, pale, tiny foci of focal emphysema in a congested area of lung.

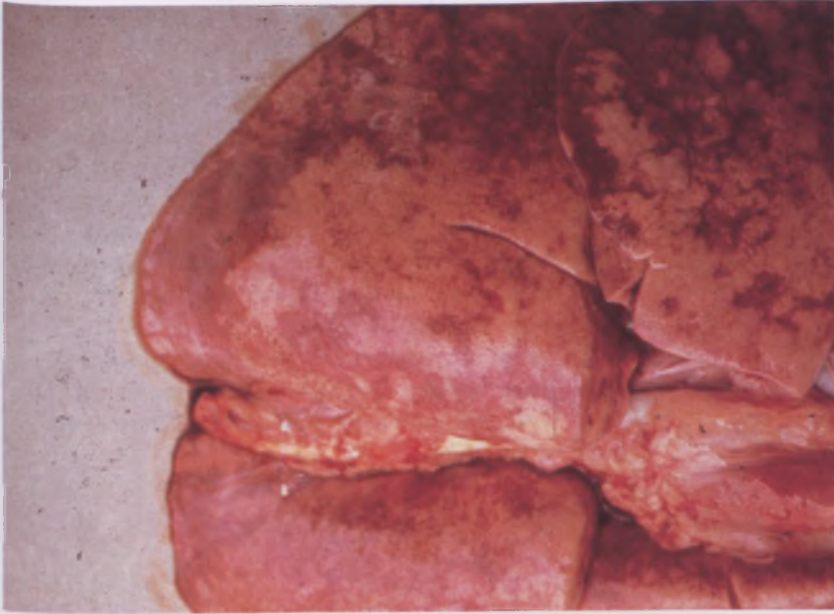
Dr. P. Meunier, Cornell, USA

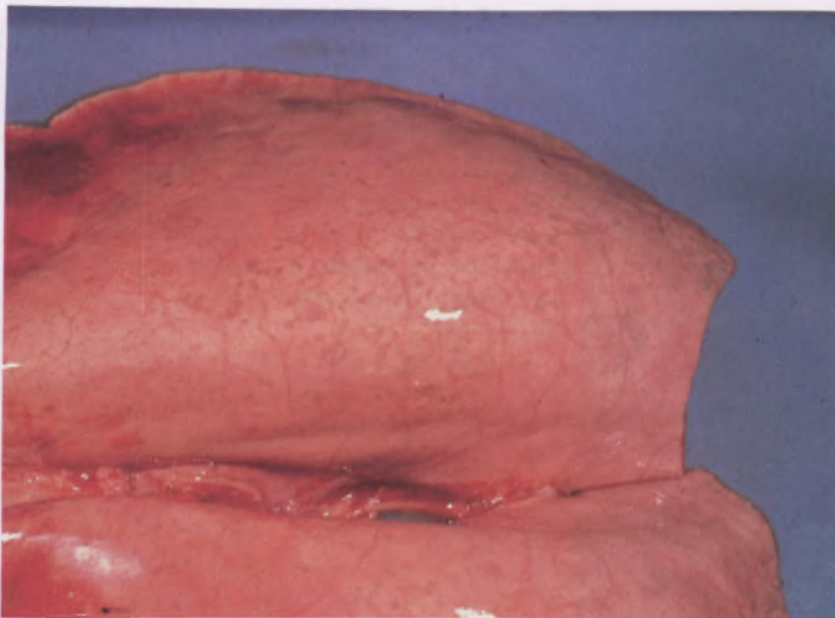

PLATE 432: VERMINOUS (*MUELLERIUS CAPILLARIS*) PNEUMONIA

The multiple tiny nodules scattered in this sheep's lung are the granulomas caused by almost microscopically sized *Muellerius capillaris* which live in the alveoli as different from the larger focal areas of bronchopneumonia caused by the larger lungworms *Dictyocaulus* spp. and *Protostrongylus* spp. that live in the larger airways. These are usually not clinically evident.

Dr. C. I. Liu, Taiwan, ROC

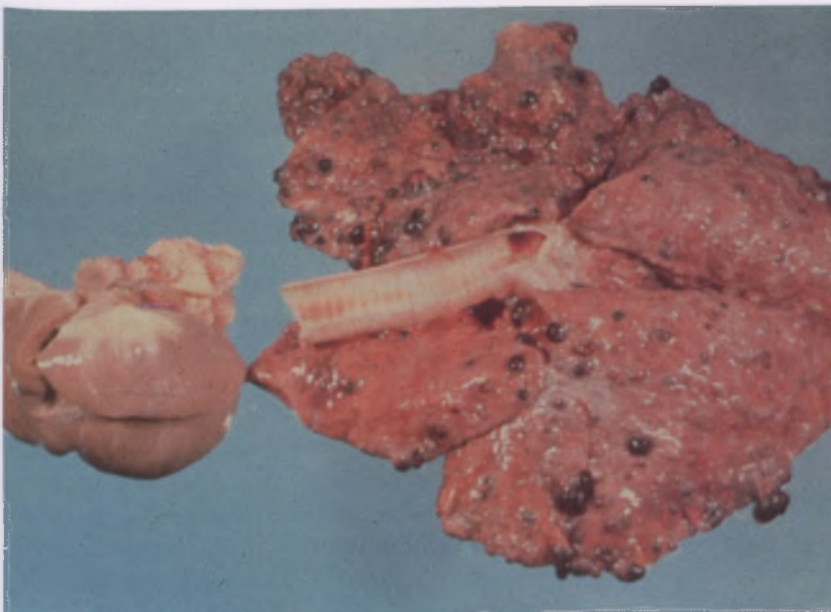


**PLATE 433: PULMONARY
LYMPHOSARCOMA**

This lung is diffusely firm and only the paler areas contain appreciable air. Histologically the lung was diffusely infiltrated with malignant lymphoid cells. The original complaint of the owner was that the dog coughed.

This shortage of blood supplies sent on the heart proper will prevent the heart from filling, or both, and the animal will die.

PLATE 434: HYDROPERICARDIUM



**PLATE 434: METASTATIC
HEMANGIOSARCOMA
OF THE LUNG**

The multiple, red bloody masses are metastatic foci of hemangiosarcoma from the right atrium. The primary site can be seen as an irregular mass on the right atrium. For some reason the right atrium is often involved with hemangiosarcomas this is common enough to make one think that it is more than by chance. One idea given is that the right atrial region in the fetus has hematopoietic tissue that might remain and undergo neoplastic transformation at a later stage.

Dr. B. Cooper, Cornell, USA

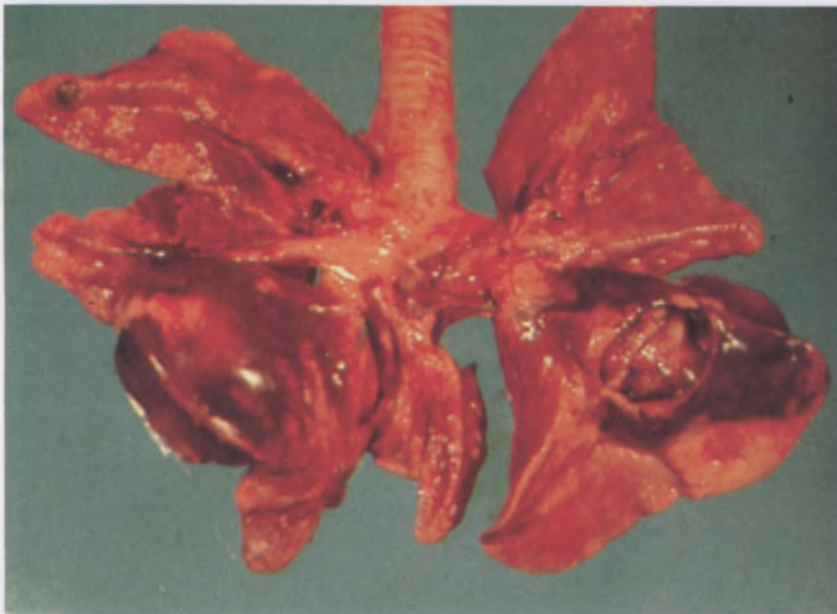

PLATE 435: METASTATIC OSTEOGENIC SARCOMIA

This dog had a typical Osteogenic Sarcoma of a long bone that metastasized to the lung. There are two large, grossly visible, metastatic foci, one in each diaphragmatic lobe and one smaller nodule in a cranial lobe. Of interest, but without known reason, is why does the Osteogenic Sarcoma more often than other malignant tumors form single large nodules in both diaphragmatic lobes. Of course the majority of metastatic tumors to the lungs, be they Osteogenic Scarcomas or any other type, are often multiple, well scattered and of various sizes.

Dr. P. Reunier, Cornell, USA

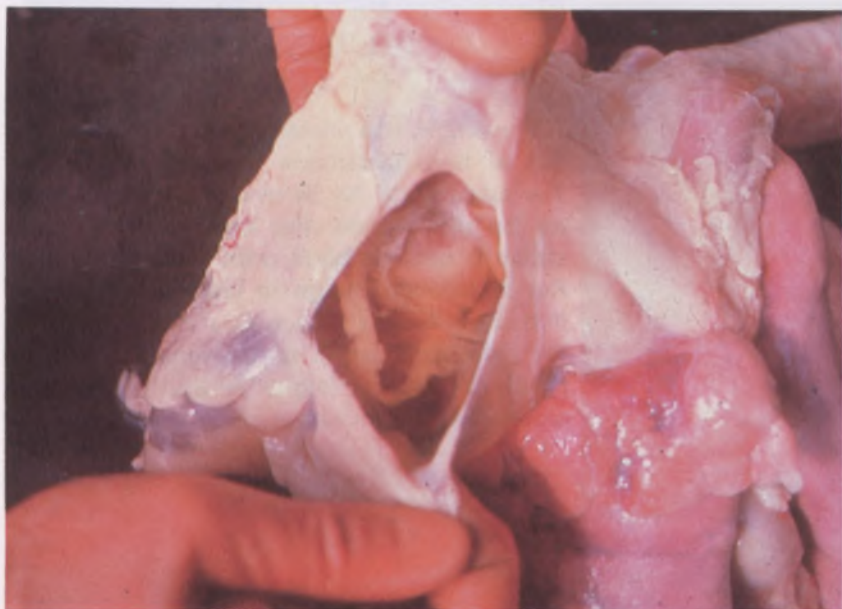

PLATE 436: HYDROPERICARDIUM

The heart sac of this cow has been opened to show the fibrin and fluid contained within. Often this Hydropericardium is the only lesion of Heartwater caused by *Cowdria ruminantium*. The way to prove this diagnosis is to use two glass slides, and squeeze off a portion of hippocampus between their end edges, and then mash the brain section ten or so times between the two slides. Then scrape the mashed brain onto the end of one of those two slides. Place the mashed tissue on one end of a new clean slide and draw it about 1 cm. Pick the slide up about 2–3 mm and move it forward and draw it again. Do this 4–5 times and then dry and stain. The stretched out hippocampal capillaries, with their endothelial cells stained with a modified Wright's stain for *Cowdria ruminantium* organisms in the endothelial cells, or other organisms such as *Theileria spp.*, and even Rabies inclusion bodies can be well demonstrated by this technique.

Dr. B. Cooper, Cornell, USA

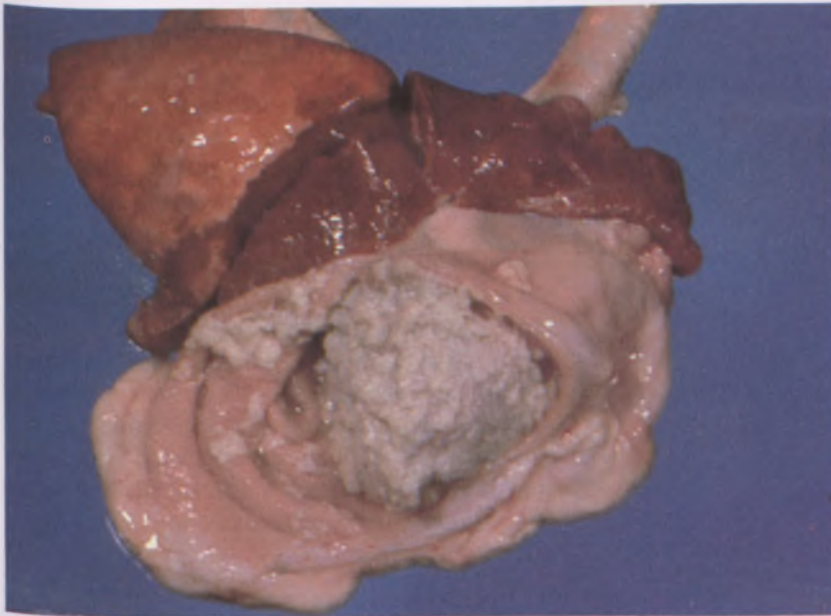


PLATE 437: CHRONIC ACTIVE FIBRINO-PURULENT PERICARDITIS

The markedly dilated pericardium in this goat is an example of a Chronic Active Pericarditis. One of many common pathogens can cause this lesion. In cattle it is often secondary to a wire or nail foreign body, that gets trapped in the reticular wall and pushed forward through the diaphragm into the heart sac (Traumatic Reticulitis, Peritonitis and Pericarditis) in turn. In most other animals it is usually derived from a hematogenous spread. The white fibrinous and fibrous shreds on the heart proper suggest it is more likely a *Streptococcus* spp. than *Corynebacterium pyogenes* infection. The dark red cranial ventral lung lobes are firm from red hepatization, caused by Enzootic Pneumonia. In time, the fluid in the heart sac can prevent the low pressure venous return to the heart, or, the maturation shrinkage of fibrous connective tissue on the heart proper will prevent the heart from filling, or both, and the animal will die.

Dr. W. Sack, Cornell, USA

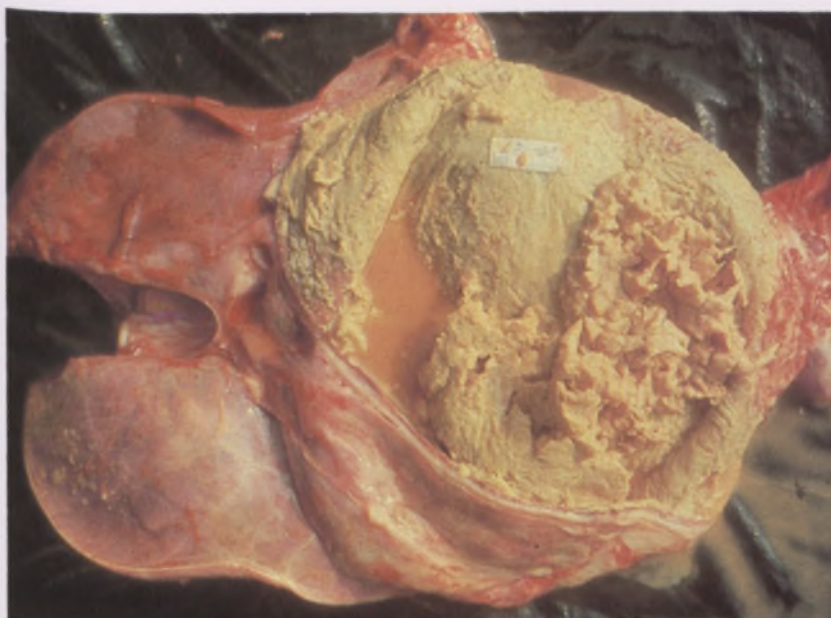


PLATE 438: CHRONIC FIBRINO-PURULENT PERICARDITIS

The massively distended pericardial sac has been opened to show the purulent fluid and fibrin that caused the distention in this pig. The actual agent was not identified but *C. pyogenes* is often found as well as Streptococci and Staphylococci. While the term "bread and butter" has often been used to describe this in the vernacular it is thought that "scrambled eggs" would be more appropriate.

Dr. R. Chu, Taiwan, ROC

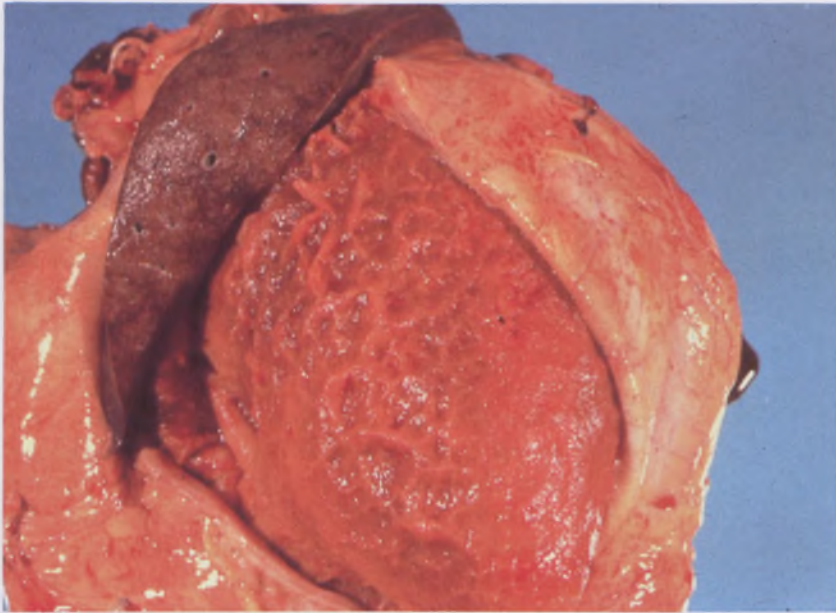


PLATE 439: CHRONIC ACTIVE PERICARDITIS

The heart sac has been opened to show the well marked hemorrhagic Chronic Active Pericarditis in this horse. It is chronic for two reasons. The pericardium is thickened by connective tissue increase and the piece of liver present shows the well marked Nutmeg appearance of Chronic Passive Congestion. It is active because of the free blood present and the fibrin coat on the heart proper. Actually, the cause of this lesion is not known for certain in most cases. Cultures are often negative, but a hematogenous organism could certainly be responsible. In one experiment, 2 of 6 horses inoculated with blood from horses with Theiler's Disease died with this lesion within a year but no cause or effect relationship was established.

Dr. B. Tennant, Cornell, USA

PLATE 440: LYMPHOSARCOMA

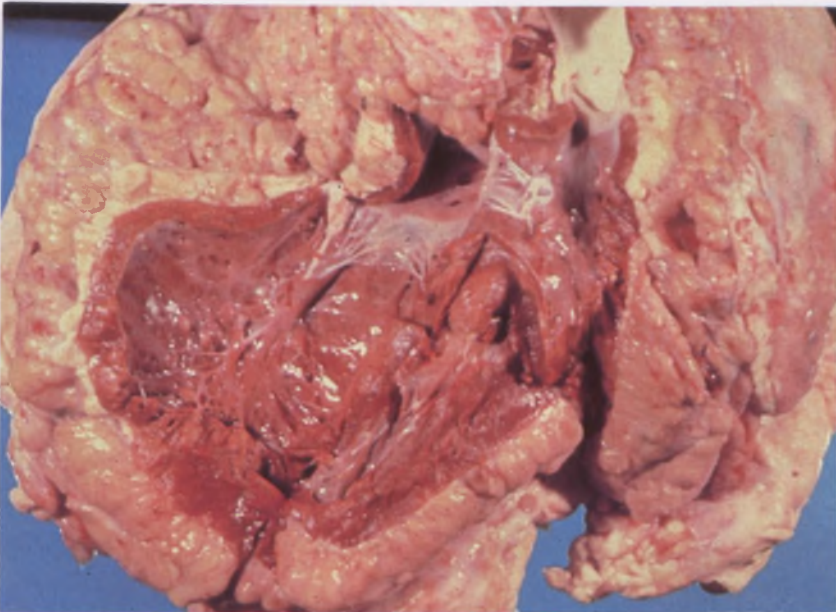
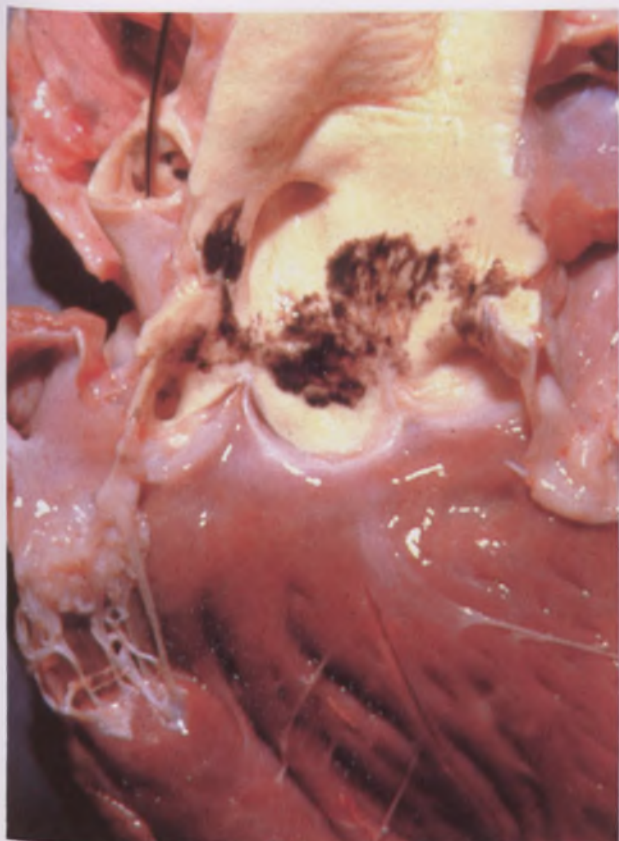


PLATE 440: LYMPHOSARCOMA

The massive infiltration of the pericardium on this cow's heart is one of the many manifestations of Lymphosarcoma. It can affect other animals in the same fashion.



Dr. W. Sack, Cornell, USA

PLATE 441: INTIMAL MELANOSIS

The black pigment in the intimal lining at the base of this sheep's aorta is normal Melanosis. It is also normal for it to be present in the stomach, adrenal, uterus, kidneys, lungs, meninges and brain.

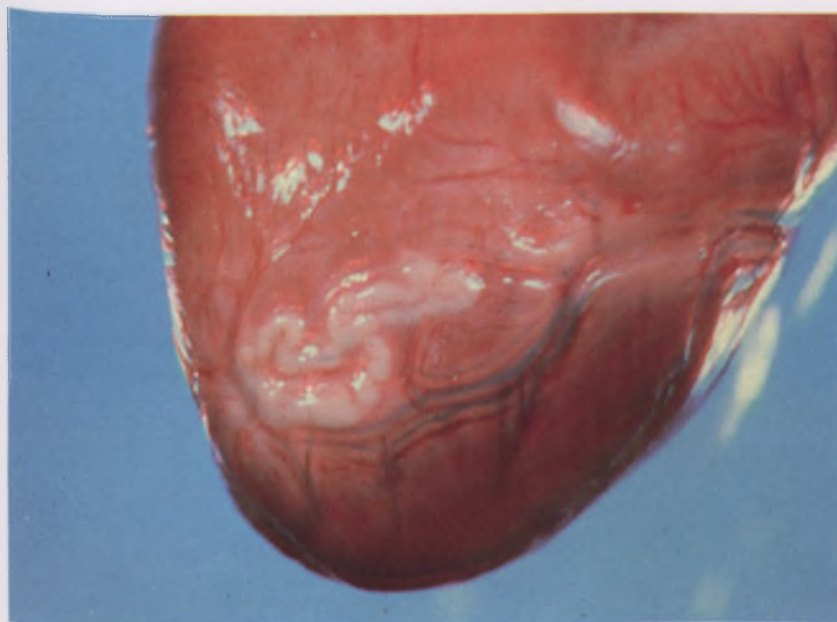


PLATE 442: LYMPHATIC VESSEL ANOMALY

The pale worm like lesion on the ventricular surface of this dog's heart is a blind ended Lymphatic Vessel Anomaly filled with partially inspissated lymph. It is a common anomaly in dogs and horses.

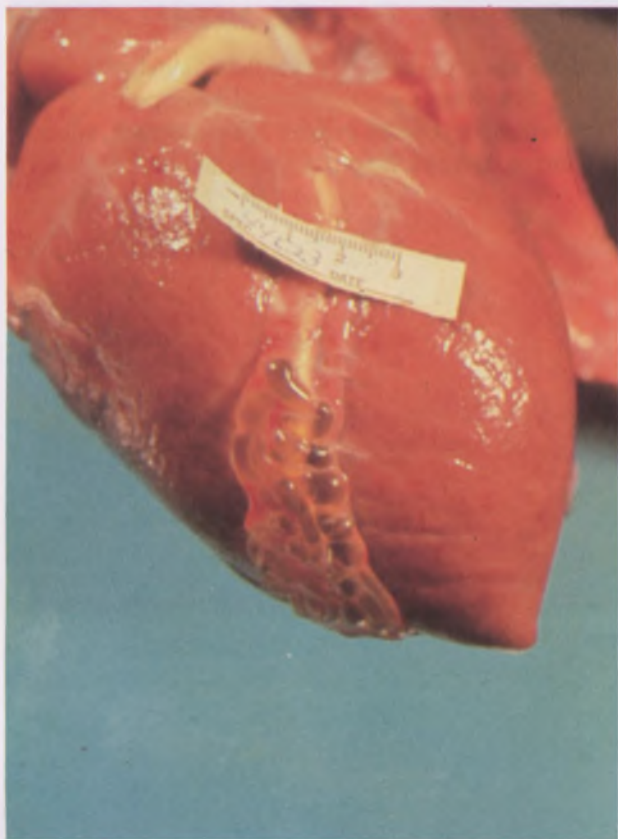

PLATE 443: LYMPHATIC ANOMALY

The clear fluid filled tortuous structure on the surface of this horse's heart is a lymph filled, blindended Lymphatic Anomaly. These are common in horses and dogs.

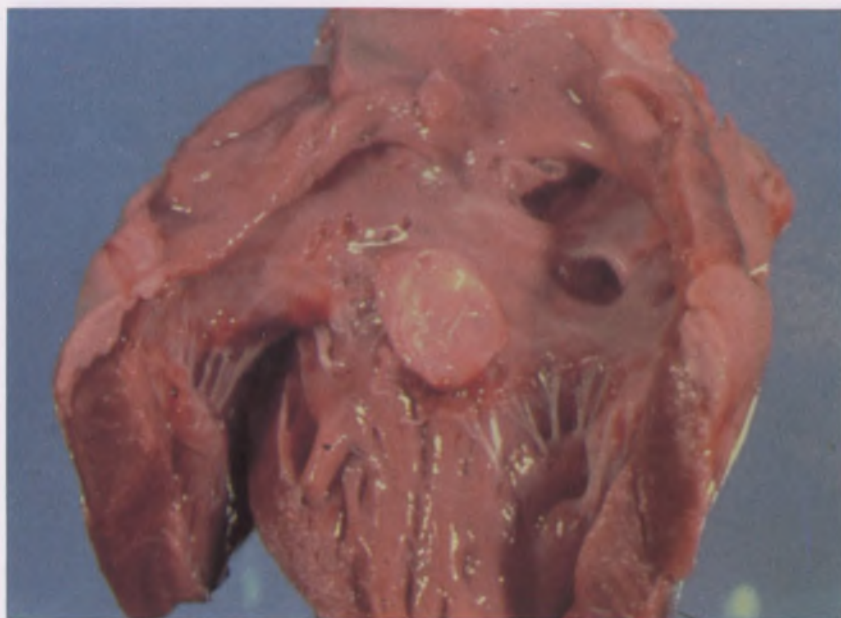


PLATE 444: CONGENITAL VALVULAR CYST

The large pale cyst on and above this septal cusp of the right atrioventricular valve of this calf's heart is a Congenital Cyst. Most of these are thought to be of blood or lymphatic vascular origin depending on their content. This one had only clear fluid suggesting its lymphatic origin. At one time it was thought these resulted from the marked turbulence generated in the heart at the time of birth but as these are also common in dead aborted calves this is probably not the reason.

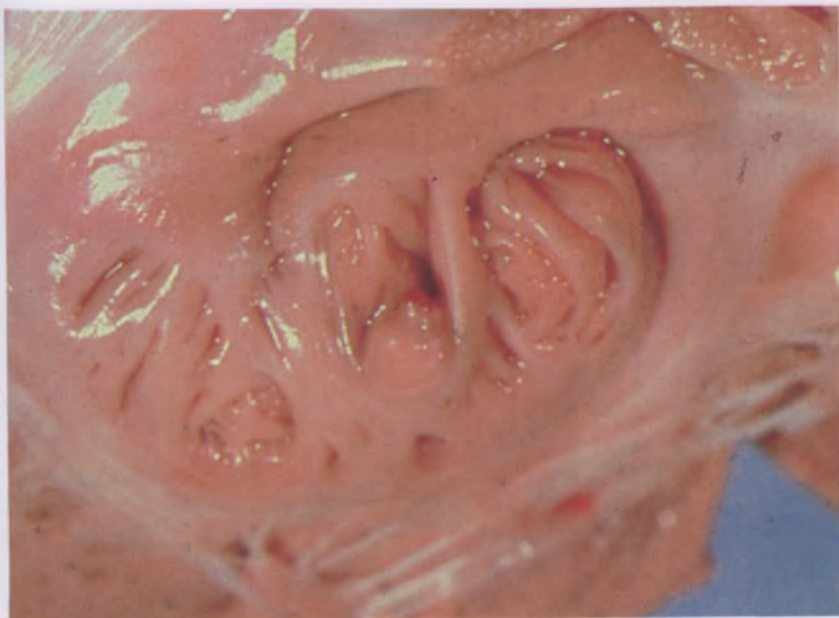


PLATE 445: ARTERIOVENOUS SHUNT ANOMALY

The tiny round mass of muscle tissue with a red nodule protruding from it is an Arteriovenous Shunt Hamartoma. It is a relatively common anomaly in calves, but rarely seen in older cattle.

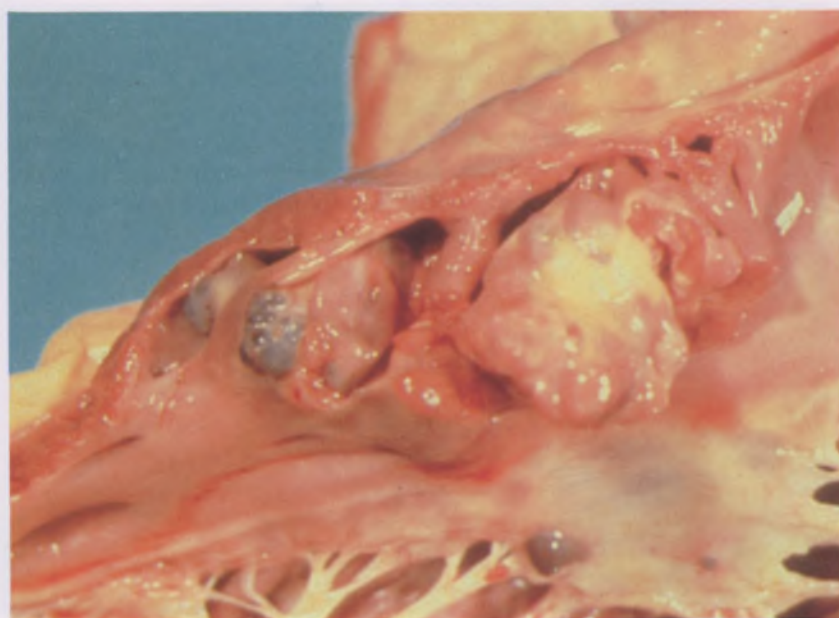

PLATE 446: ARTERIOVENOUS SHUNT

The several large knobby masses mixed among the pectinate muscles of the left atrium in this 6 year old cow are an Arteriovenous Shunt. It has also been called a Vascular Hamartoma. It is really a single lesion in spite of the several masses that make it up. In fact, its arterial nature can be surmised from the portion which is pale white and thick walled whereas the venous portion is thin walled and blue.

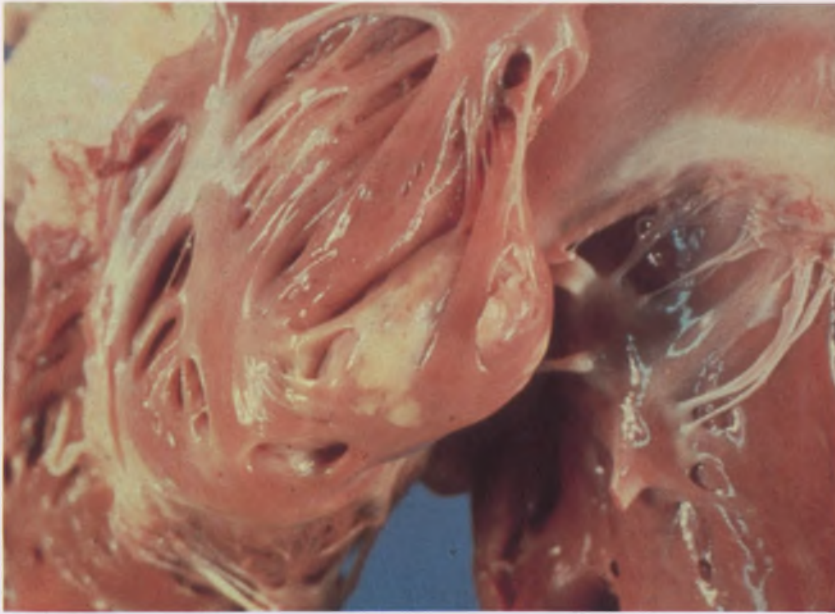

PLATE 447: ARTERIOVENOUS SHUNT

The lump in the wall of the left atrium intermingled with the pectinate muscles is a Vascular Anomaly in this 3 year old cow. The great majority of these are seen in very young calves. They consist of a twisted complex of blood vessels that can be considered a Vascular Hamartoma; some have shown them to be an Arteriovenous Shunt Nodule. They are not significant.

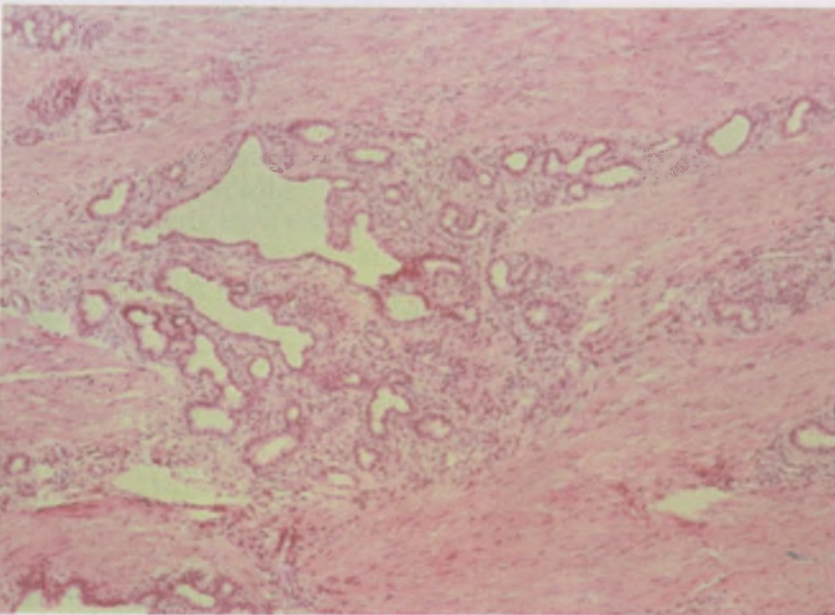
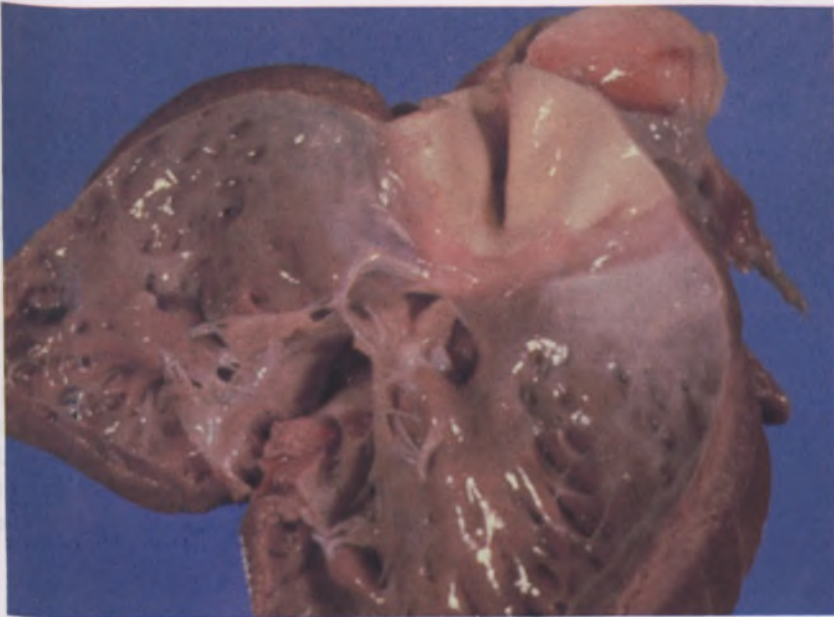

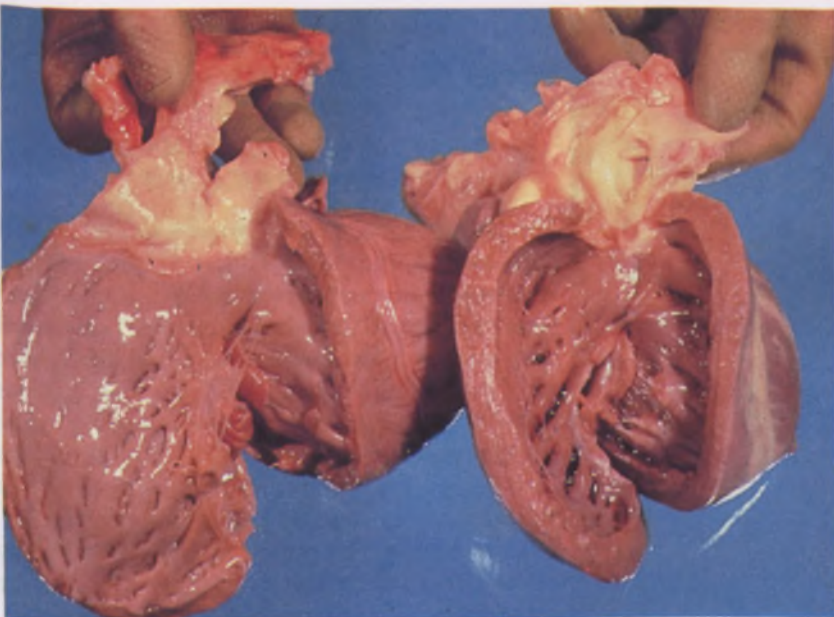
PLATE 448: ECTOPIC GUT EPITHELIUM

Grossly, this tissue was a single, white, 2 cm nodule in the left ventricular myocardium. Histologically, the cystic spaces are lined by a simple cuboidal epithelium. These are seen now and then in calves especially and it is presumed that they are embryologically displaced pieces of gut epithelium.



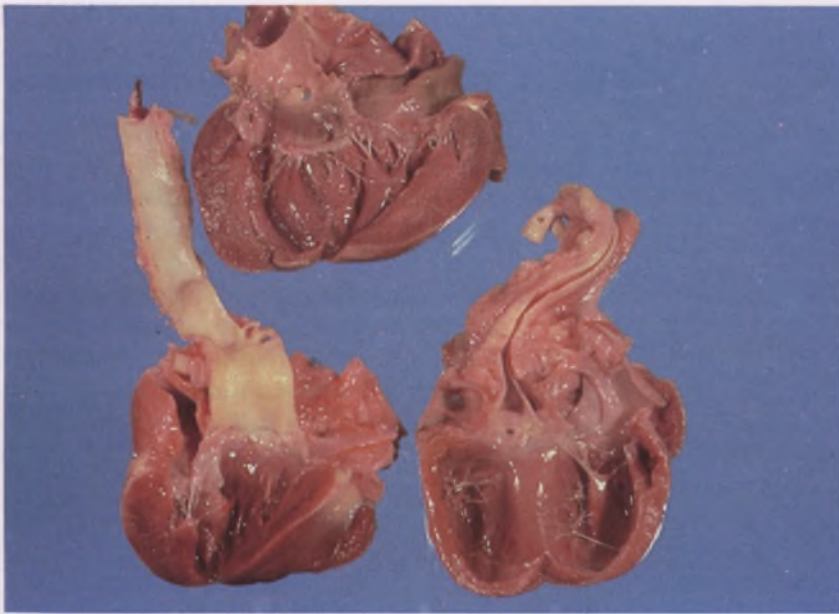
**PLATE 449: CARDIAC DILATATION,
SEPTAL DEFECT AND
SPLASH REACTION**

The right heart has been opened to show its marked degree of dilatation, its thin wall, the well marked irregular Subaortic Septal Defect below the pulmonary valve and the grey white area of endocardium opposite the septal defect and also under the pulmonary valve. These grey white areas are examples of Jet Lesions (Regurgitation Lesion or Splash Reaction) which result from the turbulent flow of blood caused by the Septal Defect Anomaly. They apparently affected this calf *in utero* as it only lived five days.



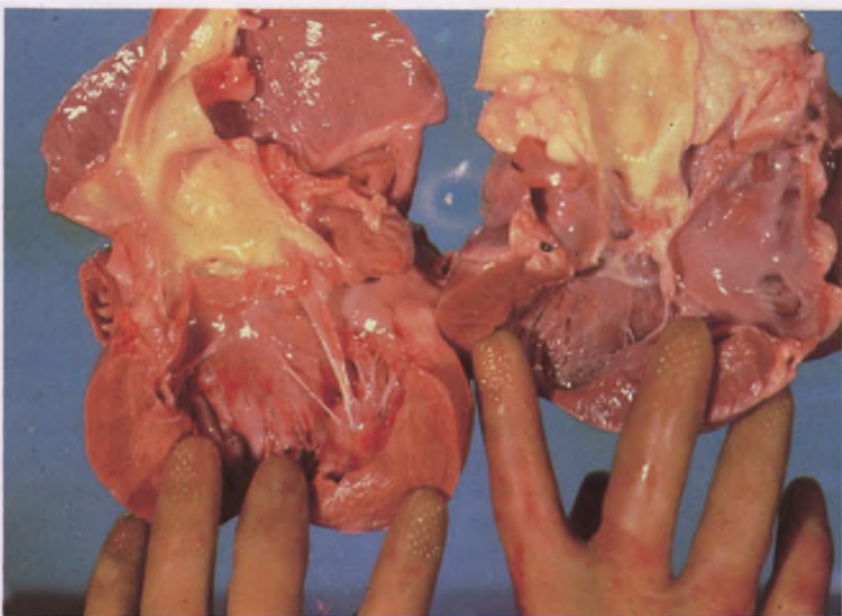
**PLATE 450: PULMONIC STENOSIS WITH
SECONDARY HYPERTRO-
PHY, DILATATION AND
POSTSTENOTIC
DILATATION**

Both these hearts from two dogs have opened through the right ventricular wall, and show the outflow region through the pulmonary valve. The larger heart is normal, while the other heart shows a thickened Hypertrophied Myocardium as a result of the small orifice at the pulmonary valve, called Pulmonic Stenosis. The pulmonary artery above this has a definite pink dilated and thinned portion called Poststenotic Dilatation, seen in the wall just under the thumb. The Stenosis is an anomaly and the Myocardial Dilatation and Hypertrophy and Poststenotic Dilatation are considered Compensatory Changes.



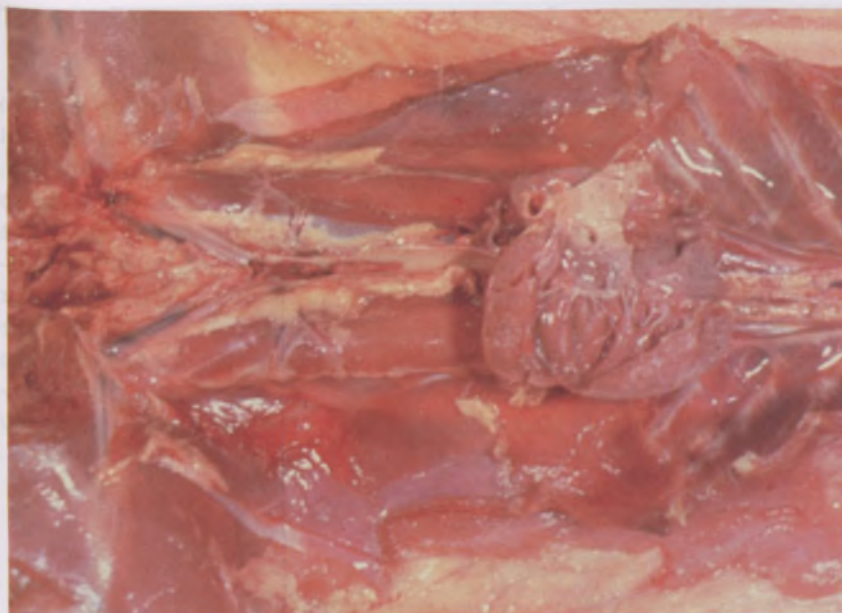**PLATE 451: SUBAORTIC STENOSIS,
CONGESTIVE AND
HYPERTROPHIC
CARDIOMYOPATHY**

The three cats all died as a result of heart disease. The heart by itself has a markedly hypertrophied left ventricular wall, a dilated left atrium and a definite complete band of connective tissue, forming the anomalous Subaortic Stenosis. The cat heart with the pale aorta has a very thickened left ventricular wall, and dilated left atrium and auricle. This is Hypertrophic Cardiomyopathy. The third heart shows a slightly dilated left atrium and a markedly dilated, thin walled left ventricle typical of Congestive Cardiomyopathy. The causes of all these problems are unknown although the Subaortic Stenosis is an anomaly.



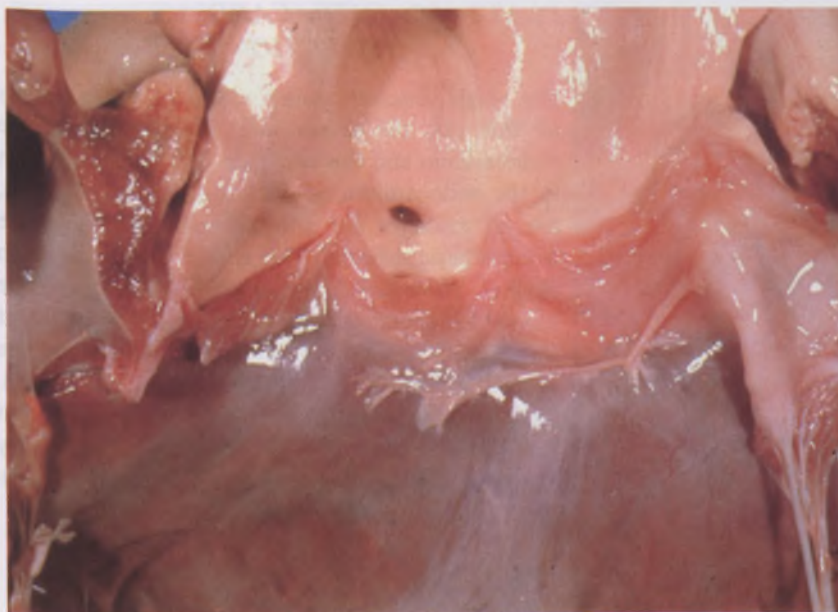
**PLATE 452: SUBAORTIC STENOSIS,
AORTIC VALVE EDEMA
AND SUBENDOCARDIAL
HEMORRHAGE**

The larger, redder heart is from a normal dog. It does have Aortic Valve Edema at the proximal attachments of the cusps, which is a common terminal artefact. It also has numerous Endocardial Hemorrhages, which are likewise of no significance and are terminal artefacts. The other heart however shows a ragged portion of mature connective tissue on the septal wall endocardium, just under the aortic cusps, which has limited the diameter of the aortic ostium; an anomaly called Subaortic Stenosis. A slight increase of pinker fibrous tissue leading up to and on the aortic cusps themselves may be reactive to the turbulent blood flow in the area.



**PLATE 453: SUBAORTIC STENOSIS
AND AORTIC THROMBOSIS**

The opened heart has been placed in the abdominal cavity of this cat. The heart itself shows a well marked Subaortic Stenosis formed by a fibrous ring located on the septal wall, just under the aortic valve. As a result of this anomaly, thrombi have formed which have embolized to the abdominal aorta at the bifurcation, to make a lesion called Aortic Thrombosis. Often acute caudal paresis is the first sign noted in such cases. The cause of the thrombi is sometimes found to be thrombosis, within the left auricle or atrium, and at other times no specific focal source can be found. Some consider them as forming in a direct result of shearing type damage to the red blood cell, as it is pushed past the constriction site. It occurs in other animals but cats are the most likely animal affected.



**PLATE 454: INCOMPLETE SUBAORTIC
STENOTIC RING**

The small tag of fibrous tissue, attached to the endocardium just under the cusps of the aortic valve in this young cow are the remnants of an Incomplete Subaortic Stenotic Ring. This anomaly is quite important economically in pigs, in some parts of the world more than others.

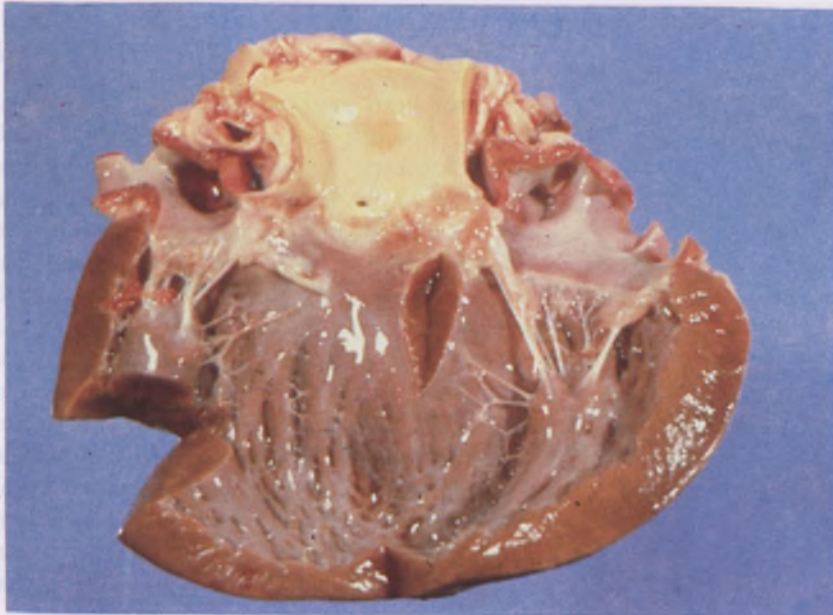


PLATE 455: INCOMPLETE SUBAORTIC STENOTIC RING

Just under the aortic cusps of this dog are two irregular bands of mature connective tissue adherent to the ventricle, an Incomplete Subaortic Stenosis. One is still intact and the other has been cut to show its lack of deep penetration. Just above the cut piece there is a slight irregularity of the overlying cranial cusp of the left atrio-ventricular (bicuspid) valve. This is part of the anomaly. The right half of this cranial cusp is not affected by the Anomalous Subaortic Stenotic Ring. This incomplete form and the complete form are relatively common anomalies.

Dr. G. Bolton, Cornell, USA

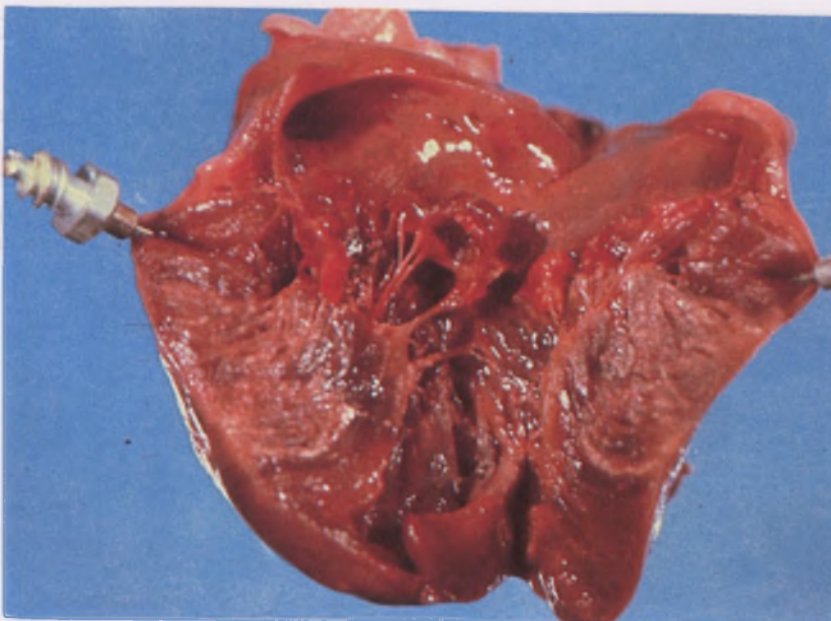


PLATE 456: INTRACARDIAC INJECTION SITE

The single, discrete, pale area in the left ventricle of this cat, the severe dark discoloration of the endocardium and the tiny pale foci, especially seen in the endocardium of the left atrium of this case, are all evidence for a Intracardiac Injection Site of anesthetic material. This is an artefact. The high alcohol content of the material hemolyzed the blood to cause the dark color and subsequent imbibition. The tiny, white foci are crystals of the agent itself which have precipitated out of solution. This lesion is often considered to be an infarct but the history, lack of good, typical, inflammatory response, and the chemical odor all help differentiate this from a true lesion.

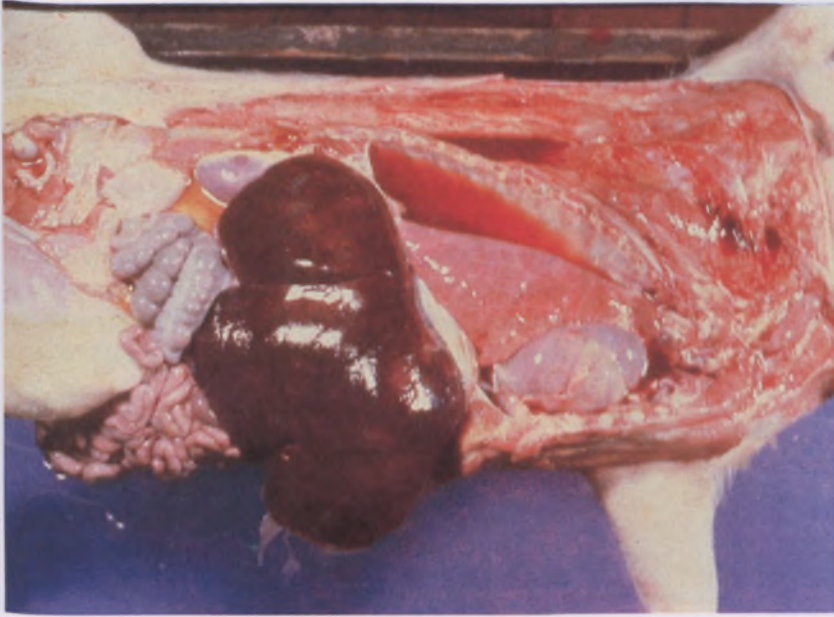


PLATE 457: CONGESTIVE CARDIOMYOPATHY AND NUTMEG LIVER IN THE PIG

The swollen, dark, mottled liver, the excess pleural and abdominal fluid and the enlarged heart, not easily seen in this view, all suggest a primary heart lesion. No specific heart lesion was found, however, except for markedly dilated left and right ventricles, and less marked dilation of the atria. Histologically, the heart showed only a few foci of myocardial lysis and fibrosis consistent with cardiomyopathy. This is one of several cases in pigs that appear to be the same disease as that seen in cats, dogs, skunks and cattles, called Congestive Cardiomyopathy, for which the cause is not known. The dark congested liver is a typical Chronic Passive Congestion (Nutmeg) Liver. Only sporadic cases occur like this in the pig, cat and other animals and no lesions suggestive of Nutritional Cardiomyopathy or Mulberry Heart Disease are found.

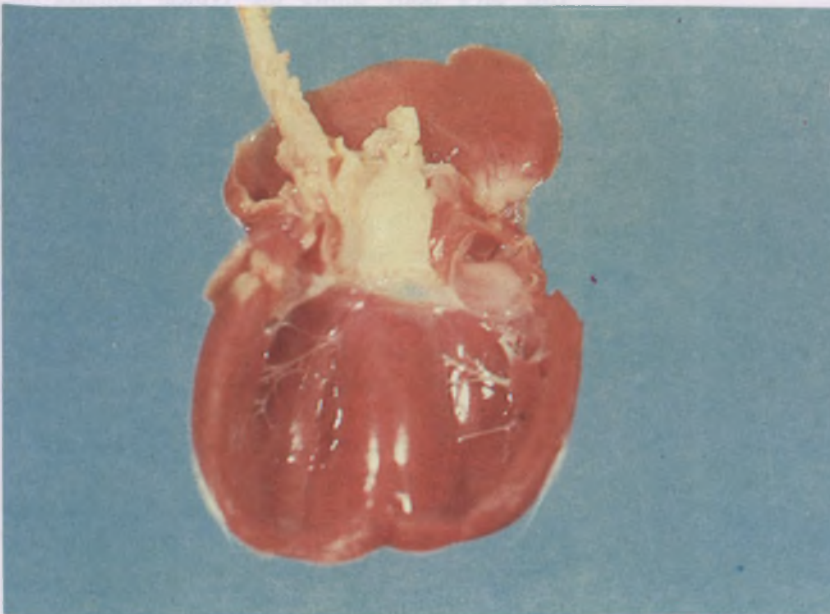
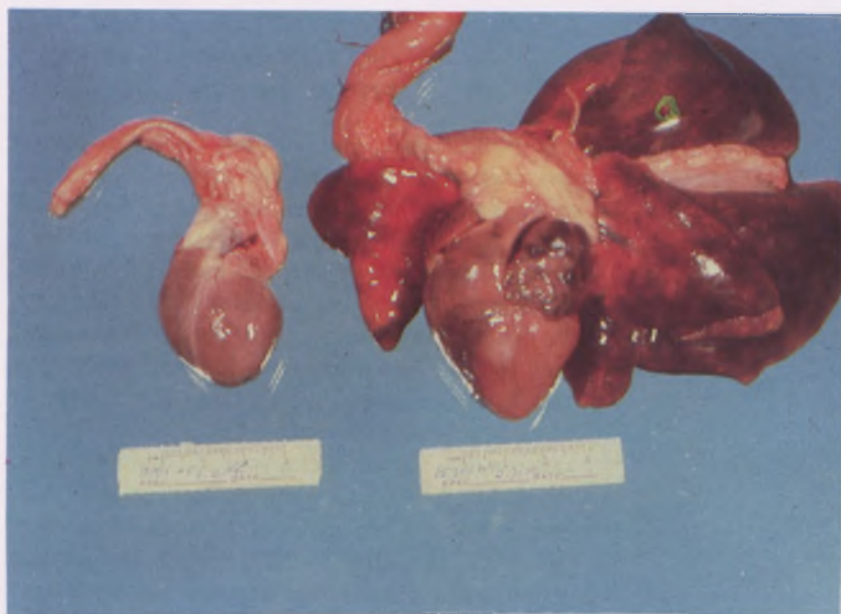


PLATE 458: NONPATENT SUBAORTIC SEPTAL DEFECT AND CONGESTIVE CARDIOMYOPATHY

This is a case of Congestive Cardiomyopathy in a cat with marked dilatation of the left ventricle and atrium. In addition but not related to this disease, is a definite thinness of the septal wall just under the aortic valve. It can be seen here as a roughly triangular bluish area of thinned septum. This is a relatively common lesion in most species of animals, and in effect is a Nonpatent Subaortic Septal Defect in which the muscle layer is missing, allowing the left and right ventricular endocardium to come together.



Dr. S. K. Liu, Animal Medical Center, NYC, USA

PLATE 459: HYPERTROPHIC CARDIOMYOPATHY

The heart by itself is essentially normal, and came from a 3.2 Kg cat. The large heart and lungs come from a 2.75 Kg cat. This enlarged heart with its prominent left auricle is an example of Cardiomyopathy. This and Congestive Cardiomyopathy are the two most common forms of this relatively newly recognized problem in animals. The cause of this disease is unknown. It usually affects young growing animals but can affect very young kittens and adults.

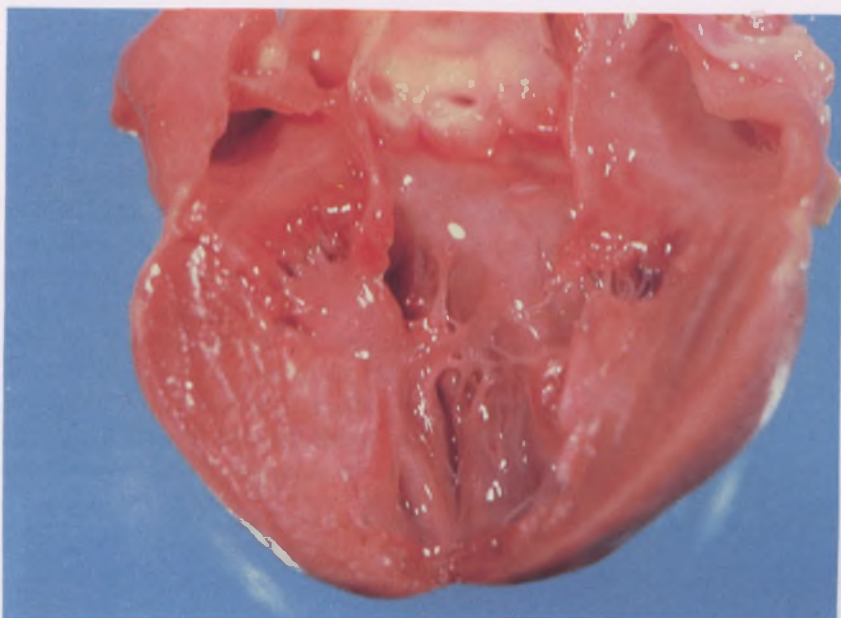


PLATE 460: HYPERTROPHIC CARDIOMYOPATHY

This cat's heart shows the typical findings for Hypertrophic Cardiomyopathy; the markedly thickened ventricular walls, and dilated atrium. The highlight in the middle of the pictures which is on the portion of septal wall that bulges out into the outflow tract of the left ventricle. In effect it is a "muscle bound" type lesion that prevents normal blood flow out of the heart. It is odd, however, that no focal endocardial fibroelastosis is seen at this point of constriction. This and the congestive form are the two most common types of cardiomyopathy in cats with a restrictive form being the third type. The actual cause is unknown. In about 50% of the cases, no lesions can be found histologically and only small areas of fibrosis or myocardial fiber lysis and atrophy in the remainder. Cardiomyopathy is quite common in dog, especially Doberman Pinschers and has been seen in cattle, horses, pigs and skunks and woodchucks among others at Cornell.

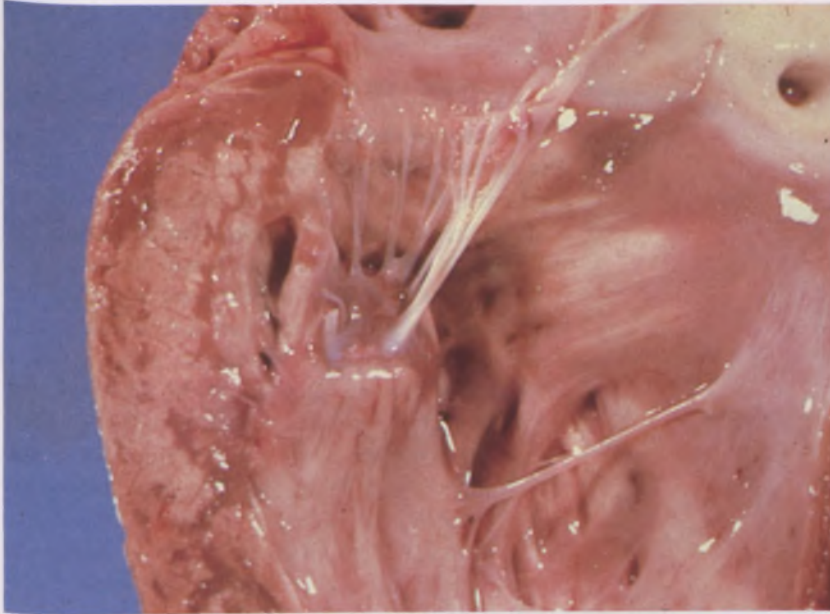
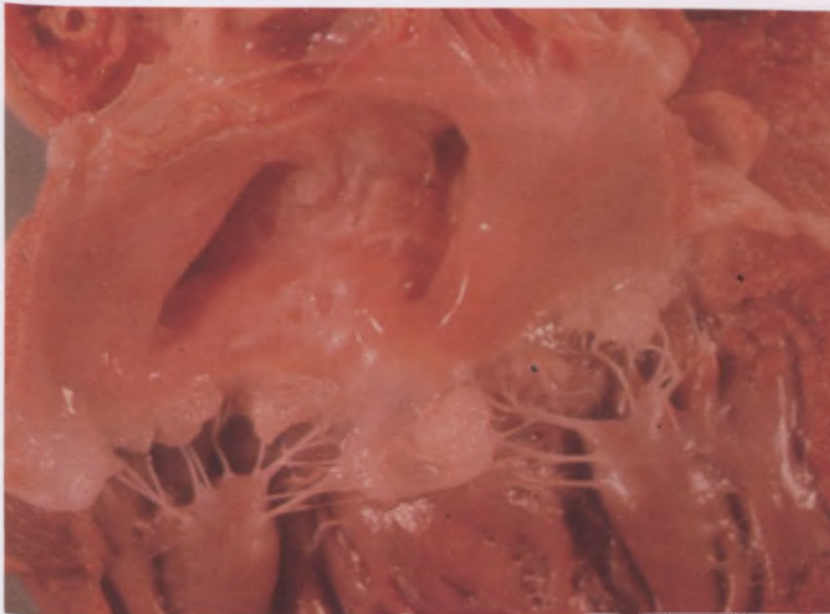


PLATE 461: NUTRITIONAL MUSCULAR DYSTROPHY (WHITE MUSCLE DISEASE)

The large, white, streaked patches of pale muscle in the septum, papillary muscle, and cut section of ventricular wall are areas of Myocardial Degeneration (Zenker's Degeneration) in this calf with White Muscle Disease (WMD). This is also called Nutritional Myopathy as most cases are a Vitamin E/Selenium Responsive Disease. While experimentally, the disease can be produced by a specific deficiency of these substances, most cases are probably due to a natural Antivitamin E factor that develops in spoiled or water damaged feed or hay. Other body muscles especially leg muscles in beef calves that have just been allowed out for the first time in the spring are commonly affected. Dairy calves on a poor milk replacer often have the lesion in the muscles of deglutition which in turn predisposes them to Inhalation Pneumonia.

PLATE 462: VERRUCOUS ENDOCARDIOSIS, PARACHUTE REACTION AND JET LESION



The free edge of this left atrioventricular (bicuspid) valve is thickened along most of its length in this old dog. This is called Verrucous Endocardiosis and it's a common aging change. In addition, several of the valves have a definite outpocketing called a "Parachute or Sail Reaction" which is caused by the ventricular pressure stretching the weakened valves towards the atrium when the valves close. Also, just above the anterior cusp of the bicuspid valve the endothelium of the atrium is irregularly thickened and pale. This is called a Jet Lesion, Splash or Regurgitation Reaction where the valves were incompetently closed and blood would reflux against this area of atrial wall during systole. Verrucous Endocardiosis, a degenerate change of valves in old animals, is to be differentiated from Vegetative Endocarditis. A bacterial inflammation on the valves most commonly seen in young animals.

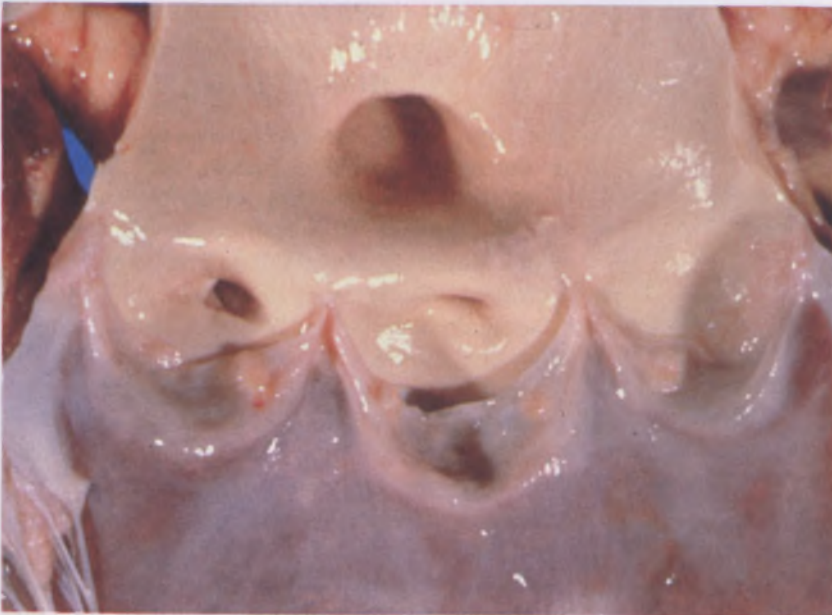

PLATE 463: FRICTION RUB GRANULATION TISSUE NODULES

Three cusps of the aortic valve of a horse are shown; just to each side of their attachment site to the aorta, and about 1-2 cm along the free edge of the cusps, there are paired granulomatous nodules. These are Friction Rub Granulation Tissue Nodules, and it is thought that they result from an abnormal rubbing against each other when the valve is closed. These are quite common but usually not as distinct as the ones shown. They are to be differentiated from the normal, centrally placed, Nodules of Aranti seen in the middle of the free edges of the cusps just barely visible in these cusps and from irregularly placed granulomas caused by *Strongylus vulgaris* larvae. A small focus of roughened endothelium is present in the aorta proper just above one attachment site for the valve. This is thought to be a Jet or Splash Reaction from the incompetent valve, or even a remnant parasite lesion.

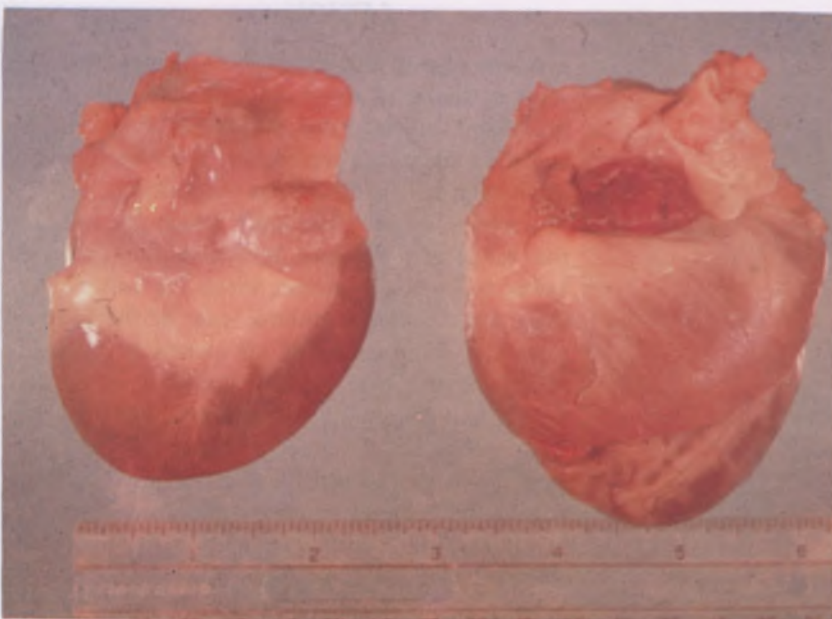

PLATE 464: AURICULAR FIBROSIS

The right auricle of both these dog hearts are thickened with connective tissue and one is more congested than the other. The cause for this Auricular Fibrosis is not known. It occurs commonly in mice.

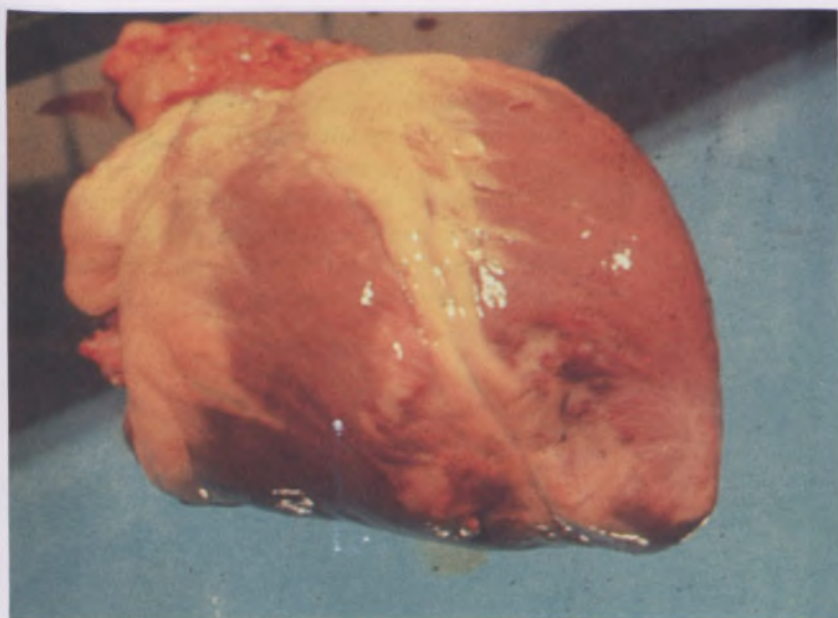
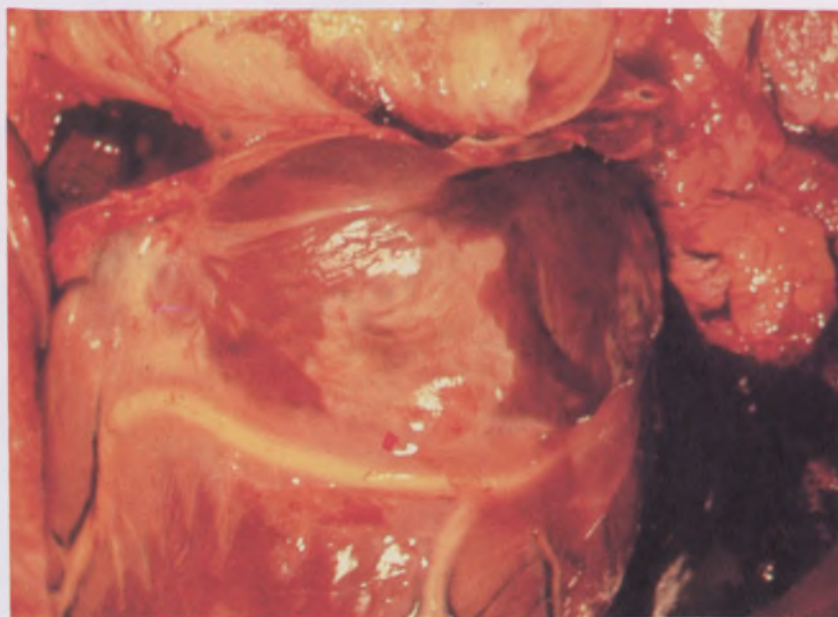

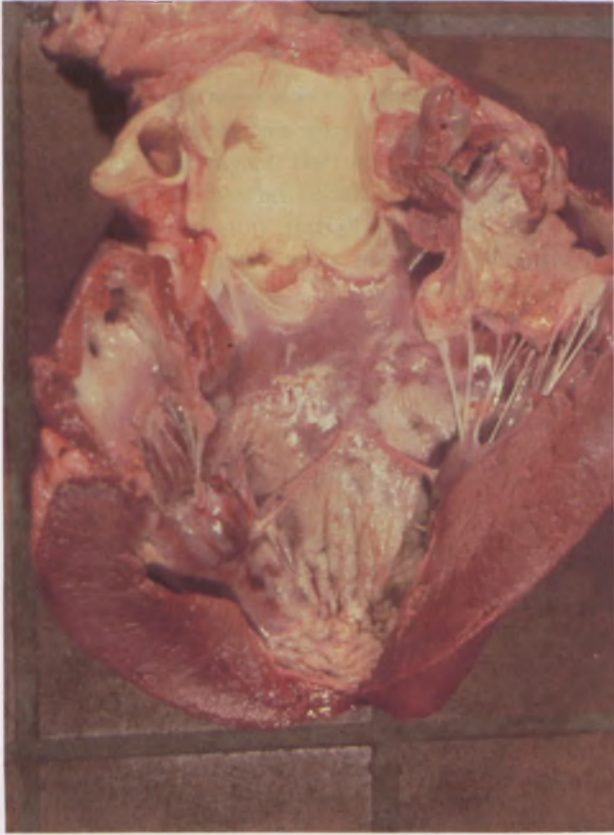
PLATE 465: HEALED MYOCARDIAL INFARCTION

Near the ventral tip of this horse's heart are several definite, irregular, pale and depressed areas on both sides of the left longitudinal (Coronary) groove. These are Healed Infarcts and are the result of Coronary Embolization from thrombosis in the region of the aortic valve, caused by the larvae of *Strongylus vulgaris*.

PLATE 466: HEALED AURICULAR INFARCTION

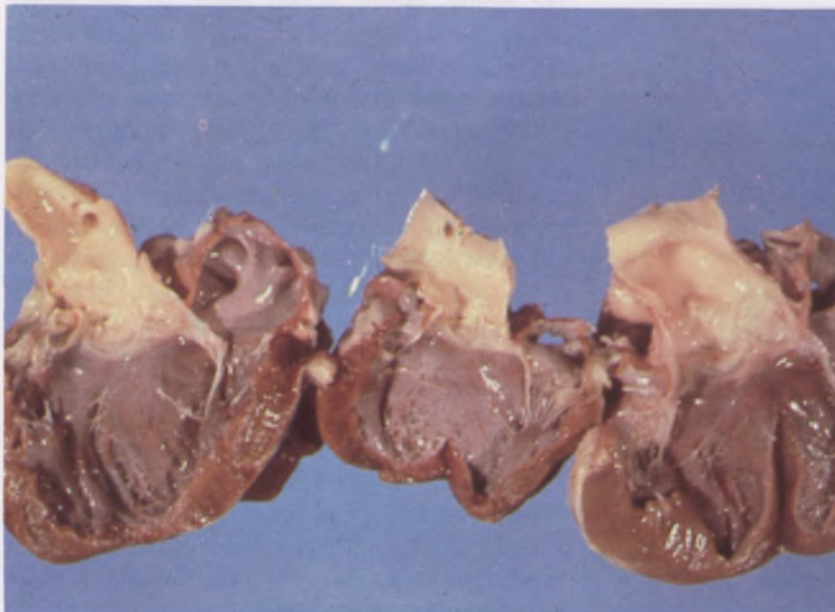


The almost square shaped lesion on the middle portion of the right auricle is a Healed Infarct in this horse's heart. It is a fairly common lesion. Initially it was thought that these were caused by an embolic shower from *Strongyle* lesions near the aortic valve, but far too many cases have been found without evidence of parasites near the heart. Even initially we could not explain why infarcts and these emboli would so commonly go to this region more than others in the heart. It is now known, although not proven causative, that of all places in the heart this area of the right auricle has the least number of Thebesian vessels to nourish it. It is then somewhat logical to suggest that the heart, whenever it might undergo a functional problem for whatever reason, may shut down these minor vessels more completely than others. This is only conjecture. This area has healed mostly with connective tissue, but often as not, fat may be the predominant replacement tissue.



**PLATE 467: TOXIC (VITAMIN D)
MINERALIZATION**

The pale white material deposited on the endocardium of both the left ventricle and left atrium is Mineralization, caused, in this case, by toxic levels of Vitamin D in a horse. Uremic Mineralization would look similar but it often starts in the atria first. Tumor induced Pseudohyperparathyroidism can also make a similar lesion



**PLATE 468: AORTIC BASE (ROOT)
MINERALIZATION**

In the wall of the base of the aorta in all three of these old dog hearts are irregular spicules of mineralization. This is a common aging change. It can often be here without mineralization elsewhere in the vascular tree.

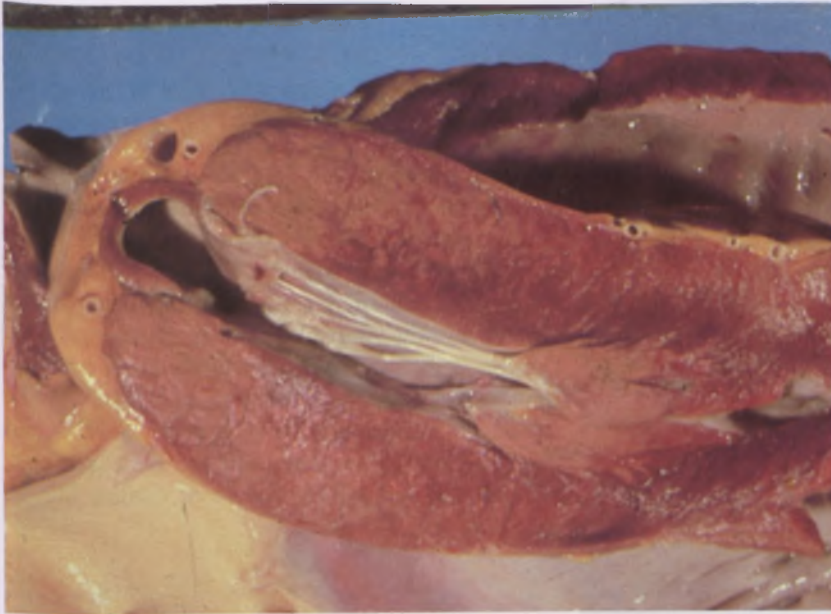


PLATE 469: EXERTIONAL MYOPATHY

The cut section of this myocardium shows discrete, pale areas of Myocardial Degeneration in this horse. This is an example of Exertional Myopathy. It is caused in some way by the affected animals having been severely exercised or worked, most of the body muscles are affected, not just the heart. It is seen commonly in captured wild animals and is called Capture Myopathy. A specific cause is unknown. Histologically, it is characteristic Zenker's Degeneration of Muscle. This horse had accidentally gotten tied up for over 24 hours in a long halter rope. This problem of Exertional Myopathy looks grossly and microscopically similar to several other diseases, and all of them usually have an acute episode of heavy work or extreme activity as a precipitating factor, but other underlying factors are involved. In White Muscle Disease or Nutritional Myopathy it is a Vitamin E or Selenium Responsive Disease. Azoturia or Monday Morning Disease is related to heavy grain feeding followed by acute activity without a warming up period. In Capture Myopathy and Exertional Myopathy no relationship to diet is known.

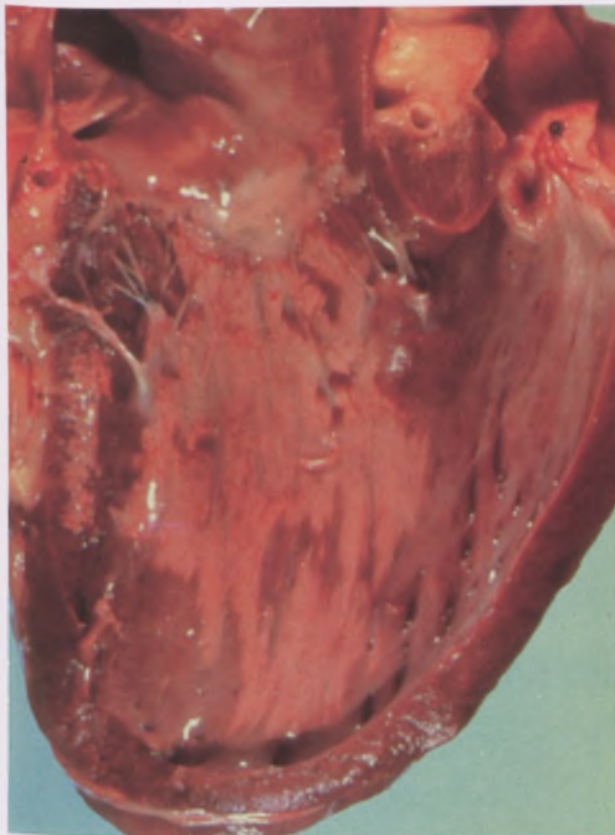

PLATE 470: ACUTE TOXIC (CANTHARIDIN) MYOCARDIAL DEGENERATION AND NECROSIS

The massive pale streaking of the septal myocardium, and the cut section of right ventricular wall, are areas of Acute Myocardial Degeneration and Necrosis associated with Cantharidin Poisoning in a horse. The source of the Cantharidin was from Blister Beetles, *Epicauta* spp., that were crushed when the hay was cut and crimped to hasten drying. The beetle infested hay was fed to the horses. The usual lesion found with this poisoning is necrosis of the various mucosal surfaces and a toxic nephrosis. One wonders about this being a specific lesion as it may be a case of Exertional Myopathy in this case.

Dr. R. Panciera, Oklahoma, USA

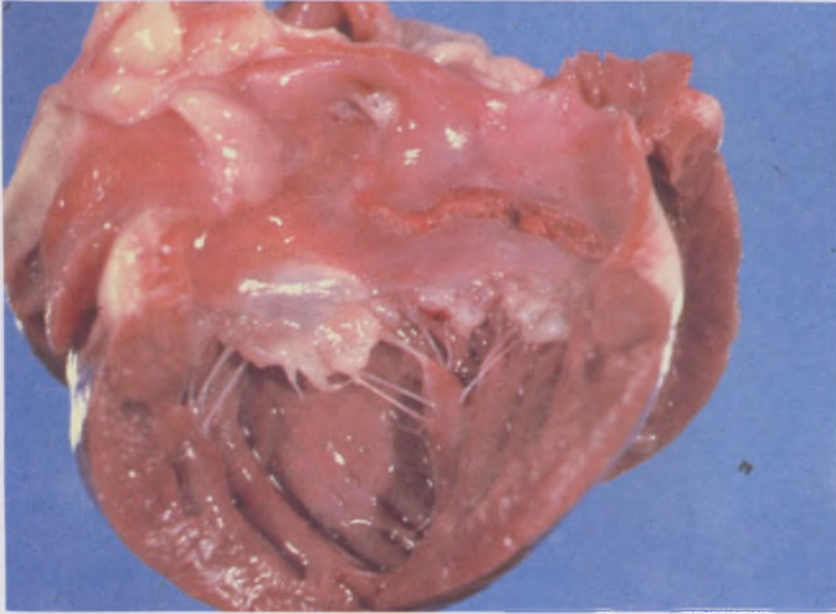


PLATE 471: VERRUCOUS ENDOCARDIOSIS, CHORDAE TENDINAE RUPTURE AND ATRIAL RUPTURE

The free edges of this left atrio-ventricular valve in a dog are thickened as a result of a chronic aging change. This thickening is called Verrucous Endocardiosis (Chronic Valvular Fibrosis). One and possibly several of the chordae tendinae to the valve over the aortic vestibule have ruptured. There is a long crooked tear in the atrial endocardium halfway up the atrial wall as a result of the valvular insufficiency. Usually such tears would result in fatal hemorrhage into the pericardial sac, but this dog was killed because of cardiac failure.

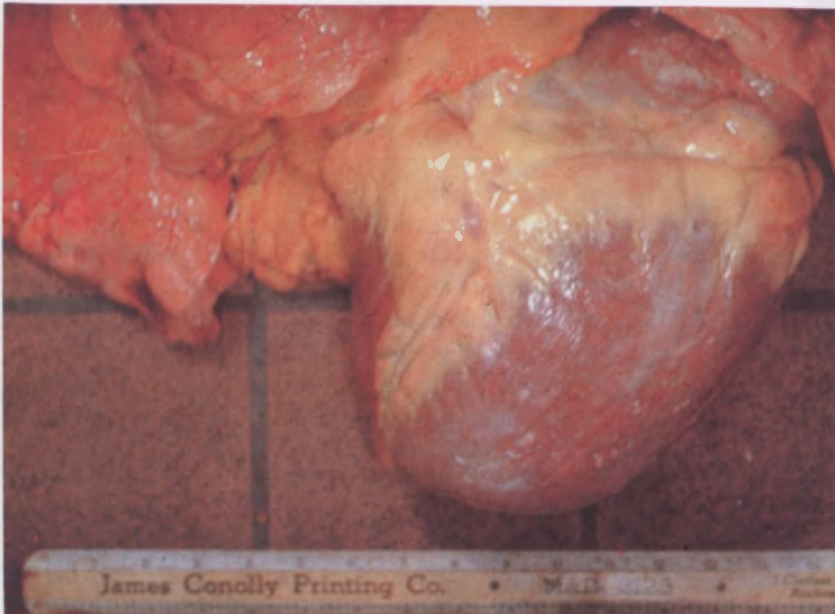

PLATE 472: AORTIC VALVE RUPTURE

The apex of this horse's heart is distinctly rounded. Of all animals, the horse normally has the most pointed apex of the heart. The rounded apex should make anyone instantly aware that a heart problem exists. This 23 year old horse had an idiopathic rupture of the aortic valves.

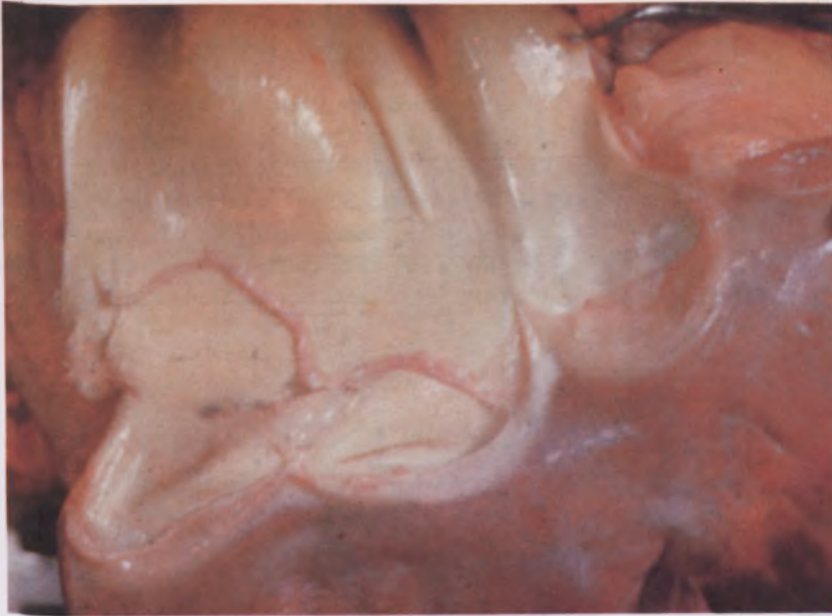
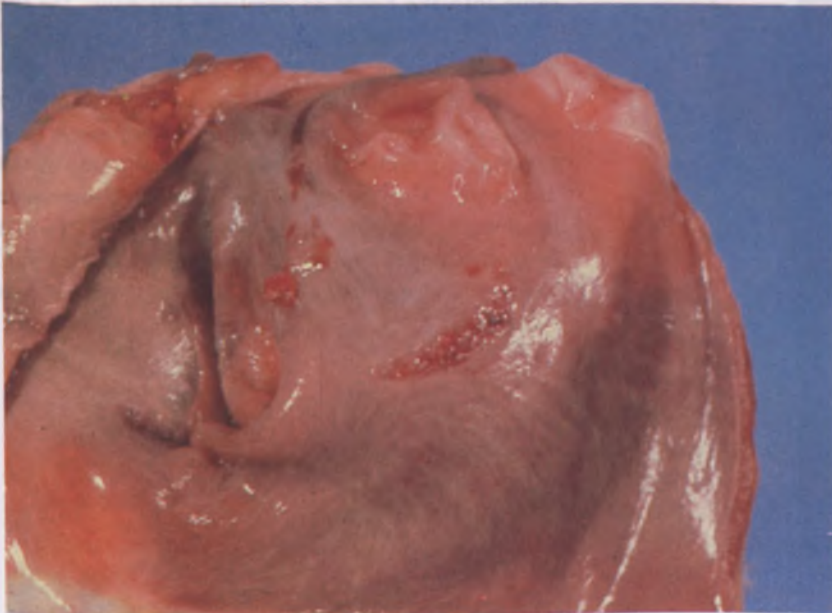
PLATE 473: AORTIC VALVE RUPTURE

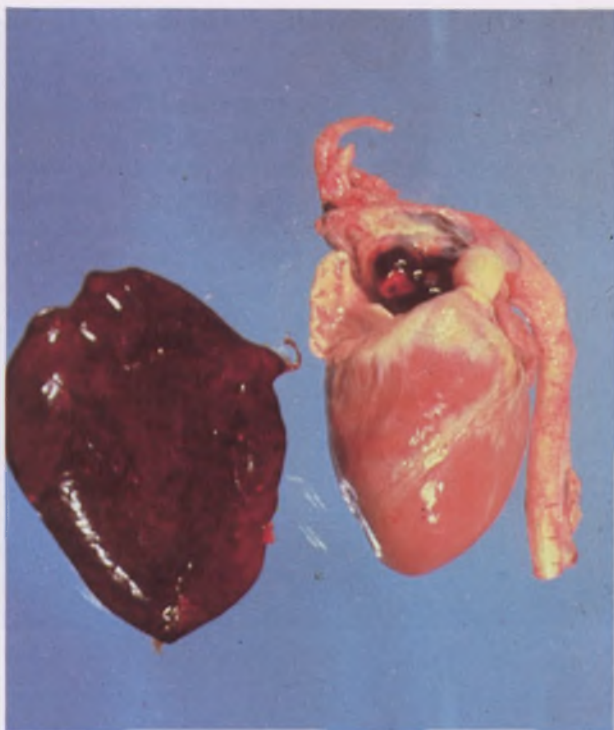The relative free edge of the two cusps, of this horse's aortic valve, have torn away and are slightly rounded as a result. The cause of this Rupture of the Aortic Valve is unknown although variations of this type lesion are quite common in the horse. Copper deficiency or a Vitamin C problem is suspected in some but it has not been proven.

PLATE 474: AORTIC RUPTURE AND
CARDIAC TAMPONADE
This aged dog was known by its owner, a most
competent pathologist, to have eaten its supper,
been allowed outside for a few minutes and then



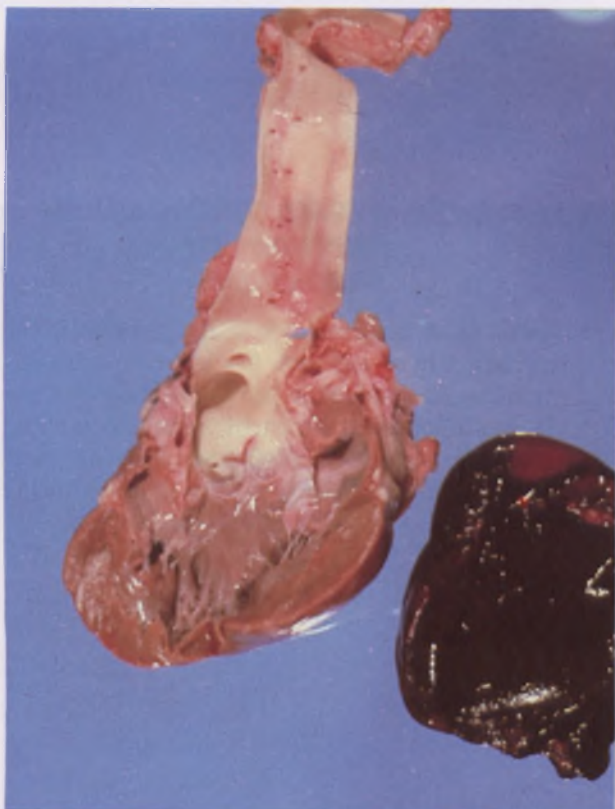
**PLATE 474: ATRIAL ENDOCARDIAL
RUPTURE AND
THROMBOSIS**

Several small tears are seen in the endothelium of this left atrium and one has a small, red, early thrombus attached. Most Atrial Ruptures like this are due to increased intraatrial pressure in the dog, caused by valvular insufficiency, usually from Verrucous Endocardiosis. This is an aging change in the free edge of the atrio-ventricular valves.



***PLATE 475: RUPTURED AORTA AND
CARDIAC TAMPONADE***

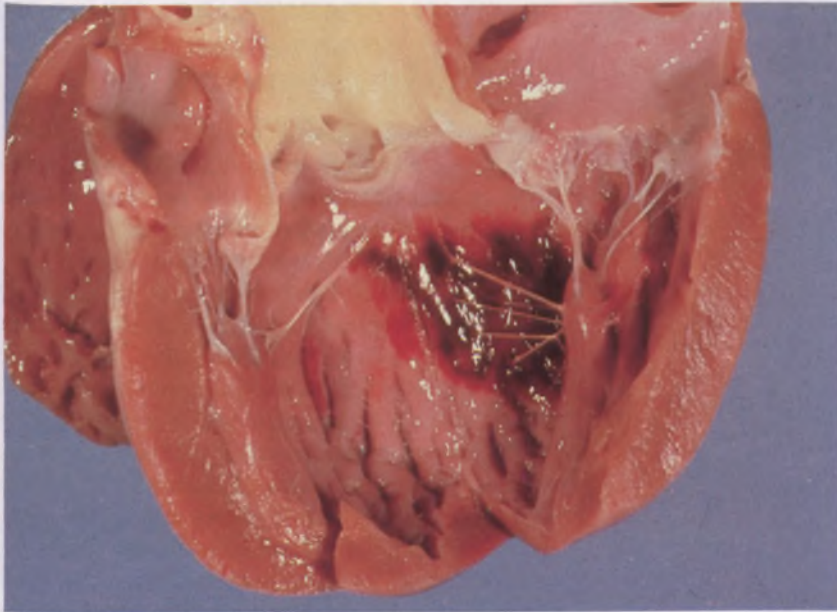
These specimens are from a young pig; a large mass of clotted blood found in the heart sac, Cardiac Tamponade, and a tear in the base of the aorta, Ruptured Aorta. Six of eight pigs died with this problem. They were housed in a cow barn and fed only discarded milk from the cows. This is considered to be a case of Copper Deficiency.



***PLATE 476: AORTIC RUPTURE AND
CARDIAC TAMPONADE***

This aged dog was known by its owner, a most competent pathologist, to have eaten its supper, been allowed outside for a few minutes and then came into the house as usual and lay down for the evening. The owner walked near the dog several times during the evening and noticed it dead without any sign about three hours later. A triangular tear is noted in the aorta near one of the aortic cusp attachments and the blood clot present was in the heart sac. The cause of the Cardiac Tamponade is obvious, but the cause of the Aortic Rupture is not. Copper deficiency and even Vitamin C deficiency were considered briefly. Trauma was ruled out.

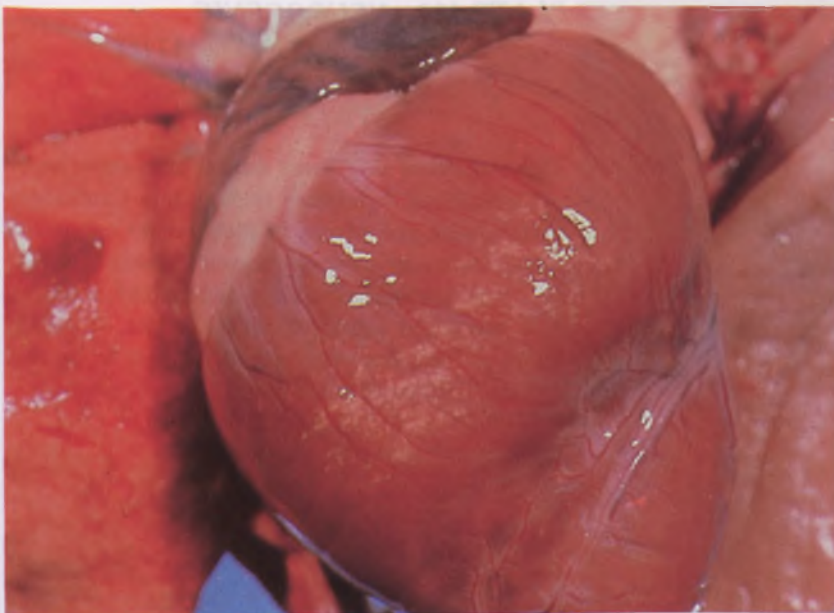
Dr. C. G. Rickard, Cornell, USA



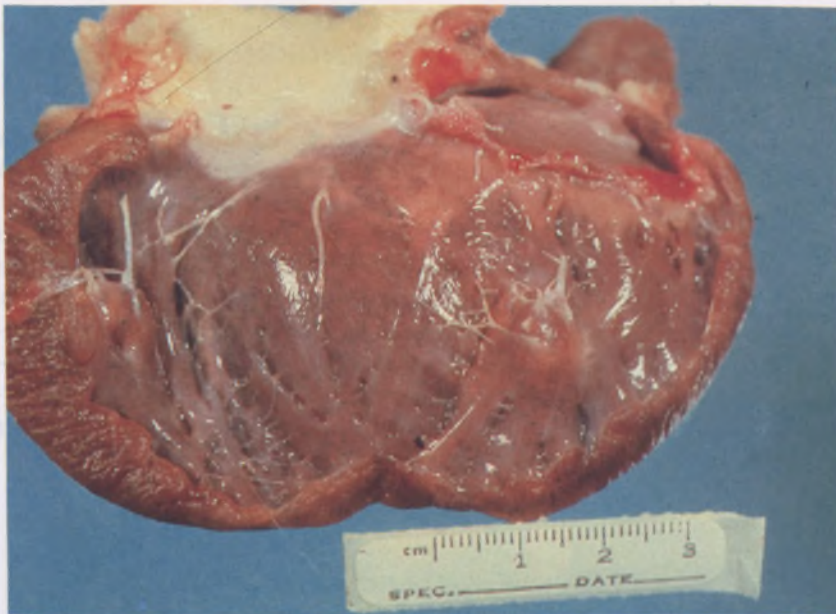**PLATE 477: TRAUMATIC
HEMORRHAGES OF
THE HEART**

The endocardial hemorrhage seen in this dog's heart is the direct result of manual trauma from cardiac massage. Out of context, epicardial, endocardial and even myocardial hemorrhages are so common as to be nonsignificant in most cases, even though they are quite extensive. The hemorrhage in this case is also to be distinguished from the Brain/Heart Syndrome (Neurogenic Cardiomyopathy) which often results following injury, usually trauma, to the brain, cord or major nerves.

**PLATE 478: NEUROGENIC CARDIO-
MYOPATHY (BRAIN/
HEART SYNDROME)**



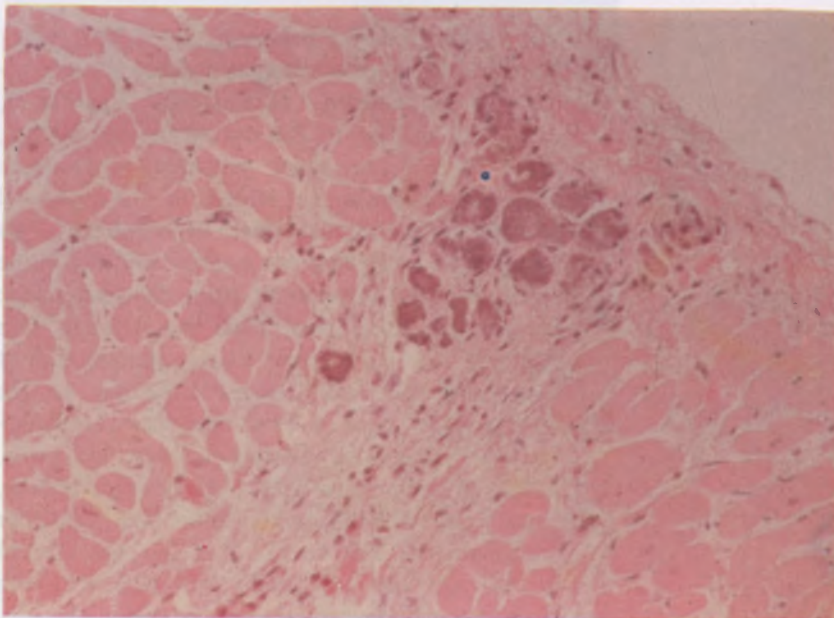
The distinct focus of pale spots in this dog's heart is myocardial degeneration, as a result of Neurogenic Cardiomyopathy (Brain/Heart Syndrome), caused by damage to the central nervous system, brain or cord, or major peripheral nerves with probable catecholamine release in the heart and subsequent myocardial fiber degeneration. This case is from a dog that was accidentally shot in the pelvis resulting in paralysis from damaged sciatic nerves. The distal cord itself was normal. This relatively newly discovered disease process is most commonly seen with traumatic damage to the brain or spinal cord, however many cases are associated with listeriosis in cattle, sheep and goats, distemper and prolapsed intervertebral discs in dogs, parasites in the brain, tumors in the brain and other nontraumatic C.N.S. damage. It is seen most marked in the right ventricle usually, but both ventricles are commonly affected.



Dr. W. Haschek, Tennessee, USA

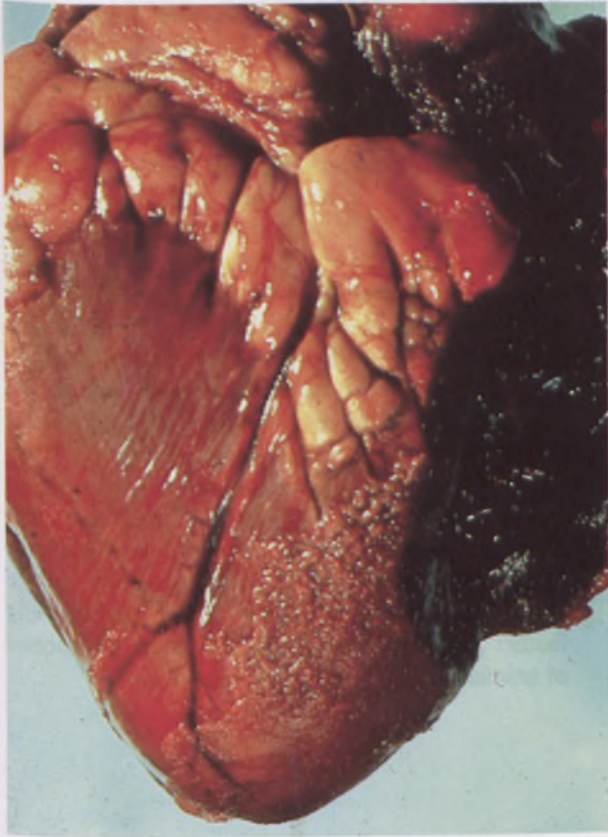**PLATE 479: BRAIN/HEART SYNDROME
(NEUROGENIC
CARDIOMYOPATHY)**

The pale cardiac muscle patches, just under the aortic cusps and more so under the atrio-ventricular valve attachments, and, in the papillary muscles are areas of degeneration with typical features of Zenker's degeneration as a result of a probable catecholamine release. This release was triggered by damage to the spinal cord from a broken back in this dog. This degeneration is called Neurogenic Cardiomyopathy or Brain/Heart Syndrome. It is usually seen 5-10 days after severe damage to the brain, spinal cord or major peripheral nerves. Trauma such as this case of sustaining a broken back from a car accident, getting shot in the neck, back or pelvis, or ruptured intervertebral discs can cause this in addition to nontraumatic causes such as Distemper in dogs, brain tumors in several species and even Listeriosis in cattle, sheep and goats. For one period of several months at Cornell we had about one case a week come to necropsy.



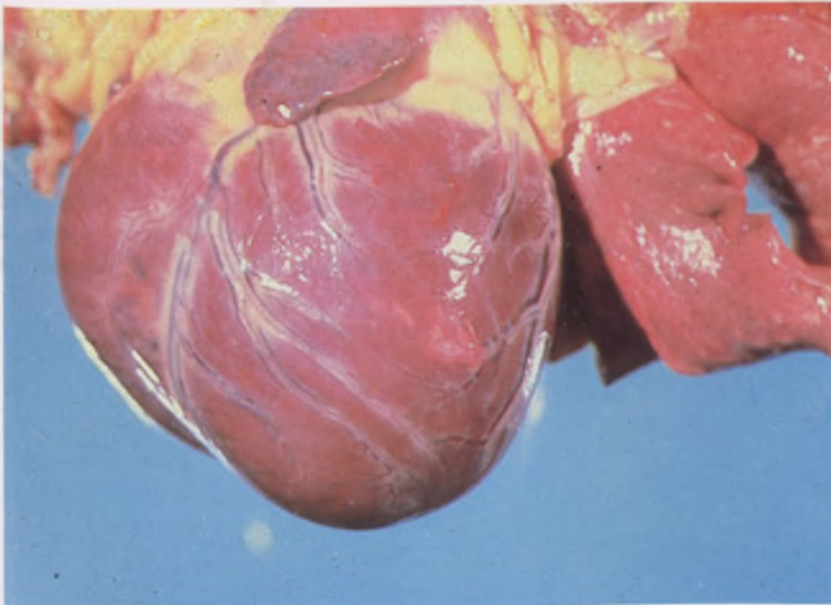
**PLATE 480: NEUROGENIC
CARDIOMYOPATHY
(BRAIN/HEART
SYNDROME)**

This section of dog heart shows the chronic lesion of Brain/Heart Syndrome (Neurogenic Cardiomyopathy), with the streaks of replacement connective tissue between areas of normal muscle bundles. The dark granular fibers are mineralized, a process that can occur rapidly in this problem. It usually takes at least five days for the lesion to be seen grossly. This one is much older.



**PLATE 481: ACUTE BACTERIAL
(*CLOSTRIDIUM CHAUVOEI*)
MYOCARDITIS**

The layer of fine granular fibrinous material on the congested surface of this heart is evidence for a Bacterial Myocarditis caused by *Clostridium chauvoei*, the causative agent for Blackleg, in this cow. Blackleg, usually affects the major muscle masses like those of the limbs, but can affect individual muscles as the heart and diaphragm. A relatively new form affects the muscles around the vagina in cows that have recently calved. The extremely dark, shiny tissue to one side is the endothelial surface of the right side of the heart, with marked blood hemolysis and imbibition as a direct result of the bacterial infection.



**PLATE 482: MULTIFOCAL EMBOLIC
MYOCARDITIS**

The several small pale foci scattered, in both the right and left ventricle walls, and having a slight linear appearance are areas of Myocardial Degeneration and Suppuration associated with Septic Embolization from Vegetative Endocarditis. The vegetative lesion is usually near the aortic valve, as that is the location of the ostia for the coronary vessels, and it is only during diastole that the coronary vessels receive blood. During the turbulent flow period from systole to diastole, pieces of thrombotic debris may break off, go down the coronary vessels, and cause this lesion. Thrombotic material from other areas would probably travel rapidly past this area.

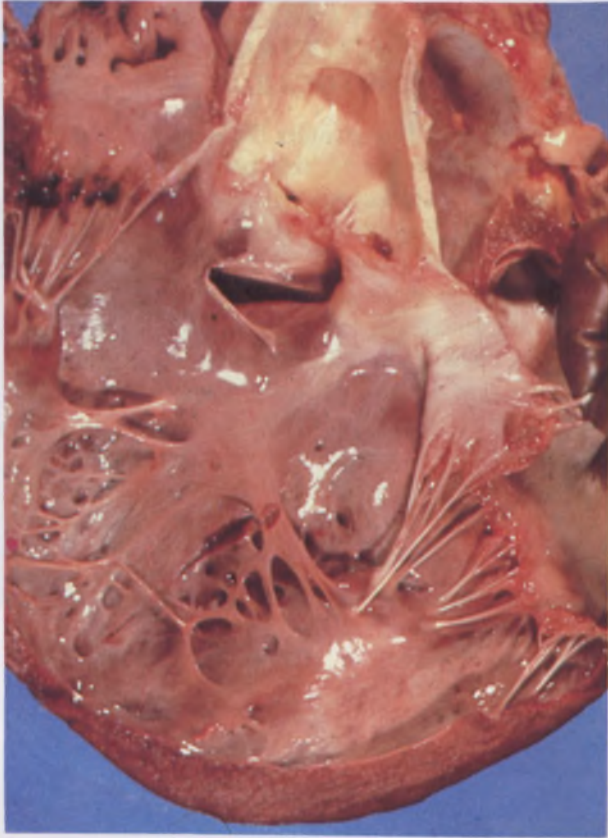

PLATE 483: SUBAORTIC SEPTAL DEFECT WITH SECONDARY VEGETATIVE (BACTERIAL) ENDOCARDITIS

This cow's heart is markedly dilated, and just under the aortic valve is a roughly triangular, fibrous tissue ringed hole through the septum to the right side. This is a Subaortic Septal Defect, one of the most common heart anomalies in animals. In addition and not so easily seen, and so often missed, are small red yellow masses of Vegetative Endocarditis, on two of the three aortic cusps and on the reflected free edge of the left atrio-ventricular valve. These are bacterially infected foci on these cusps, as a result of trauma to the valve from turbulent blood flow associated with the anomaly. Chronic Septic Arthritis, Heart Anomalies and Chronic Infections anywhere in the body in the above order, are commonly found predisposing factors to Vegetative Endocarditis in all species of animals.

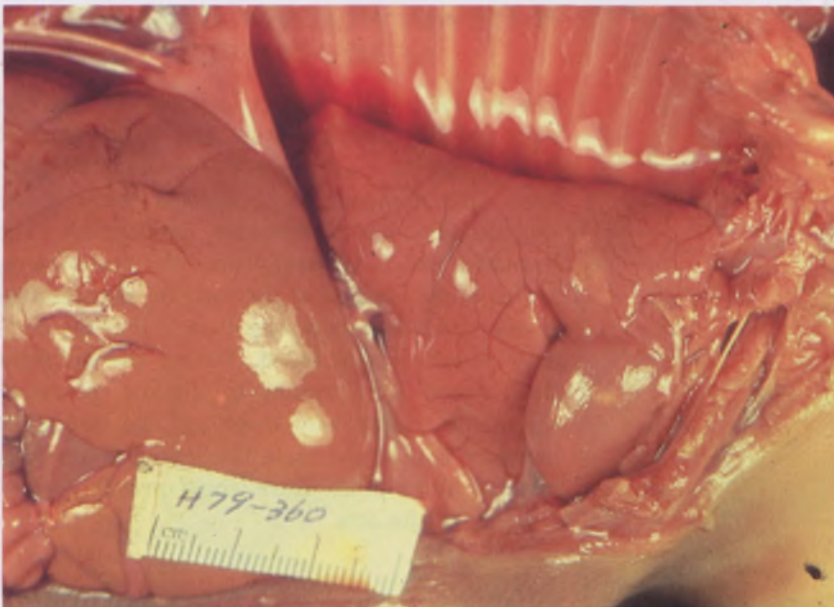


PLATE 484: PROTOZOAL (*TOXOPLASMA GONDII*) MYOCARDITIS

The small pieces of yellow fibrin on the lungs, and the yellowish foci in the heart of this aborted piglet are evidence for Toxoplasmosis, which caused the abortion. *Toxoplasma gondii* were demonstrated in the areas of acute necrosis. In some piglets, a well marked multifocal hepatitis and pneumonia may be seen.

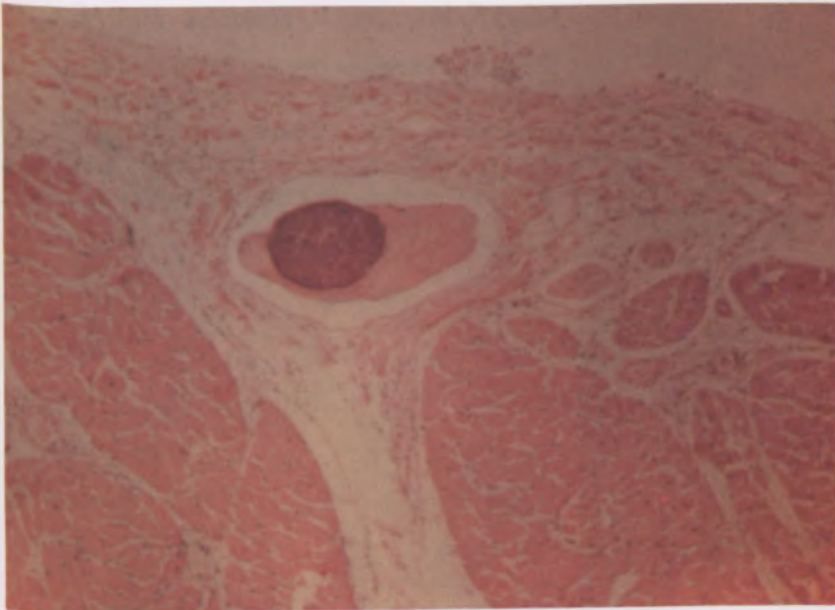


PLATE 485: SARCOSPORIDIOSIS

The discrete dark body in the Purkinje fiber of this cow's heart is a protozoal parasite, *Sarcocystis* spp. It is a very common parasite in the muscles of many animals. When it is in this location, it is not known to affect the function of the heart. A relatively new aspect of this parasite is its ability to cause cattle abortions, where the parasite is found in the placental tissues and in the endothelial cells of the fetuses.

Dr. P. Frelief, Cornell, USA

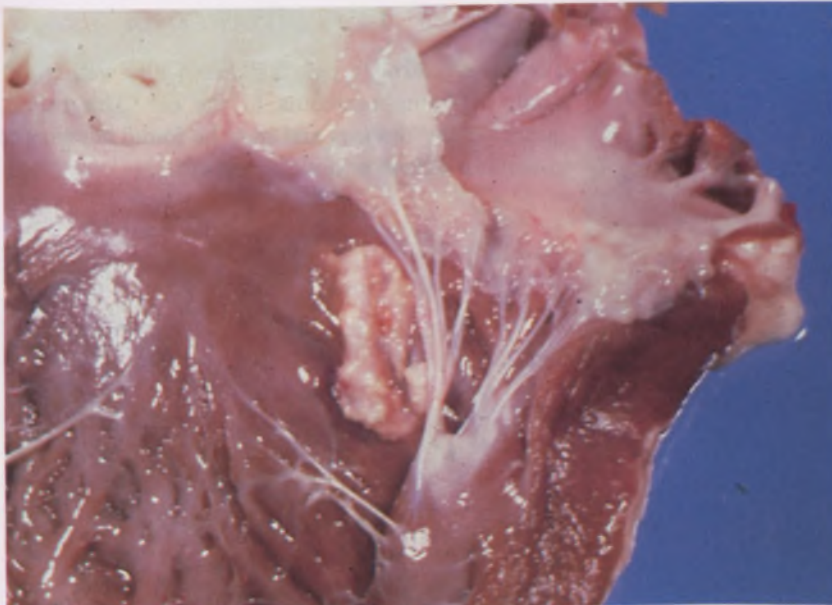
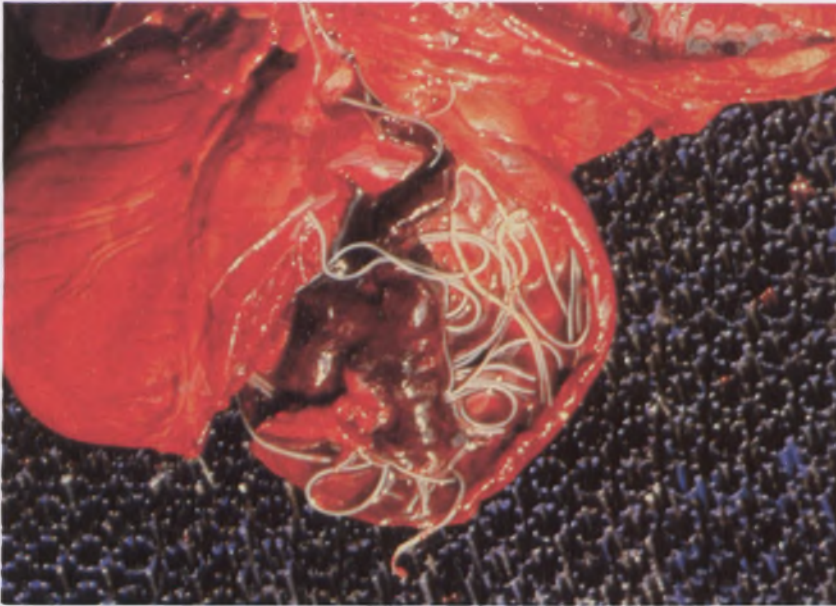


PLATE 486: HEALED ENDOCARDIAL PARASITIC ABSCESS (PRESUMPTIVE)

Just under the chordae tendinae and grooved by them is a chronic abscess in the wall of this left ventricle of a sheep's heart. It is probably an aberrant nodular worm, *Esophagostomum columbianum*, induced abscess. It could also be considered a healed focus of Vegetative Endocarditis but its site, shape and healed nature makes this unlikely.



Dr. C. I. Liu, Taiwan, ROC

PLATE 487: DIROFILARIA IMMITIS

The white worms in this dog's heart are *Dirofilaria immitis*. Heart Worms often cause clinical disease when the live or dead worms get into the pulmonary vascular bed, and interfere with blood flow. It is a parasite of dogs, cats, sea lion and other species.

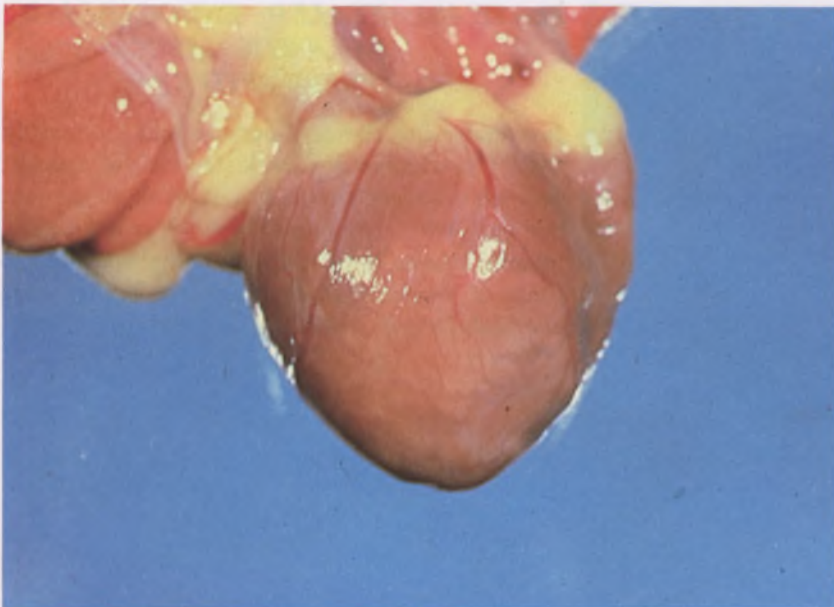

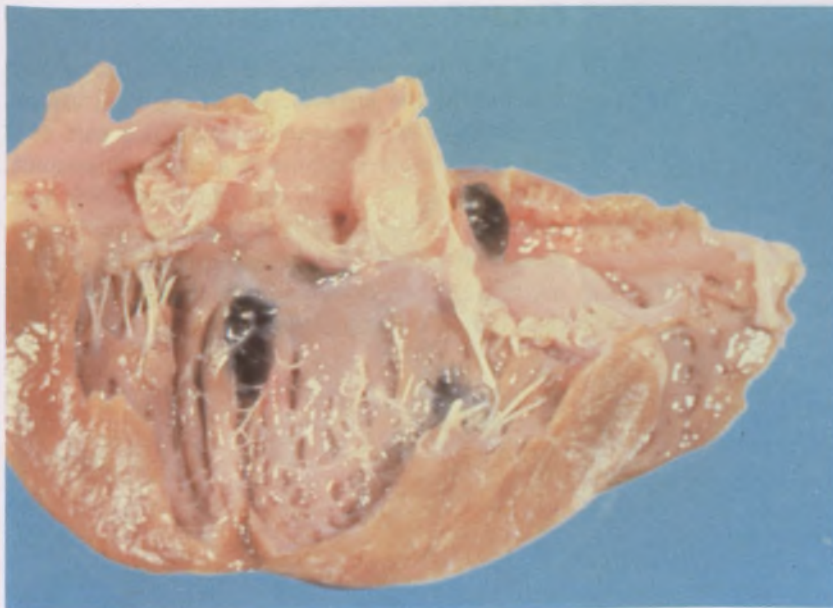
PLATE 488: LYMPHOSARCOMA

The slightly swollen pale left ventricular wall is the result of Lymphosarcoma in the cat. This tumor mimics many diseases and may be found anywhere, either as a diffuse or nodular growth.

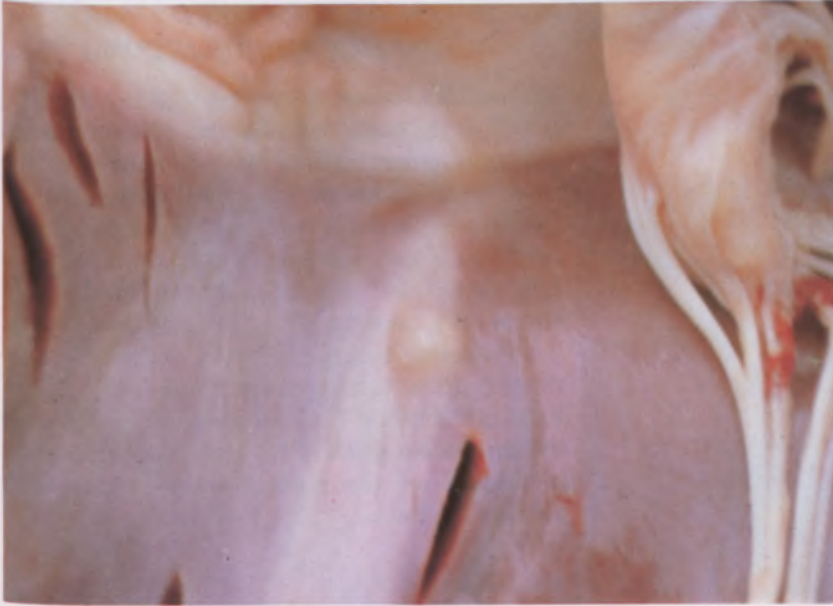

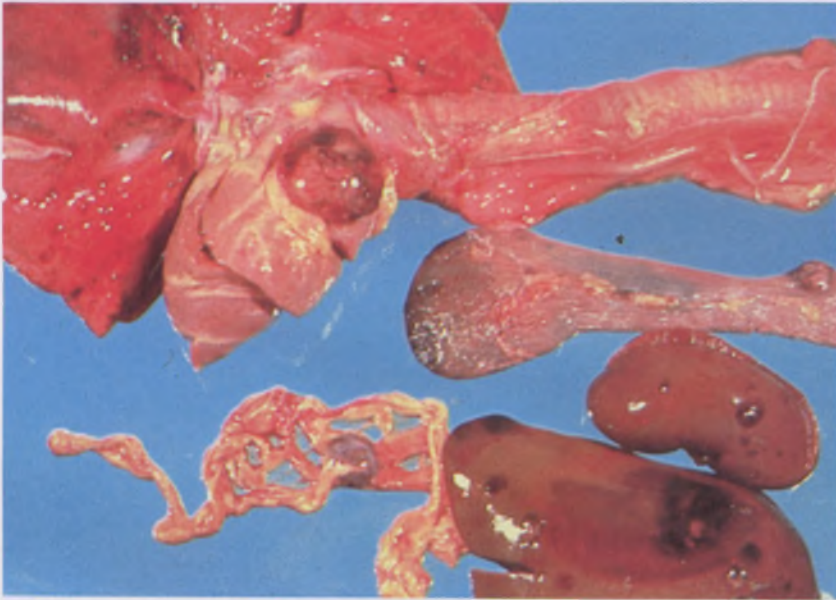
PLATE 489: NEUROFIBROMA

The solitary, white, firm nodule in the endocardium of this bull's heart is a Neurofibroma. This is a common organ to be affected. These are often seen directly in the line of a nerve.



**PLATE 490: METASTATIC
MELANOSARCOMAS**

The dark black masses scattered in the left atrium and ventricle of this dog's heart are Melanosarcomas which metastasized from the oral cavity. Melanosarcomas in the mouth usually warrant only a poor prognosis clinically.



Dr. C. I. Liu, Taiwan, ROC

**PLATE 491: GENERALIZED
HEMANGIOSARCOMA**

The multiple masses in the liver, kidney and lung as well as the single masses in the spleen, omentum and right atrium are all Hemangiosarcomas. The large, ventral edge of the spleen is firm due to Infarction. Of note, is that many Hemangiosarcomas and Lymphosarcomas even though they are generalized, often have a significant mass in the right atrium. The cause for this right atrial involvement is not known, but some consider the possible relationship to a hematopoietic center being in the heart in embryonic life. The spread of the tumor in the case shown above is not easily understood, nor is the site of the primary tumor when one is involved.

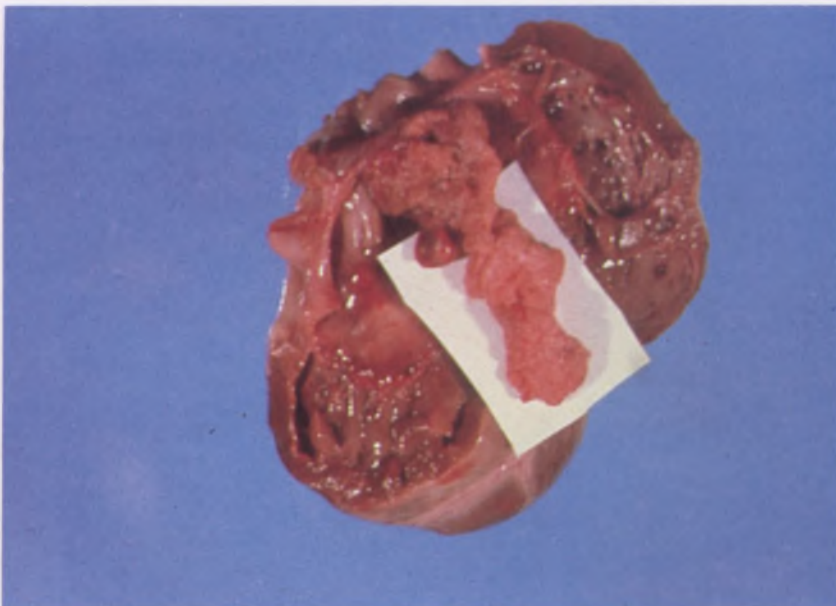
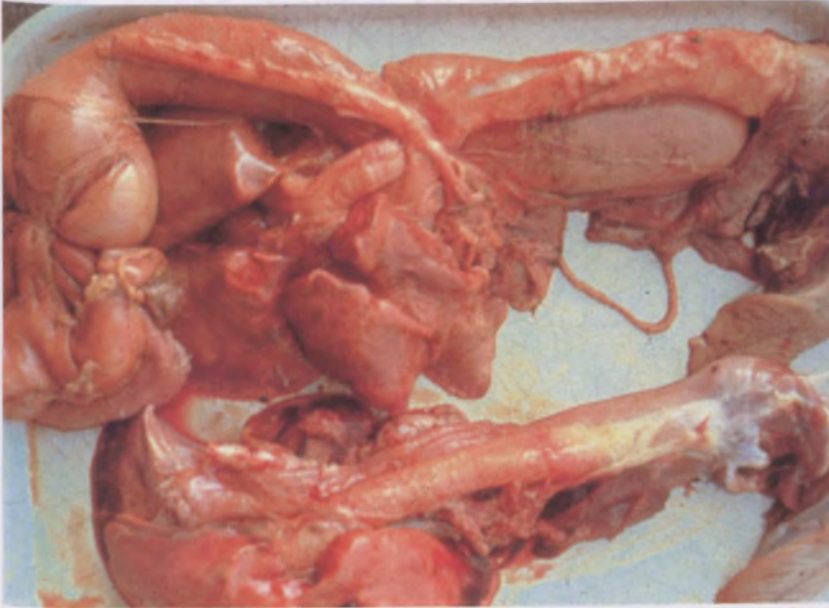


PLATE 492: HEMANGIOSARCOMA

The long finger like projection of soft tissue is attached to the endocardium of the right atrium. The more solid bloody round mass is a part of it also. This whole structure is a Hemangiosarcoma, arising here in the wall of the right atrium. For some unknown reason there is a tendency for Hemangiosarcomas and Lymphosarcomas to be present either primarily or secondarily in the wall of the right atrium in many animals.



Dr. R. Wells, Michigan, USA

PLATE 493: PERSISTENT RIGHT AORTIC ARCH WITH MEGAESOPHAGUS

The two sets of pluck shown here are from dogs. The bottom one is essentially normal and shows the aorta and esophagus on the left side of the trachea and no major vessel on the right side of the trachea above the heart. The other pluck shows a markedly dilated esophagus above and below the vessel that runs over the esophagus and trachea on the right side to the heart. This is the Right Aortic Arch which normally disappears in embryonic life allowing the left aortic arch to remain on the left side of the trachea. The ductus arteriosus being attached to the pulmonary artery and now to the right aortic arch instead of the left, forms the constricting ring about the esophagus and trachea. Usually it is the cranial portion only of the esophagus that dilates from the constriction just above the heart but in this case it is dilated cranially and caudally.

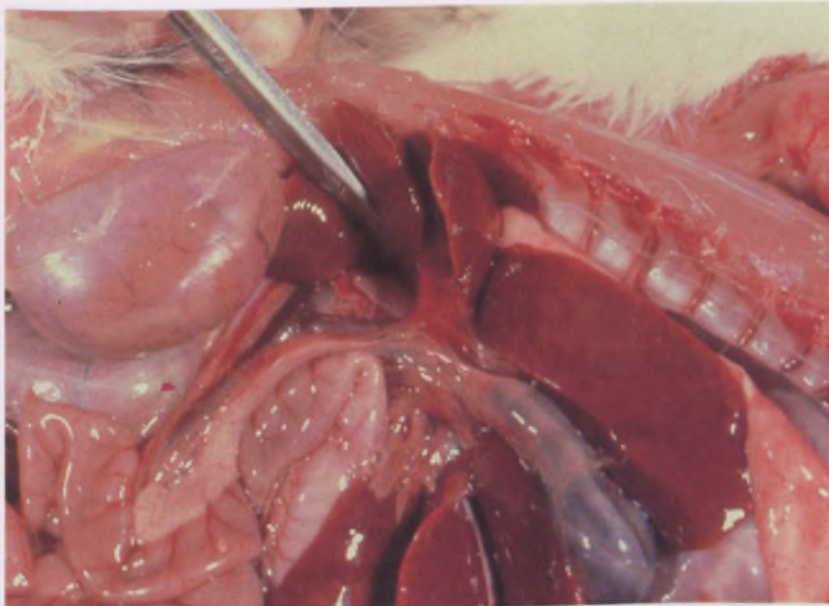


PLATE 494: PORTOAZYGOUS SHUNT

The steel instrument pointing out that the portal vein in this cat is partially bypassing the liver, to finally enter the vena azygos. This is one example of the portal shunt anomalies, the most common being variations of portocaval shunts. In some, but not all, the liver may be smaller than normal as a result of Disuse Atrophy. Many are brought to a clinician's attention because of nervous signs often related to eating. Histologically such cases may show multiple clear spaces in the white matter of the brain, Polymicrocavitation.

Dr. A. de Lahunta, Cornell, USA

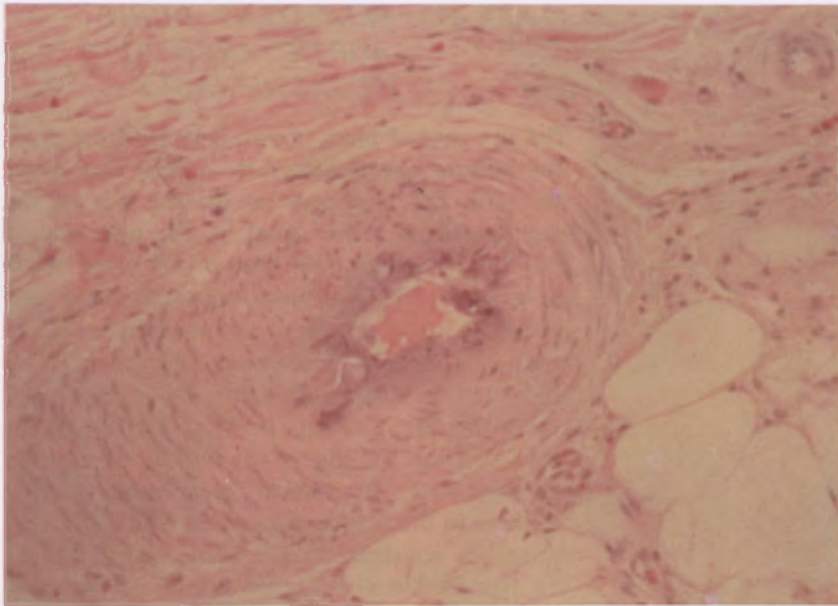


PLATE 495: INTIMAL BODIES

The tiny purple staining bodies in the intima of an intestinal vessel from a horse are called just that, Intimal Bodies. These are normal in the horse and most easily found in the intestinal vessels.

of the capillaries that cluster from the contraction
just above the heart but in this case it is dilated
ventrally and caudally.

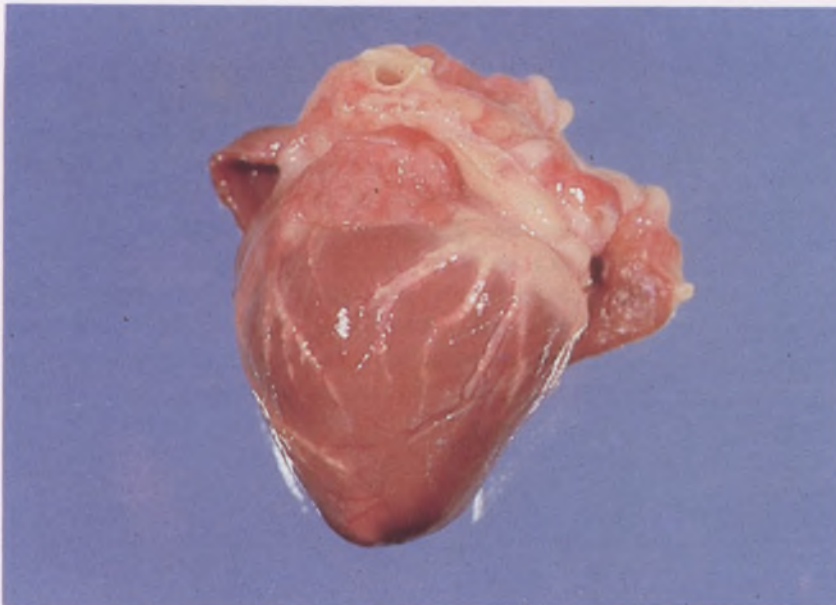


PLATE 496: ATHEROSCLEROSIS

The various branches of the coronary artery of this dog's heart can be seen to be raised above the surface, and are opaque white in many scattered foci. This is due to Atherosclerosis, a deposition of fat, cholesterol and other lipids in the vessel wall usually just under the endothelium. This is most common in diabetic dogs in our opinion, but there are some who consider hypothyroid dogs to be more often affected.

Dr. A. de Lahunta, Cornell, USA

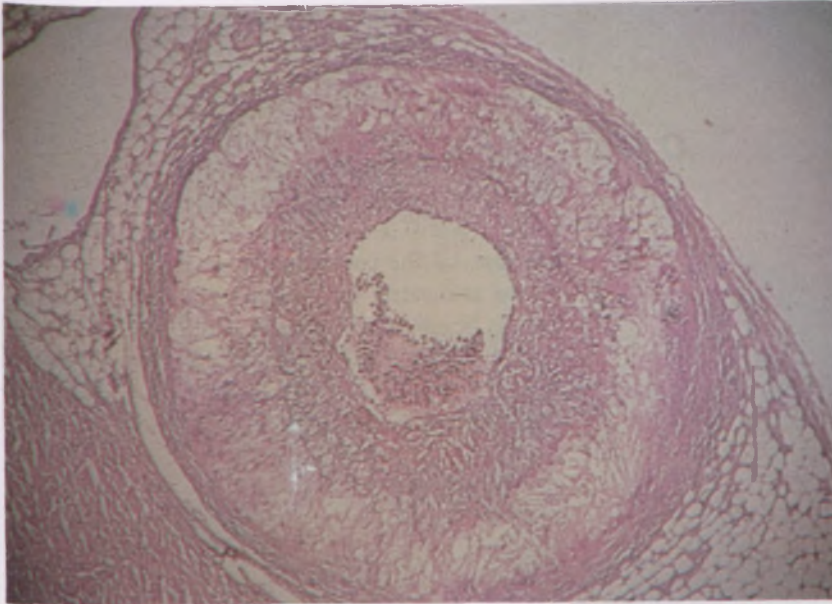


PLATE 497: ATHEROSCLEROSIS

The coronary vessel of this dog is enlarged with a marked infiltration of its wall with lipid and cholesterol which have in part been washed out by the histological technique used to make the slide. Most of the cases we've seen have been in diabetic dogs, but there are others who think hypothyroidism plays an important role.

Dr. R. Wells, Michigan, USA

PLATE 500: UREMIC MINERALIZATION
The opaque, white, corrugated plaques in the intima of this calf's pulmonary artery are mineralized intimal plaques as a result of uremia caused by renal amyloidosis. Toxic levels of Vitamin D as well as some plants can also cause this.

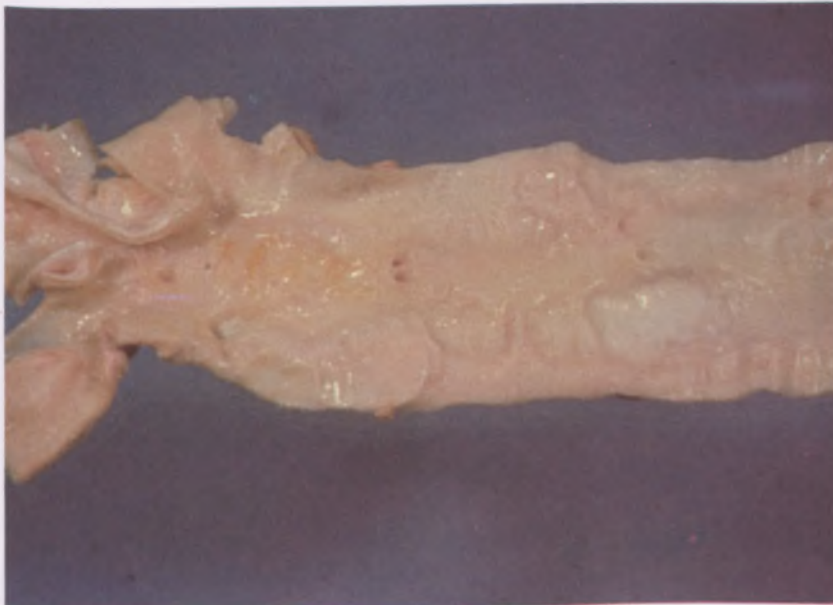

PLATE 498: AORTIC MINERALIZATION

The mineralization in the aorta of this cow is recognized by the multiple pale, slightly raised plaques. Often these are just found as incidental lesions in cattle and other animals. They are however quite commonly found in cattle with Johne's Disease and also in the past when Hyperkeratosis (X Disease) was prevalent. It is now thought to be more commonly seen with a vitamin/mineral imbalance or even uremia.

Dr. D. Kradel, North Carolina, USA

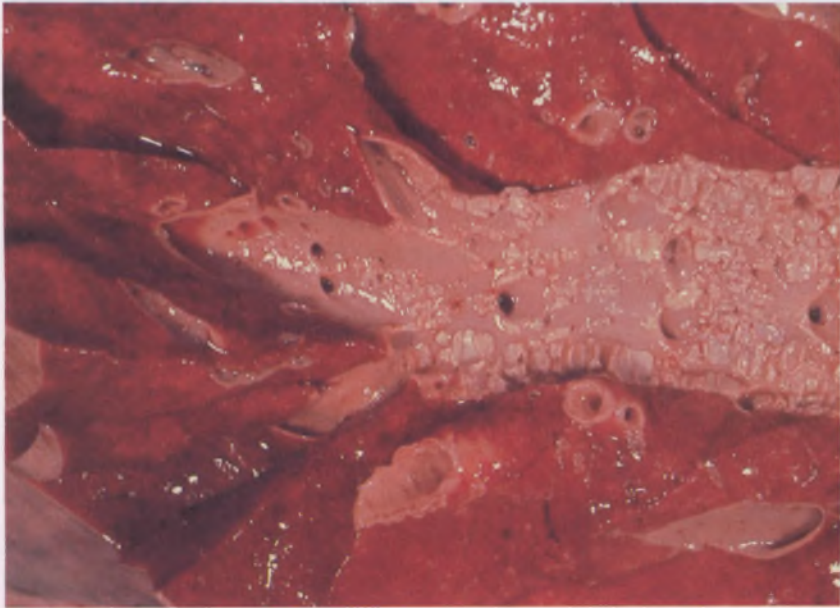


PLATE 499: MULTIFOCAL ARTERIAL MINERALIZATION

The multiple discrete opaque plaques on the intima of this pulmonary artery are plaques of mineralization, mostly composed of calcium. This may be caused by uremia, hypervitaminosis D, hypovitaminosis A (A is antivitamin D, in effect), and, in this case by the pseudohyperparathyroidism which is seen associated with some malignant neoplasms, such as lymphosarcoma as in this horse, and malignant anal sac gland tumors in dogs. Similar lesions can be seen in other vessels. The aorta is sometimes heavily mineralized in Johne's Disease in cattle.

Dr. D. Meuten, Ohio, USA

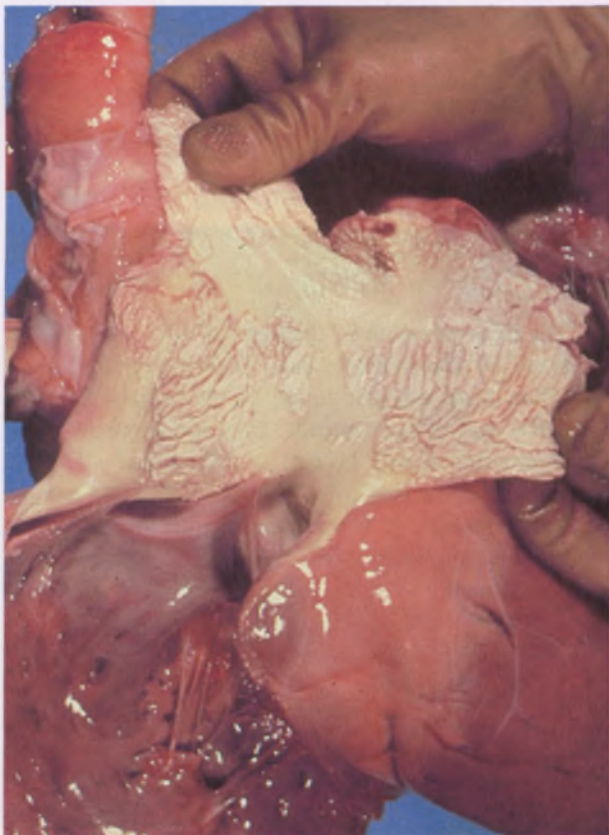


PLATE 500: UREMIC MINERALIZATION

The opaque, white, corrugated plaques in the intima of this calf's pulmonary artery are Mineralized Intimal Plaques, as a result of uremia caused by Renal Amyloidosis. Toxic levels of Vitamin D as well as some plants can also cause this.

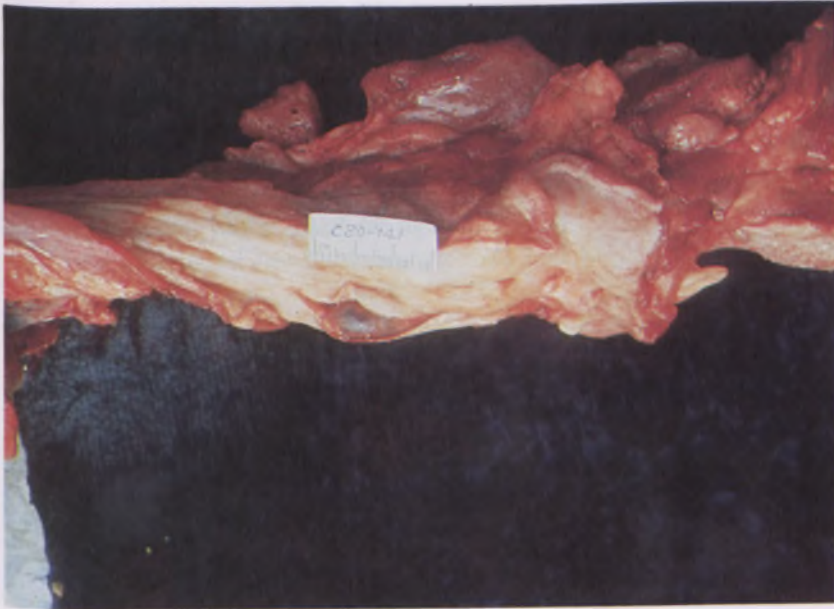

PLATE 501: ESOPHAGEAL VEIN THROMBOSIS

The red lump in the periesophageal tissue, exposed by the cut in the esophagus, is a thrombus of a major vessel in this area. The cause is thought to be traumatic, possible from swallowing a hard bolus of food. It has been seen only in the pig. It is to be differentiated from jugular vein thrombosis associated with intravenous therapy.

Dr. R. Chu, Taiwan, ROC

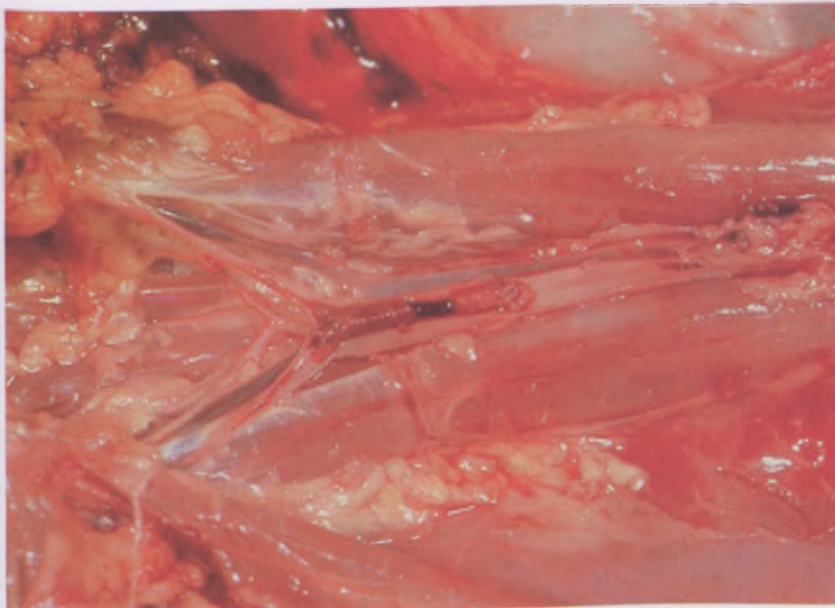


PLATE 502: AORTIC THROMBOSIS

The blood clot in the distal portion of this cat's aorta is a thrombus, which is attempting to go down both femoral branches at the bifurcation of the aorta. This is called a Saddle Thrombus and originated from the left heart of a cat with Cardiomyopathy. It is an acute lesion and may still be considered an embolus as it is only trapped not attached. These often cause acute paralysis in the cat with a most striking absence of a femoral pulse.

Dr. J. Inhelder, New York, USA

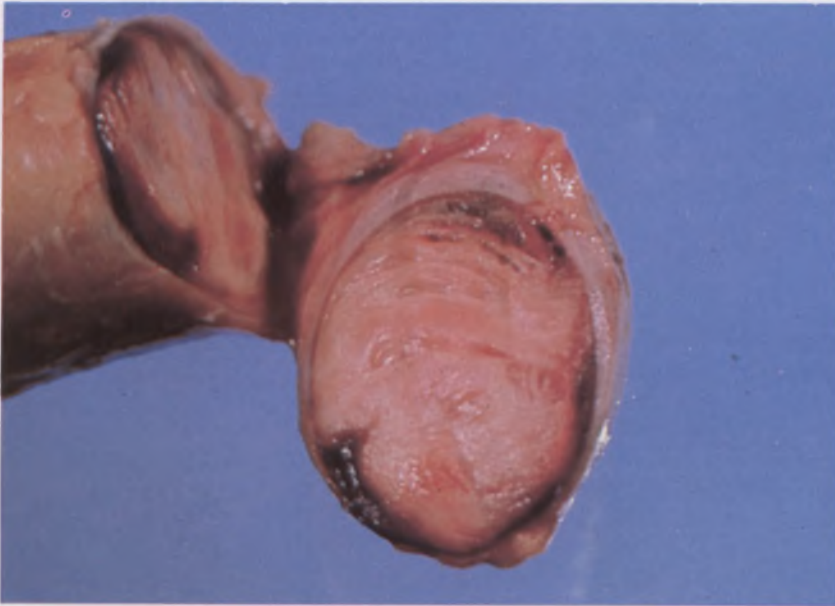

PLATE 503: JUGULAR VEIN THROMBOSIS

The well marked irregular laminations, its overall dry and fragile appearance and its apparent attached nature all make this a thrombus in the jugular vein of a horse. These can become free and move as emboli through the heart to the pulmonary arterial bed. Most are associated with intravenous injections.

Dr. J. Hinrichs, New York, USA

PLATE 500: UREMIC MINERALIZATION

The opaque, white, corrugated plaques in the lumen of this calf's pulmonary artery are mineralized fibrin plaques, as a result of uremia caused by renal amyloidosis. Toxic levels of Vitamin D as well as some plants can also cause this.

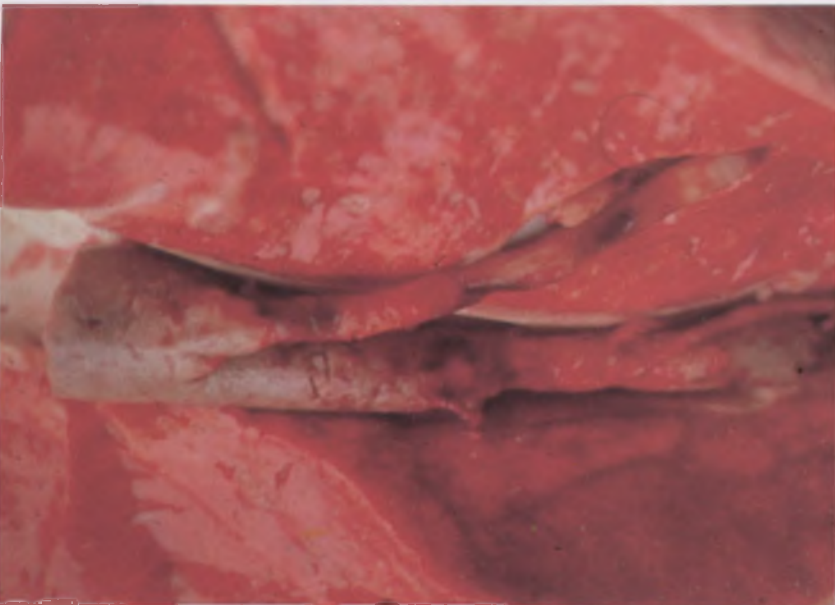


PLATE 504: PULMONARY ARTERY THROMBOSIS

This foal's lung shows a typical, dry, irregularly laminated, fragile, attached mass in a branch of the pulmonary artery. Many of these can come from other areas of the body, where infection or other causes of venous thrombosis can occur, such as from infected leg lesions, jugular vein thrombi and right heart vegetative endocarditis. A new and maybe not too uncommon source may be from renal vein thrombosis, associated with diarrhea or extensive electrolyte therapy. If this one did arise elsewhere in the body it should have properly been called a thrombus where it arose and was attached. When it broke free and traveled it was an embolus. As it is now attached again and it is a blood clot, it can be called a thrombus. Thromboembolism would explain this process neatly.

Dr. J. Hinrichs, New York, USA

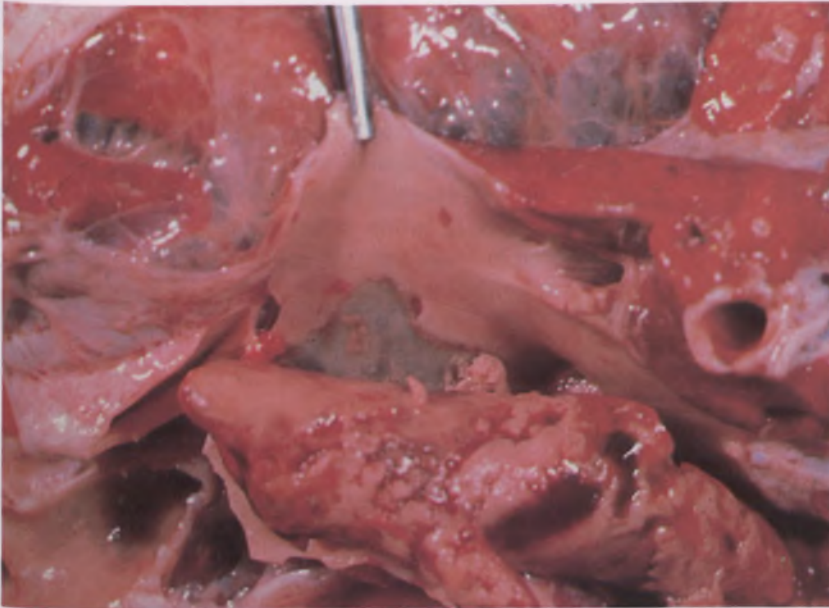

PLATE 505: PULMONARY ARTERIAL INFARCTION

The large, friable, roughly laminated, attached mass in the pulmonary artery of this cow is a thrombus. Underneath the thrombus and affecting the wall of the vessel itself is a distinct zone of blue green discoloration with a slight lip at its boundary. This is a rare lesion of Pulmonary Artery Infarction, apparently caused by compromise of the vessels to the arterial wall itself, probably by pressure on the vasa vasorum. The source of such large thrombi are usually from jugular vein thrombosis, uterine or mammary gland vein thrombosis or the more newly recognized renal vein thrombosis.

Dr. C. I. Liu, Taiwan, ROC

PLATE 510: RUPTURED VENA CAVA ABSCESS

A gloved hand is holding the mass of tissue away from the ruptured vena cava in a cow. In the

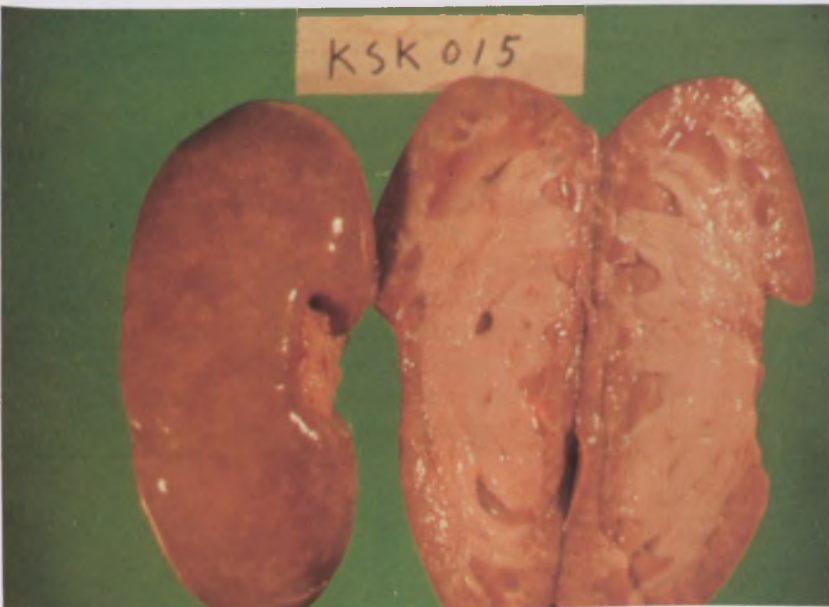

PLATE 506: POLYARTERITIS NODOSA

This kidney shows many pale areas primarily in the cortex, some of which have a slight inflammatory reaction associated with them. These areas histologically are classical examples of Polyarteritis Nodosa. Apparently large numbers of pigs affected with this disease are to be found in the southern part of Taiwan, but the cause is unknown.

Dr. C. I. Liu, Taiwan, ROC

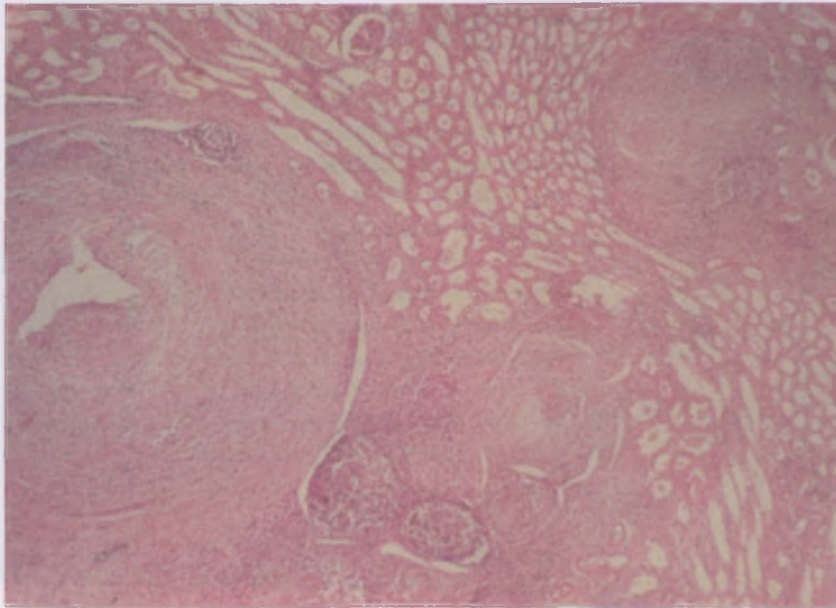


PLATE 507: POLYARTERITIS NODOSA

The thickened vessels involving all three layers of these renal arteries along with the mononuclear inflammatory cell response are all characteristic of this common disease in pigs in the southern part of Taiwan. The cause of this renal Polyarteritis Nodosa in swine is unknown. Similar lesions are seen in other animals, especially in the cow and rat, as well as man.

Dr. C. I. Liu, Taiwan, ROC

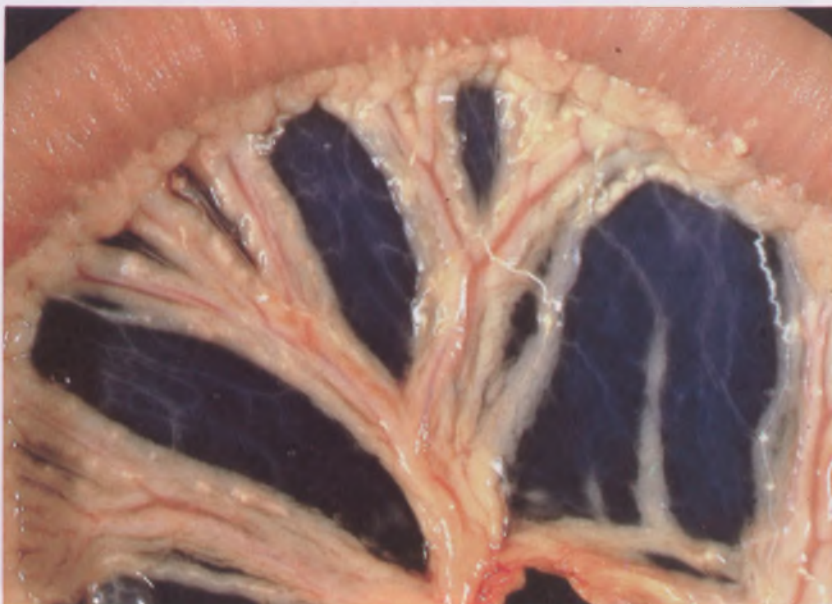
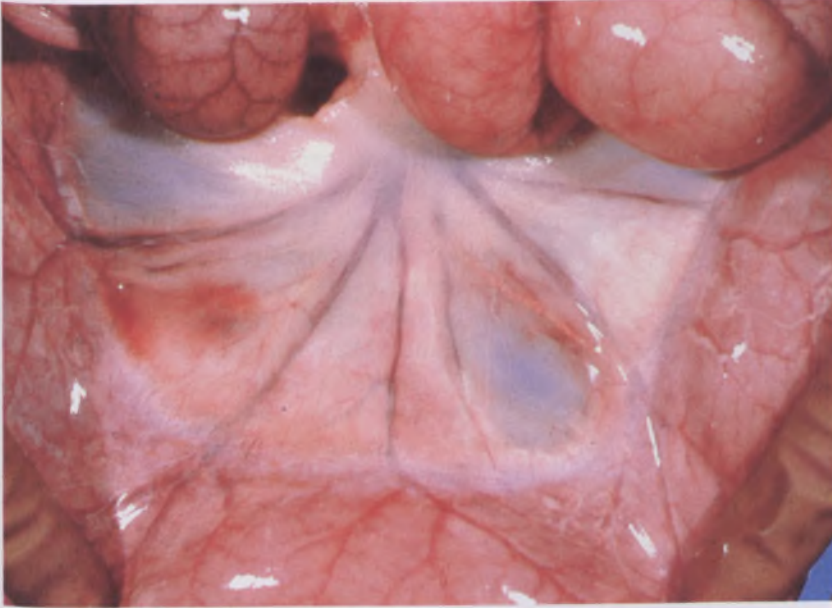


PLATE 508: NECROTIZING LYMPHANGITIS

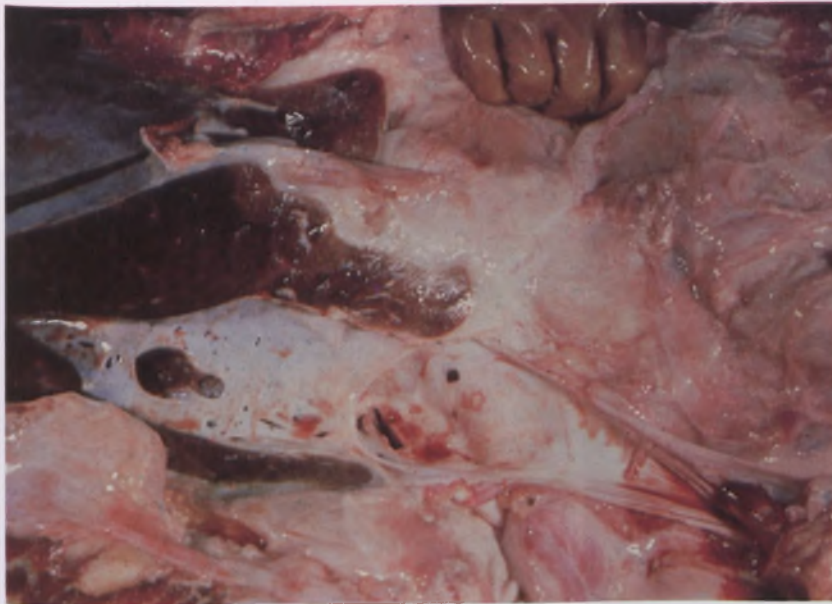Scattered in the serosa of this loop of intestine just at the mesenteric attachment area are numerous 1-2mm opaque white nodules. In the mesentery itself are a few scattered irregular linear streaks of opaque white material. These are foci of acute necrotizing lymphangitis in the mesentery and serosa. These have been seen in the dog and pig, but no cause has been established. Histologically some lymphatic stasis is present with a marked necrotic reaction in the vessel wall with many neutrophils present.

Dr. D. Meuten, Ohio, USA



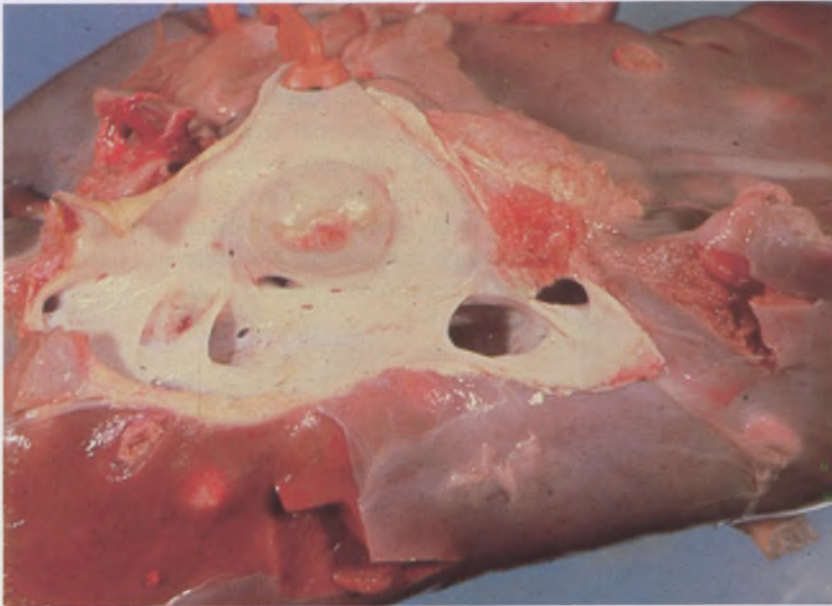
**PLATE 509: NECROTIZING
LYMPHANGITIS**

This intestinal loop segment from a pig shows several opaque, irregular streaks in the mesentery, and the more faint streaks in the serosa of the gut itself. These are areas of necrosis of the lymphatic vessels with many neutrophils as part of the inflammatory component. No cause has been established. It has also been seen in dogs.



**PLATE 510: RUPTURED VENA CAVA
ABSCESS**

A gloved hand is holding the mass of tissue away from an opened caudal vena cava in a cow. In the wall of the vena cava an opening with granulation tissue can be seen with a lump like mass just cranial to it bulging into the lumen of the vena cava. This cow had multiple liver abscesses, one of which ruptured into the vena cava and one which potentially could have. The rupture of these into the vena cava is one of the more common causes of sudden death in cattle in New York State. It causes an acute massive pulmonary edema, considered to be an anaphylactic reaction because it is usually seen with multiple more chronic, small embolic abscesses scattered in the lung. This is suggestive of a previous embolic shower which in effect sensitized the animal for the second rupture, which kills by massive pulmonary edema. Sometimes cattle die without evidence of a previous rupture of the liver abscess. One can often find emboli of necrotic debris, histologically, in the pulmonary arterioles.

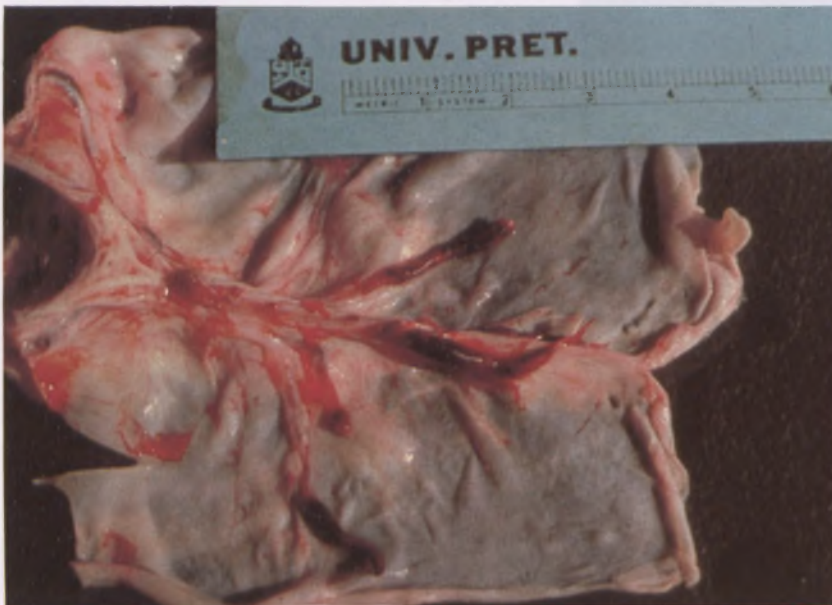


Dr. C. J. Litz, Tshwane, ROC

PLATE 511: HEPATIC ABSCESS

This was an incidental finding in this cow. It is a liver abscess that is bulging into the lumen of the caudal vena cava. The noteworthy point is that it had apparently ruptured once sometime in the past and healed over, as evidenced by the reaction on the bulging surface. It is suggested from this that as pressure builds up again in the abscess this could rupture again for the second time, which would cause an anaphylactic type lung reaction and the cow would most likely die of acute massive pulmonary edema. Scattered smaller abscesses can also be seen in the liver. Often when only a single abscess is present in a cow's liver it is near the vena cava but the reason for this location is not known.

PLATE 510: RUPTURED VENA CAVA
ABSCESS
A gloved hand is holding the mass of tissue away from an opened caudal vena cava in a cow. In the



Dr. P. Pienaar, Onderstepoort, RSA

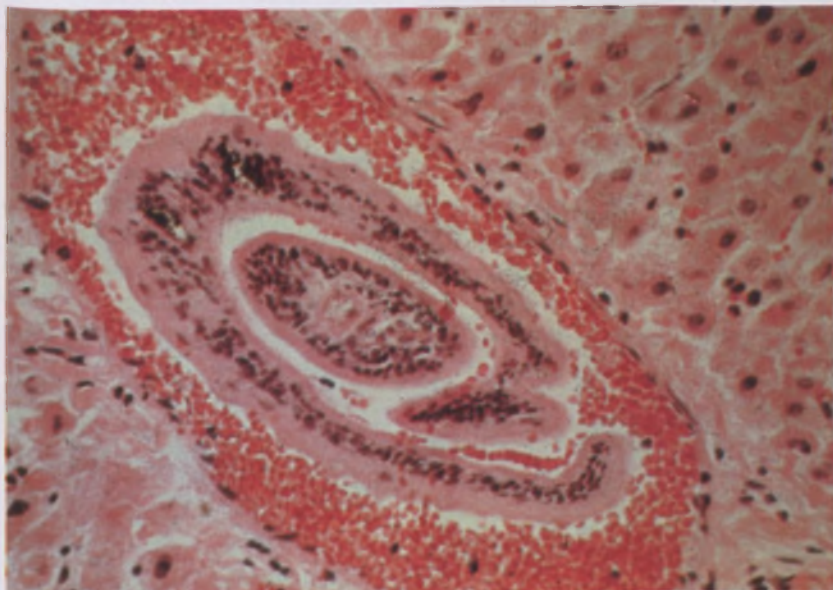
PLATE 512: CEREBRAL VASCULAR THROMBOSIS

The dorsal portion of the cerebral dura mater including parts of the falx cerebri and tentorium cerebelli along with their attached vessels are shown. The vessels are thickened and firm because several contain well marked thrombi. This is from a natural case of Turning Disease in a cow caused by *Theileria mutans*. These thrombi were associated with large areas of infarction in the cerebellum. Of diagnostic aid, is to make direct smear impressions from damaged tissues at the edge of the lesions, and look for the protozoal organisms in the white blood cells.

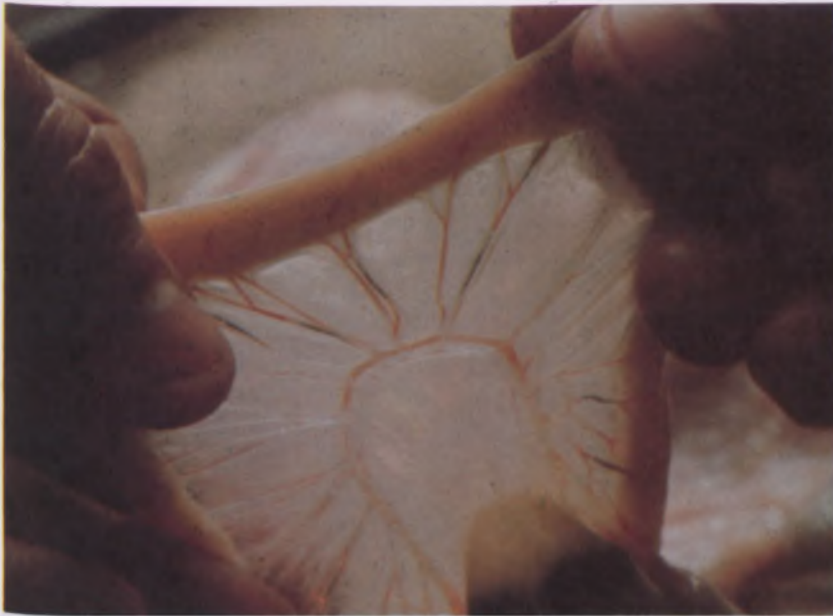

PLATE 513: PORTAL VEIN BLOOD FLUKES

Eight long, thin, black parasite, *Shistosoma spp.* can be seen in the portal veins of this sheep's mesentery. Two are in the same tributary. Blood flukes are common in most of the warmer parts of the world. They cause a great deal of damage as the female lays spiked eggs which travel to the liver and produce a granulomatous response. With many eggs, one can imagine the final outcome. Some are found in the urinary bladder and ureter vessels with the same granulomatous reactions.



**PLATE 514: BLOOD FLUKES
(*SCHISTOSOMA SPP.*)**

This histological section from the liver shows the smaller female *Schistosoma spp.* clamped by the larger male. This is only one of the few species of parasite in which the male is larger than the female. These probably migrated to this area after the death of the host as usually they are found in the various tributaries of the portal vein.

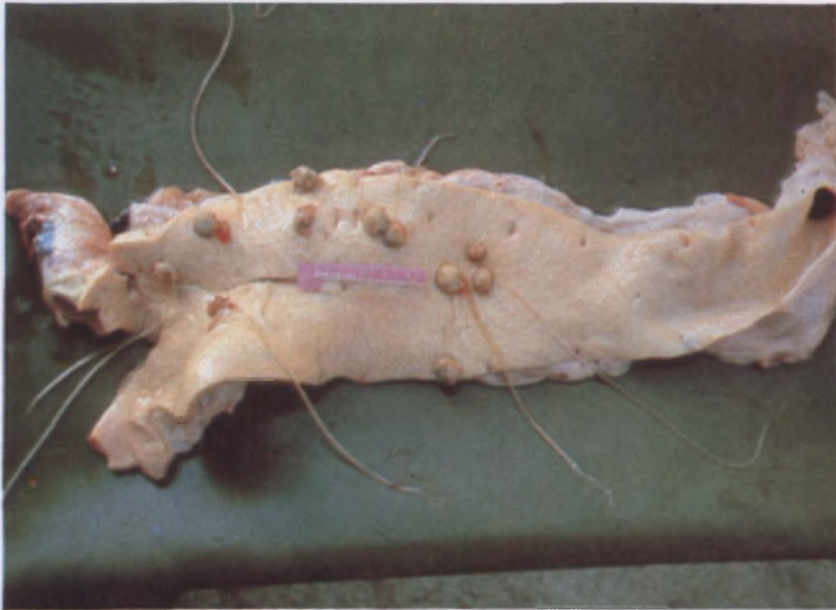


PLATE 515: MULTIPLE PARASITIC GRANULOMATOUS AORTITIS

The multiple parasitic granulomas in this cow's aorta with a worm attached are *Eleaophora* spp. This is a common parasite in cattle in Bangkok, Thailand where this photo was taken.

Dr. P. Arjdonkoon, Thailand

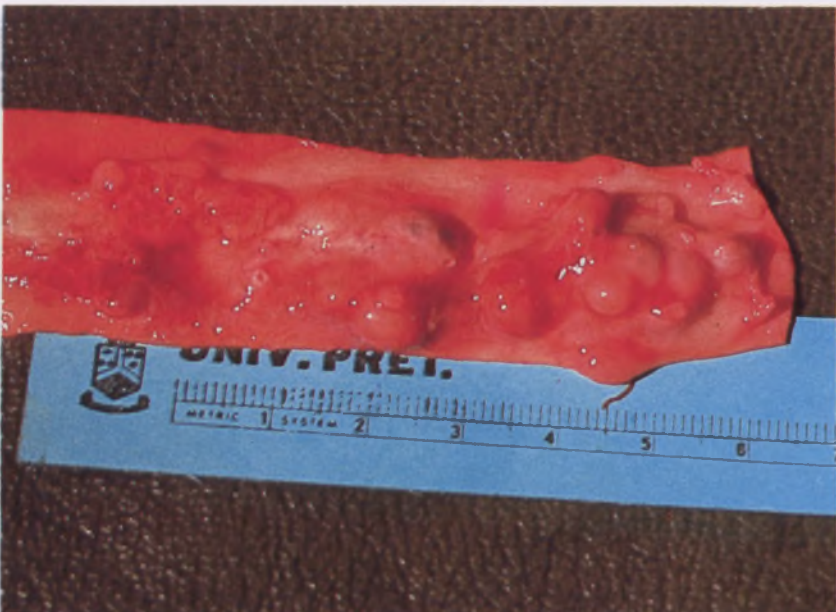
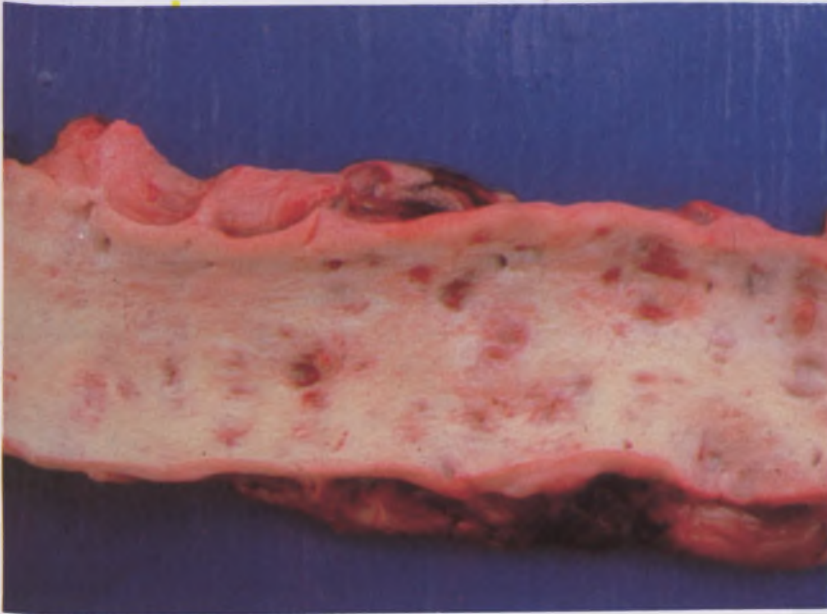
PLATE 516: PARASITIC AORTIC GRANULOMAS

This external view of a dog's aorta shows multiple nodules intimately associated with the tunica adventitia. These are the granulomatous nodules and brood pouches, caused by the migration of *Spirocerca lupi* larvae from the aorta to the esophagus. Often they are associated with the formation of malignant mesodermal neoplasms such as fibrosarcomas, osteogenic sarcomas and in some instances, carcinomas. Fatal hemorrhage from these has also been noted.



Dr. George Appel, Africa

PLATE 517: PARASITIC AORTITIS

The inner surface of this dog's aorta shows many red and grey stained slightly roughened depressions in its surface in addition to the paired, normal intercostal arteries. These irregular depressions are scars caused by the egress of the esophageal worm, *Spirocerca lupi* towards the esophagus.

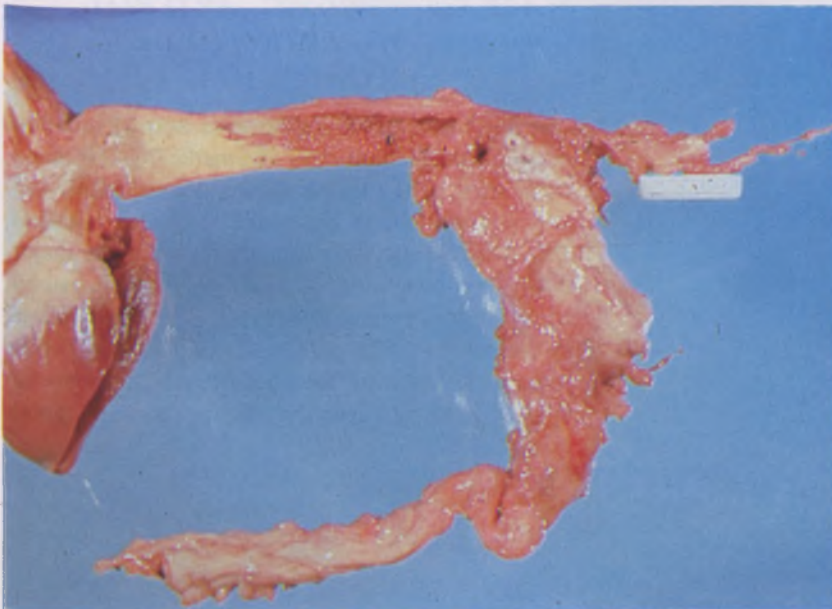


PLATE 518: VERMINOUS ARTERITIS

The closed cranial mesenteric artery of this horse is markedly thickened and dilated and the aorta from this vessel cranially has been opened to show the marked endothelial roughening and thrombosis caused by *S. vulgaris*. This verminous induced arteritis extends as far forward as the midthoracic aorta. The amazing compensatory response of an animal's body is shown by the fact that, as severe as this lesion is in a major vessel, it often does not cause such problems as gut infarction.

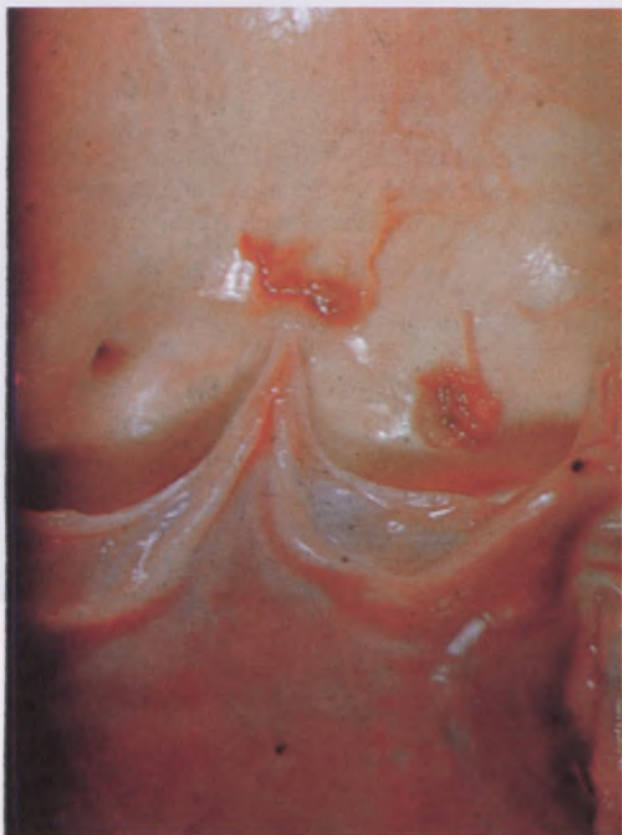

PLATE 519: PARASITIC GRANULOMAS OF THE AORTA

On the wall at the base of the aorta just above the aortic cusps are two granulomatous masses forming around two dead *S. vulgaris* larvae whose shape can just be made out within the young granulation tissue. Fine, crisscross streaking of the aortic intima just above these nodules are hemolyzed blood stained endothelial tracks previously made by the larvae in their wandering up the cranial mesenteric artery and related vessels from the intestines.

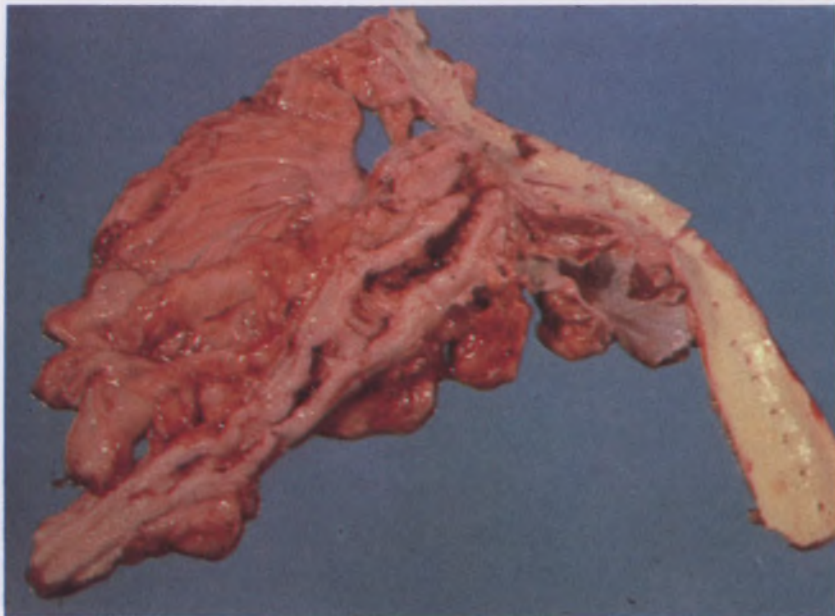


PLATE 520: CHRONIC ARTERIAL HYPERTROPHY AND HYPERPLASIA

The aorta of this young horse is normal, but the cranial mesenteric artery is markedly thickened along most of the length shown. The proximal end of the artery shows the typical parasitic vasculitis caused by *Strongylus vulgaris* larvae, but the major thickening along most of its length has been caused by a marked medial hypertrophy and hyperplasia as the result of the parasite damage above. This is quite different from the usual vascular response of a granulomatous reaction to the parasite larvae locally.

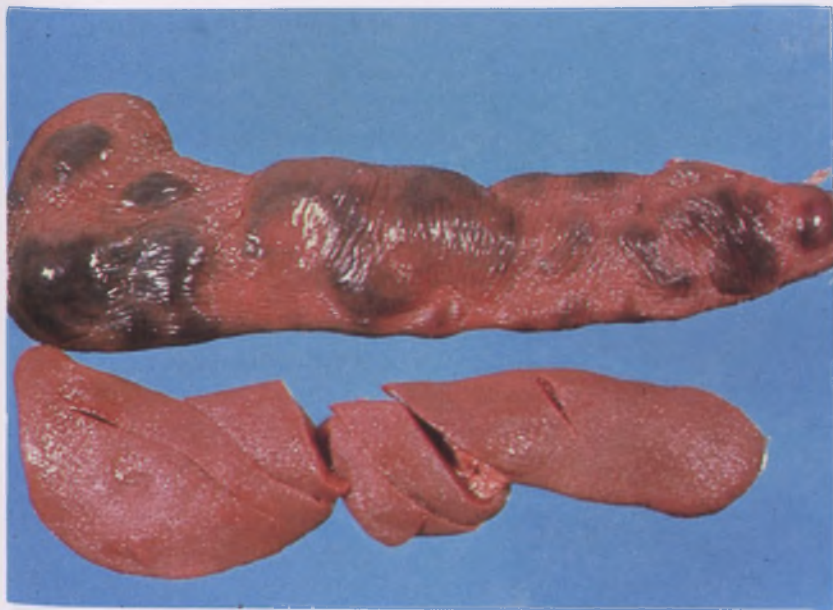


PLATE 521: UNEQUAL EXPULSION OF BLOOD

The dog's spleen with the several knife cuts is normal. The other spleen shows many irregular dark masses scattered in its parenchyma. These are areas where blood was trapped before the spleen had contracted fully, for whatever reason. It is called Unequal Expulsion of Blood and is a common post-mortem finding of usually no significance. Sometimes thrombi may form in these.

Dr. T. H. Miller, M.D., Ph.D., D.V.M., D.A.C.V.P.

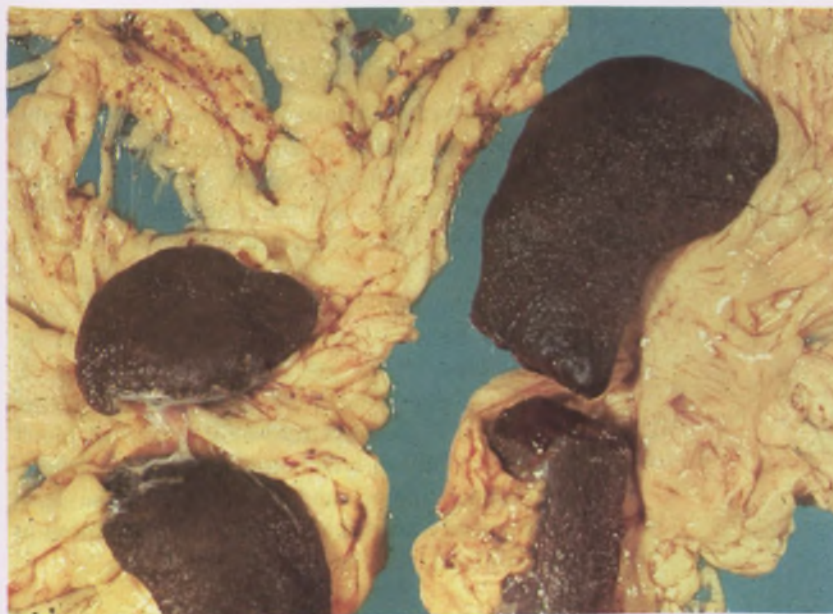
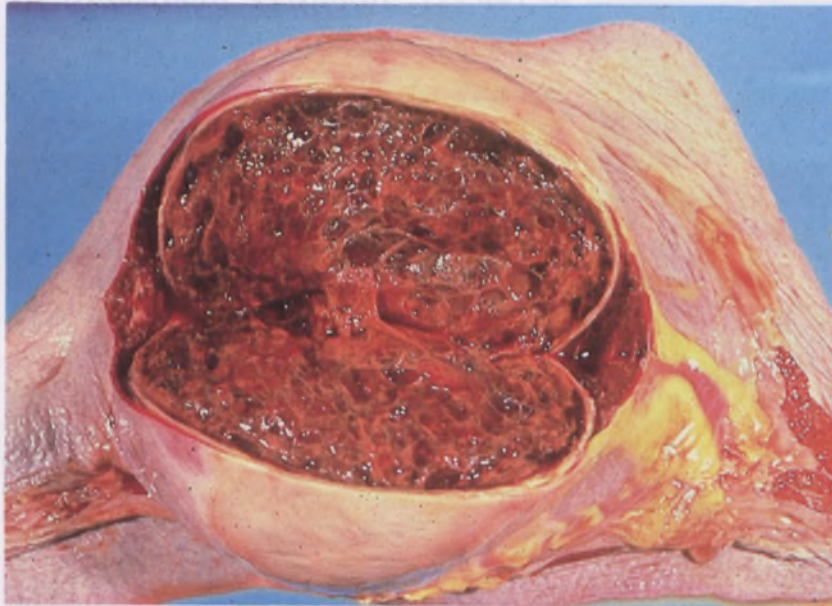


PLATE 522: SPLENIC TRAUMA WITH DAUGHTER SPLEEN FORMATION

The two dog spleens shown here have both been traumatized. The slightly larger spleen had been traumatized just 18 hours before in a car accident. It is thought that the spleen itself had been in a fully contracted state when the accident occurred as minimal blood loss was seen. Only bits of fibrin are sealing the ruptured site. The other spleen shows a rupture of several weeks duration and some early connective tissue about its ruptured edges. In addition many tiny, small, dark nodules of traumatically scattered splenic parenchyma are seen embedded in the surrounding mesentery and omentum. These are called Daughter Spleens. When many daughter spleens are seen, one should always look for healed scars in the splenic capsule, otherwise an implanted abdominal neoplasm, such as a hemangiosarcoma may be suspected.



Dr. K. McEntee, Illinois, USA

PLATE 523: SPLENIC HEMATOMA

The visceral surface of this horse's spleen is shown cut open to reveal a large well encapsulated bloody mass. Histologically, it was only a blood clot with a connective tissue capsule, but before anyone makes such a diagnosis they should carefully serial section the mass grossly, and possibly histologically, to rule out the presence of a small neoplastic mass of vascular tissue that may have ruptured and bled. In a few but significant number of such cases the animal has had a history of a nonresponding anemia, which in the senior author's opinion, may well be explained by the slow blood loss into the mass, with not enough blood loss at any one time to stimulate hematopoiesis.

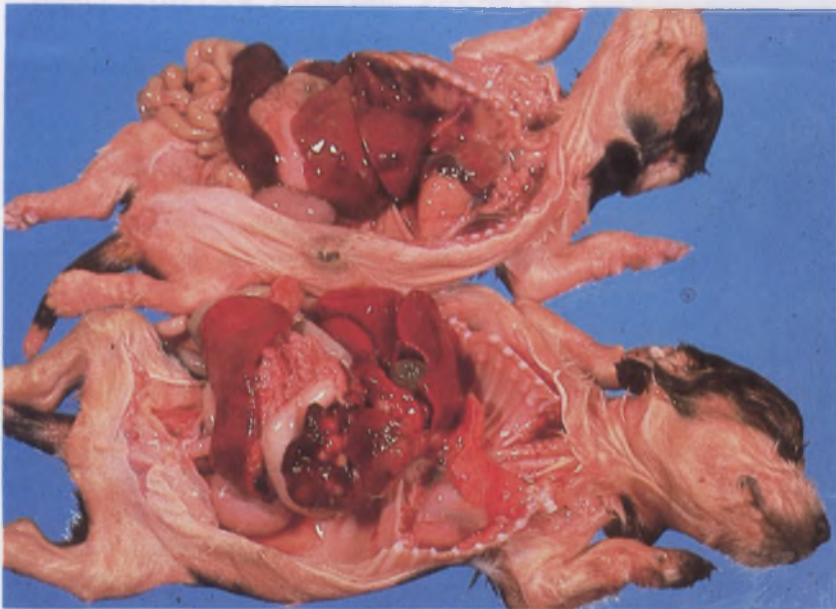


PLATE 524: INFECTIOUS (BACTERIAL) SPLENOMEGALY

These two beagle puppies both show Splenomegaly, although one spleen is larger than the other. The puppy with the largest spleen has many abscess pockets in its liver, and the other has only a few. Both puppies had an infected umbilicus, the probable portal of entry for the liver infection. Any of the common bacterial pathogens could have been involved. Splenomegaly has four major causes. 1-Barbiturates, or any of several chemical agents used for euthanasia; 2-Acute, severe, bacterial diseases such as this one; 3-Most protozoal blood diseases; 4-Diffuse lymphoproliferative and myeloproliferative tumors and mastocytosis. The term Splenomegaly as used above describes the spleen as being diffusely, not nodularly enlarged.

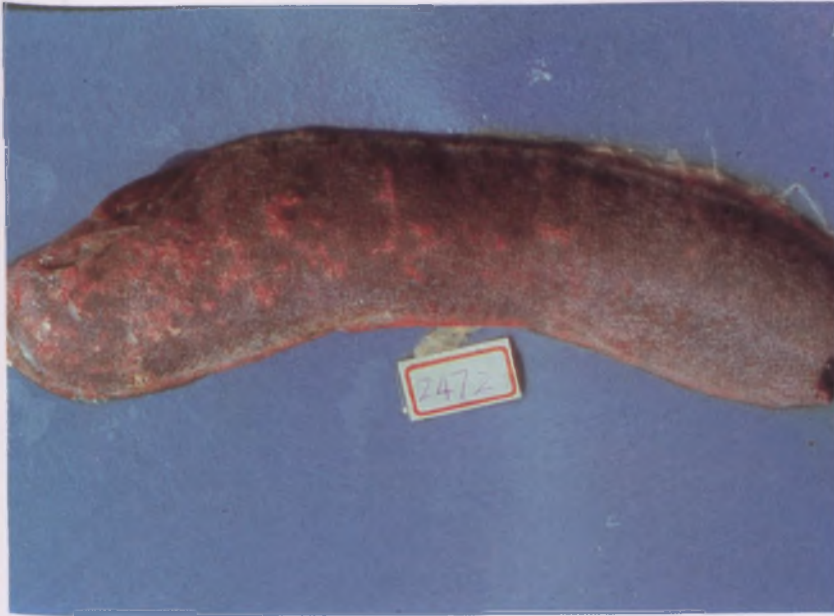

PLATE 525: BACTERIAL (*SALMONELLA CHOLERASUIS*) SPLENITIS

This pig's spleen is enlarged, rounded and blood does not run from its cut surface. It also has many yellow red firm foci scattered in its parenchyma. Pure cultures of *Salmonella cholerasuis* were obtained from this infected spleen. Another common pathogen could just as easily have been isolated.

Dr. T. H. Wang, Taiwan, ROC



PLATE 526: SPLENOMEGALY

The middle specimen of these three horse spleens is essentially normal in size even though it is from a positive Equine Infectious Anemia horse. The largest spleen is from a horse killed with a barbiturate and it is about 3 times normal size. Spleens up to 6 or 7 times normal size are not unusual in animals killed with some chemicals, especially barbiturates. At necropsy these enlarged spleens can be cut, and blood will flow quite freely from the cuts or the splenic veins if the blood is still unclotted. The smallest spleen shown came from a horse that was debilitated from chronic Strangles, and is shown here to counter the idea that one usually sees an enlarged spleen with chronic infections. Acute or chronic blood protozoal diseases splenic tumors and gastric torsions are also characterized by enlarged spleens.

Dr. R. Siller, Cornell, USA

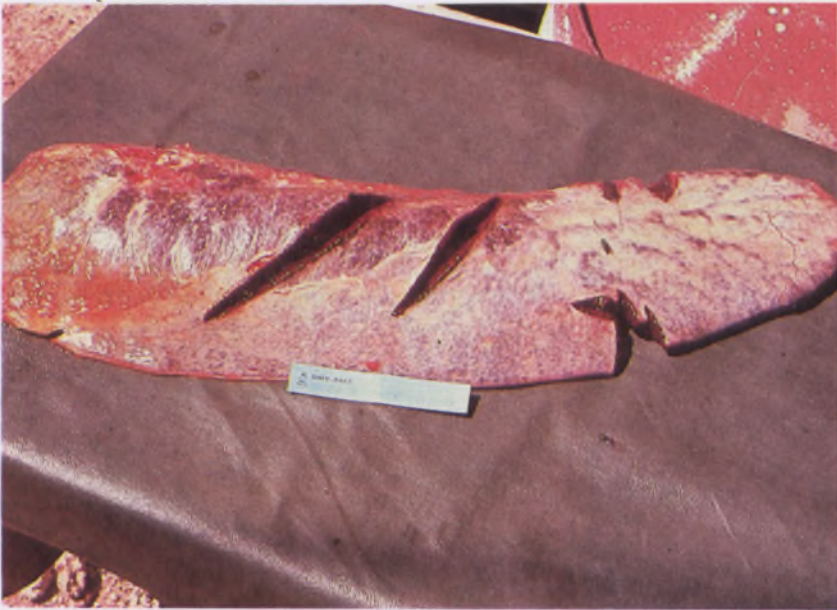

PLATE 527: INFECTIOUS (PROTOZOAL) SPLENOMEGALY

The cow spleen shown here is enlarged about 3 times. It is soft and swollen, the cut surface bulges and no blood drains or oozes from it. Several of the protozoal blood diseases such as Babesiosis and Anaplasmosis can be suspected. For some diseases such as this one of Bovine Babesiosis, this, along with red urine may be the only lesions. Blood smears of peripheral blood are always indicated to help make the diagnosis. This spleen is not as soft and mushy as in the usual neoplastic type of Splenomegaly and blood does not run freely from its cut surface as it would from a "Barbiturate Spleen" or "Chemical Spleen" from the drugs often used to kill the animals.

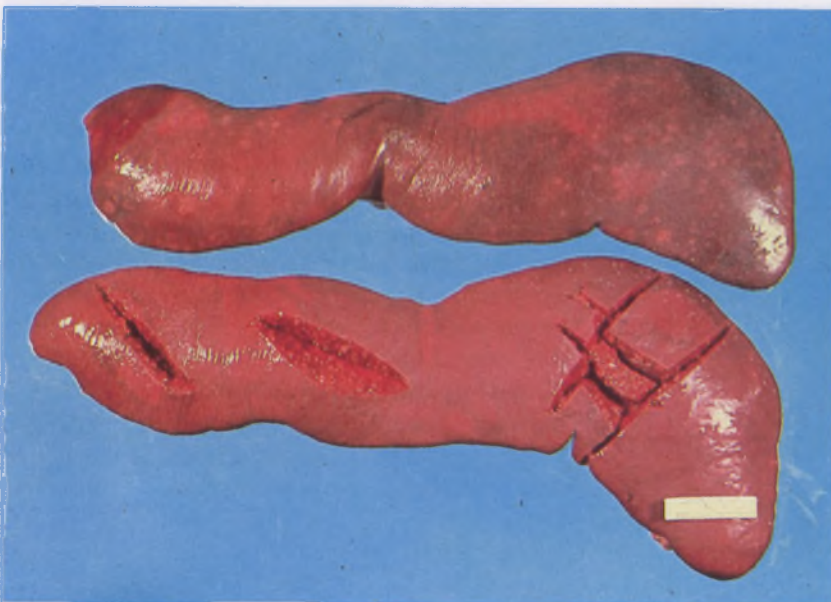


PLATE 528: NEOPLASTIC SPLENOMEGALY

The two dog spleens shown are from unrelated natural cases of Lymphosarcoma. They are both enlarged about 4–5 times and have distinctly rounded edges and a soft, mushy texture. The germinal centers are well pronounced in the parenchyma of both and show through as well as penetrate the capsule of one. These can get large enough to cause capsular tearing and fatal intraperitoneal hemorrhage. Out of context, one should also consider barbiturate or other chemical means of euthanasia, lymphoid or myeloid tumors, protozoal diseases, acute infections, even some storage diseases or amyloidosis when an enlarged spleen is first seen.

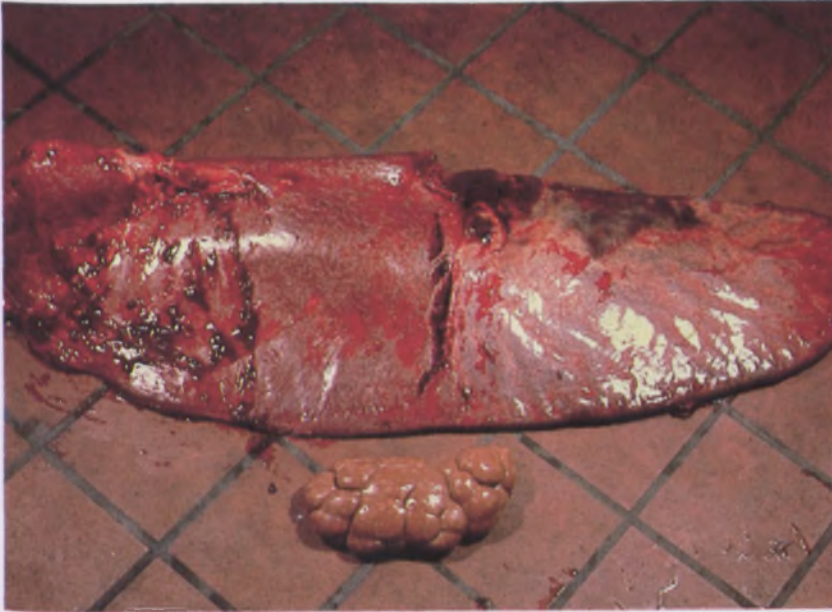

PLATE 529: NEOPLASTIC (MYELOPROLIFERATIVE DISEASE) SPLENOMEGALY

This cow actually bled to death from the ruptured splenic capsule. This Splenomegaly is the result of Myeloproliferative Disease and small white foci of similar cells, histologically can be seen scattered in the kidney. Lymphosarcoma may also affect the spleen and kidney like this, but it usually would affect other tissues too. These two tissues or even just the spleen itself may be the only organ affected grossly with Myeloproliferative Disease. The lack of blood freely draining from the spleen tends to rule out chemicals used for euthanasia and it is too soft and mushy to be from a reaction to acute or chronic infection.

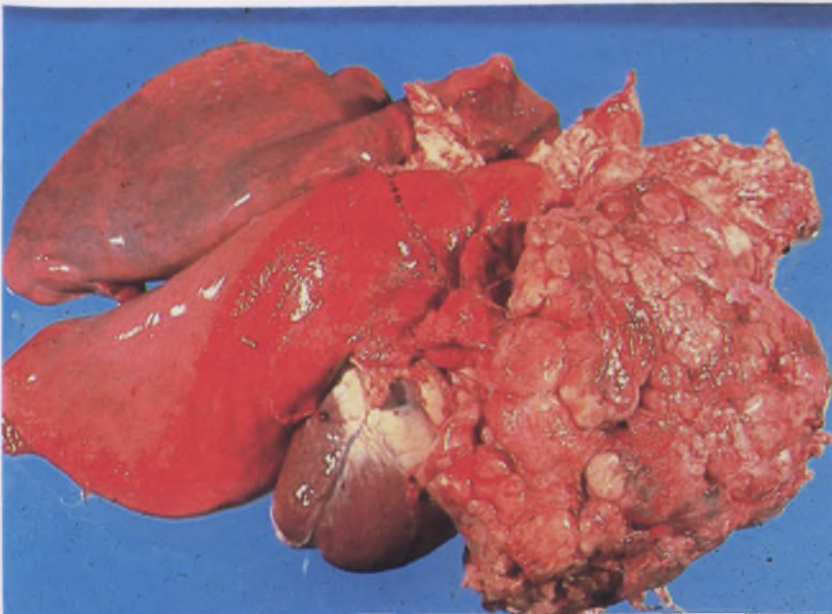


PLATE 530: THYMOMA

The large thymic mass shown here, in the anterior mediastinal region of a 15 year old goat, is a Thymoma. This is the most common tumor of old goats and they consist of lymphoid type cells, thymocytes and a minimal number of epithelial components, Hassel's corpuscles. Large anterior mediastinal masses of almost pure epithelial structures, the Hassel's corpuscles, have also been seen in aged goats.

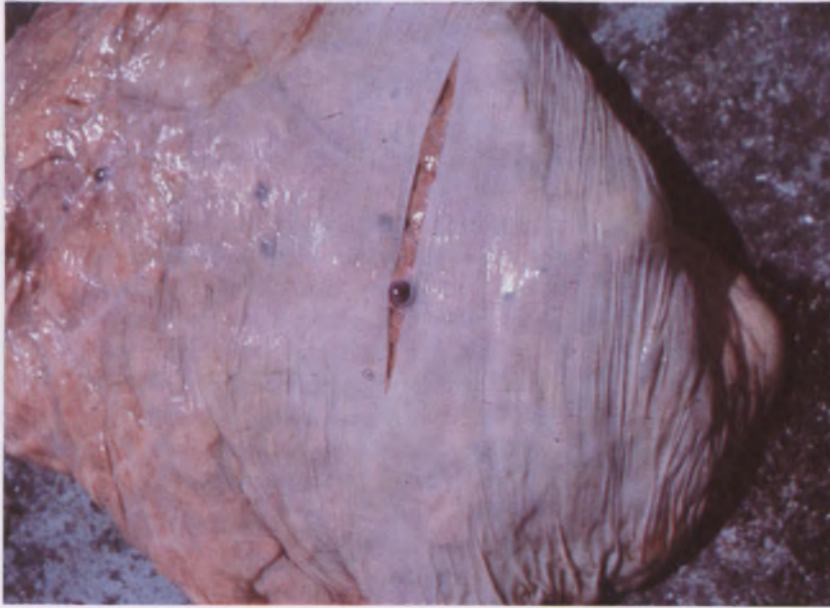

PLATE 531: PULMONARY HEMAL NODES

The use of artificial light film in sunlight results in pictures being off color, but it still shows the dark shiny nodules of Enlarged Hemal Nodes scattered in the lungs. The pleura has been cut over one node to demonstrate it better. This is a common problem of cattle in the Dominican Republic.

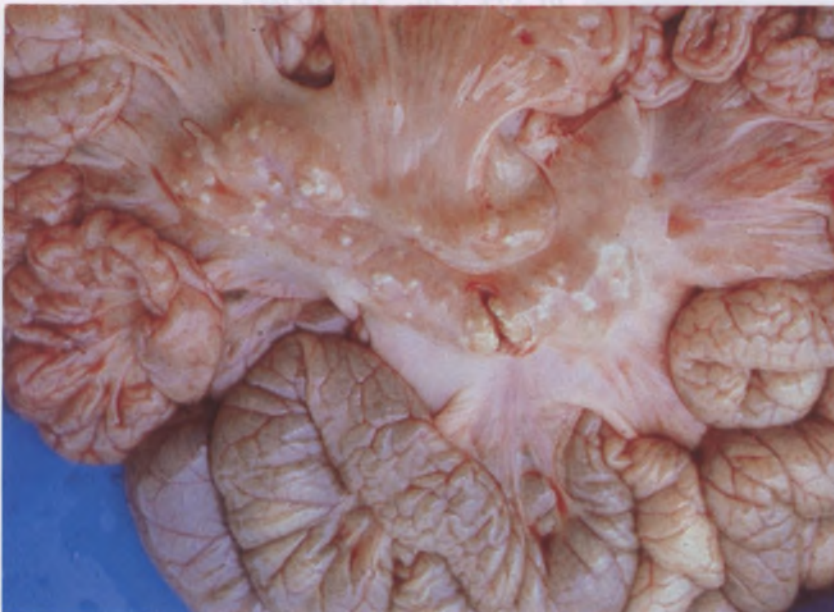


PLATE 532: MESENTERIC NODE ABSCESSSES

The multiple yellow foci in the mesenteric node of this pig are abscesses caused by *Staphylococci* spp. *Mycobacterium* spp. abscesses (or granulomas) are also quite common in this location. Bacteriological studies are necessary in such cases to prove the cause.

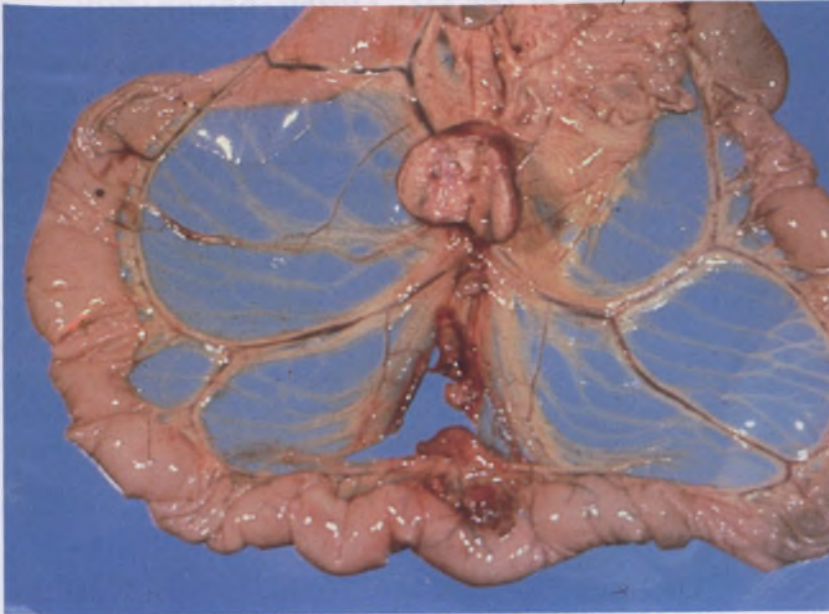


PLATE 533: BACTERIAL LYMPHADENOPATHY AND THROMBOSIS

The lymph node is markedly enlarged as the result of chronic *Streptococci equi* infection and the vessels leading to it are also infected and thrombosed. Bastard Strangles, such as this case, are difficult to treat for obvious reasons.

Dr. J. Coyne, North Carolina, 1934

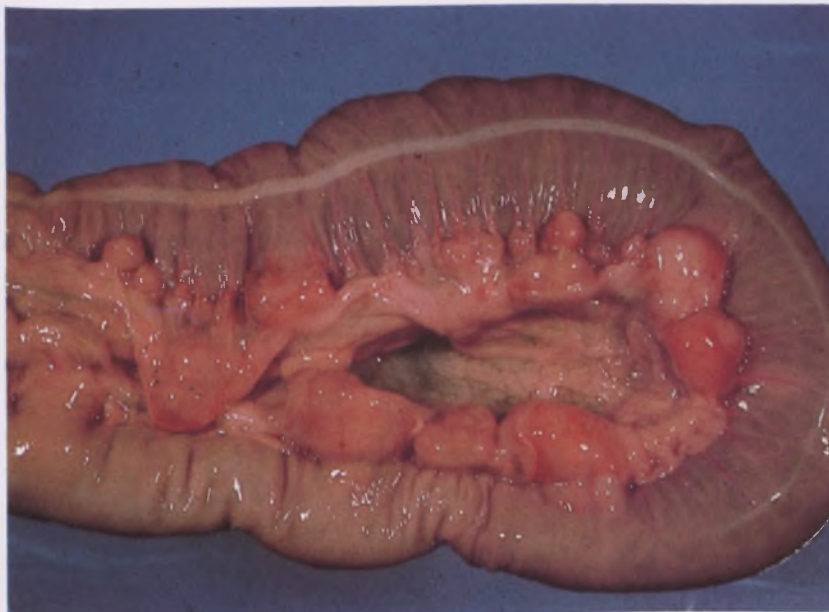


PLATE 534: MESENTERIC LYMPHADENOPATHY

The greatly enlarged lymph nodes along the colonic mesentery are due to chronic infection caused by *Streptococcus equi*, the cause of Strangles in the horse. Several areas of the colon wall are also pale and firm with mucosal ulceration underneath. *S. equi* infections in areas other than the neck are often termed Bastard Strangles. Bacterial smears and cultures are necessary to prove this diagnosis as other agents can mimic this infection.

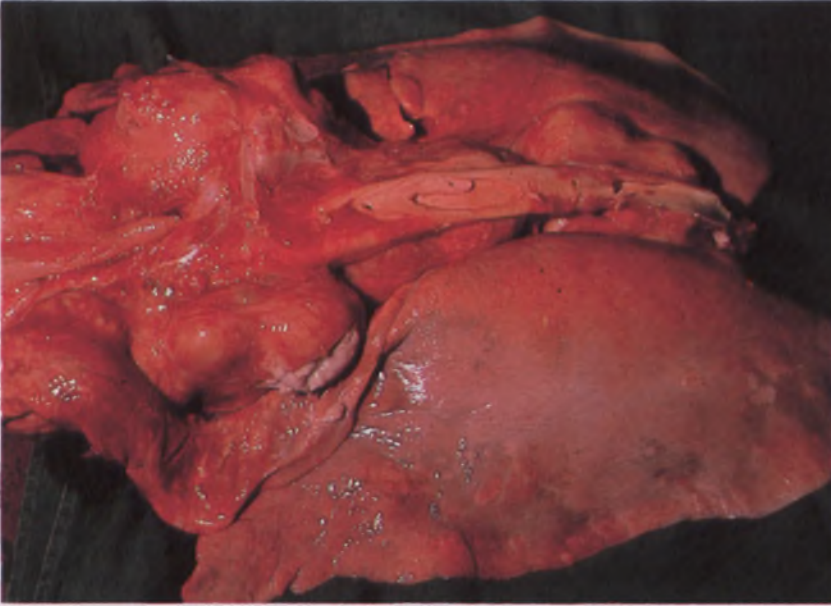


PLATE 535: LYMPHADENOPATHY

The bronchial nodes are markedly enlarged as the result of a chronic *Corynebacterium equi* infection. The causative agent for Strangles, *Streptococcus equi*, could also cause such lesions as can other bacteria. When nodes get this large as a result of infection one should also think that the host may not be able to mount a very efficient immune response against the organism. This may be a defect on the host's part or a variation in the virulence of the agent or both. There are several opposing views on treatment of such lesions in clinical cases. Cultures or smears are necessary to be more definitive.

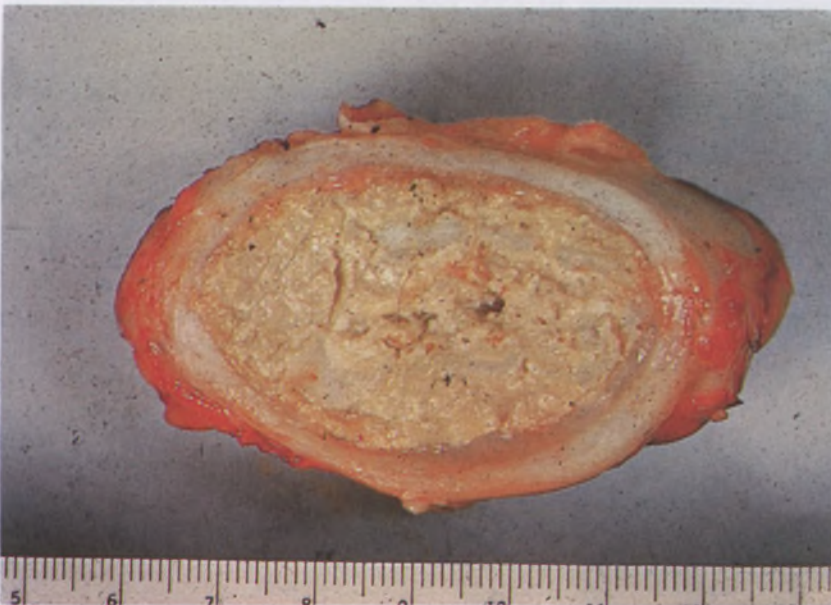

PLATE 536: CASEOUS LYMPHADENITIS

The sheep's lymph node shown here may actually be almost any one in its body, but most often affected like this are those in the cervical chain or bronchial nodes. The concentric laminations are unique and are characteristic of infections caused by *C. ovis*. Caseous Lymphadenitis, the name for this disease, is most often associated with shearing wounds allowing organisms to enter the lymphatic tracts. In some cases, nodular worms, *O. columbianum*, are possibly inciting agents. Some sheep have large encapsulated pockets of fluid pus in scattered nodes from which *C. ovis* is isolated. This suggests that the laminations are the result of periodic inspissation, while others are very small and already concentrically laminated, possibly suggesting that they are quite dry initially. One wonders how these would enlarge against the constrictive capsular pressure.

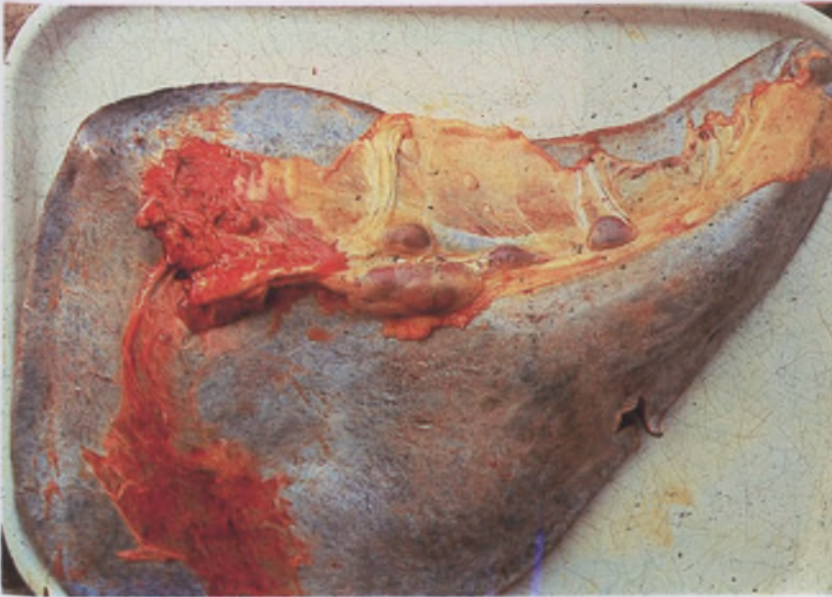

PLATE 537: SPLENIC LYMPHADENOPATHY

The enlarged brown splenic nodes and not the enlarged spleen are quite diagnostic for Equine Infectious Anemia (EIA Swamp Fever). These nodes have well marked reticuloendothelial cell hyperplasia, red blood cell stasis and phagocytosis making them enlarged. The spleen itself may or may not have follicular hyperplasia. The liver histologically has the diagnostic lesions for EIA which consist of a scattered mononuclear cell infiltrate in the sinusoids. Sometimes in 2–5% of the cases, the kidneys show a glomerulonephritis.

Dr. L. Coggins, North Carolina, USA

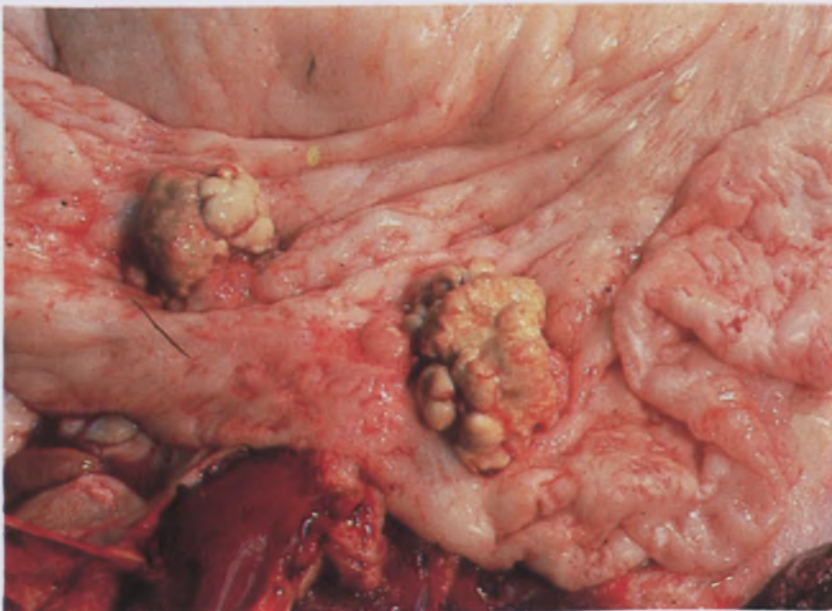
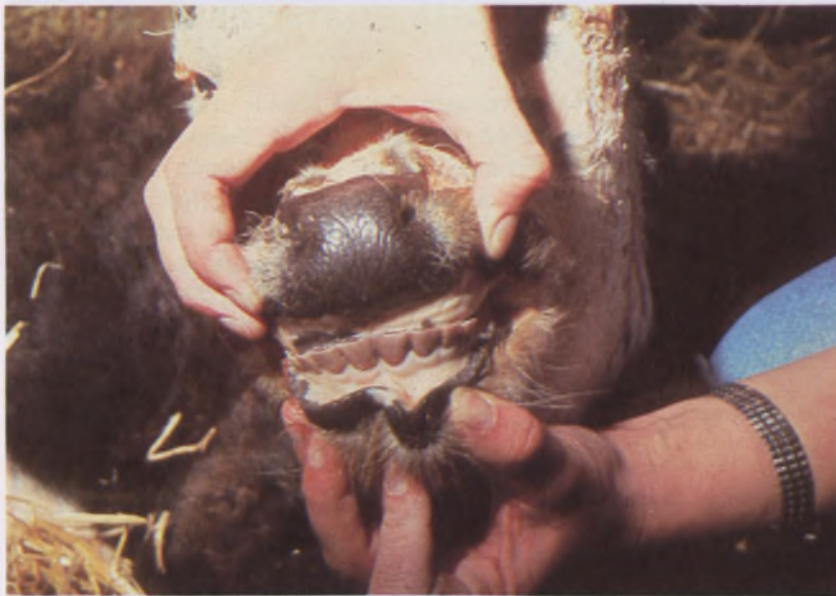

PLATE 538: LYMPHOSARCOMA

These are only two of many such masses associated with mesenteric lymph nodes in a goat. They are multinodular (botryoid) and many are firm, dry and green yellow while others are more flesh colored. At first the tentative diagnosis was given as Tuberculosis but the histological diagnosis confirmed the case as Lymphosarcoma. Nodules were scattered elsewhere in the body which also were not initially considered as neoplasia. The green yellow color is due to necrosis of the rapidly growing tumor masses which is a characteristic feature for lymphosarcomas more than most other tumors.



Dr. B. Glenn, Oklahoma, USA

**PLATE 539: CONGENITAL PORPHYRI-
NOSIS OF TEETH**

The slightly pink purple discoloration of the incisor teeth of this cow is the result of a congenital defect in the metabolism of porphyrin. The bones likewise would be a pink purple to even darker shades. Some, but not all, affected animals show photosensitization as a result of this disease. An occasional pig in Taiwan has been seen with the disease.

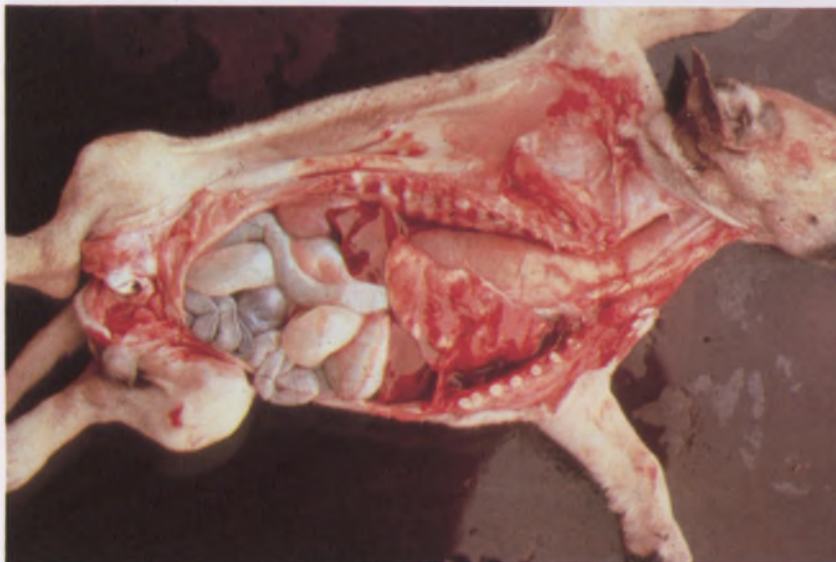
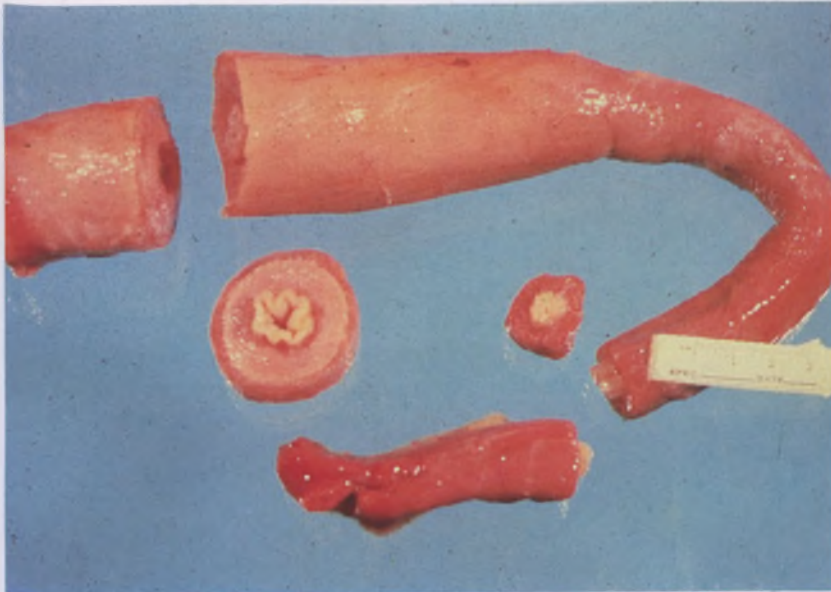


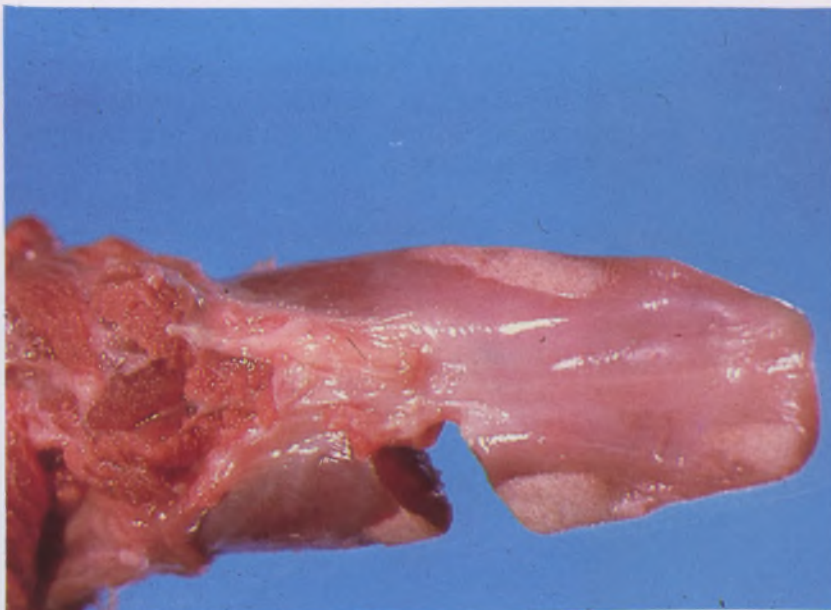
PLATE 540: MEGAESOPHAGUS

The entire esophagus as exposed here is markedly dilated in this dog. No vascular ring is present near the heart which rules out a commonly found cause of persistent right aortic arch. With no observable obstruction at the distal end of the esophagus one is forced to consider that the lesion is an intrinsic malformation of the esophagus itself. The cause is not known.



**PLATE 541: IDIOPATHIC HYPERTROPHY
OF THE DISTAL
ESOPHAGUS IN A HORSE**

Most of the horse's esophagus is shown here. Its cranial end is red, striated muscle as is normal, but its distal portion and almost half its length consists of markedly hypertrophied, pale, smooth muscle cells. The cause of this distal esophageal hypertrophy is not known. It is seen in up to 30% of 600 or so horses necropsied at Cornell yearly. Rarely does this lesion cause clinical problems such as difficulty in swallowing, whereas the Idiopathic Hypertrophy of the Ileum in horses and pigs, commonly cause digestive problems.



**PLATE 542: UREMIC EPITHELIAL
NECROSIS**

Along side the ventral surface of this cat's tongue are two granular plaques and a third similar plaque anterior to one of paired plaques. These are areas of surface epithelial necrosis with mineralization as the result of chronic renal disease with uremia.



PLATE 543: WHITE MUSCLE DISEASE OF THE TONGUE

The distinctly opaque, white muscles scattered between the more normal muscle bundles, in a zone just under the epithelium on the dorsal surface of this calf's tongue, are degenerate muscles affected with White Muscle Disease, usually a Vit E or Selenium Responsive Disease. Some calves, especially veal fed calves on milk replacer, may have a true type of Vit. E/Se deficiency, but this is not the case in most naturally fed animals that get the disease. The opaque white appearing tissue deeper and more caudally placed in the tongue is the normal adipose tissue in that area.

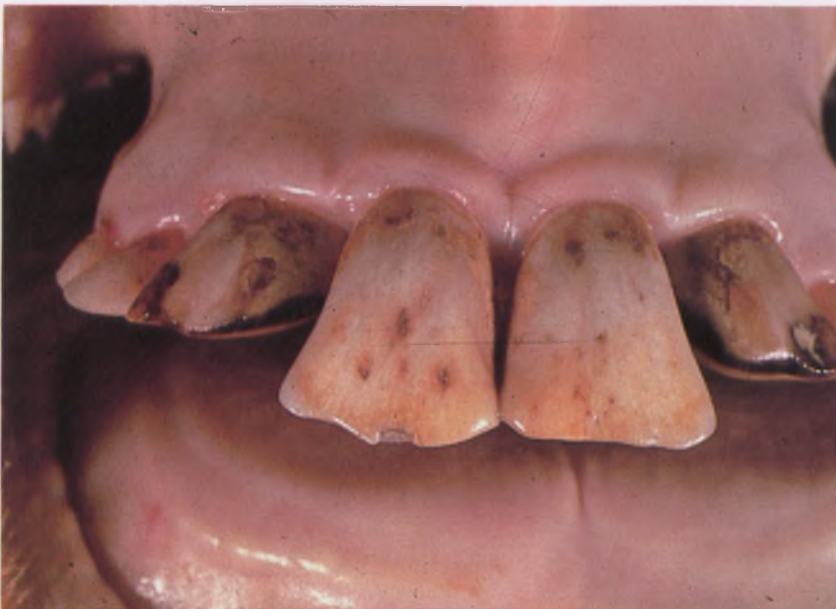

PLATE 544: ENAMEL EROSION

The improper eruption, but especially the brown stained pits, on this heifer's teeth are the result of chronic fluorosis. This was from an animal raised near an aluminum factory.

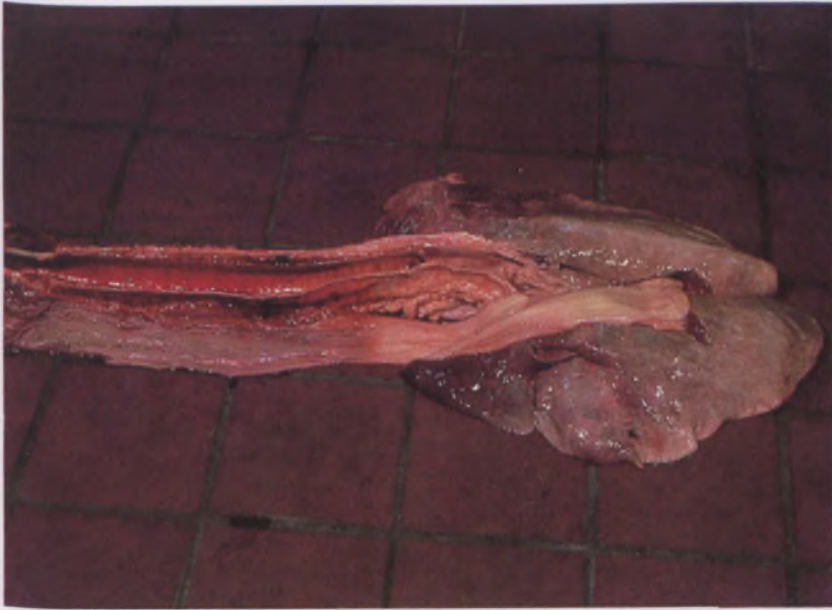

PLATE 545: BLOAT LINE

The distinct line of demarcation in the trachea and esophagus, from a pale zone into an area of severe congestion and edema cranial to the heart and lungs, is called the Bloat Line. It results in some but not all, cases of bloat in cattle or sheep, when the abdominal pressure increases sufficiently to effectively decrease blood flow back to the heart. There may be pallor and edema of the hindquarters also. One also has to consider that a suggestion of a Bloat Line may be seen in an animal that bloats rapidly after death while the blood is still fluid.

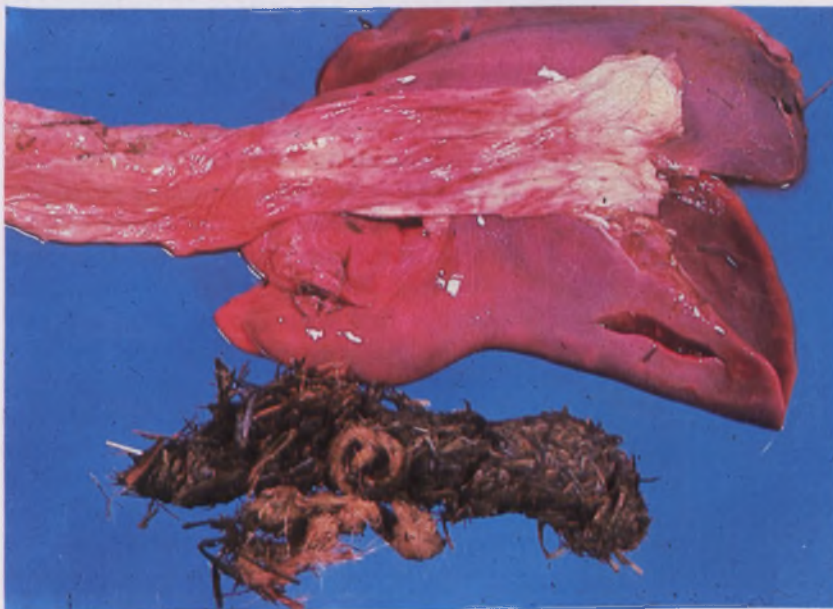

PLATE 546: ESOPHAGEAL CHOKE WITH SUFFOCATION


The partially collapsed state of the lung, and the large mass of grass ingesta mixed with the string and found in this location in the esophagus, suggest the diagnosis of choke with suffocation. The bolus of grass and string had been there long enough to have caused the erosions and ulcers seen in the esophageal mucosa. Finding a bolus of food in the esophagus of ruminants without evidence of other lesions as seen here may simply be a terminal or postmortem event.

Mouth and Esophagus

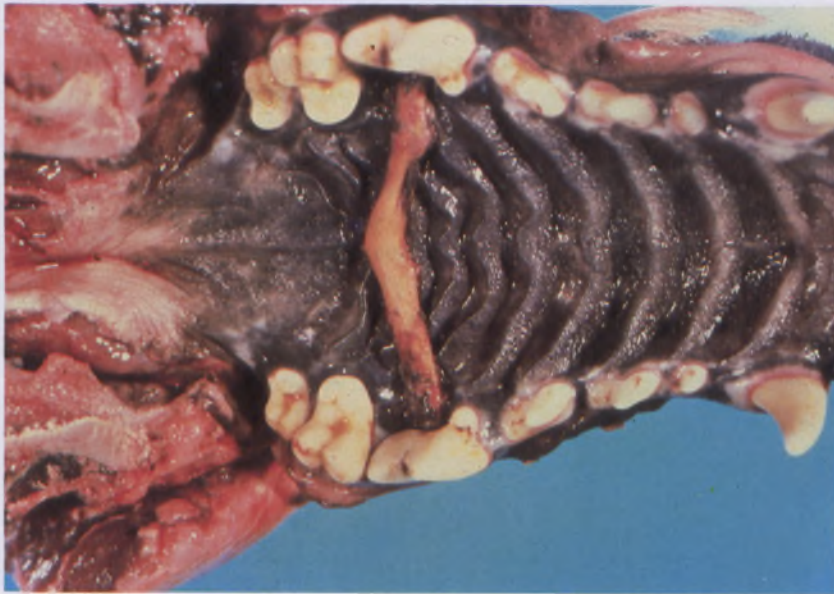

PLATE 547: ORAL FOREIGN BODY

One can just imagine the discomfort this dog had as a result of this stick foreign body that lodged between the first upper molar teeth. A granulomatous pocket had formed under both ends testifying to its prolonged presence.



**PLATE 548: TOXIC (BLISTER BEETLE)
(*EPICAUTA* SPP.)
ESOPHAGITIS**

The large number of esophageal ulcers which are partially healing are the result of the caustic action of Cantharidin, a biological product produced by blister beetles, *Epicauta* spp. This can be called a true Disease of Progress as in the older days, when alfalfa infested hay was cut; the beetles would leave the hay field while the hay dried, but now when the alfalfa is cut, because rapid drying is desired, it is crimped. As the crimping machine pinches the stems of the hay in numerous places it also mashes the beetles in to the hay itself. When this is ingested by horses, sheep, or cattle, the toxic agent, Cantharidin, can be locally damaging, as here, or it can kill by toxic damage to the renal tubules. Spanish Fly or Russian Fly also produce Cantharidin but in higher concentration.

Dr. R. Pancira, Oklahoma, USA

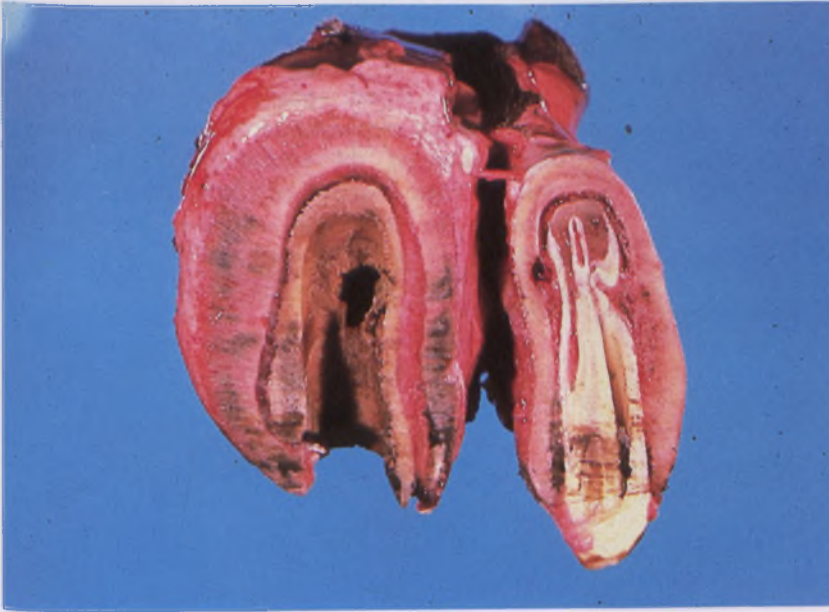

PLATE 549: BONE SEQUESTRUM AND PERIOSTEAL NEW BONE FORMATION

The jawbone of the horse has been sawed in two to show the results of a severe tooth infection. The bony socket that was around the tooth is now completely dead, a Sequestrum. Peripheral to the sequestrum is a small zone of inflammation and some new bone formation, and then the dense compact jaw bone with a marked amount of new bone proliferating away from it.

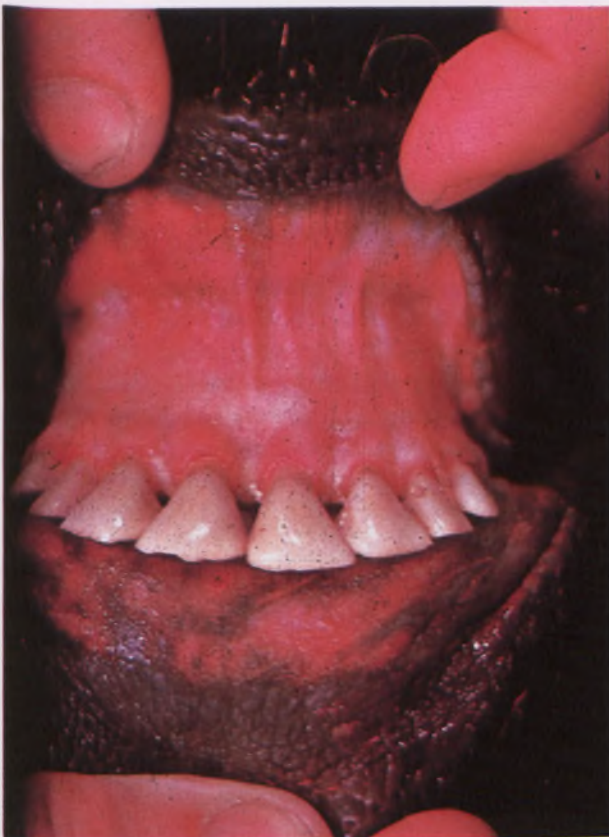

PLATE 550: MUCOSAL ULCERATIONS

The marked ulcerations of the gingiva around the teeth and gums on the lower lip of this cow are quite diagnostic for Virus Diarrhea, although a somewhat similar lesion may be seen with Bovine Malignant Catarrh and even Rinderpest. The lesions on the dental pad and upper gingiva have to be considered as possibly caused by the lower teeth and by themselves should not be given much significance.

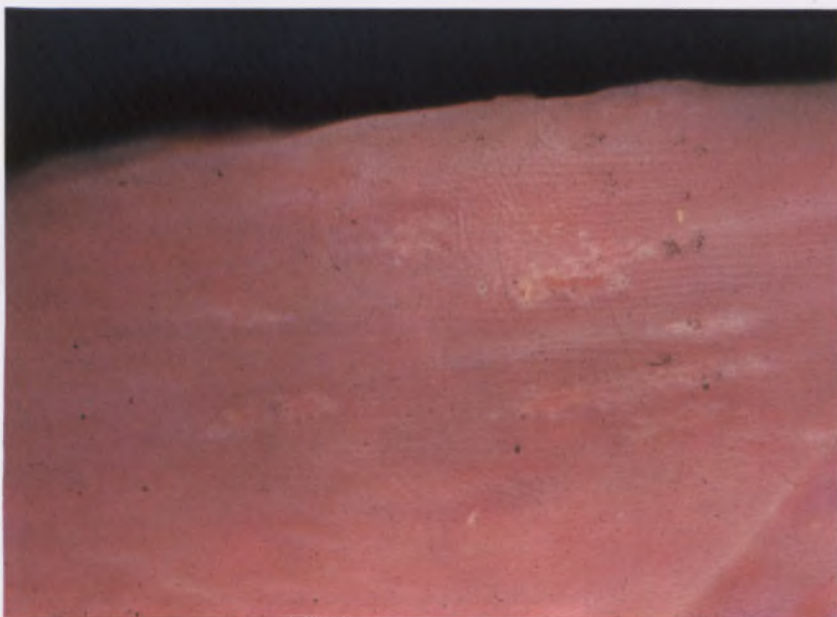


PLATE 551: VIRUS DIARRHEA OF CATTLE

The slightly, raised, opaque, white linear plaques on this cow's esophagus are the result of hydropic degeneration of the epithelium, caused by the virus of Virus Diarrhea of Cattle. This is an early lesion as the degenerate epithelium has not been scratched off by swallowed feed.

Dr. Peter Olafson, Cornell, USA



PLATE 552: ESOPHAGEAL EROSIONS

The distinct erosions of this esophagus are due to Bovine Virus Diarrhea. The basal layer of epithelium is still present, but the submucosal vessels while being more prominent, are not exposed to the surface, so these are rightfully considered erosions not ulcers. These erosions and necrosis of Peyer's patches are quite diagnostic for this disease.

Dr. F. Fox, Cornell, USA

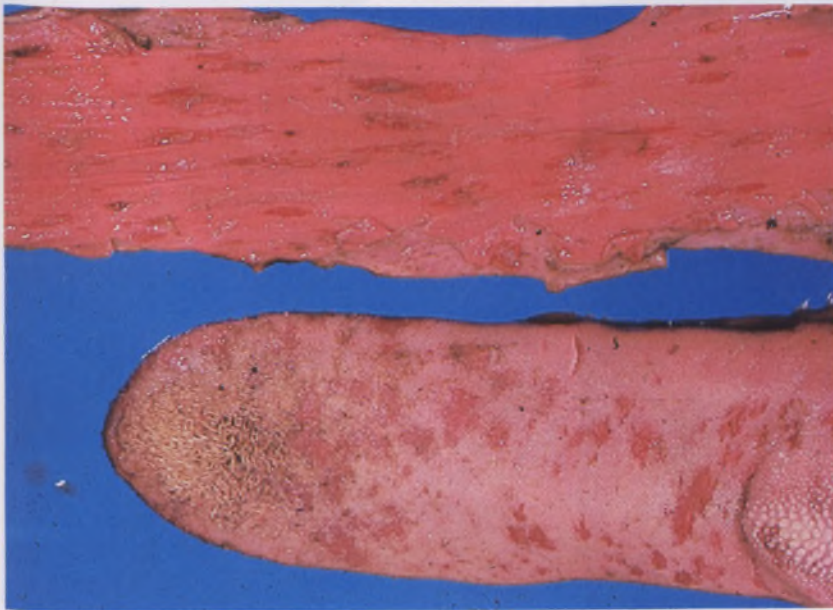

PLATE 553: BOVINE VIRUS DIARRHEA

While quite red, these lesions in the tongue and esophagus are still erosions, some with necrotic debris on them, because only the superficial epithelium has been lost allowing the blood in the submucosal vessels to be more prominent. This is a case of Bovine Virus Diarrhea.

Dr. R. Pancher, Oklahoma, USA

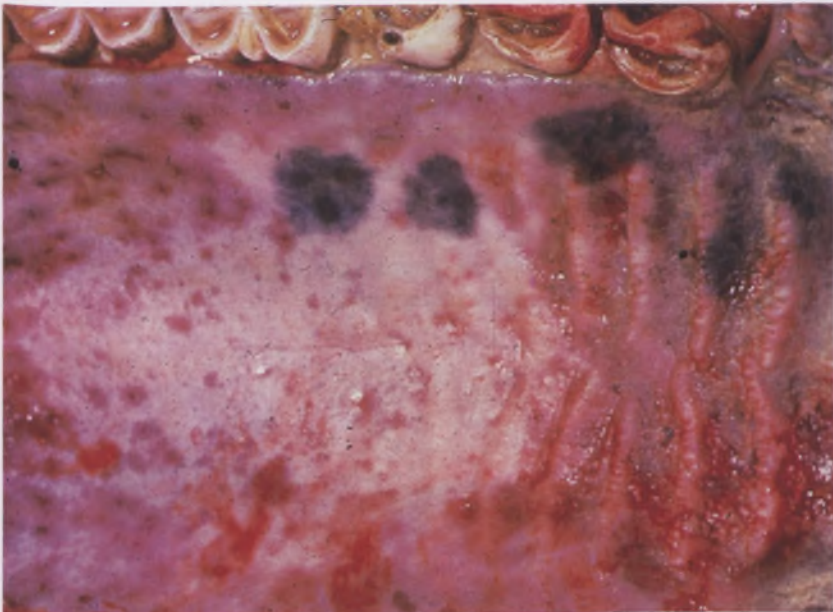

PLATE 554: ORAL ULCERATIONS

The hemorrhages and ulcerations on the hard palate of this cow are caused by Bovine Malignant Catarrh (BMC) (Malignant Catarrhal Fever) but out of context one would also be forced to consider them lesions of a severe case of Bovine Virus Diarrhea (BVD). High fever, central nervous signs and conjunctivitis would all help point to this being a case of BMC.

Dr. L. Roth, Oklahoma, USA

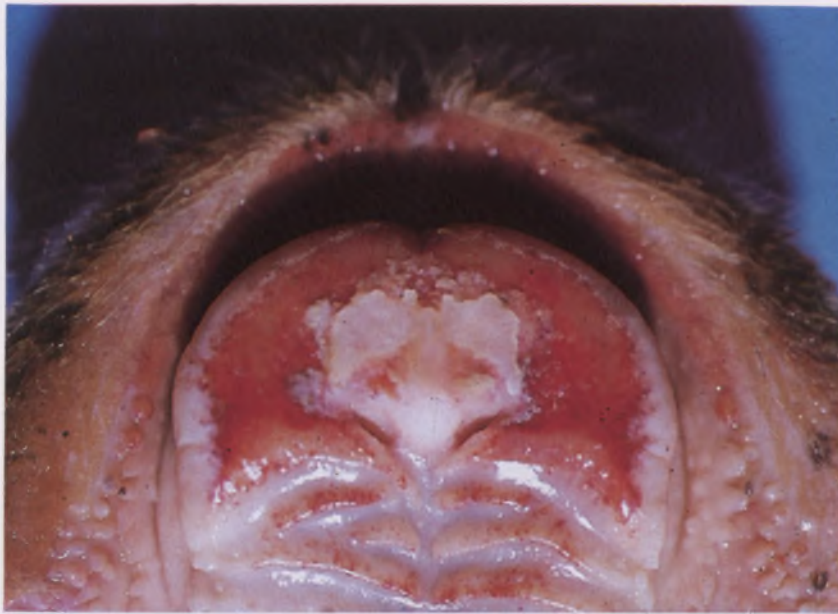

PLATE 555: DENTAL PAD ULCERATION

The upper dental pad, palate and gums of this sheep show the severe ulceration associated with Bluetongue, a viral disease. Hemorrhages in muscles and in large vessels walls especially near the heart are quite diagnostic.

Dr. R. Panciera, Oklahoma, USA

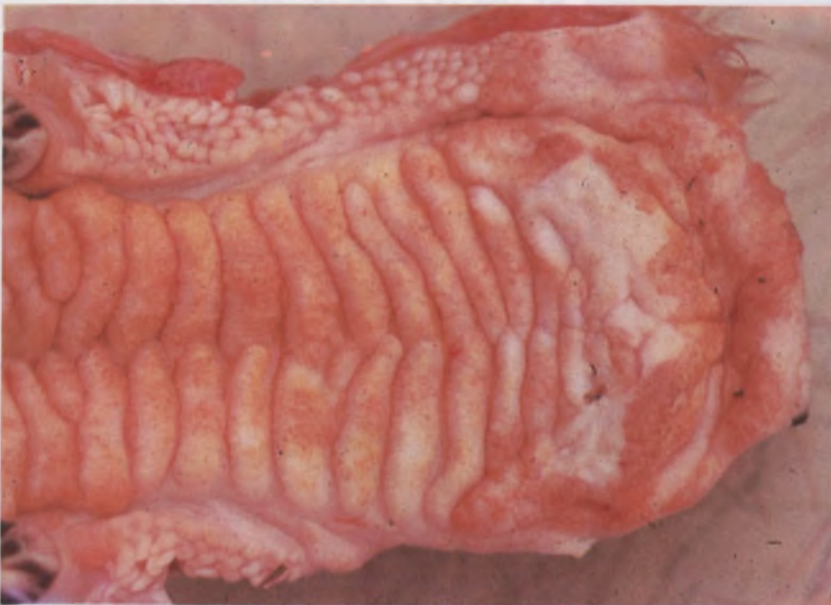
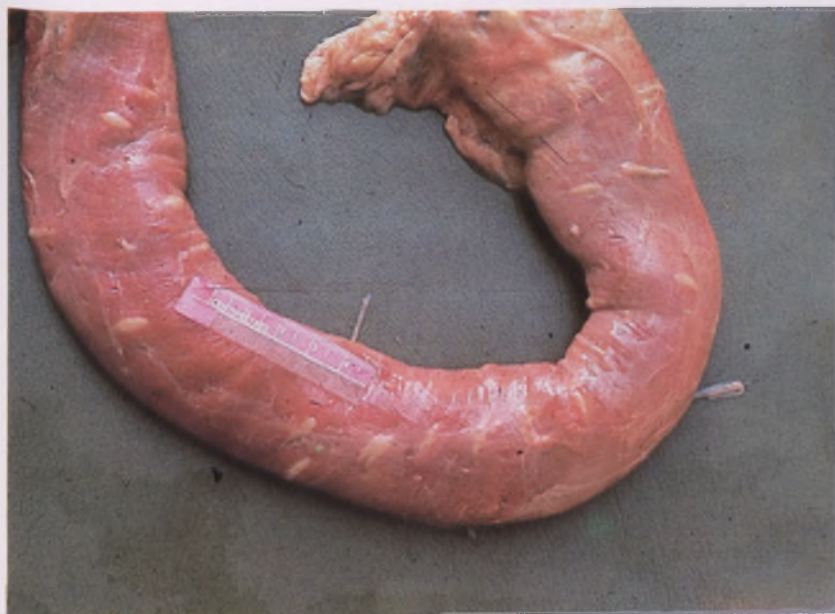
PLATE 556: PAPPULAR STOMATITIS

The entire upper lip, dental pad and most of the rugae of the hard palate are markedly thickened themselves or with raised granular plaques. These are lesions of the viral disease, Papular Stomatitis. It is quite common in calves. It may get secondarily infected with *Fusobacterium necrophorum* to affect the animal's eating, but usually it is not clinically important.

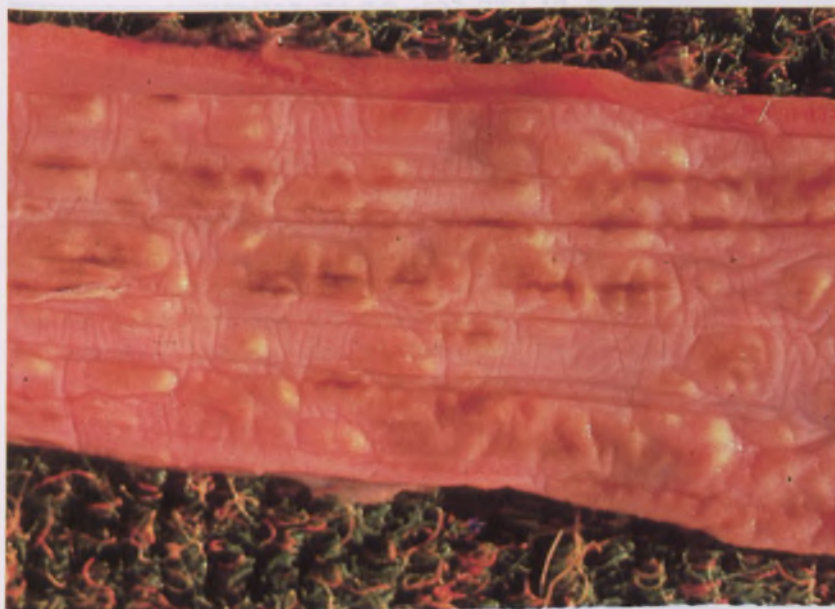
Dr. F. Fox, Cornell, USA



**PLATE 557: SARCOSPORIDIOSIS
(SARCOCYSTIS SPP.)**

The large, pale white elongated, spots, running parallel to the muscle fibers of this cow's esophagus are intracellular parasites, *Sarcocystis* spp., in the muscle fibers proper. Large ones like this in sheep may be *Babbania gigantia*.

Dr. W. Wooding, New Jersey USA



**PLATE 558: ESOPHAGEAL
CANDIDIASIS**

The plaque like lesions on the esophageal mucosa in this foal are the result of prolonged use of antibiotics which allowed these organisms to grow. *Candida* spp. are the most likely organisms to cause such a lesion but some bacteria can also mimic this lesion by their surface growth. This can be seen in most animals especially young ones when anorectic.

Dr. L. Roth, Oklahoma, USA

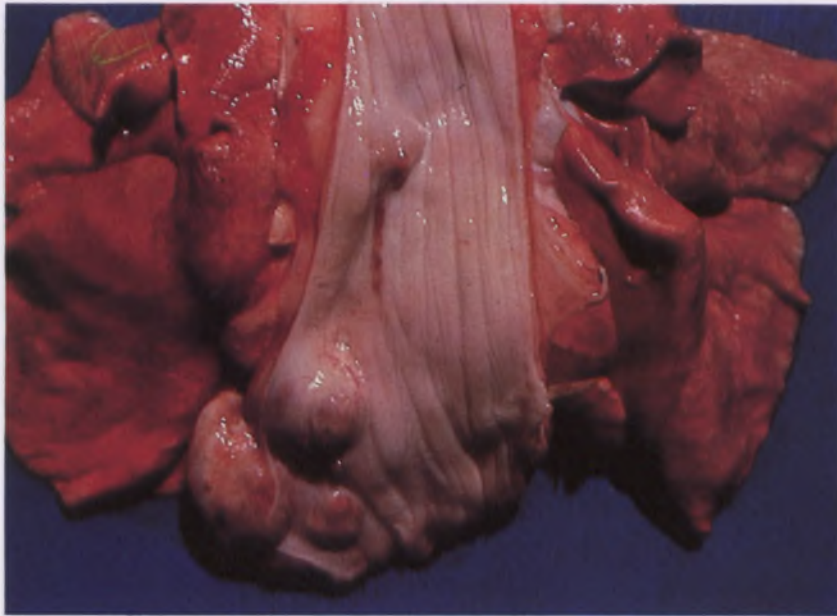


PLATE 559: SPIROCERCA LUPI BROOD NODULES

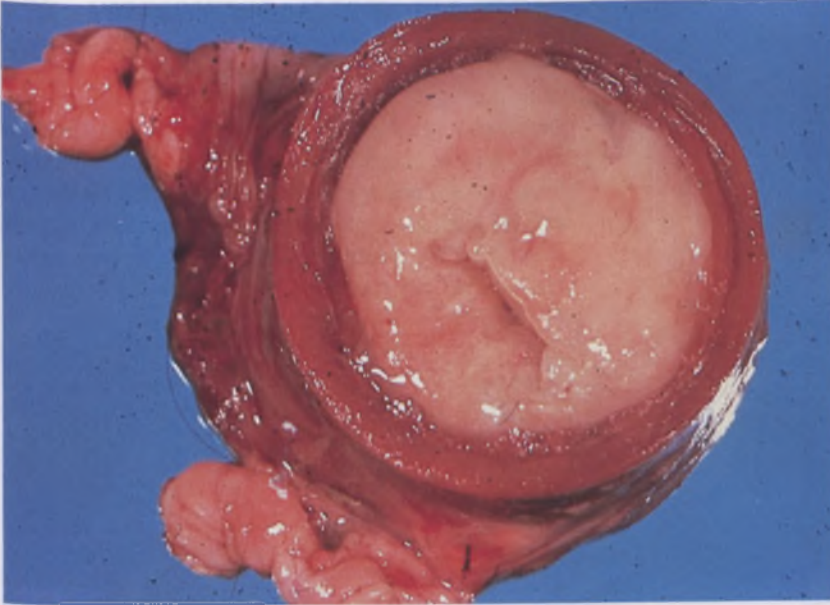
The multiple nodules in the distal end of this dog esophagus are brood nodules of *Spirocerca Lupi*, the esophageal worm of dogs and similar carnivores. The adults have migrated out of the aorta in this region to the periesophageal tissues. The female will form a fistula, as in several of these, from the brood nodule to the esophagus in order to shed eggs into the dog's esophagus. Often these nodules are the seat of neoplastic transformation to osteogenic sarcomas, fibrosarcomas and even carcinomas.

Dr. G. Appel, Kenya

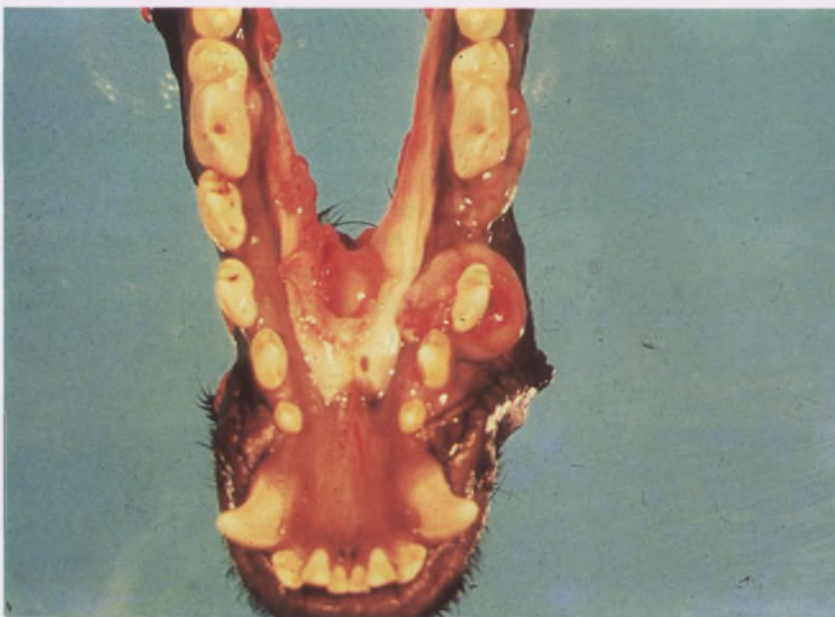

PLATE 560: ORAL LYMPHOSARCOMA

All the premolars are present on one side of this dog's jaw but the fourth premolar is missing from one side. The third premolar has a mass growing around this entire premolar with smaller growths between P_1 and P_2 and along side of M_1 . A small similar mass is present on the buccal side of M_1 on the opposite side. These at first might be considered Gingival Hyperplasia but those usually are more pedunculated and very firm. These are soft and histologically are classical examples of Lymphosarcoma.



D. C. Hall, Cornell, USA

PLATE 561: ESOPHAGEAL SUBMUCOSAL LYMPHOSARCOMA

The two muscle coats of this bull's esophagus can be easily distinguished as can the slit like cavity, the lumen of the esophagus, in the middle of the pale fleshy mass. This is a classic case of Esophageal Submucosal Lymphosarcoma.

Dr. J. Rott, Cornell, USA

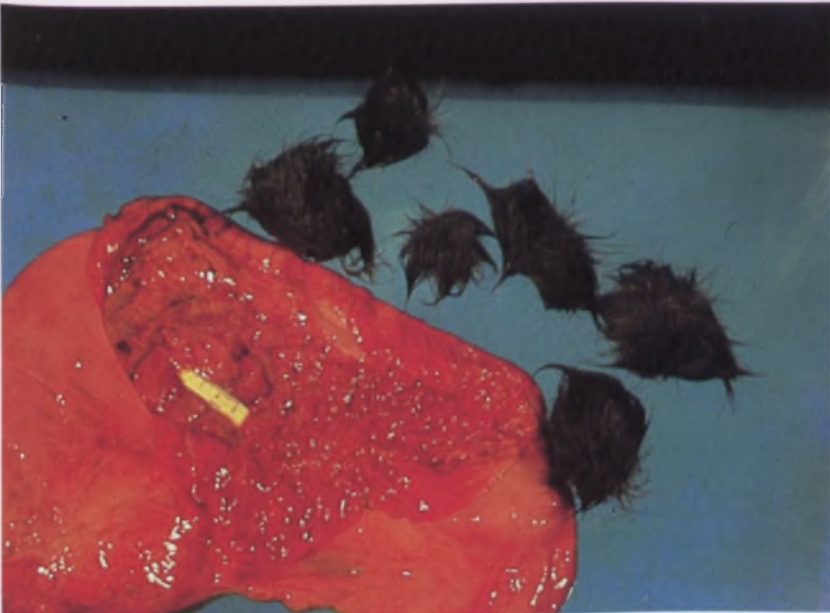
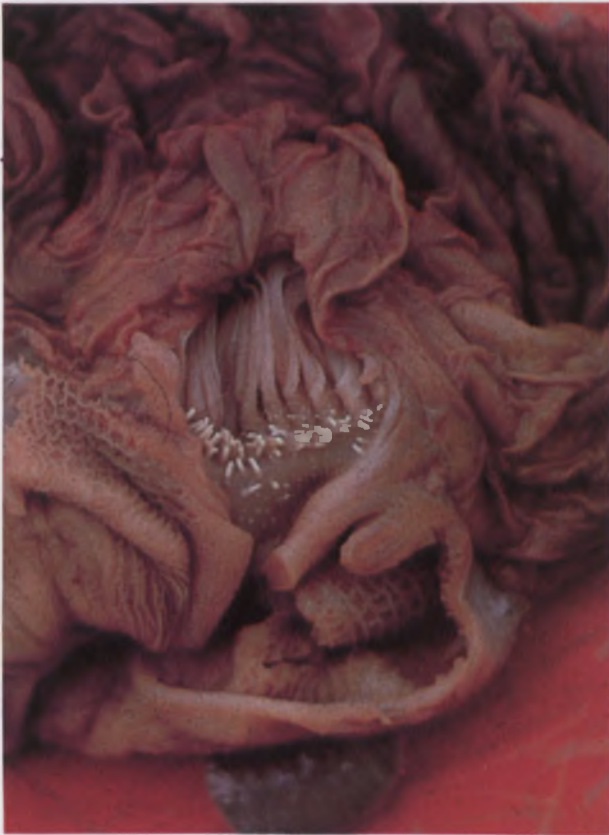
PLATE 562: TRICHOBEZOARS (HAIR BALLS)

The six masses of hair are called Hair Balls, Trichobezoars or even Trichoconcretions, although they are not hard. They were found in the abomasum of this aborted calf, which incidentally demonstrates that these animals *in utero* do swallow amniotic fluid and its content. Postnatally, they are common in calves that lick themselves or other calves as the result of pica, boredom, lice or some other skin irritation.



Dr. L. Roth, Cornell, USA

PLATE 563: NORMAL UNGUICULATE PAPILLAE

The multiple white papillae at the end of the esophageal groove and the entrance to the omasum are normal Unguiculate Papillae of ruminants. They often enlarge with age and darken as the animal eats more pigmented food. In older animals they may be several centimeters long and sometimes larger. Most break off with time.

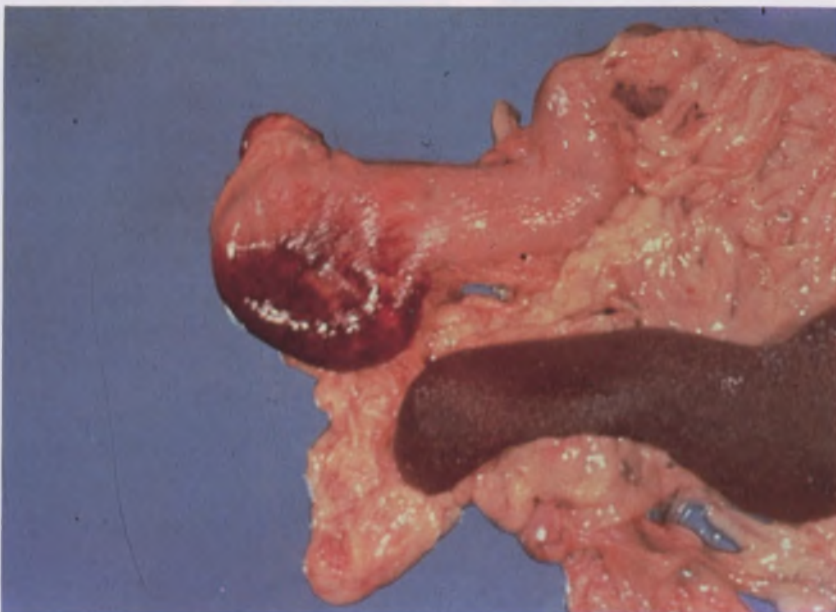

PLATE 564: GASTRIC EVERSION INTO THE ESOPHAGUS

This dog's stomach shows well marked serosal and muscular congestion and hemorrhage in one area of the greater curvature. This is the result of Gastric Eversion into the distal esophagus. Most of these cases are associated with vomiting. These can occur terminally, but they will not have a vascular reaction of significance along with it.

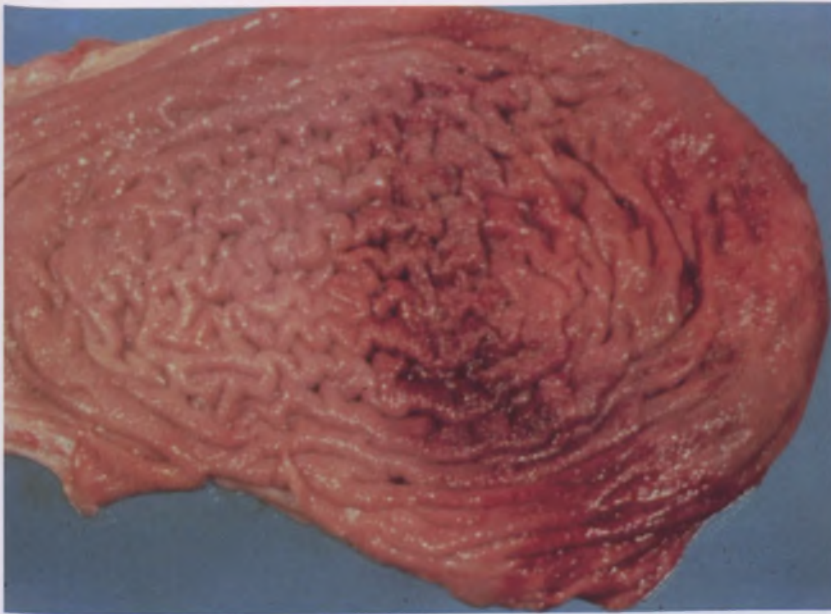


PLATE 565: GASTRIC EVERSION INTO THE ESOPHAGUS

This dog's stomach has been opened to show the marked congestion of the mucosa in the fundic region. This is a case of Gastric Eversion into the esophagus as a result of vomiting. This is a fairly common lesion in dogs which may be overlooked easily, because of the way the stomach is often first pulled out of the abdominal cavity and then cut off at the esophagus. This can be seen in Canine Parvovirus Disease as well as other cases of Vomition. One of our last cases was in a dog with an electrolyte upset as a result of liver atrophy.

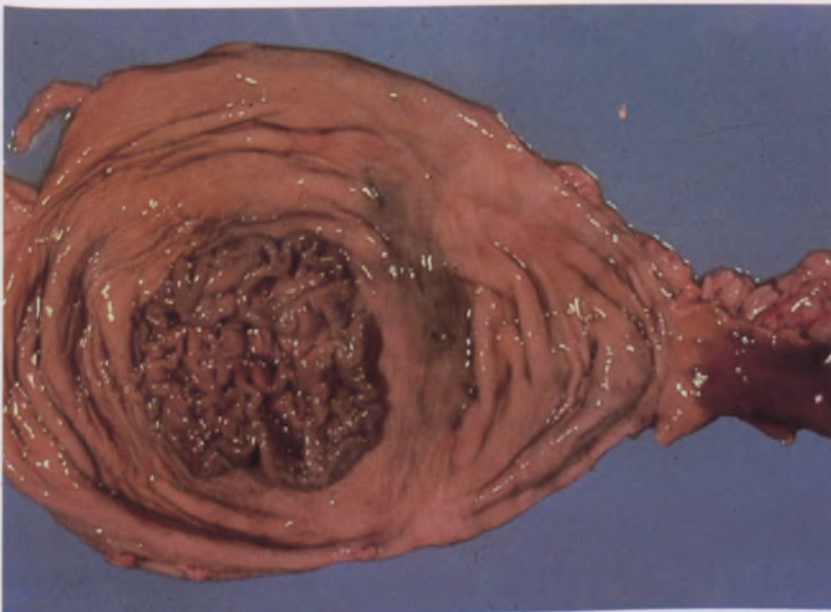
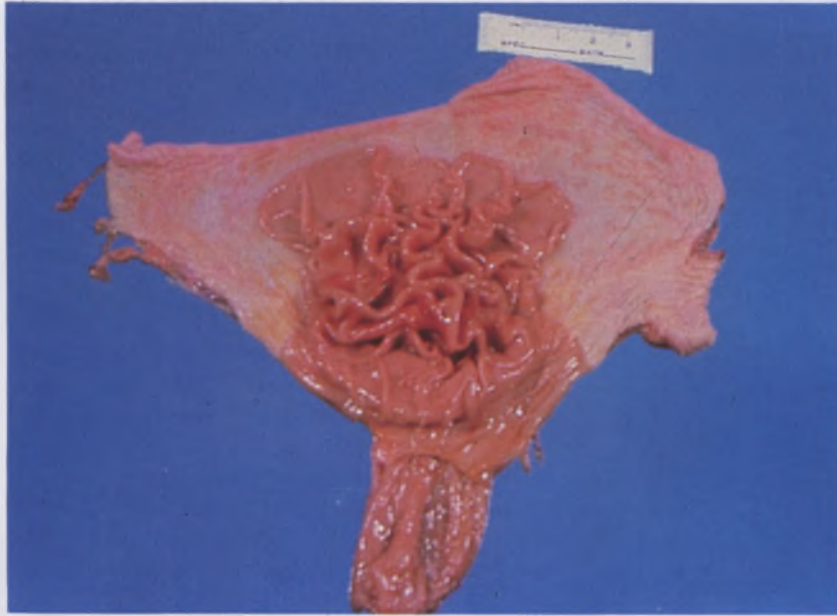

PLATE 566: GASTRIC HYPERPLASIA AND RUGAL HYPERTROPHY

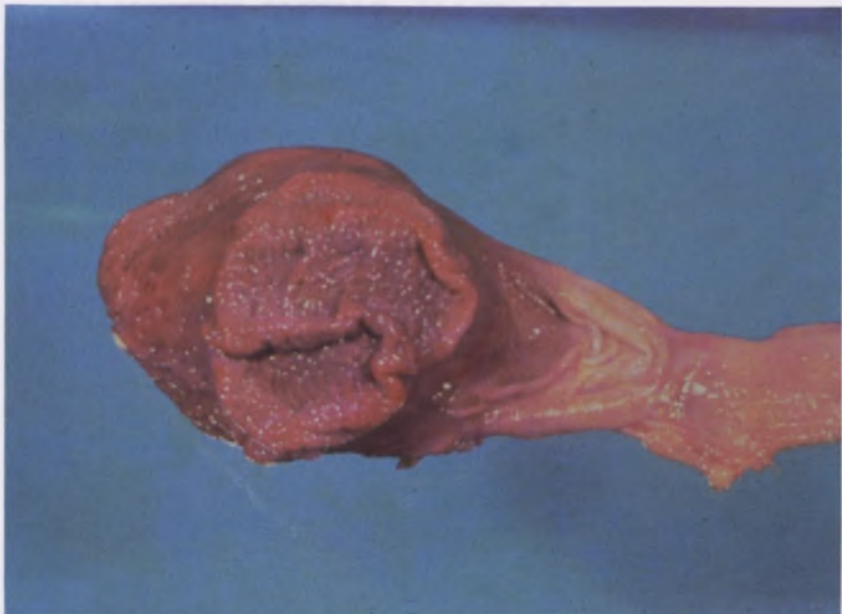The single, round, discrete patch of gastric mucosa in a dog's stomach, thrown up into distinct folds, is a relatively new disease called Gastric Hyperplasia and Rugal Hypertrophy. Both processes are at work here to make the lesion. It is quite common in dogs and also has been seen by the authors in pigs, foals, skunks and woodchucks.



**PLATE 567: PSEUDOHYPERTROPHY
OF THE RUGAL FOLDS**

The central area of this foal's gastric mucosa is thrown up into large folds of Rugal Hypertrophy. It probably should be called a Pseudohypertrophy of the Gastric Rugae, as these can be straightened out fairly completely by stretching the stomach wall. The cause is not known.

Dr. L. Roth, Cornell, USA



**PLATE 568: GASTRIC RUGAL
HYPERPLASIA AND
HYPERTROPHY**

The central portion of this dog's stomach is thrown up into large thickened folds, and the mucosa itself is thickened. This is a case of Rugal Hyperplasia and Hypertrophy. The cause of this problem in animals is unknown but vomiting is often involved, either as a cause or a result. It is advised here that some cases that look somewhat like this may be just Pseudohypertrophy, as they can be stretched back to normal manually. This has been seen in several species including the dog, horse and skunk.

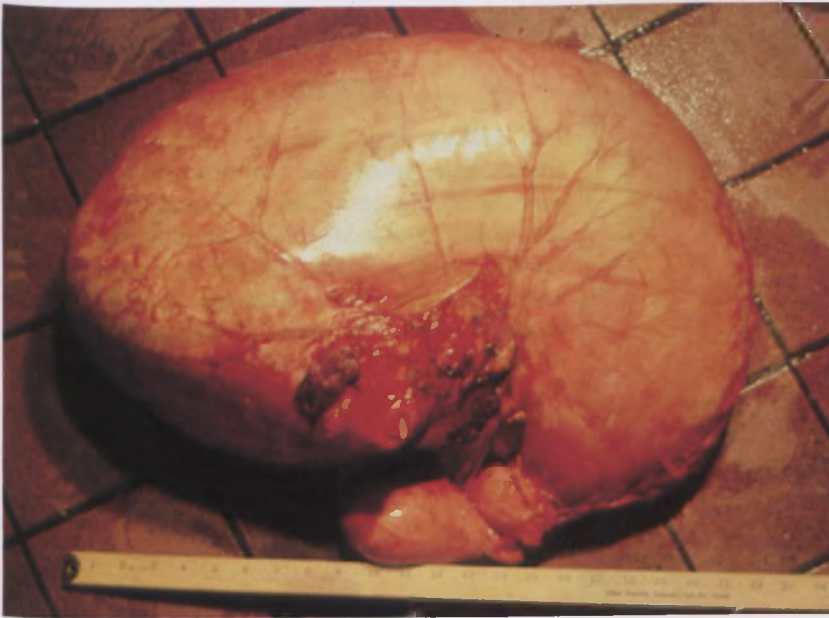


PLATE 569: NORMAL STOMACH

This markedly firm, filled stomach is normal in a horse. Many times the stomach can be this distended with ingesta and still be normal.

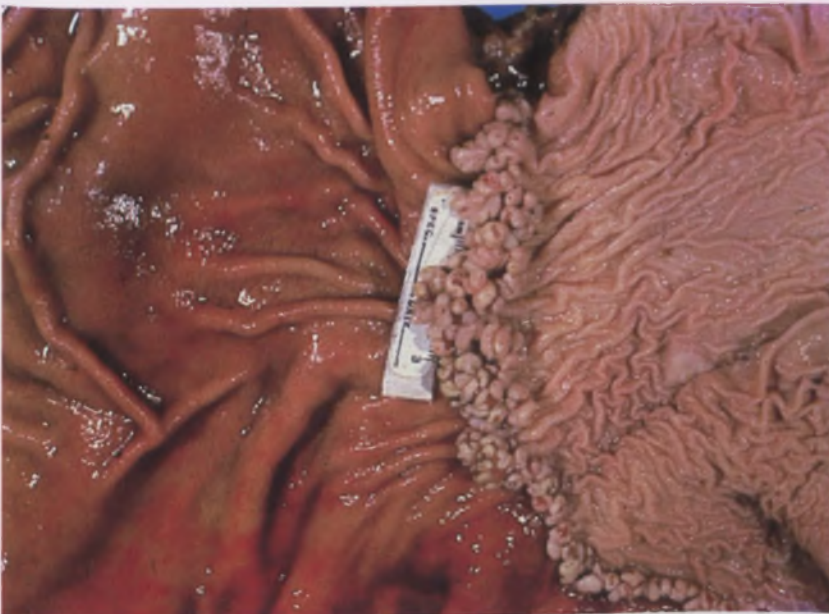
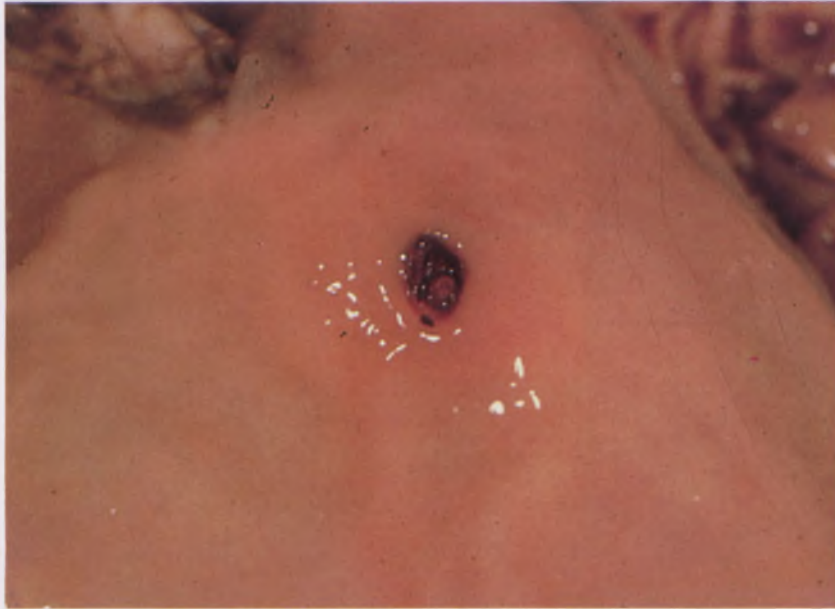
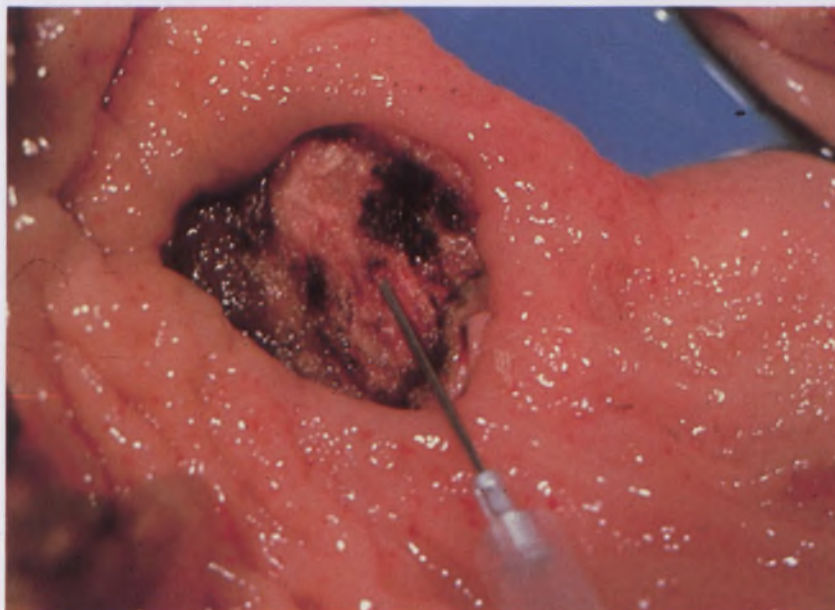
PLATE 570: EPITHELIAL PAPILLARY PROLIFERATION

The cause of multiple Stratified Epithelial Papillary Proliferations along the margo plicatus of this horse's stomach is unknown. It can be seen in many horses.



**PLATE 571: ARTERIAL ASSOCIATED
ULCERATION WITH
EXSANGUINATION**

This solitary deep Ulcer has a major artery in its approximate center in the mucosa of a cow's abomasum. The cow died by Exsanguination from this vessel. Nonspecific ulcers are quite common in the abomasum of cattle, but this type appears more unique because of its centering around a major vessel as though the vessel played a major role in its pathogenesis. Several of these have been found in cattle and no explanation can be given.



**PLATE 572: ABOMASAL ULCERATION
WITH VASCULAR EROSION
AND EXSANGUINATION**

The crater lesion in this cow's abomasum is an Ulcer. The cause is not known for most cases. Also seen in this one is the needle point actually in the lumen of a moderately large artery in the submucosa. The erosion of this vessel in association with the ulcer was the cause of the animal's death by Exsanguination. It is interesting to speculate that many of these solitary erosive ulcers have a major vessel directly in their centers, because the vessel played an etiological role in the pathogenesis of the ulcer itself; otherwise the vessels should be more toward the edges of these ulcers.

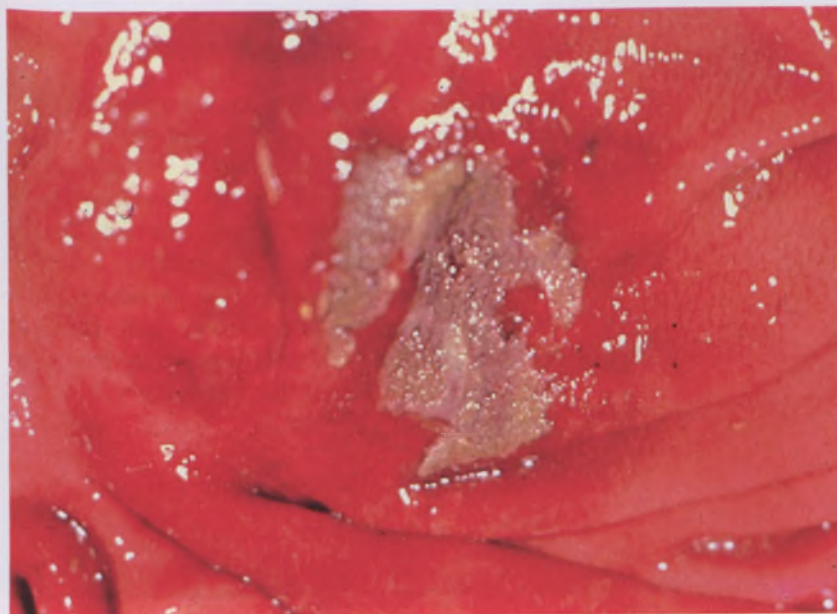


PLATE 573: ACUTE FOCAL ABOMASITIS

The reddened, surrounding area of the yellow grey necrotic superficial epithelium is the initial lesion of Acute Focal Gastritis (Abomasitis) in this cow. It is suggested that this possibly could go on to become a typical and common Abomasal Ulcer. The actual cause of most of these is not known, but physiological factors are probably paramount.

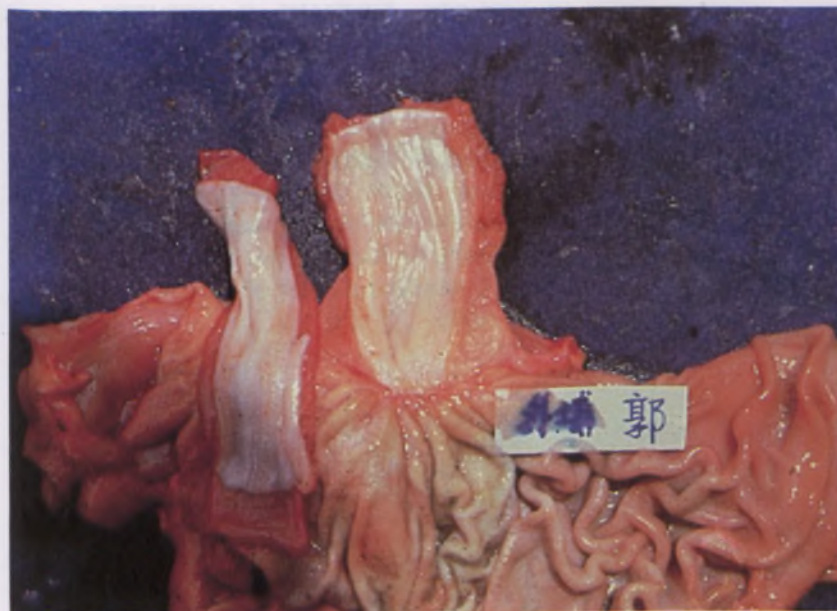


PLATE 574: CHRONIC GASTRIC ULCERATION WITH ABLATION OF THE ESOPHAGEAL REGION OF THE STOMACH

This pig's esophagus is seen as it connects to the glandular stomach at a slightly wrinkled and constricted line. This would almost be normal for a dog, but it is absolutely abnormal in a pig, as there is no esophageal region of the stomach left. The area has been completely lost due to gastric ulceration and the two remaining epithelial surfaces have joined. The precipitating causes of Gastric Ulcers in pigs are many, but the underlying one is genetic as the disease can be stopped in a herd by Drastic Slaughter of all relatives in the breeding herd.

Dr. R. Chu, Taiwan, ROC

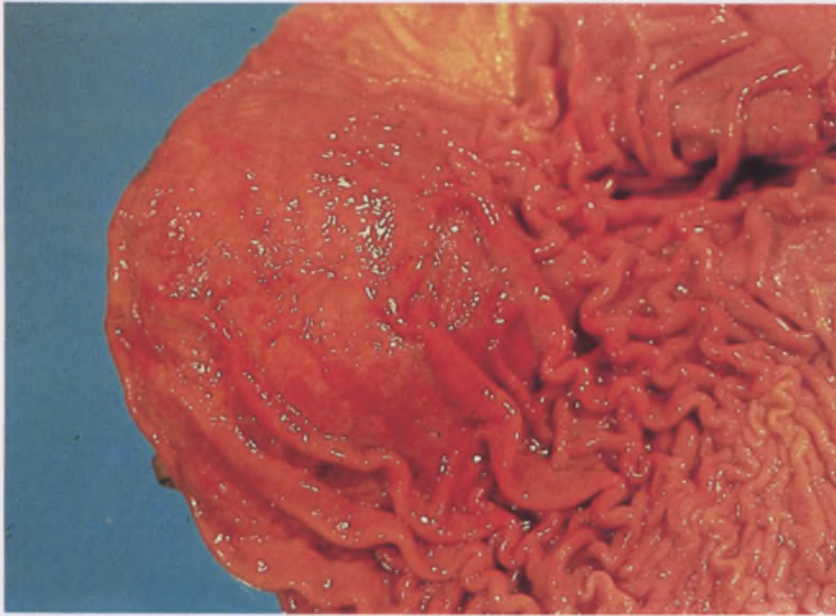


PLATE 575: UREMIC MINERALIZATION

The congested area of this dog's stomach has pale areas just recognizable in the mucosa, which would be firm and gritty if the stomach was allowed to cool. This is an area of Uremic Mineralization as the result of chronic renal disease. The term Uremic Gastritis is often used for this condition as blood in the lumen is a common feature so much so that blood in the vomitus is commonly seen. It is not due to a gastritis, but rather is probably related to small mineralized vessels that tear easily with gastric distention.

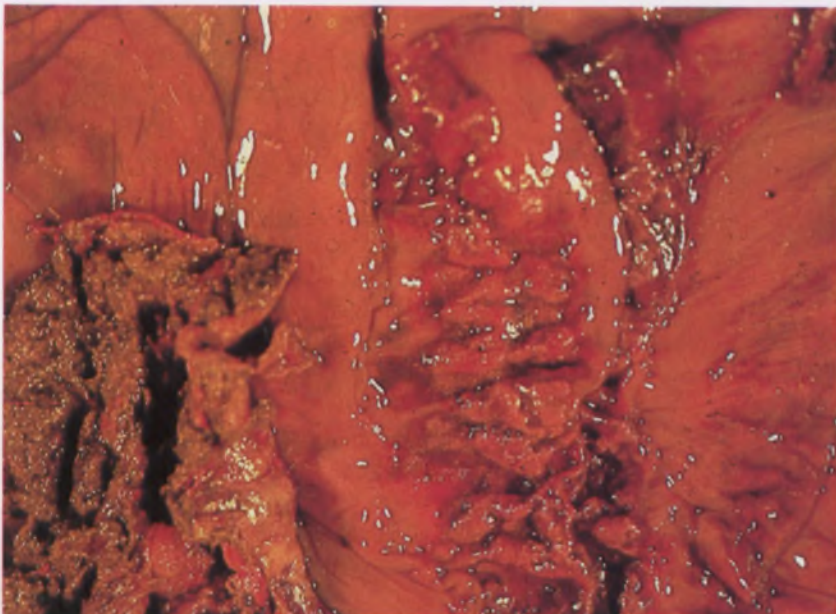
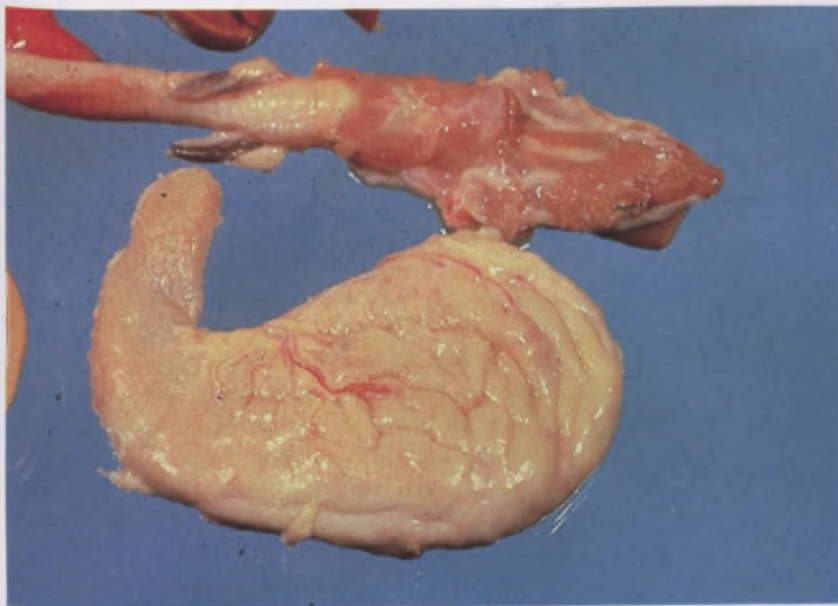


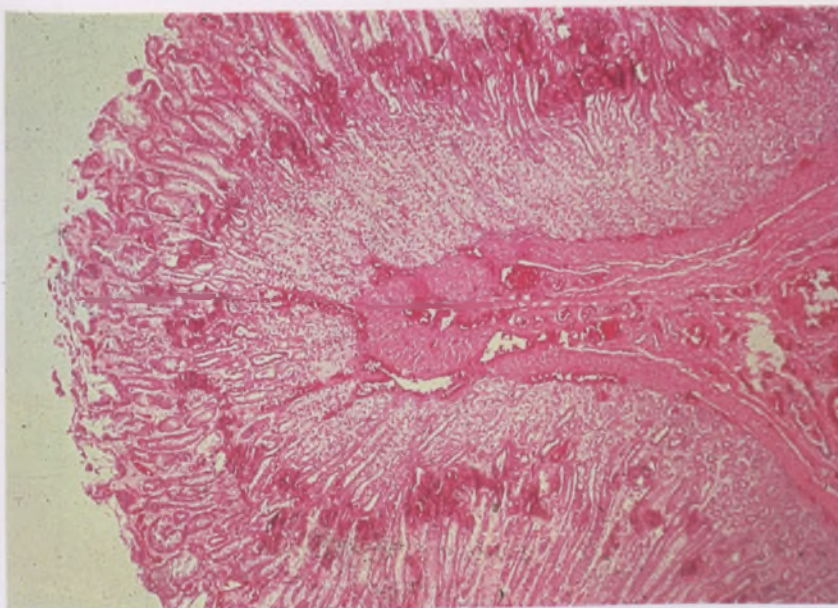
PLATE 576: UREMIC GASTRITIS

The dark necrotic patches of debris in this cow's abomasum are relatively rare lesions, as underlying these scattered necrotic areas are large relatively discrete areas of mineralization in the mucosa and submucosa. This is an example of Uremic Gastritis in a cow. The cow died of renal failure from Renal Amyloidosis. In dogs and cats it is common to have Uremic Gastritis as a result of renal failure, but it is rare in cattle.



**PLATE 577: GASTRIC
MINERALIZATION AND
PARATHYROID
HYPERPLASIA**

The pale stomach shown here is from a cat and closer observation of it will show a distinct pale white deposition of material in its parietal wall leaving the greater curvature and pyloric areas relatively free of the material. This is Uremic Mineralization of almost the entire stomach and is the result of renal failure. The pyloric portion of the stomach points, so to speak, to the normal thyroid and massively enlarged parathyroid glands. This enlargement of the parathyroid glands is Parathyroid Hyperplasia as a result of the renal failure. The animal's bones, in time, can become extremely soft due to Fibrous Osteodystrophy. Pleural mineralization called Uremic Frosting is a constant feature. The whole process is often called Renal Secondary Hyperparathyroidism.



**PLATE 578: MIDEPIHELIAL ZONE
MINERALIZATION**

The dark purple masses in the mid-epithelial zone of this dog's stomach are patches of Uremic Mineralization associated with renal failure, for whatever reason. In some cases of uremia, the vessels and even the smooth muscles of the lamina propria, submucosa and the gastric muscle coat itself may be mineralized.

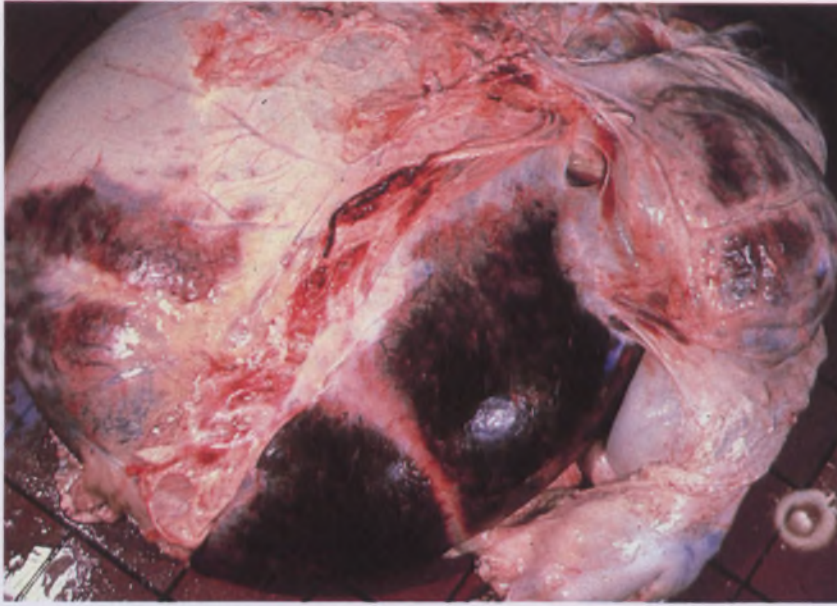


PLATE 579: TOXIC RUMENITIS AND OMASITIS (OVEREATING DISEASE)

The serosal surface of the rumen and omasum and even a small bit of the abomasum show a marked Hemorrhagic Peritonitis. This is the external view of these organs affected with Toxic Rumenitis, one of the four major forms of overeating disease. Lactic Acid Indigestion does not have significant lesions except a lowered rumen pH and a high blood lactate. *Clostridium perfringens* type D has extra fluid and fibrin in the heart sac with ecchymoses scattered in the serosa of the bowel and abdominal wall. *Clostridium perfringens* type C is usually in calves associated with massive hemorrhages scattered in the serosa of the bowel.

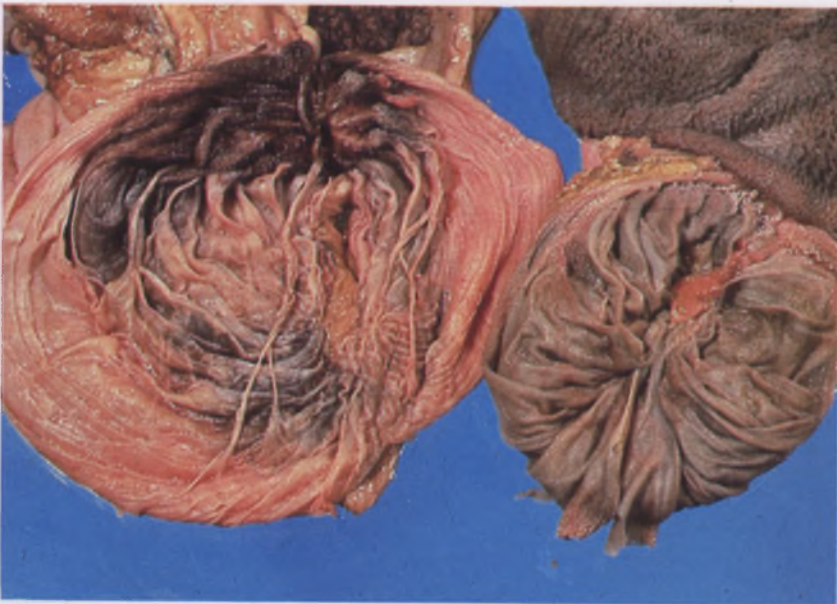
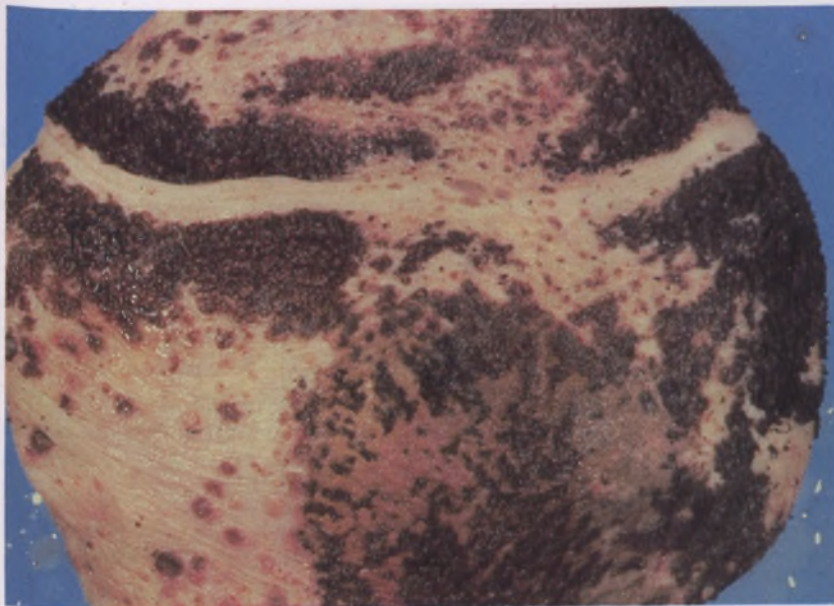


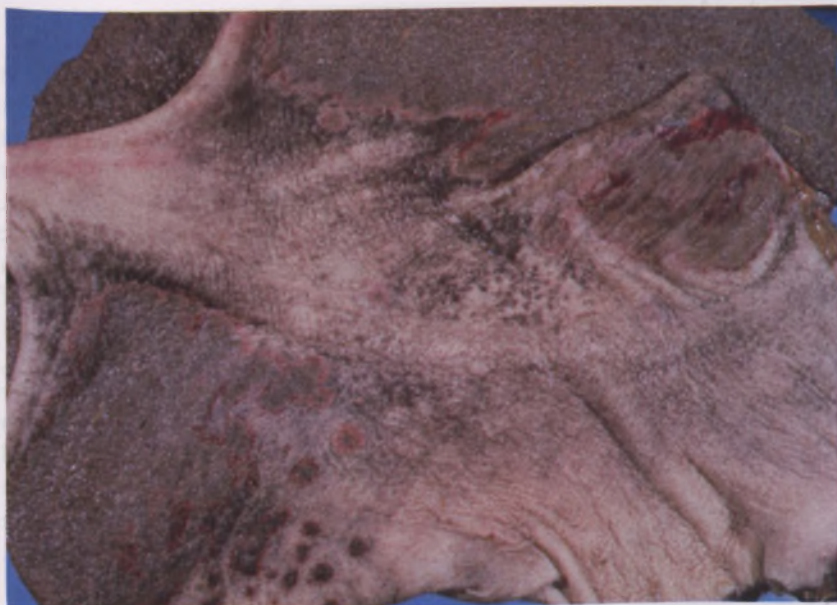PLATE 580: TOXIC OR CAUSTIC ABOMASITIS

A normal cow's omasum is lying open, beside a cow's omasum that has had most of its folds destroyed by a caustic agent, leaving the free edges of many folds as a thin band of tissue. This may have resulted from a case of Toxic Omasitis, a Reflux of Gastric Juice or a Caustic Chemical. As the lesion was limited to this area it probably rules out Toxic Indigestion as that usually involves the rumen or the abomasum as well. This is a chronic lesion as no evidence for acute inflammation is present.



**PLATE 581: TOXIC RUMENITIS WITH
SECONDARY MYCOTIC
RUMENITIS**

On both sides of the one stripe of rumen pillar in this picture are patches of dark rumen mucosa, and large areas devoid of normal mucosa. In these denuded areas are scattered red and dark foci of focal inflammation caused by a secondary mold infection. One large area has both dark rumen mucosa and a pink area of recently necrotic mucosa. This is a case of Chronic Toxic Rumenitis, which has sloughed most of the rumen mucosa, with Secondary Mycotic Rumenitis scattered in both the sloughed and non sloughed mucosal surfaces. This animal overate on grain or other concentrate, to cause the acute necrosis of the wall which subsequently became secondarily infected with mold. We have heard of cases of suspected primary mycotic rumenitis but all our cases of this severity and extent have been secondary to Toxic Rumenitis. Several different molds can be isolated from such cases.



**PLATE 582: TOXIC (METABOLIC)
RUMENITIS**

An inflammatory line of demarcation between the ventral sacs of the rumen, and the various portions of the rumen pillars demonstrate well the mucosal lesion of Toxic Rumenitis. Several target shaped lesions of Secondary Mycotic Infection are also present near the junctional areas. Most cases of Toxic Rumenitis are associated with the ruminant suddenly overeating on grain. Bread dough, corn or any concentrate can cause this and even the same quantity of concentrate normally fed to the animals, if given in a more easily digested form such as ground wheat versus whole wheat, will cause the problem.



PLATE 583: CHRONIC TOXIC INDIGESTION WITH HEALING ULCERATION

The large, dark area of the pink colored abomasal mucosa, and the large raw lesion in the omasal mucosa around which many of the omasal folds have been completely lost, are Ulcers with only minimal healing at their edges. The piece of honey-combed reticulum and small segment of rumen present, both have white patches of scar tissue almost completely healing former ulcerated areas in these organs. These Ulcers are all the result of Toxic Indigestion. The cattle, or actually the microorganisms in their forestomachs, were given finely ground, easily metabolizable grain instead of the normal grain they were accustomed to receiving. This usually is the result of a sudden single change of feed to which the organisms cannot adapt rapidly.

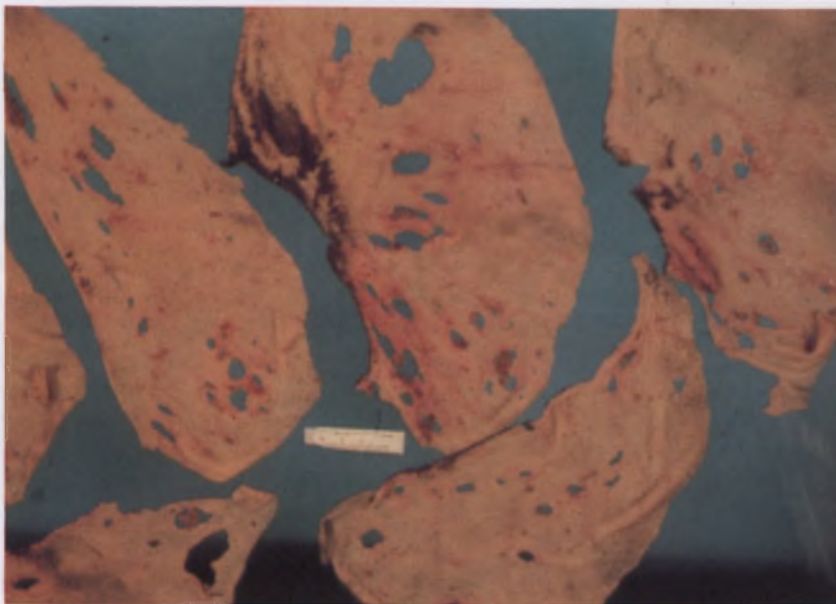
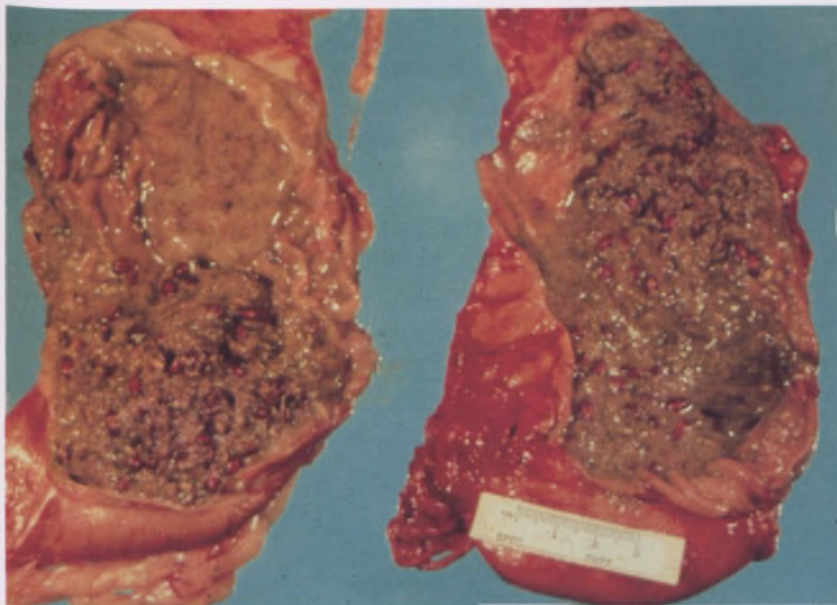
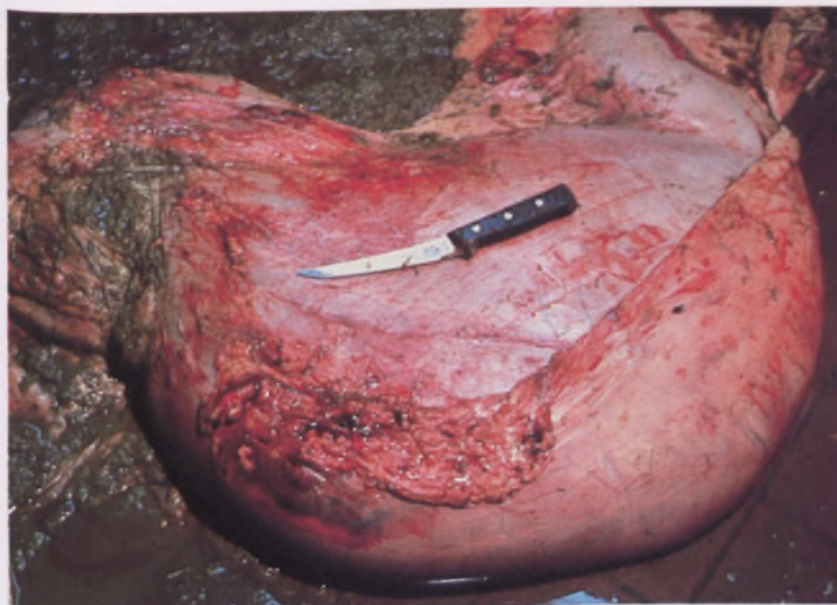


PLATE 584: CAUSTIC ULCERATION

These pieces of tissue are several of the many folds of the omasum of a cow. They show many holes in them with well healed edges and several holes with necrotic tissue debris still attached at their edges and bridging some of the holes incompletely. These are considered to be the result of Caustic Ulceration. The cause can be Toxic Omasitis from Overeating Disease or, more likely, the result of Gastric Fluid Reflux. At one time it was thought that Bovine Virus Diarrhea was the main cause, but the age of this lesion and absence of other lesions and signs rules this out. Mycotic infection has also been considered, as molds can be found in these but there is usually no predisposing cause found, many of the lesions are healed and the active lesion does not look like most mycotic lesions do.

**PLATE 585: STRYCHNINE POISONING**

The two dogs whose stomachs are shown here died rather suddenly with tetanic convulsions. No specific lesions were found in any tissue or organ grossly or microscopically. On opening the stomachs, however, these dark red stained wheat kernels were found. The stomach content was washed to isolate these red kernels which were then soaked in a small amount of warm fluid. The supernatant was injected into mice which after a few minutes went into tetanic convulsions at almost any harsh noise. The dogs had been poisoned with Strychnine treated wheat seed added to raw meat balls.

**PLATE 586: ABOMASAL IMPACTION**

While a horse's stomach may be full of dry ingesta and still be normal it is almost always a lesion in the cow when the true stomach, the abomasum, is grossly distended with dry feed. The cause of many of these cases of Abomasal Impaction is not always found. Most cases are associated with a lesion, physical or functional, that interferes with outflow from the abomasum. This case followed surgical correction for a Displaced Abomasum with probable damage to the nerves involved. Enough cases of this are seen with abscesses and pneumonia near the vagus nerves to suggest it may commonly be a localized neurogenic problem. While the abomasum is almost never distended and firm, the omasum in a cow is almost always large and firm with very dry content in its normal state. We have only seen it extraordinarily large in conjunction with an Impacted Abomasum.

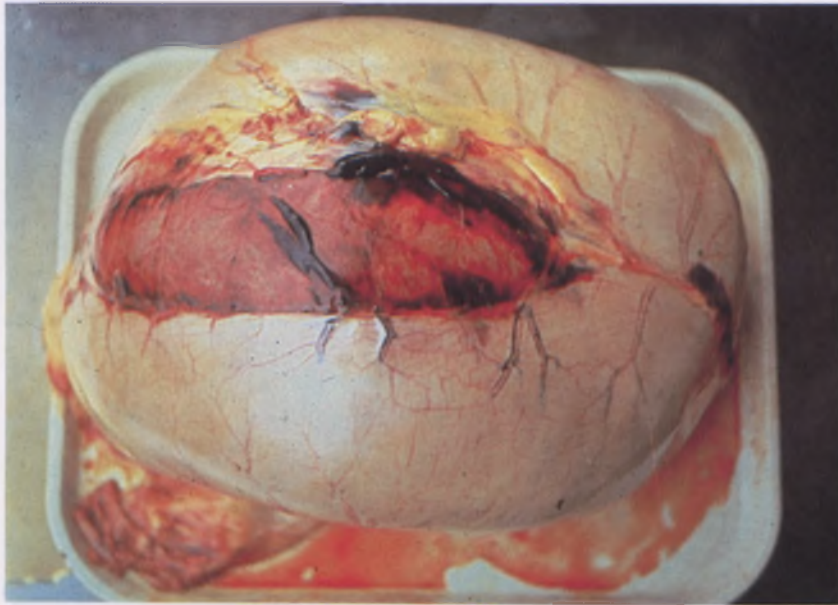


PLATE 587: GASTRIC RUPTURE

The great distensibility of the gastrointestinal tract's submucosa is shown here in a horse's stomach in a case of Gastric Rupture. The muscle coat has ruptured, as evidenced by the hemorrhage associated with the tear, but the submucosa is still intact. In almost all cases of Gastric Rupture in a horse, there is usually an underlying intestinal obstruction farther down the gastrointestinal tract. Most of the stomachs will be dilated with wet ingesta and gas.

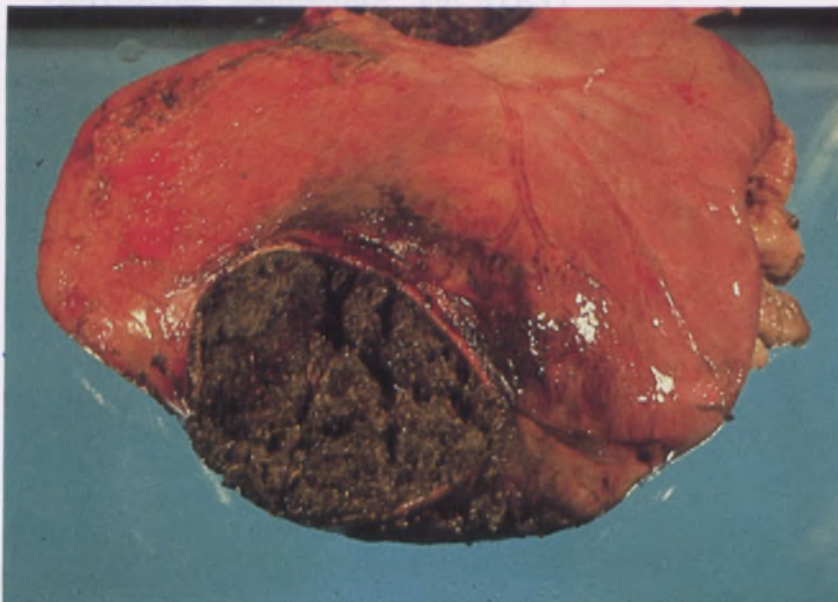
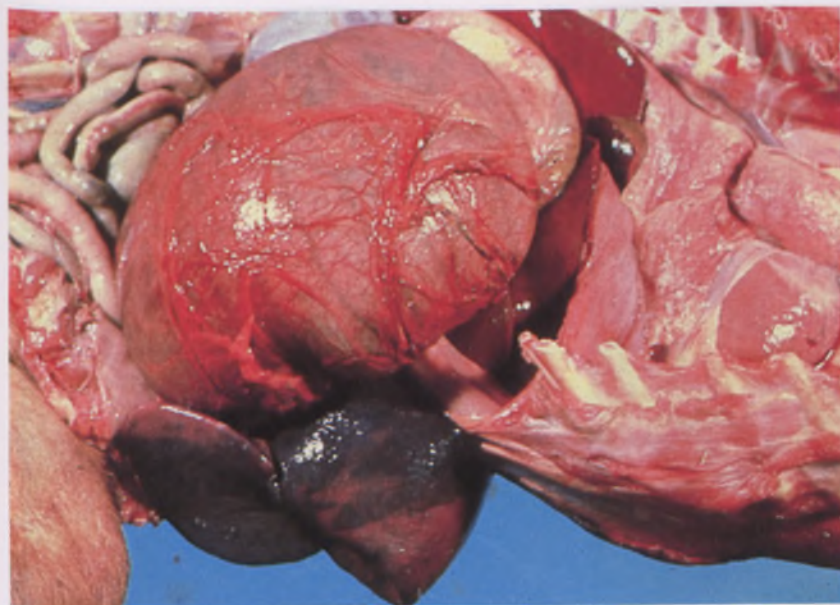

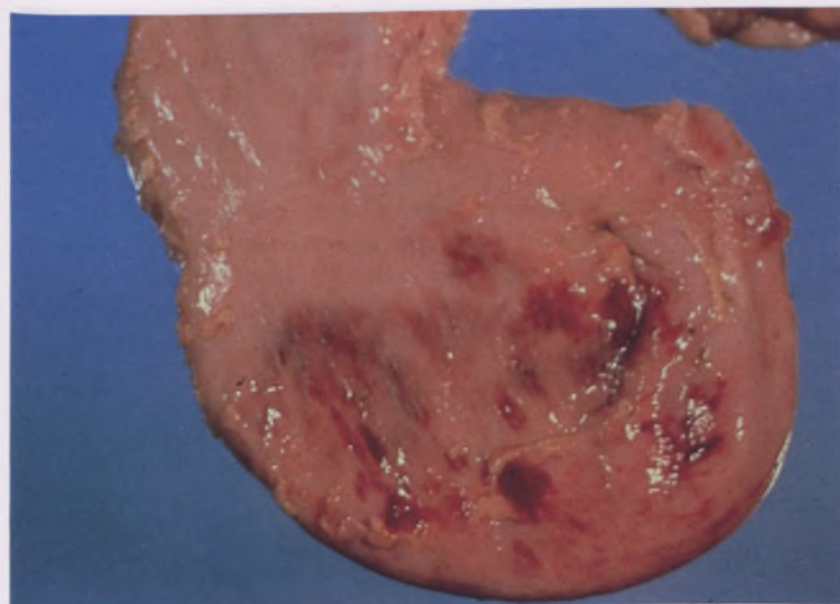
PLATE 588: ACUTE GASTRIC RUPTURE

This large distended stomach in a horse has ruptured along its greater curvature where hemorrhage and edema is seen around the rupture. This is an Acute Gastric Rupture. Of note are the apparent rounded edges of the tear line which is sometimes thought to be evidence of chronicity because the edges are rounded and smooth as though by an attempt of healing. This is not so of the stomach and intestines, particularly, as their mucosa is so loose and abundant that it commonly bulges out and over an exposed edge to give a smooth rounded appearance to the opening. If on the other hand, the mucosa is positively adherent to the very edge of the opening, and it is slightly rounded, then it probably is an attempt at healing and is a more chronic lesion.



**PLATE 589: GASTRIC TORSION AND
EVERSION**

This picture shows an approximately 360 degree twist of a dog's stomach with a markedly congested spleen. The stomach covered by a portion of the omentum. Although not able to be shown in this picture, this is a relatively newly recognized problem of gastric inversion onto the omental sling. No hole is present in the mesentery or omentum and the epiploic foramen is not involved. Only careful dissection in a fresh case will demonstrate this difficult to describe condition.



**PLATE 590: GASTRIC EVERSION INTO
THE ESOPHAGUS**

The marked hemorrhages in the wall of the major part of this dog's fundus is the result of having been everted into the esophagus. This case of Gastric Eversion into the esophagus was secondary to prolonged vomiting associated with an atrophic liver.

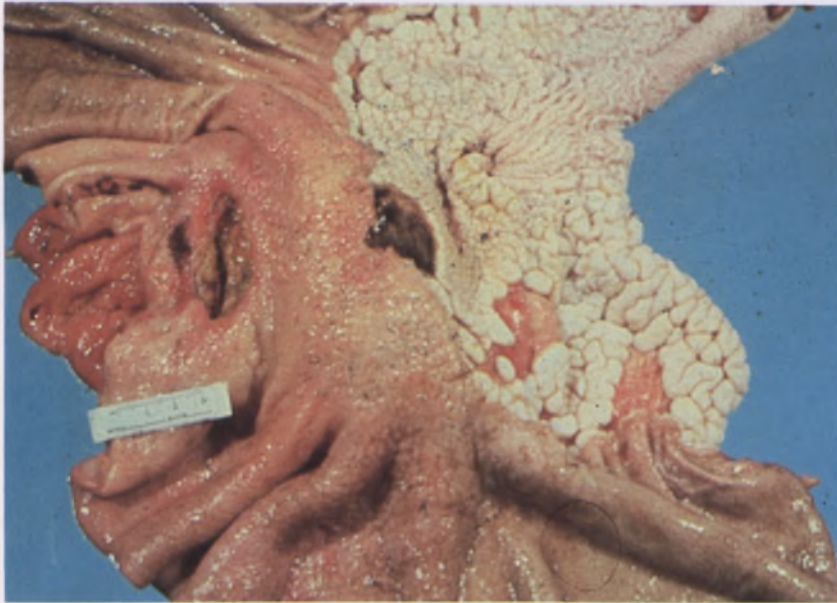

PLATE 591: GASTRIC ULCERS

Two pink based ulcers are present in the stratified epithelial area of this horse's stomach, along with a dark hemorrhagic based ulcer. These are quite common in horses and there is no known cause. Some consider them associated with bots. There are also several deep ulcers in the glandular epithelium of this stomach which are not as common. These latter type are usually associated with the heavy or prolonged usage of the nonsteroidal antiinflammatory type drugs as they were in this case.

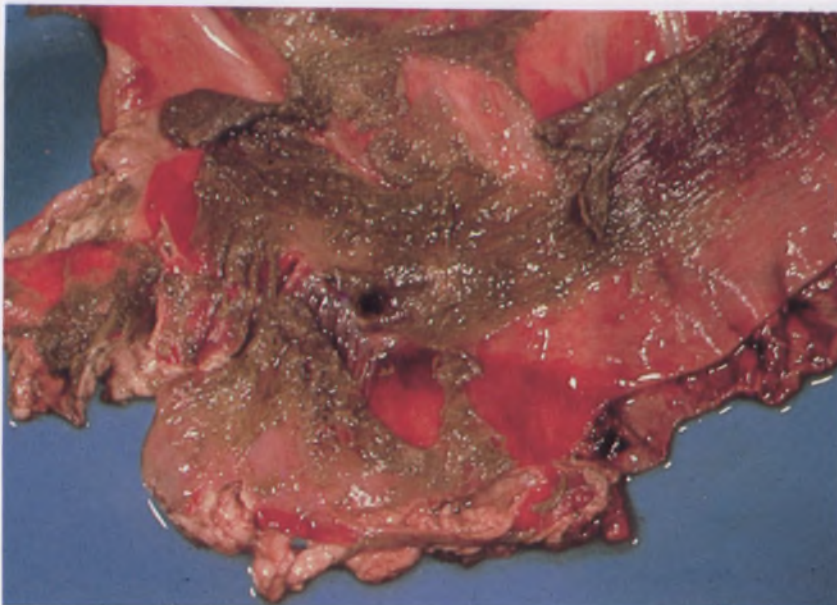
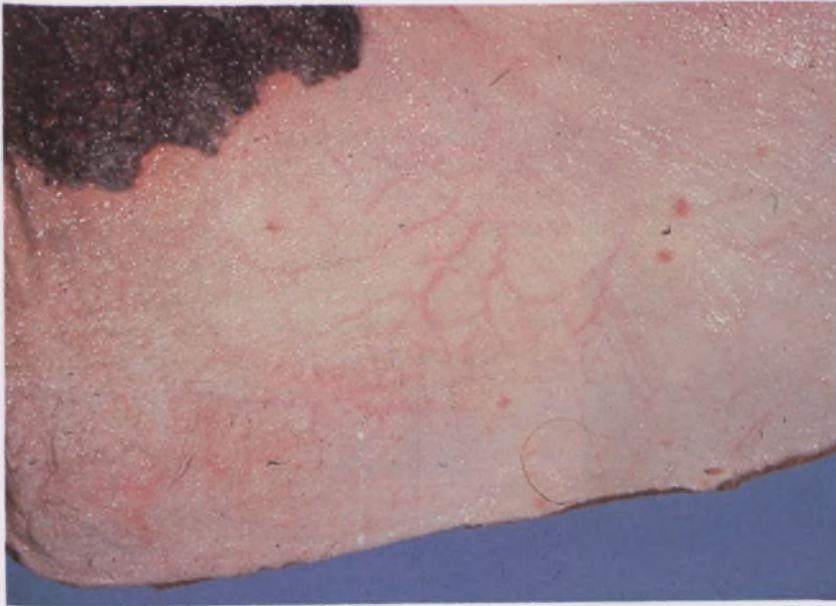


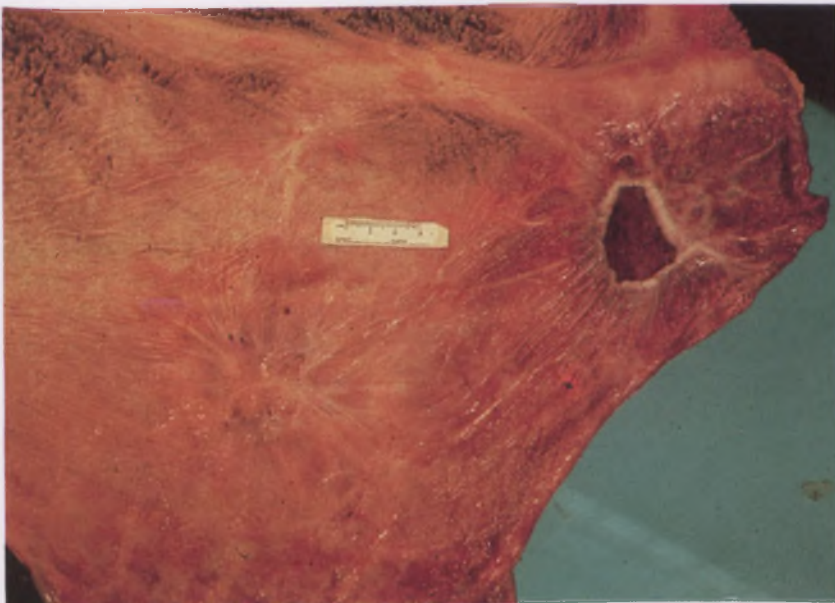
PLATE 592: ACUTE PERITONITIS AND GASTRIC ULCER PERFORATION

The small round hole in the lateral wall of this cow's abomasum is the result of a Perforated Abomasal Ulcer. The serosal surface shows some ingesta, fibrin sheets and severe inflammation as a result. The cause of most of these ulcers are not known. One other known cause is associated with Mycotic Ulceration but they only rarely perforate.



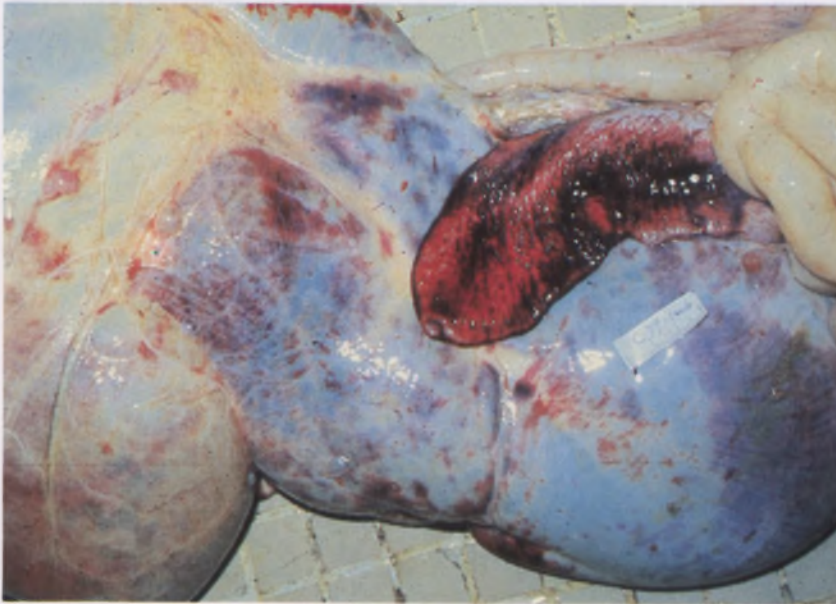**PLATE 593: MULTIFOCAL BACTERIAL
(*HEMOPHILUS SOMNUS*)
RUMENITIS**

The mucosa has sloughed off most of this rumen wall as a result of autolysis. It actually can start sloughing in about twenty minutes after death in normal animals. On the submucosa, several rounded pink papules can be seen which are focal areas of infection associated with *Hemophilus somnus* (agni), the causative agent for Thromboembolic Meningoencephalitis (TEME). Lesions like this may also be found in the urinary bladder wall and a major lesion is sometimes found in the laryngeal area. The primary lesion of TEME is the meningoencephalitis of the brain and cord.



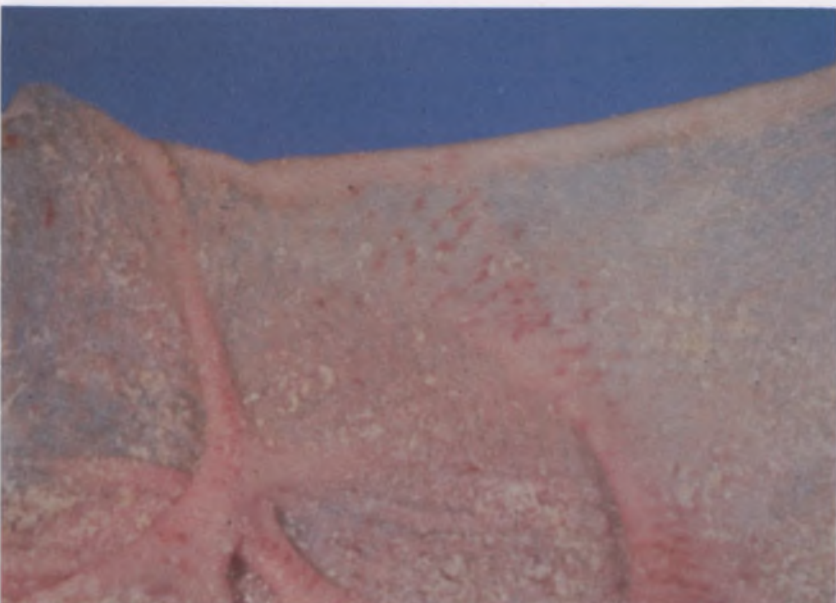**PLATE 594: HEALING RUMEN
ULCERATION WITH
CICATRICIAL STAR**

The rumen pillar near one edge has a few areas of mucosal surface on both sides of it with almost normal rumen villi. The rest of the rumen is devoid of villi as a result of Toxic Indigestion. One oval crater of Active Ulceration with a rim of thick connective tissue (scar) is present, but most of the area shows the classical Cicatricial Stars of healing. Most of this area probably has a very thin layer of squamous epithelium covering it so it cannot be considered an ulcer any longer, except for the one cratered area.



**PLATE 595: ENTEROTOXEMIA
CLOSTRIDIUM
PERFRINGENS TYPE C**

The massive hemorrhage of the abomasal and forestomach walls and splenic capsule of this calf are quite helpful in making a diagnosis of Enterotoxemia, *Clostridium perfringens* type C. This is one of the four types of Overeating Disease seen in ruminants. Lactic Acid Indigestion, Toxic Rumenitis and/or Abomasitis and Enterotoxemia, *Clostridium perfringens* type D are the other three.



**PLATE 596: MULTIFOCAL VIRAL
(INFECTIOUS BOVINE
RHINOTRACHEITIS)
RUMENITIS**

The small hemorrhages and the multiple, yellow foci of necrotic debris scattered on this rumen mucosa are the result of Infectious Bovine Rhinotracheitis (IBR) infection in a newborn calf. These look like pieces of curdled milk that won't wash off, but histologically, they are clumps of necrotic debris attached to the areas of focal necrosis in the mucosa. With hard (acid) fixatives intranuclear inclusion bodies may be found in these areas and in the lung, liver and especially in the focal areas of necrosis in the adrenal glands.

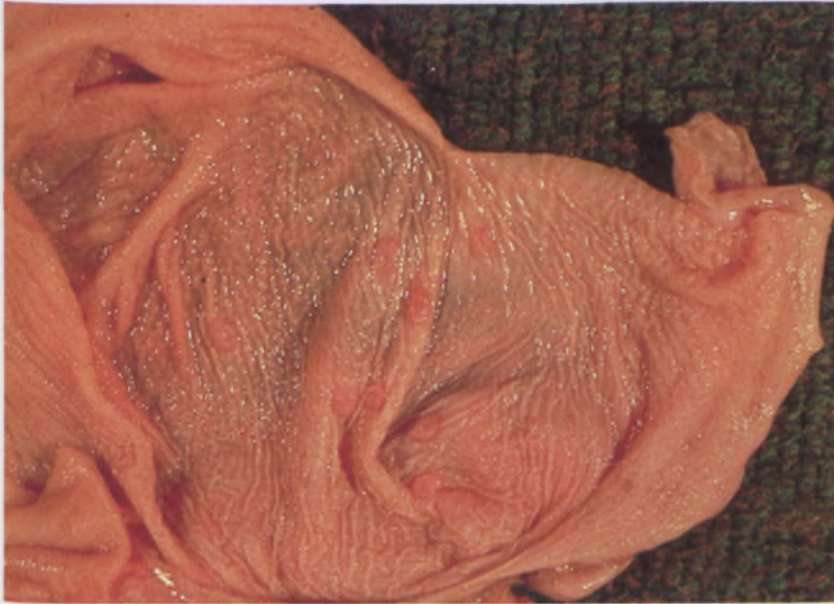

PLATE 597: VIRAL (BOVINE PAPULAR STOMATITIS) RUMENITIS

The several slightly elevated round pink papules scattered in the mucosa of this one week old calf are the lesions of Bovine Papular Stomatitis, a viral disease of young calves. Intracytoplasmic inclusions were present histologically. Lesions of this disease are usually on the lips, nose and the palate of calves.

Dr. R. C. Liu, Taiwan, ROC

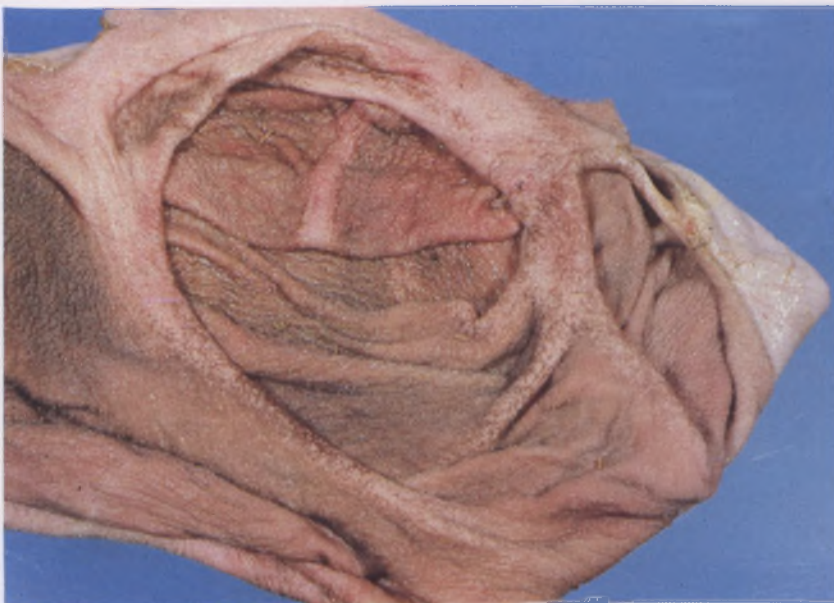

PLATE 598: MULTIFOCAL VIRAL (VIRUS DIARRHEA) EPITHELIAL DEGENERATION

The many white foci scattered in the dark rumen pillars are foci of hydropic degeneration of the superficial epithelium caused by the virus of Virus Diarrhea in this cow. Other diagnostic lesions will often be found as similar lesions in the mouth and esophagus and necrosis of Peyer's patches in the intestines.

Dr. C. L. Liu, Taiwan, ROC

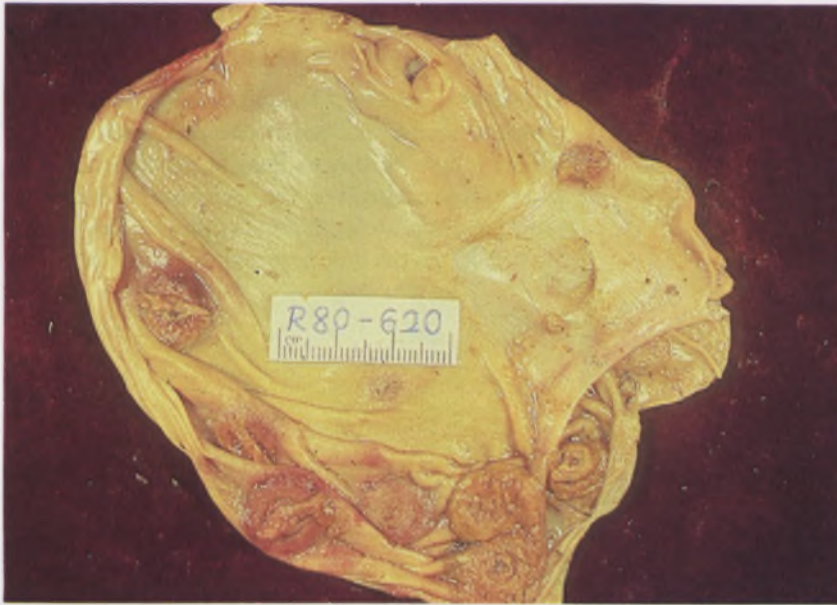


PLATE 599: MULTIFOCAL MYCOTIC GASTRITIS

The multiple, slightly elevated, concentrically structured plaques are focal lesions of Mycotic Gastritis. Excessive use of antibiotics is a common association made with this problem. It is more common in the mouth and esophagus. *Candida* spp., and *Aspergillus* spp. are two common isolates in such cases.

Dr. R. Chu, Taiwan, ROC

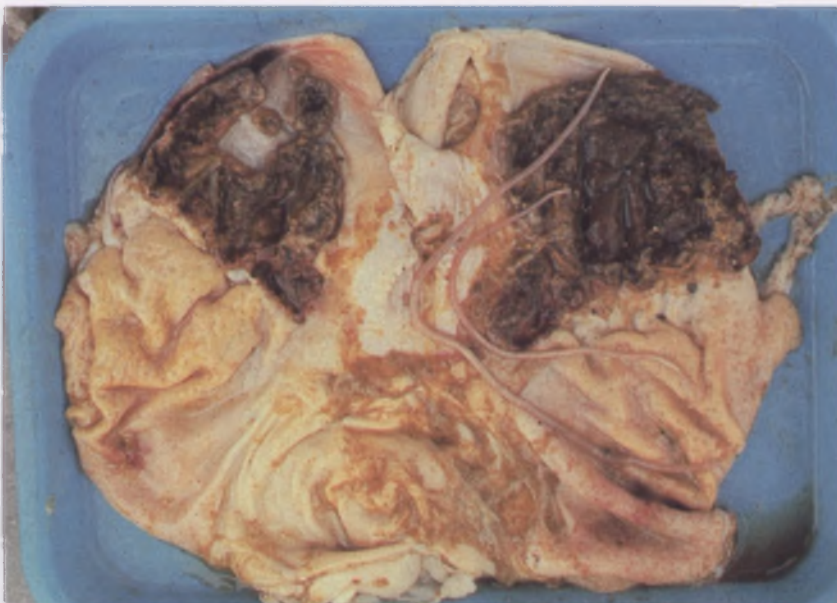

PLATE 600: MYCOTIC (*MUCOR* SPP.) ULCERATIVE GASTRITIS

The large dark areas of necrotic debris attached to the mucosa of this pig's stomach are due to Mycotic Ulceration. The definite raised edges and several small target shaped similar lesions are quite typical. The two ascarids, *Ascaris lumbricoides*, are postmortem migrants from the intestine. *Mucor* spp. was isolated from the Mycotic Ulcers. Often these ulcers are related to excessive dosage or prolonged use of antibiotics.

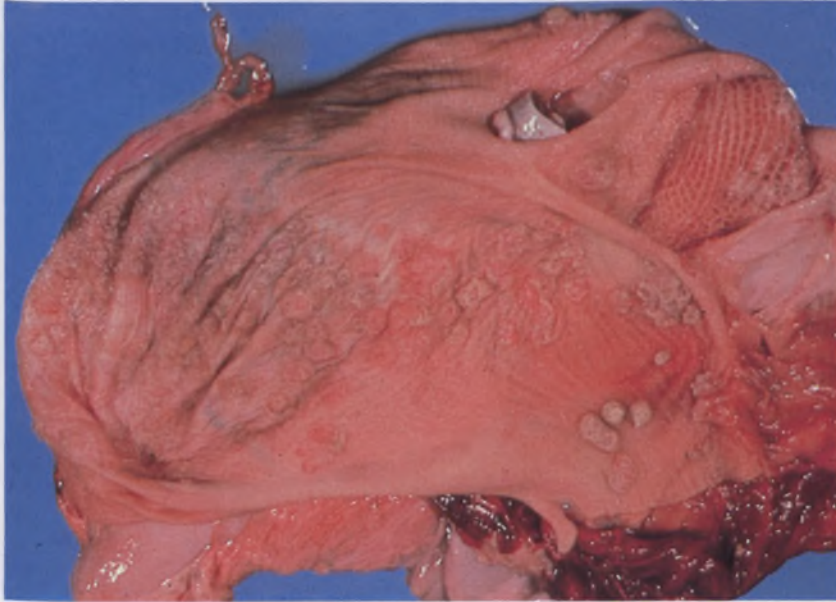


PLATE 601: MYCOTIC RUMENITIS

The multiple, discrete and confluent, circular target shaped lesions in this calf's rumen are caused by Mycotic Rumenitis. It is usually associated with the over use by dose or time of antibiotics in the feed. *Mucor* spp. and *Aspergillus* spp. are commonly isolated.

Dr. C.I. Liu, Taiwan, ROC

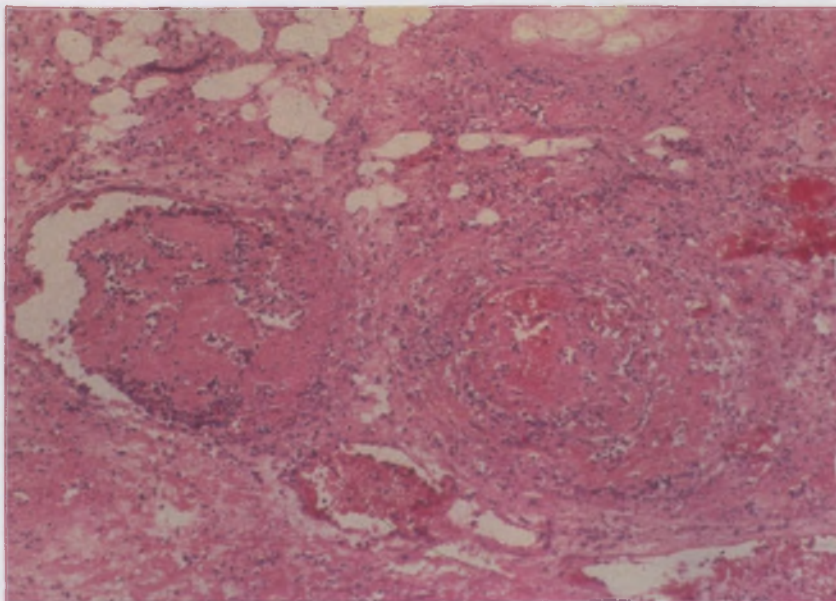
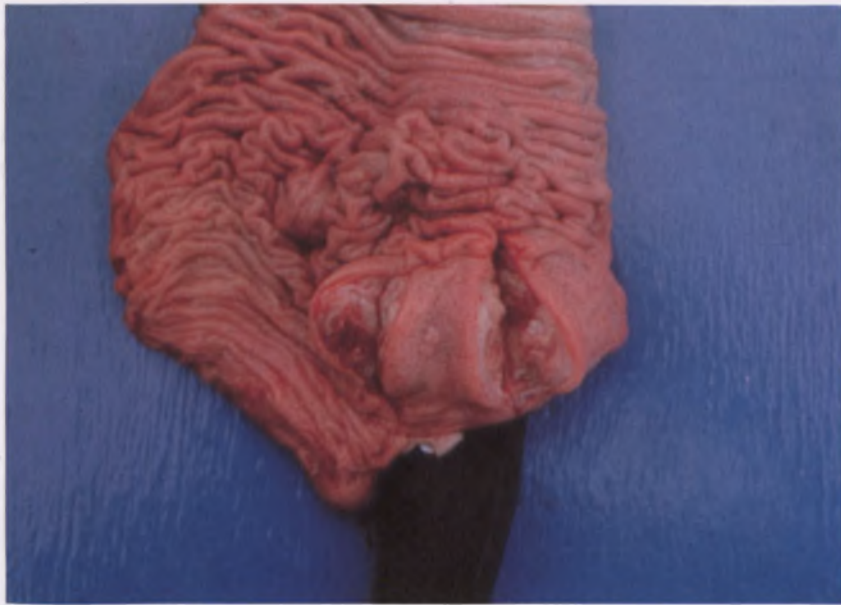

PLATE 602: NECROTIC VASCULITIS AND THROMBOSIS

The histological finding of Necrotic Vasculitis and Thrombosis should always make one look for mold hyphae, as these findings are very consistent with Mycotic Infections. This was from a calf with *Mucor* spp. ulcers in the abomasum. Several purple pieces of shrunken hyphae are in the thrombus part of this lesion. Often, silver stains are helpful in diagnosis when only a few hyphae are present.

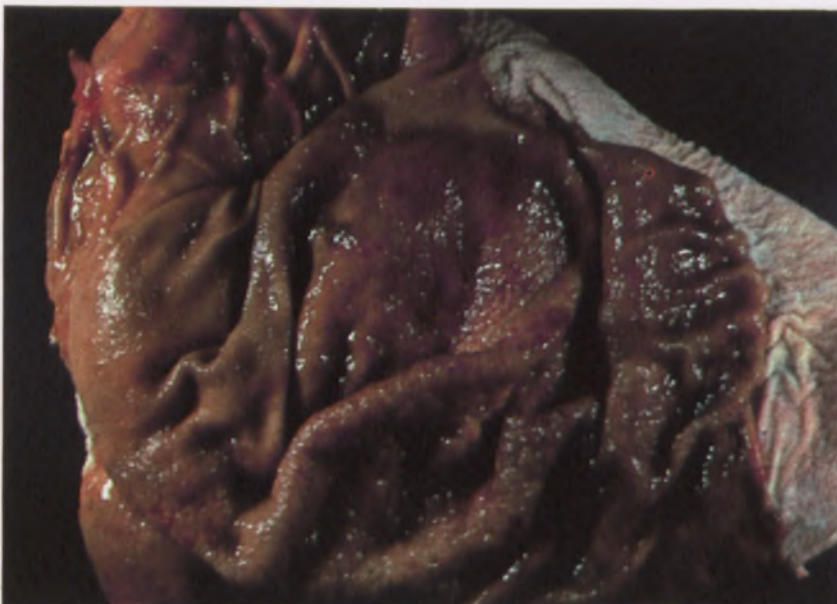
Dr. C.I. Liu, Taiwan, ROC



**PLATE 603: *SPIROCERCA LUPI*
GASTRIC BROOD POUCH**

The large granulomatous mass in the submucosa of this dog's stomach is a Brood Nodule of the Esophageal Worm, *Spirocerca lupi*. As their name suggests they are usually located near the esophagus, but they can be elsewhere as here and even in the rectal area.

Dr. G. Appel, Kenya



**PLATE 604: *HYPERTROPHIC*
GASTRITIS**

The granular, thickened, congested mucosa of this horse's stomach is Hypertrophic Gastritis caused by *Trichostrongylus axei*.

Dr. C. L. Taylor, RDC

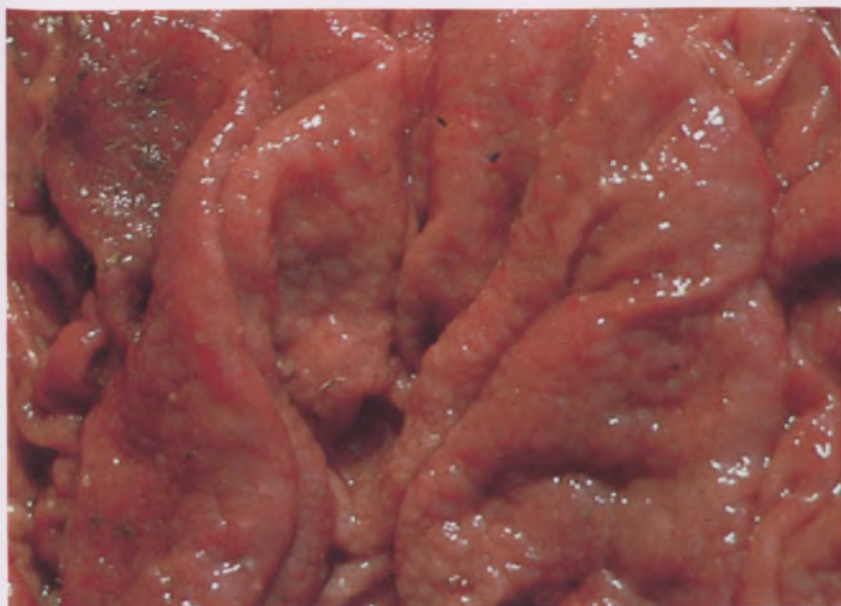

PLATE 605: PARASITIC (*OSTERTAGIA OSTERTAGI*) GASTRITIS

The fine uniform granularity of the mucosa of this calf's abomasum is the result of Ostertagiosis caused by *Ostertagia ostertagi*. This is the middle sized stomach worm of cattle and sheep. The fine granularity is sometimes called "Morocco Leather" pattern.

Dr. C. Burgeff, Morocco, USA

Note the rugae pattern, which is altered. While the horse can cause some alterations in the stomach, this alteration is probably the remnant of Congenital Gastric Ulceration that was often to be seen in abused and newborn foals.

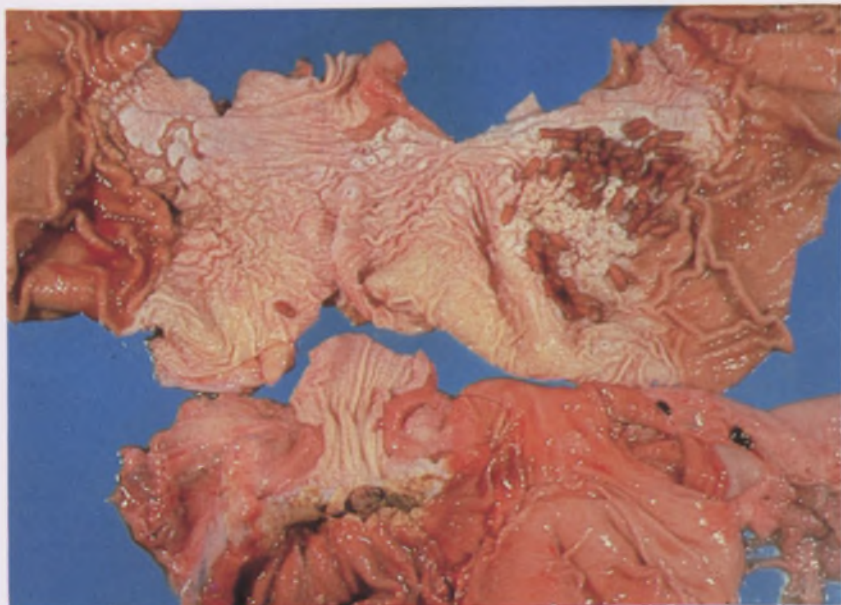
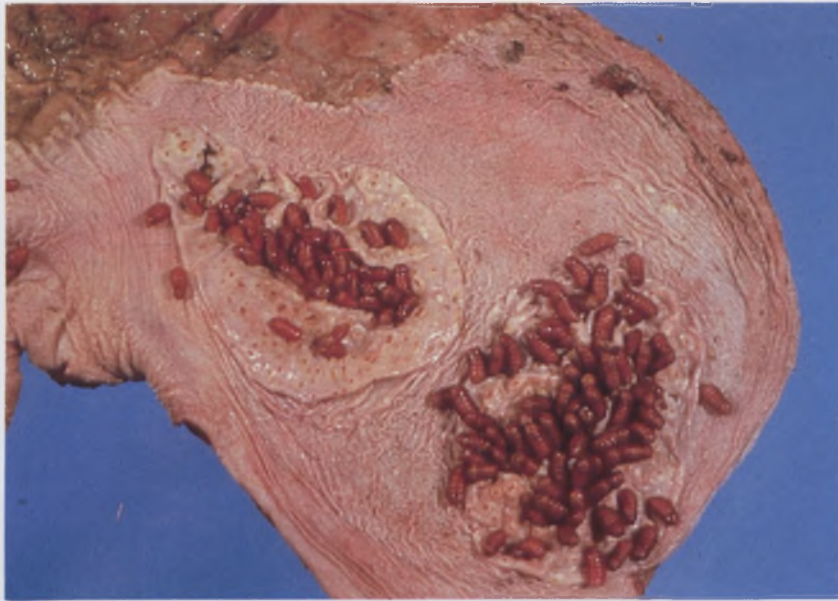


PLATE 606: GASTRIC ULCERATION AND HEALING

The one young horse's stomach with the Bots, *Gasterophilus intestinalis*, attached is essentially normal and shows a large squamous region in the stomach. The other foal's stomach has almost no squamous region of the stomach, and the distal esophagus is directly contacting the glandular stomach at a corrugated ulcerated line. This lesion in pigs is thought to be the result of Gastric Ulceration, with loss of the entire esophageal region of the stomach and subsequent healing. Its cause in foals is not known, but a similar process certainly could explain it. Epithelial Defects have also been considered but these are usually in the esophagus proper of foals.

Dr. J. Lay, Cornell, USA



Dr. G. Appel, Texas

**PLATE 607: GASTEROPHILUS
INTESTINALIS
EPITHELIAL PLAQUES**

The two masses of Stomach Bots in this horse are *Gasterophilus intestinalis* and they are in the squamous region of the stomach as is normal, but what is odd is that they are both on Smooth Plaques of Stratified Squamous Epithelium. The cause of these plaques is related to the presence of bots but as we have only seen it a few times we do not have an explanation.

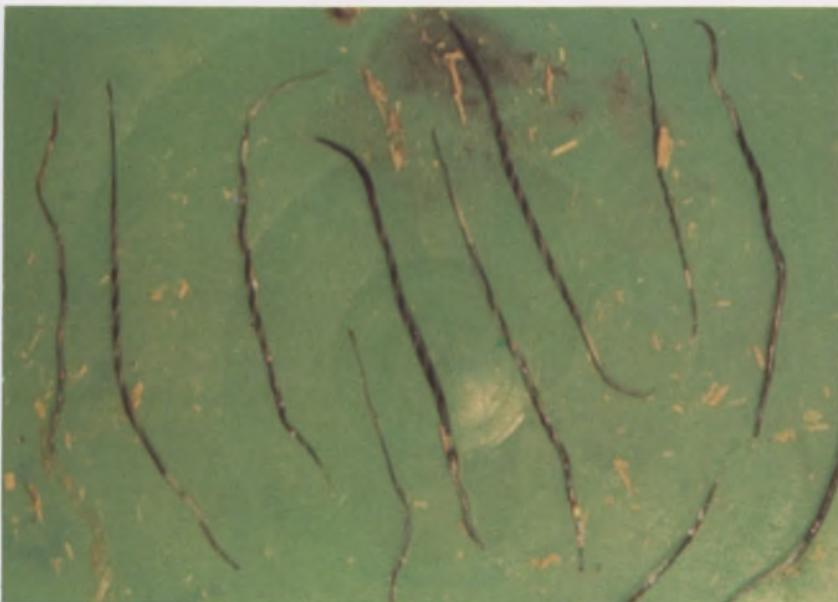
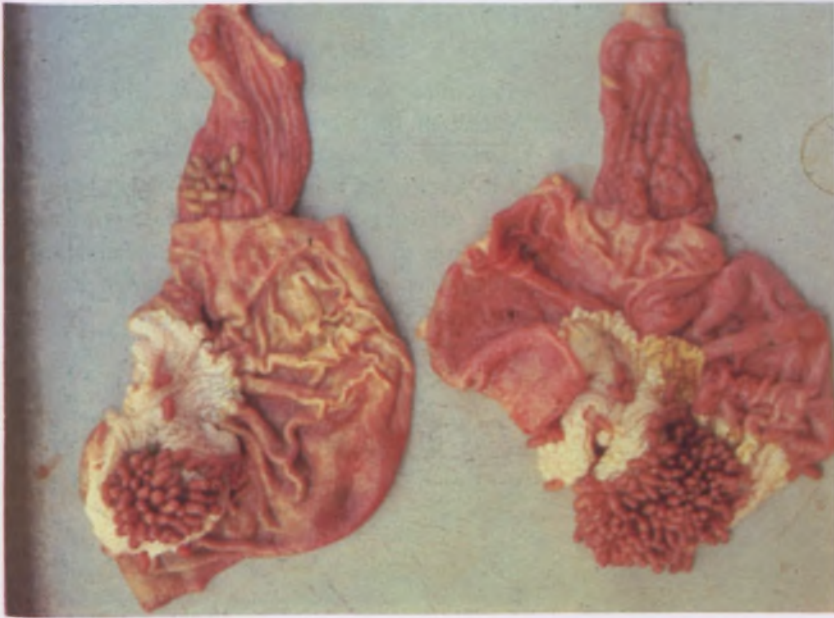


PLATE 608: HEMONCHUS CONTORTUS

One often hears of the "Barber Pole Worm", *Hemonchus contortus*, seen in cattle, sheep and goats, but this feature is not always as easy to see as in these worms from a cow.

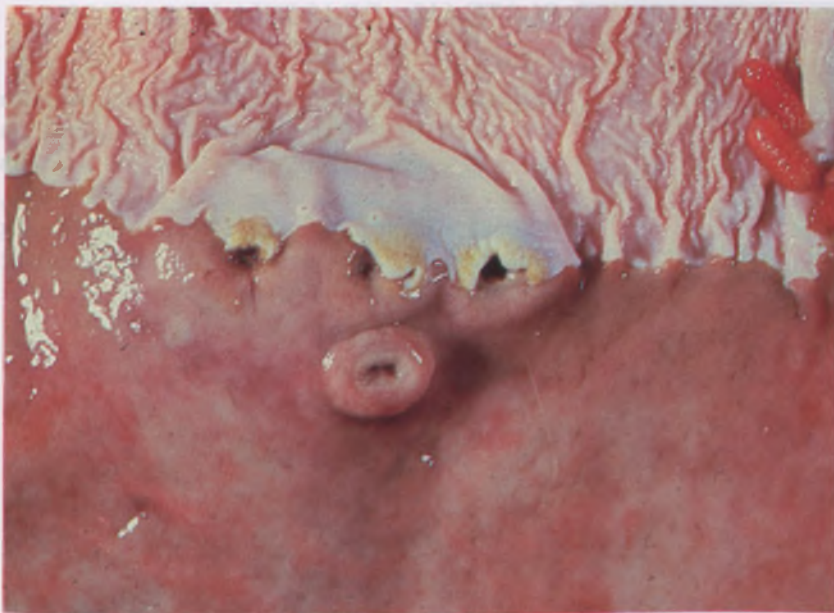Dr. W. Krull, Oklahoma, USA



**PLATE 609: CONGENITAL GASTRIC
ULCERATION AND
MYIASIS**

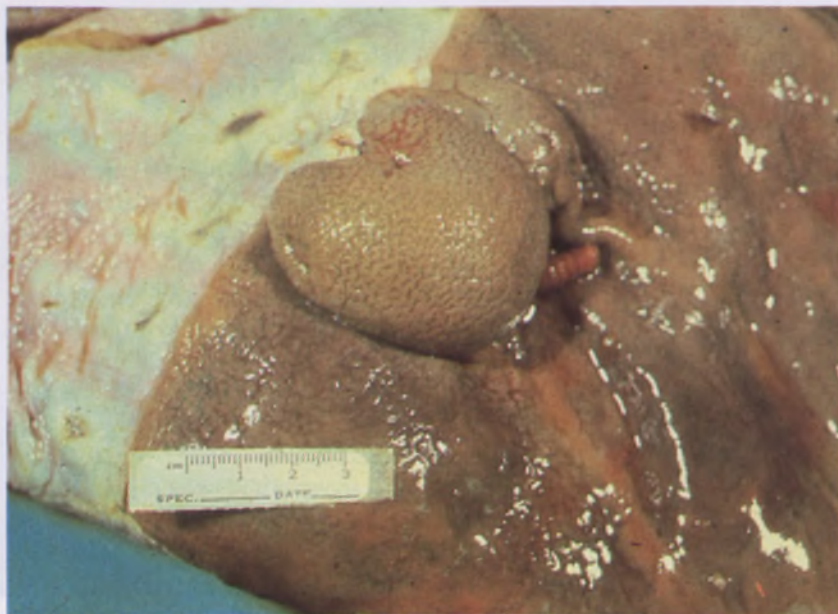Two stomachs of horses are shown here to demonstrate the natural location of horse Bots, *Gasterophilus intestinalis* and *Gasterophilus nasalis*. The red tinged bots attached in the stratified squamous portion of the stomach are *G. intestinalis* and the pale bots, which are not in the stomach as many believe but in the cranial end of the duodenum, are *G. nasalis*. To keep these straight in one's mind it is best to think they are located opposite to the anatomical location that their names indicate. The nodular projections in the most distal part of the duodenum shown are the duodenal papillae, the opening of the bile ducts. One of the stomachs shows a yellow area of the stratified epithelium portion of stomach, about in its middle portion near the margo plicatus, which is ulcerated. While the bots can cause some ulcerations in the stomach, this ulceration is probably the remnant of Congenital Gastric Ulceration that can often be seen in aborted and newborn foals.

Dr. C. Burgelt, Honida, USA



**PLATE 610: *DRASCHIA MEGASTOMA*
BROOD POUCHES
(GASTRIC
HABRONEMIASIS)**

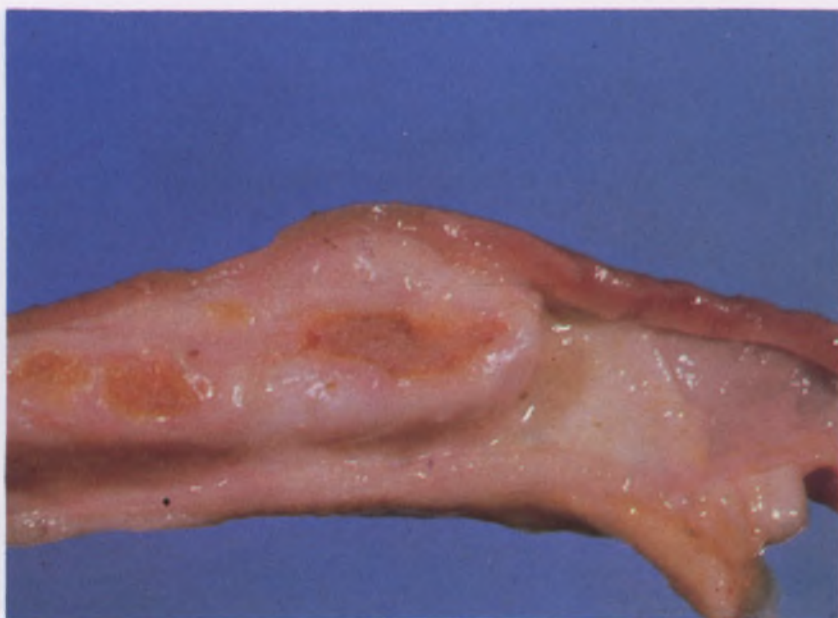The several cratered lesions in the glandular portion of this horse's stomach, near the margo plicatus are *Draschia megastoma* Brood Pouches. These are one of several species of stomach worms in the horse. An aberrant location for these parasites is in the skin where the intermediate host, often the house fly, deposits the *Habronema* spp. larvae from its saliva onto wet wounds to help cause progressive lesions called Summer Sores or Cutaneous Habronemiasis.



**PLATE 611: *DRASCHIA MEGASTOMA*
BROOD POUCH**

The large mass shown here just under the glandular epithelium of the stomach near the margo plicatus is a *Draschia megastoma* Brood Pouch. A healed ulcer is seen on one side and the small fistulous opening, allowing the parasites to escape, is seen near the top of the mass. Most are located in the glandular area of the mucosa but some may be primarily under the squamous portion.

Dr. C. Bugell, Honida, USA the hole can cause some ulcerations in the stomach, this ulceration is probably the result of Congen- ital. Cystic location that can often be seen in started and develop later.



**PLATE 612: *DRASCHIA MEGASTOMA*
BROOD POUCH**

In the submucosa of this horse's glandular stomach is this pale white granulation tissue pouch with a clump of many small pale parasites. This is a cross section of a *Draschia megastoma* Brood Pouch, with the worms still present. The fistulous opening to the lumen is not shown. The older name for this parasite was *Habronema megastoma*.

Dr. W. Kraut, Oklahoma, USA

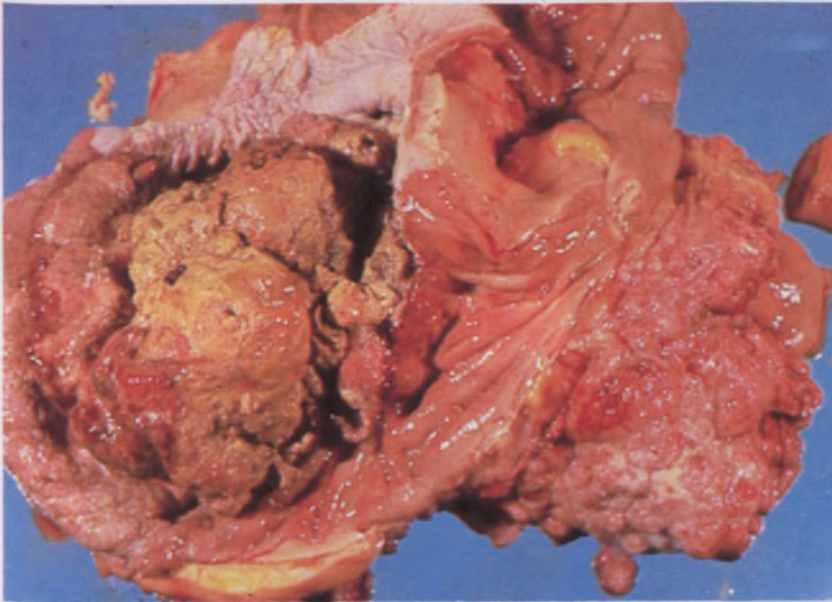


PLATE 613: SQUAMOUS CELL CARCINOMA

The stomach of this horse has a large ulcerated area in the wall which involves both the squamous and glandular regions of the stomach. The large irregular rounded mass is a large necrotic part of this Squamous Cell Carcinoma. At necropsy this would usually have a very foul odor. Many cases of this malignant neoplasm are usually associated with cachexia and eating problems in the horse, but every now and then a severe case even like this is found as an incidental finding at necropsy. While this may be seen in any species of animal, the horse is the most commonly affected.

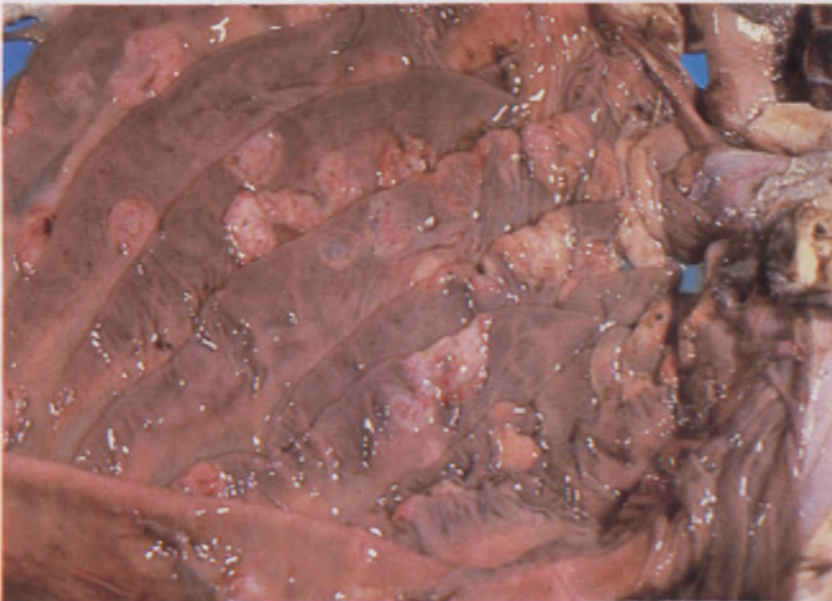


PLATE 614: LYMPHOSARCOMA

Usually Lymphosarcoma in cattle causes a marked thickening of major parts of most abomasal folds, but in this case of Lymphosarcoma only multiple discrete flattened plaques were formed on the folds.

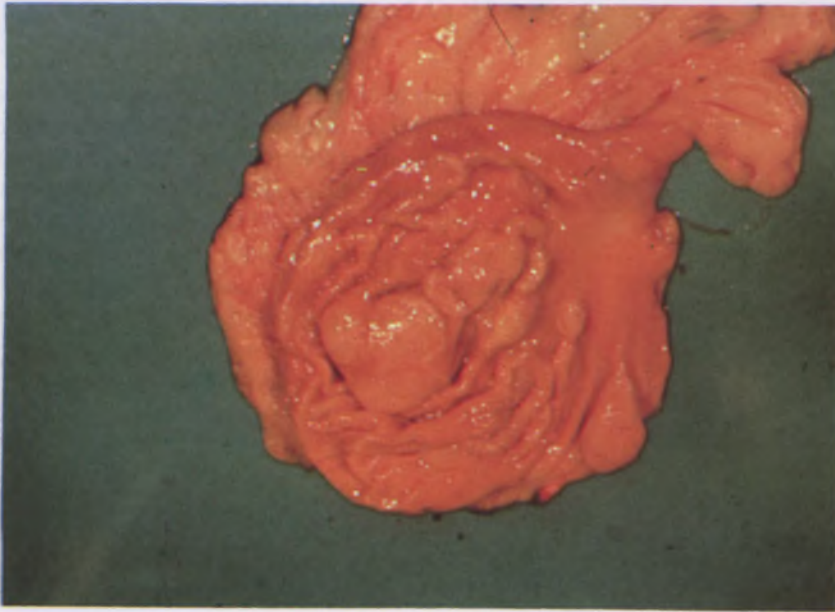


PLATE 615: LYMPHOSARCOMA

The multiple various sized pale masses and areas of gastric folds in this cat are caused by Lymphosarcoma. As in the cow, they may be found in many scattered tissues.

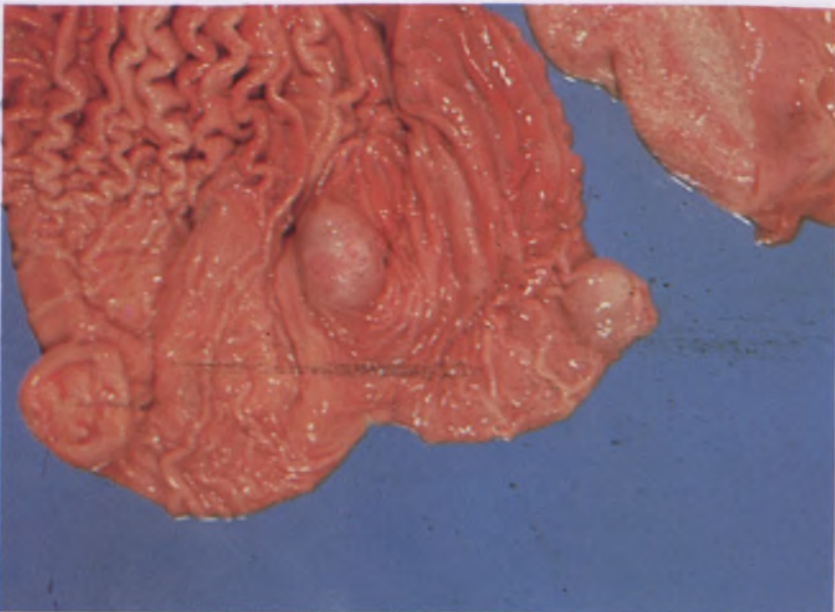


PLATE 616: LEIOMYOMAS

The three masses in the submucosa of this dog's stomach are firm and one has an ulcerated surface. They are usually located near the esophageal openings and a single mass is far more common than multiple masses. These are Leiomyomas, benign smooth muscle tumors of the stomach wall usually in old dogs. Actually they are quite common tumors but many are found just under the mucosa and more often palpated than seen. The ulcerated one shown here was probably traumatically eroded initially.

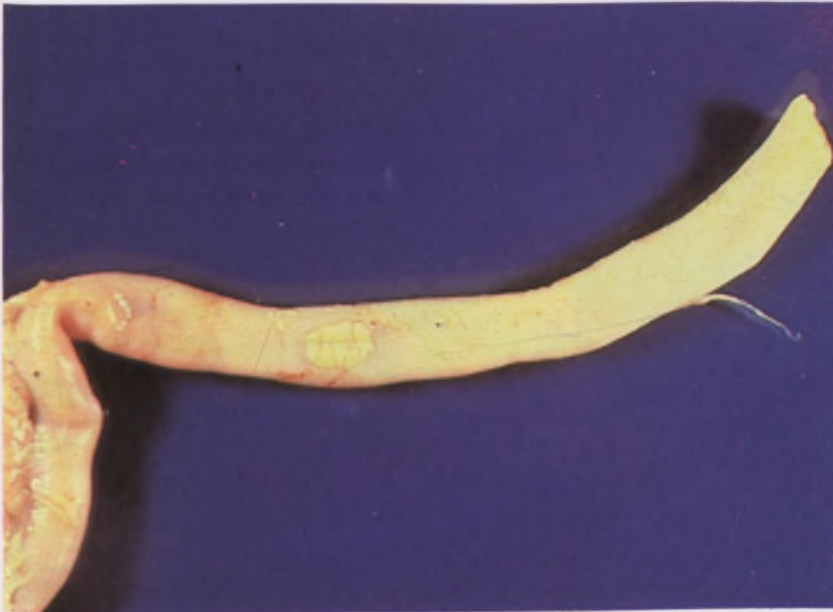

PLATE 617: ECTOPIC PANCREATIC TISSUE

The small, pale slightly streaked plaque in the serosa of this dog's duodenum is Ectopic Pancreatic Tissue. The normal pancreas is more pink and attached near one end of this portion of duodenum. Ectopic tissue of all types may be found in almost any part of the body.

Dr. H. J. ...

can be seen in the stomach and colon. It may also be seen in the urinary bladder, uterus and even the spleen. It is seen in cats as well as dog. This was first noted years ago in the bilious flatulated dogs and called "Maple Sugar Intestine".

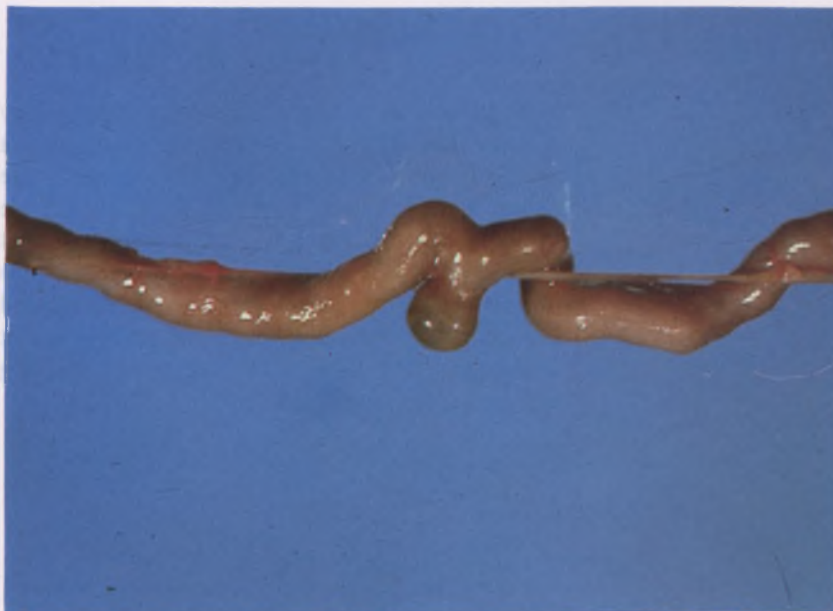

PLATE 618: MECKEL'S DIVERTICULUM

The small diverticulum off the small bowel in this cat is a remnant of the yolk stalk called Meckel's Diverticulum. It is seen in most species and is usually located at the level of the ileum or distal jejunum. They can be quite elongated or short like this. They may even be a free stalk from the umbilical area.

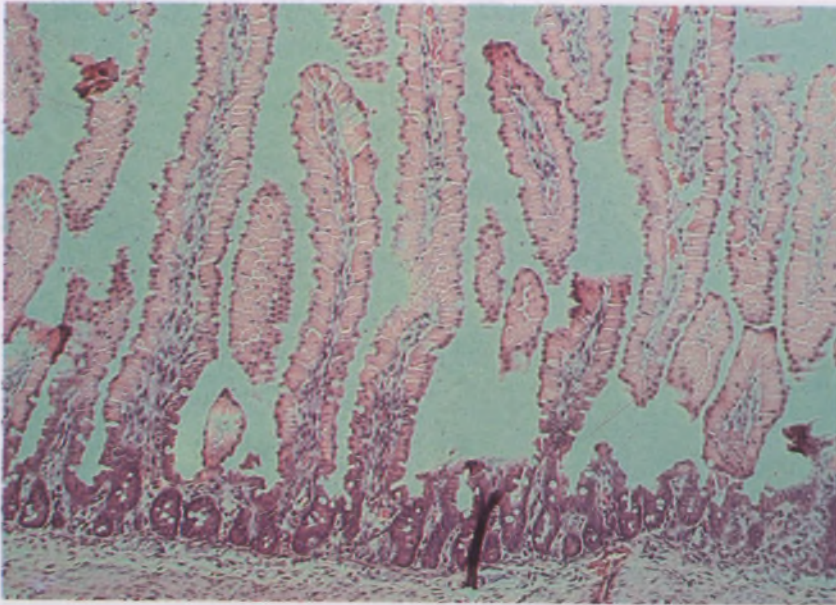


PLATE 619: INGESTED COLOSTRUM GLOBULES

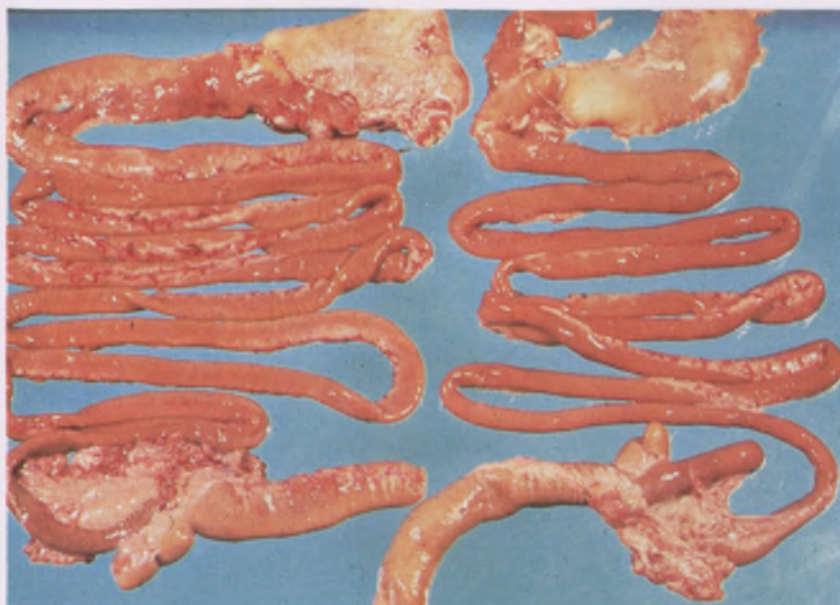
This histological section of intestinal villi of a piglet shows the many pink globules of Ingested Colostrum filling most of the epithelial cells. These are often mistaken for an unknown pathological process.

Dr. R. Chu, Taiwan, ROC

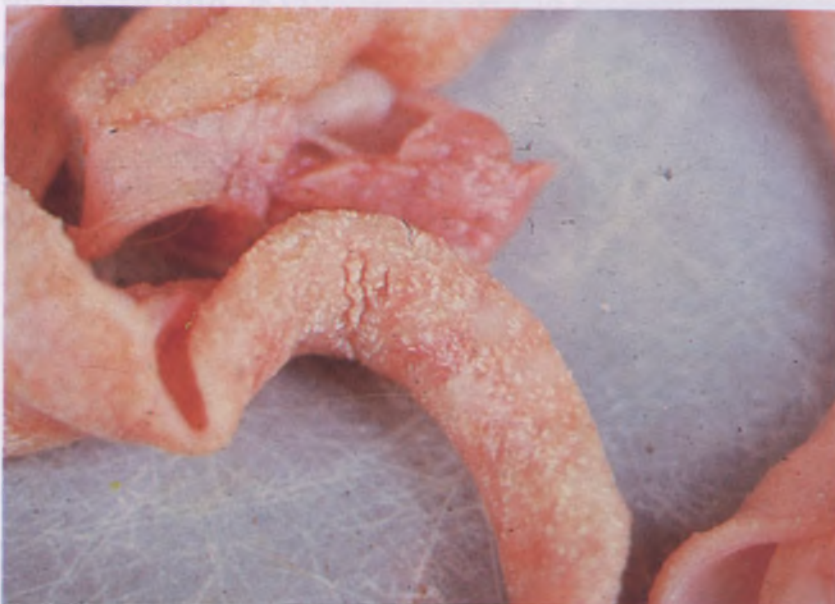

PLATE 620: VILLOUS LYMPHANGIECTASIA

This portion of a dog's duodenum shows many opaque white villi, as the result of Lymphangiectasia of the lymphatics in the villi. The opaque white nature is due to the increased amount of chyle in the lymphatics. The actual cause of this apparent obstruction is unknown. It has been seen in three generations of Yorkshire terriers. A few dilated lacteals in any one dogs intestinal mucosa is not uncommon, but when it is this severe the dog usually has digestive problems.

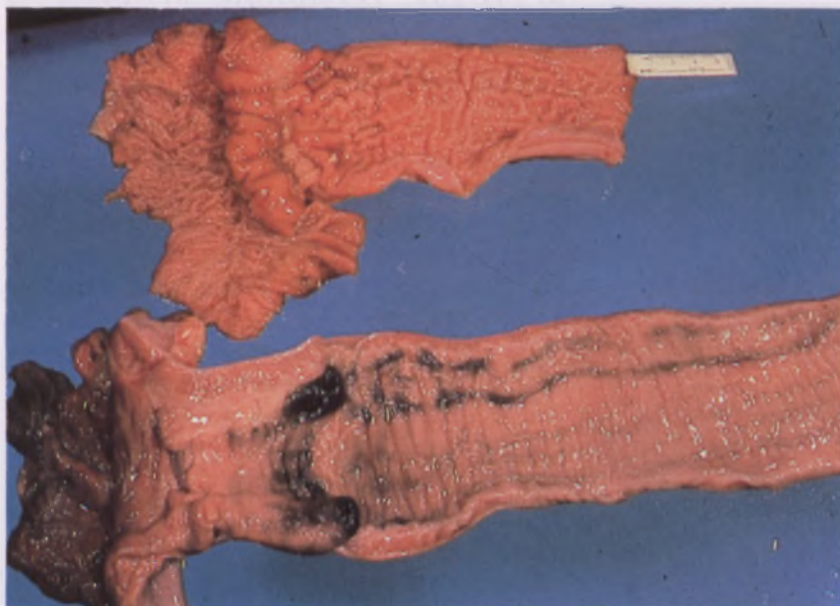


Dr. B. Shetfy, Cornell, USA

**PLATE 621: LEIOMYOMETAPLASIA
(INTESTINAL
LIPOFUSCINOSIS) (BROWN
DOG GUT)**

The distinct brown discoloration of the intestines and scattered portions of the stomach walls of these two dogs are Grade 6 examples of Leiomyometaplasia (Brown Dog Gut) associated with a Vit. E Deficiency. In milder cases only the intestine is involved either starting at the duodenum and fading out in the ileum or vice versa. It is a lipofuscin pigment deposition, as the result of improper lipid metabolism. Histologically, it is seen as brown granules, Leiomyometaplasts, located near the nuclear poles in the smooth muscle cells.

They are most common in the outer fibers of the circular muscle layer in extremely mild, Grade 1 cases. It is only in Grades 5 and 6 that the lesions can be seen in the stomach and colon. It may also be seen in the urinary bladder, uterus and even the spleen. It is seen in cats as well as dog. This was first noted years ago in the biliary fistulated dogs and called "Maple Sugar Intestine".



**PLATE 622: IDIOPATHIC
HYPERTROPHY OF THE
ILEUM**

These two segments of ileum and attached colon came from two horses with Idiopathic Hypertrophy of the Distal Ileum. The one portion with pseudo-melanotic blackening of the mucosa has about a 7 cm markedly thickened portion, with a small lumen and a partial flap at the proximal end of the constricted lumen. The rest of the ileum shown has a slightly thickened muscular coat. The other ileum has a hypertrophied muscle coat and a complete area of healing ulceration at the ileocecal junction. The cause of Idiopathic Hypertrophy of the Ileum in horses is unknown. It is a common lesion and often is associated with clinical signs.

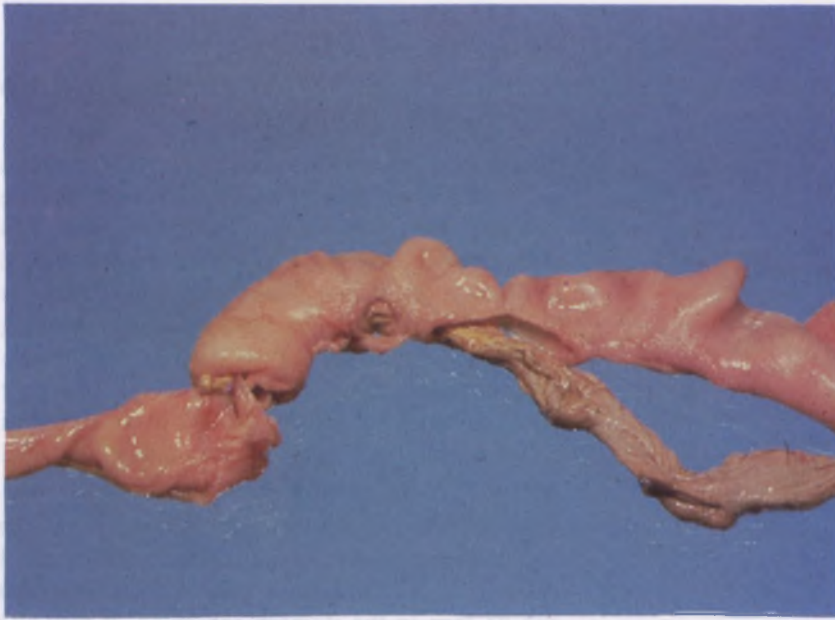


PLATE 623: LINEAR FRICTION ULCERS

At one end of this portion of dog's small intestine the entering layer of the intussusception is invaginating into the Intussusciens. Along the mesenteric attachment border a small Perforating Ulcer (Linear Friction Ulcer) can be seen with the invaginated piece of bowel, the Intussusceptum, within the bowel lumen. A short distance from this perforation is another longer Linear Friction Ulcer again along the same mesenteric border, through which the degenerated Intussusceptum has been pulled to demonstrate the lesion. Only a bit of the fibrin remains, scattered to show that it was an antemortem ulceration. Other Linear Foreign Bodies, principally string, but parasites can cause similar lesions.

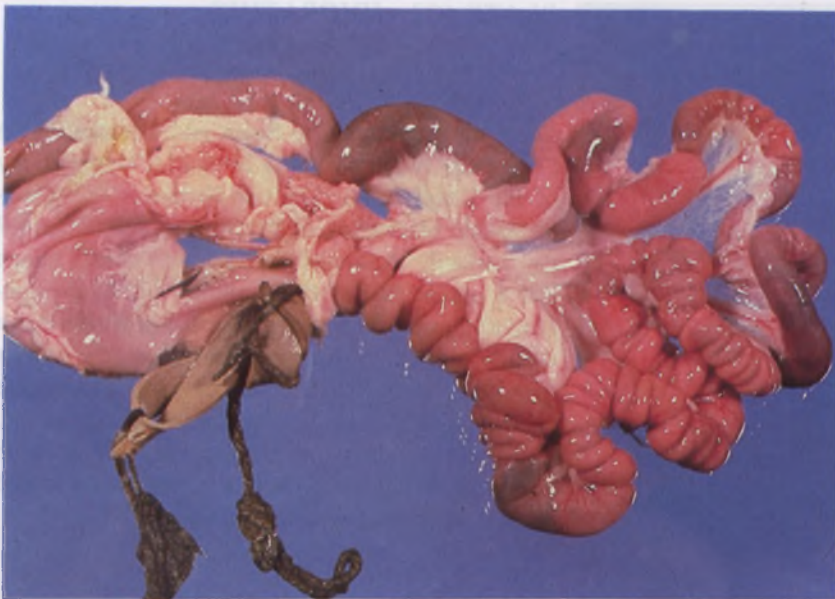


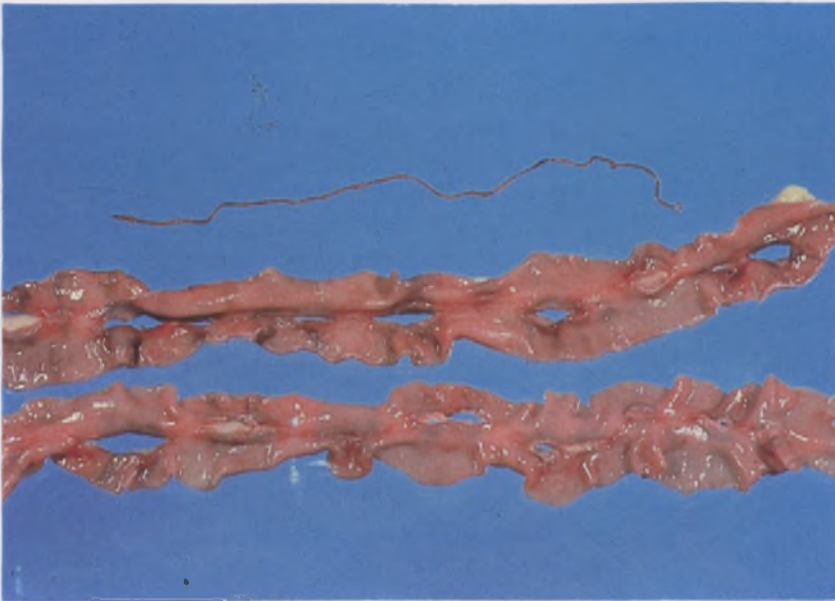
PLATE 624: ACCORDION PLEATED INTESTINE AND LINEAR FOREIGN BODY

Approximately half the small intestine is thrown in marked folds in this Accordion Pleated Intestine. This is the result of eating a Linear Foreign Body, in this case a string with several elastic bands attached. The lump of string and rubber band stayed in the stomach to act as the anchor, while a free end of the string went down the intestine to allow the pleating of the bowel. Several early Linear Friction Ulcers were seen in the intestinal mucosa but none had perforated, as they may do. Towards the end the small intestine in the ileum two Postmortem Intussusceptions can be seen as round smooth invaginating areas of bowel. These were easily pulled out. A vascular reaction or inflammation was not associated with them.

Dr. R. Kirk, Cornell, USA

**PLATE 625: LINEAR FRICTION ULCERS
AND LINEAR FOREIGN
BODY**

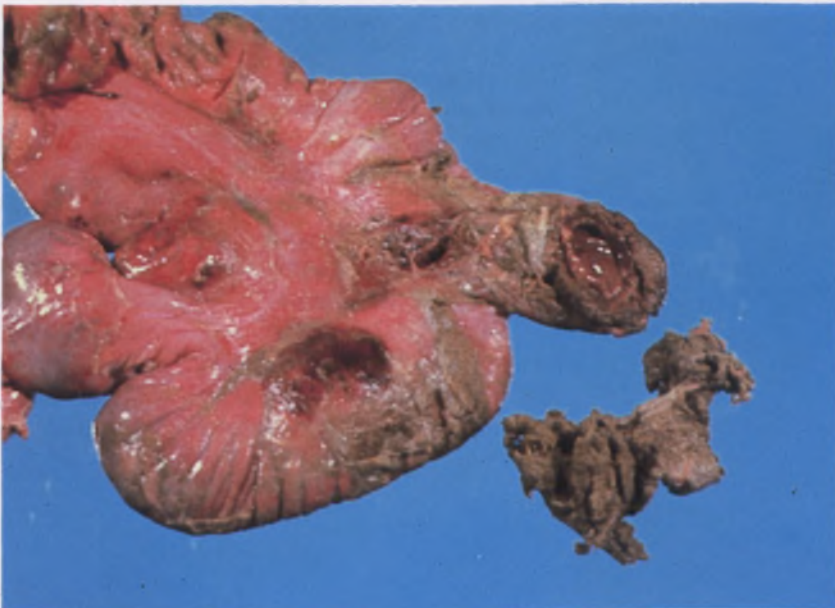Only a small segment of the fishing line that caused the problem is shown. This cat had swallowed the string with a loop catching over its tongue. This formed the anchor necessary for the above multiple Linear Friction Ulcers to develop along the mesenteric border of the bowel. Grossly, the small intestine usually appears greatly convoluted, Accordion Pleated. Cats are the animals most likely to have this lesion. Linear Foreign Bodies, even the bowel itself in an intussusception, can cause this.



Dr. D. Smith, Cornell, USA

**PLATE 626: PARTURITION RELATED
INTESTINAL RUPTURE**

The entire portion of small intestine shown here was in the pelvic canal of this pregnant cow. It is covered with ingesta and fibrin. The clump of ingesta was lying alongside the finger like projection of gut with a perforation in it. This perforation and subsequent peritonitis is the result of the loop of bowel being trapped during parturition in the pelvic canal, and during the process in which the calf was expelled, it stripped the bowel caudally until it ruptured within the pelvic canal. This is usually seen in cases of "owner assisted" parturition.



Dr. B. Tennant, Cornell, USA

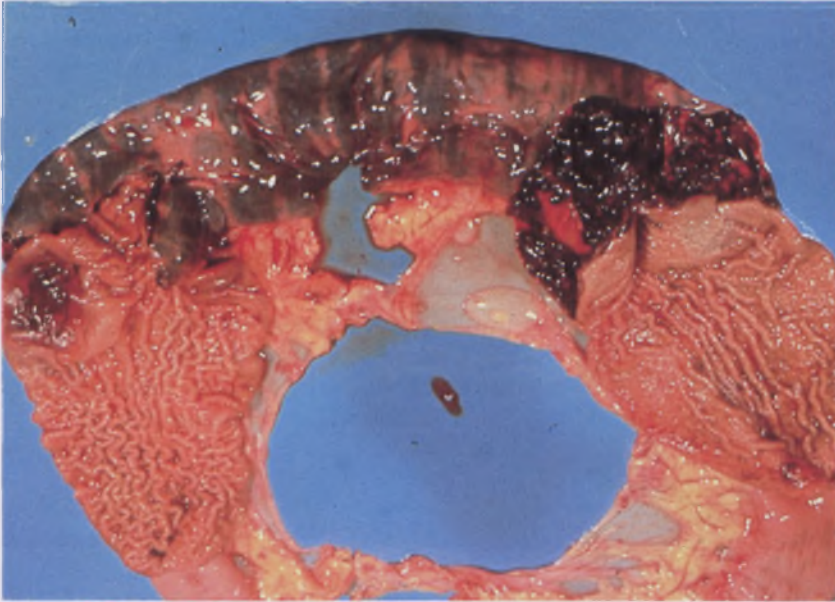


PLATE 627: SUBSEROSAL TRAUMATIC HEMORRHAGE

The massive Subserosal Hemorrhage of this horse's bowel is probably the result of external trauma to the gut as from a shearing type lesion or even direct trauma as with a kick. The mucosa is usually normal and vascular lesions such as those caused by *Strongylus vulgaris* larvae are not present. Several of these have been operated upon successfully.

Dr. D. Smith, Cornell, USA

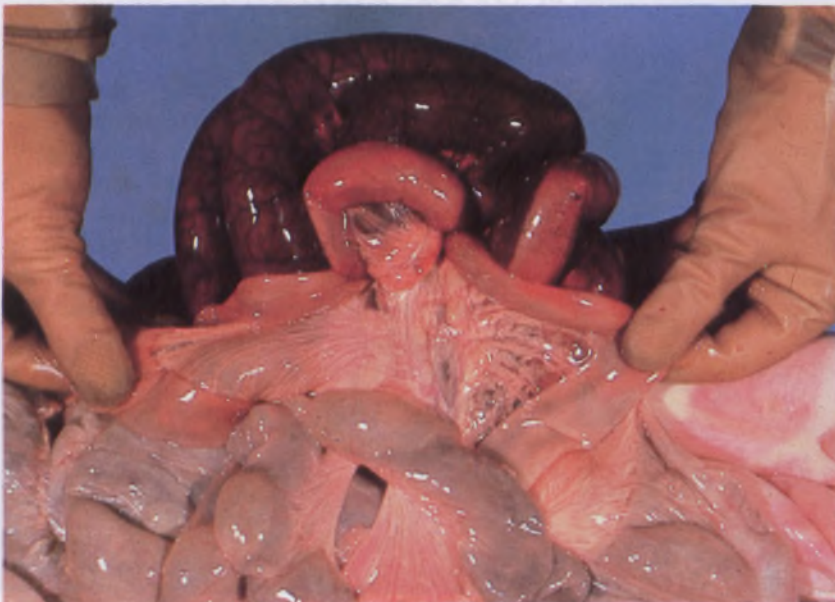

PLATE 628: INTESTINAL KNOTTING

This pig's intestine is markedly congested from strangulation as a result of Intestinal Knotting. The two relatively unaffected distal and proximal portions of the knot are being held away from the area and in the center area, a piece of gut which forms the actual center of the affected knotted bowel, is seen to be slightly less dark than the portions on both sides of it. This whole process can be explained and actually unknotted and reknotted by first holding up two pieces of bowel and making a single simple overhand tie knot, without any defect in the mesentery. How it occurs in an animal is not so easily explained.

Dr. B. Tennant, Cornell, USA

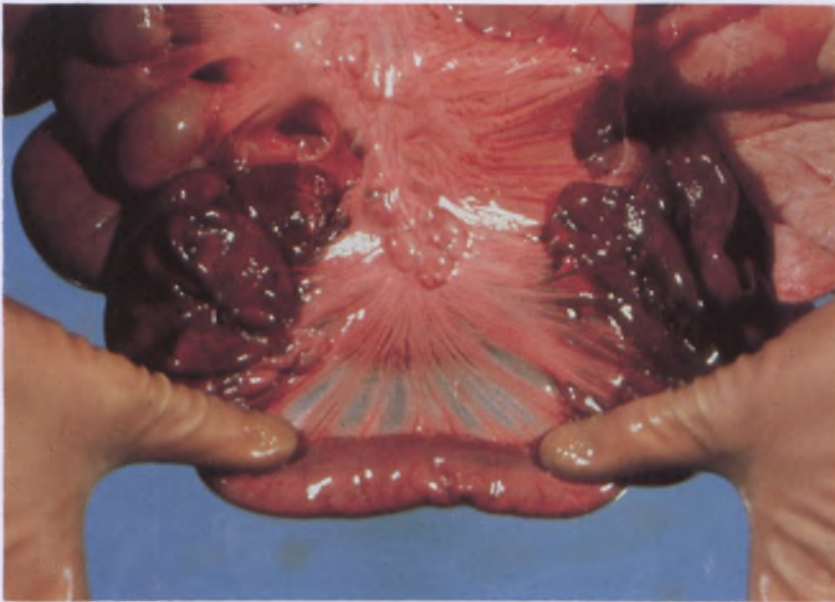


PLATE 629: UNTIED INTESTINAL KNOT

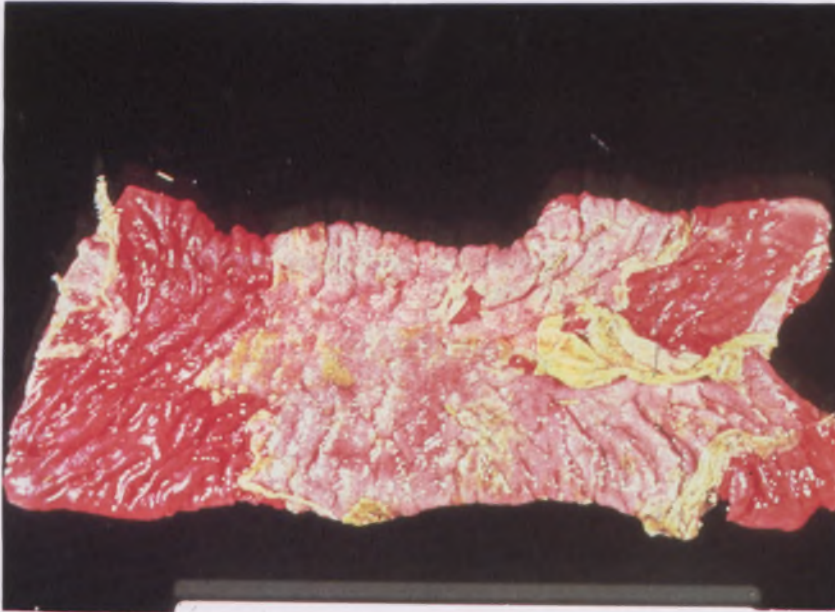This pig has had an intestinal knot which has been unknotted to show the classical more affected two portions, with a relatively less affected joining segment. The cause of such a simple overhand knot, in this or any bowel is unknown, but it can occur without any predisposing lesion in the mesentery or omentum.

Dr. J. Roth, Cornell, USA



PLATE 630: SIMPLE OVERHAND KNOT

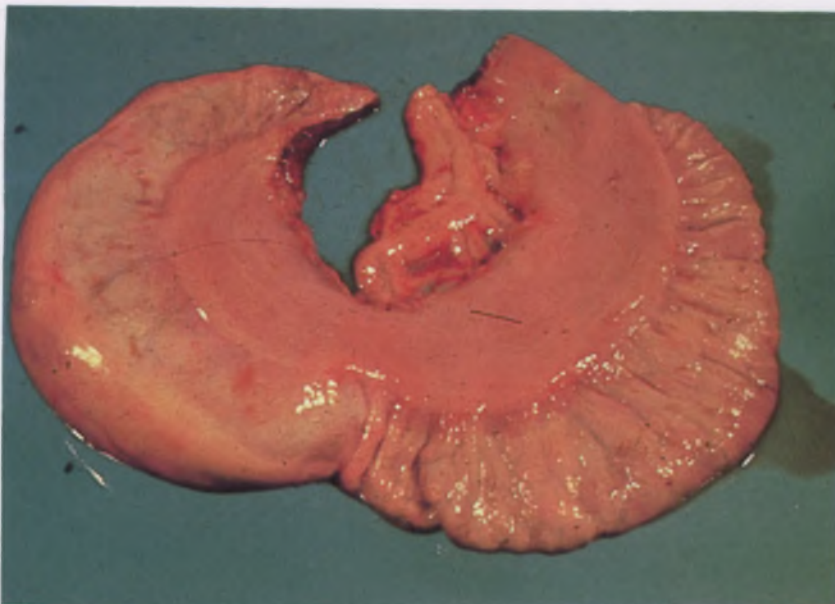
This rope has been tied in a simple single overhand tie knot to demonstrate that a knot can be tied in the bowel without a defect in the mesentery.



**PLATE 631: ACUTE SUPERFICIAL
NECROSIS (BLISTERING)**

The small intestine mucosa of this horse shows the marked congestion and surface necrosis with sloughing caused by the blistering agent, Cantharidin, produced by the Blister Beetle, *Epicauta* spp. It resulted from the horse eating hay contaminated with the carcasses of the beetles which were killed while on the fresh hay which was cut and immediately crimped to hasten its drying. Cattle and sheep are rarely affected, but would be expected to have similar lesions.

Dr. L. Roth, Cornell, USA



**PLATE 632: PROPULSION DIVERTICULI
OF THE ILEUM**

The inner semicircular tissue is a thickened ileum from a horse with Idiopathic Hypertrophy of the Distal Ileum. Bulging from its antimesenteric side for almost its entire length are the two slightly paler areas, one more dilated with ingesta than the other. These areas are Propulsion Diverticuli of the ileum, as a result of the obstruction associated with the Idiopathic Hypertrophy and its probably abnormal peristalsis. Usually such diverticuli are more globular than this no matter where they occur.

Dr. S. Tennant, Cornell, USA

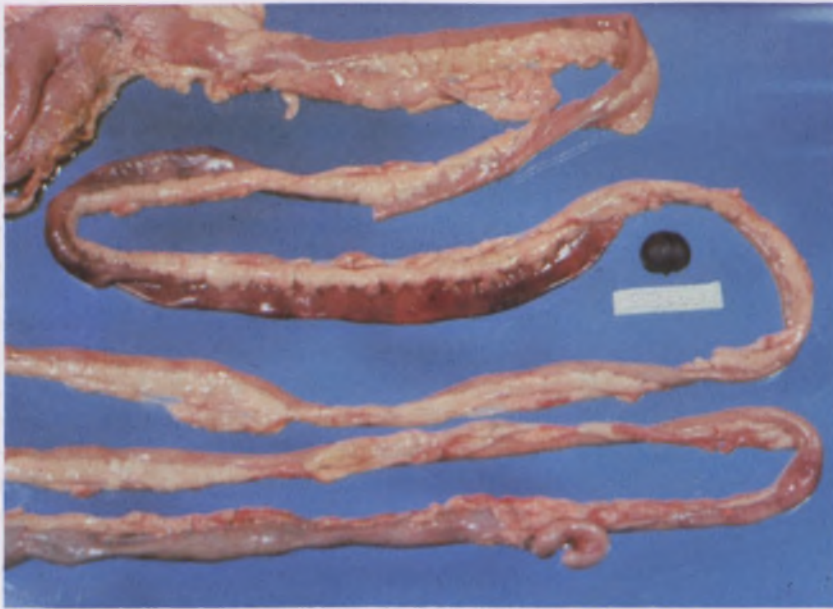

PLATE 633: INTESTINAL FOREIGN BODY

The hard foreign body that caused the hemorrhagic enteritis in the first part of this dog's intestine is a hickory nut. Intestinal Foreign Bodies may be of all types and vomit is usually a good clinical sign of the problem.

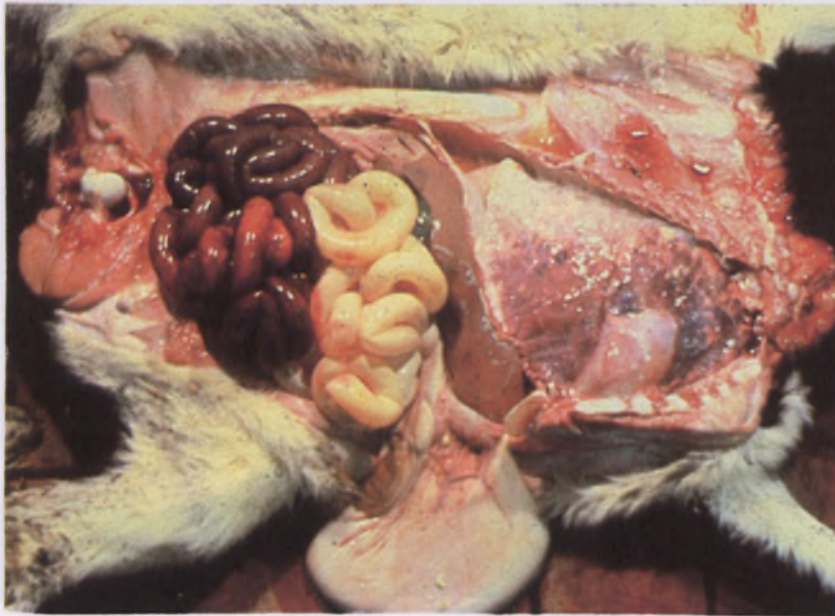
USA, Florida, University of Florida, Gainesville, Florida, USA

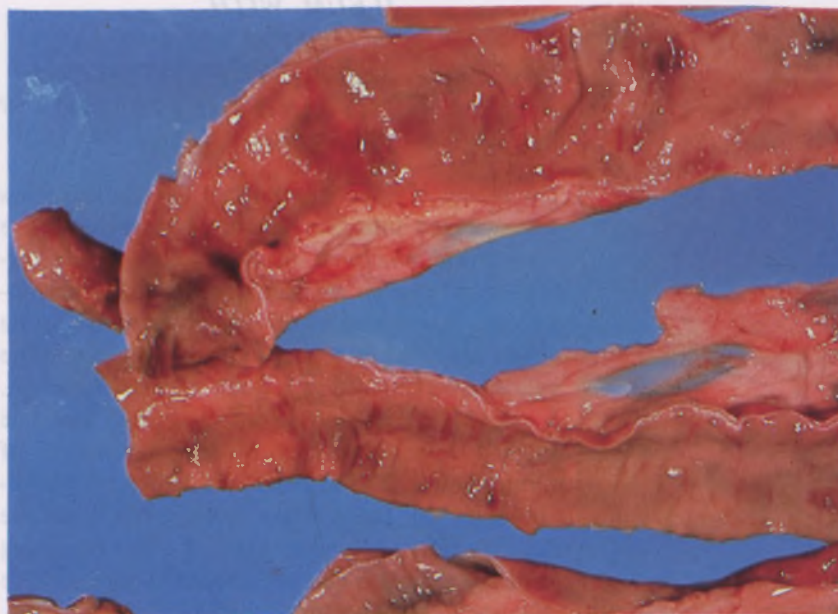

PLATE 634: CIRCULAR LAYER ATROPHY

The dog's bowel shown here is very flaccid and dilated. The muscle layer is thinner than it should be as the result of Circular Layer Atrophy. This quite specific lesion is usually associated with soft, not hard intestinal foreign bodies. It is thought that the atrophy is a form of Exhaustion Atrophy. Histologically, the external or longitudinal muscle layer is essentially normal, but the circular or inner in their place are a few atrophic fibers and scattered or clumped plasma cells, lymphocytes and mononuclear phagocytes. It is thought that hard foreign bodies can also cause this lesion if they don't kill too rapidly.

Dr. J. Ross Cornell, USA



Dr. L. Roth, Cornell, USA

PLATE 635: INTESTINAL TORSION

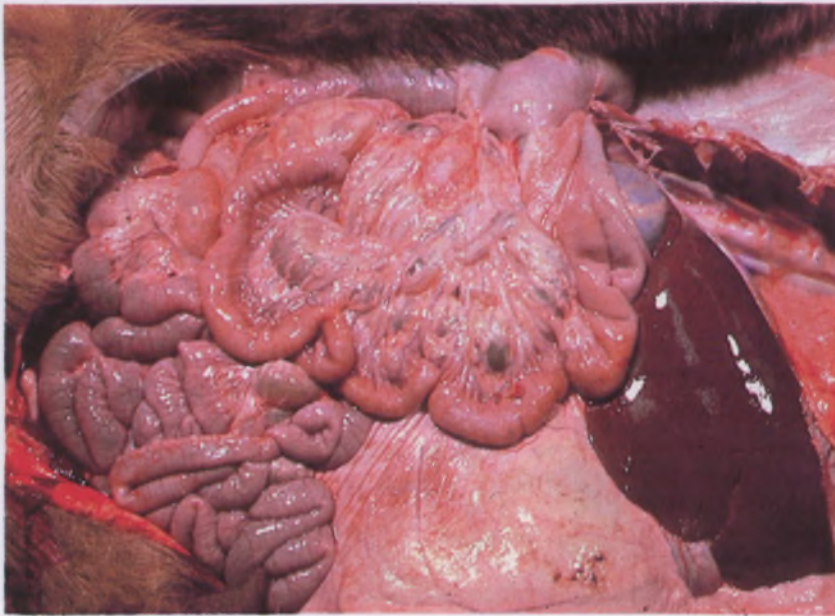
The markedly reddened intestines in this calf are the result of the intestines twisting upon the root of the mesentery, cutting off its own circulation. The terms Torsion and Volvulus are often used interchangeably, although some consider Torsion to be a twist of an organ upon itself or its longitudinal axis and Volvulus to be any other type of twist, such as through a hole in the mesentery. When these are seen it is usually best to make sure another underlying process causing abdominal pain is not present or the animal did not suddenly tumble. When abdominal pain is present, the natural protection of Abdoninal Press is not completely functional, and can not hold the abdominal viscera in place during a tumble or fall. This allows the fluid filled viscus to remain stationary, as the body twists and thus Torsion may develop. This calf actually had an Intestinal Intussusception of a chronic nature present when this Torsion occurred.



PLATE 636: IDIOPATHIC HYPERTROPHY OF THE ILEUM WITH INTUSSUSCEPTION AND SECONDARY HYPERTROPHY AND DILATATION OF THE SMALL BOWEL

The cecum is essentially normal but the ileum has intussuscepted into the cecum; not seen here. The ileum itself has well marked Idiopathic Hypertrophy and probable was the cause of the Intussusception. In addition approximately one half of the rest of the small intestine is greatly dilated and the wall is hypertrophied as a result of the obstruction. A cleaned off portion of affected small intestine weighed four times that of an equal length of normal bowel. The cause of the Idiopathic Hypertrophy of the Ileum is not known, but of course the Secondary Hypertrophy of the remaining small bowel in this case was caused by the blockage associated with the intussusception.

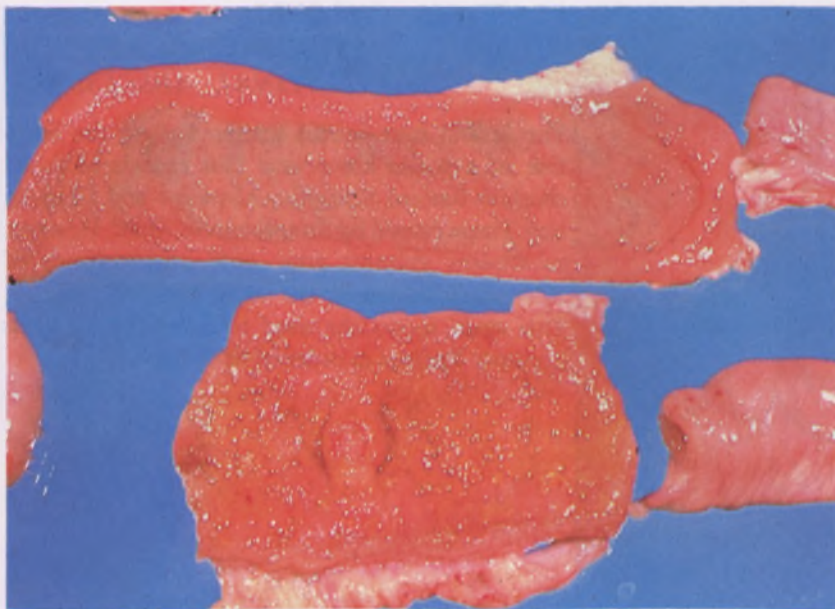
Dr. L. Roth Cornell, USA



**PLATE 637: JOHNE'S DISEASE
(PARATUBERCULOSIS)**

The darker small intestine in this goat is essentially normal but the paler small bowel, mostly ileum, is thickened as a result of *Mycobacterium paratuberculosis* infection, the cause of Johne's Disease. This goat had a history of intermittent diarrhea. Clumps of phagocytes filled with the organisms will be seen in the mucosa, lamina propria and submucosa in these cases. Acid fast organisms on the surface alone are not diagnostic. Regional nodes and even the liver may have the organisms present.

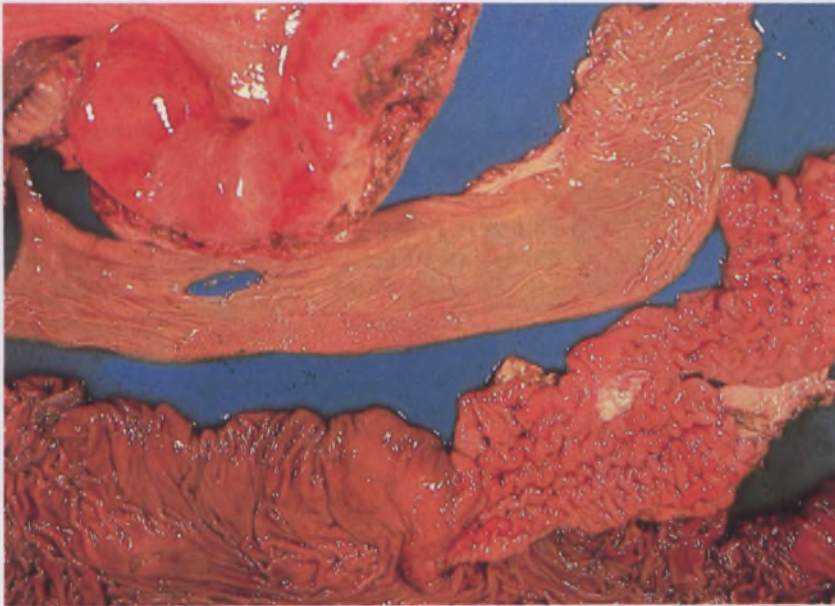
Dr. C. Buergelt, Florida, USA



**PLATE 638: JOHNE'S DISEASE
(PARATUBERCULOSIS)**

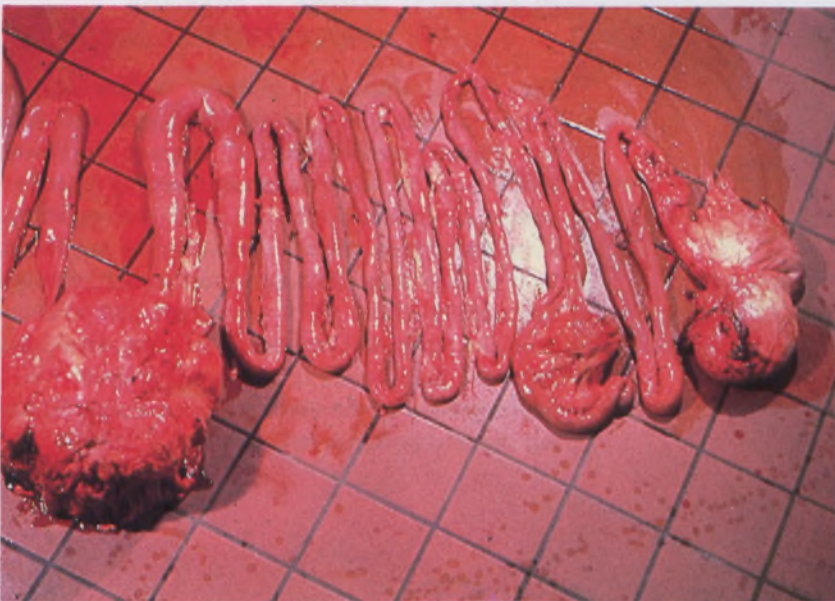The rough, thickened, granular surface of one section of this goat's intestine contrasts well with the thinner, smooth, normal segment of bowel. This is a case of Johne's Disease caused by *Mycobacterium paratuberculosis*, an acid fast organism. Sometimes these affected areas may be segmental. That is, they may affect one short section of bowel but slightly ahead of it or behind the affected areas the bowel will be normal. In cattle, especially, there are many cases of Johne's Disease in which mineralization of the aorta is a conspicuous finding but the relationship is not clear.

Dr. R. Chu, Taiwan, ROC



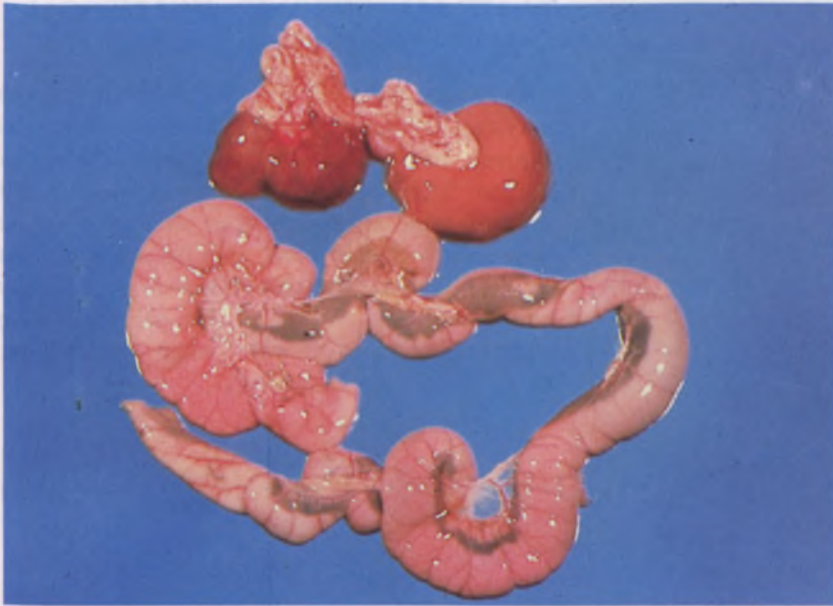
**PLATE 639: JOHNE'S DISEASE
(PARATUBERCULOSIS)**

The thickened corrugated mucosa of the ileum as it enters the cecum is typical for many of the cases of Johne's Disease of cattle and goats. It is to be contrasted with the normal, thin, pale section of small intestine next to it. It should also be noted that 50% of Johne's Disease (Paratuberculosis) cases caused by *Mycobacterium paratuberculosis* do not have gross lesions. The region of ileum and cecum shown are the areas of choice for biopsy specimen collection in such grossly negative cases, along with regional lymph nodes in order to find the causative acid fast organisms. Most clinically affected animals are debilitated from diarrhea.



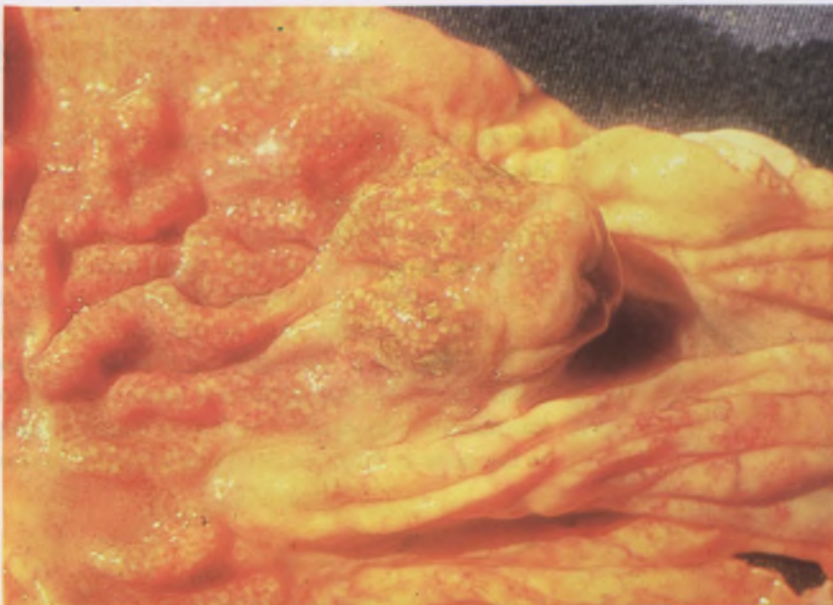
**PLATE 640: CHRONIC
ACTINOBACILLUS EQUULI
INTESTINAL ABSCESSES**

The several large masses scattered along the intestine of a young horse were first considered to be classical Bastard Strangles, Abscesses and Granulation Tissue caused by *Streptococcus equi*. However subsequent cultures grew only pure cultures of *Actinobacillus equuli*, the usual cause of Joint Ill. This again shows the need to follow up on gross necropsy findings in order to be definitive.



**PLATE 641: HYPERPLASTIC
INTESTINAL LYMPHOID
TISSUE**

The kidneys shown here from a freshly necropsied lamb are very soft and pulpy. Also shown are the dark areas of essentially normal bowel along the mesenteric attachment of the bowel, but the remaining three fourths of the circumference of the intestine is Hyperplastic Lymphoid Tissue of the bowel. This affects almost the entire segment of bowel present. The lamb also had excess fluid and fibrin in the heart sac. This is a case of Enterotoxemia caused by *Clostridium perfringens* type D. While the fluid and fibrin in the heart sac along with scattered ecchymoses in the gut are common findings in Enterotoxemia, Lymphoid Hyperplasia is not common. However, it is quite diagnostic as it is usually only seen in cases of Enterotoxemia.



**PLATE 642: MULTIFOCAL LYMPHOID
NECROSIS**

The small wrinkled nodule in the center is the protruding ileo-cecal opening of the ileum into the cecum of this pig. The cecum has been opened to show its mucosa with many normal 1-3mm pale foci of lymphoid tissue scattered in the mucosa including up and on the ileal papillary projection. In addition and also on the projection are several larger yellow round areas of necrosis of this lymphoid tissue. Most often *Salmonella* spp. can be isolated from these. This is a very common lesion even for essentially normal pigs.

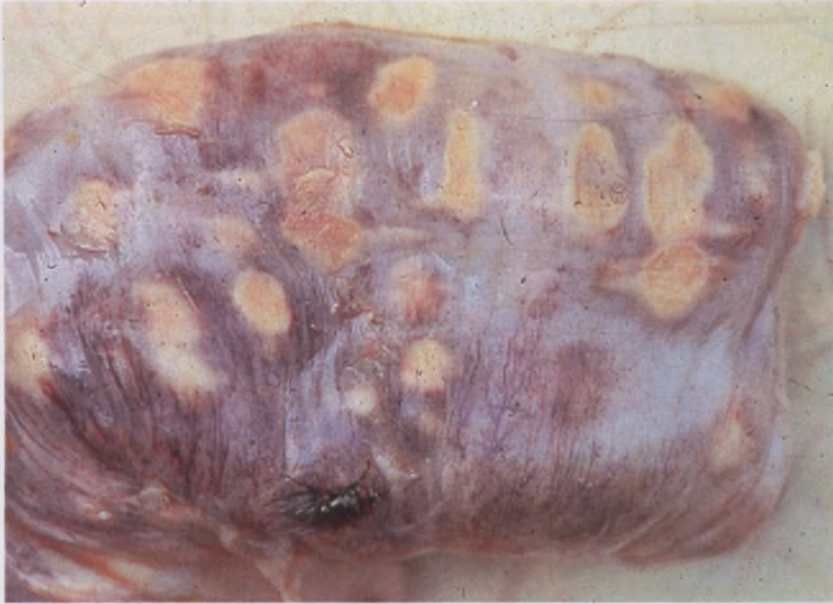

PLATE 643: CHRONIC MULTIFOCAL PURULENT ENTERITIS

The discrete yellow foci in the ileum of this cow are areas of deep necrosis that have penetrated through the wall to the peritonium in this case of Chronic Salmonellosis, caused by *Salmonella* spp. A whole herd of cattle was involved with sudden onset of diarrhea in most, with the death of seven or eight animals. The chronic nature of this lesion belies the acute nature of the outbreak. Many samples were taken of water, silage, grain etc. but the source was not ascertained.

Dr. R. Kahrs, Florida, USA

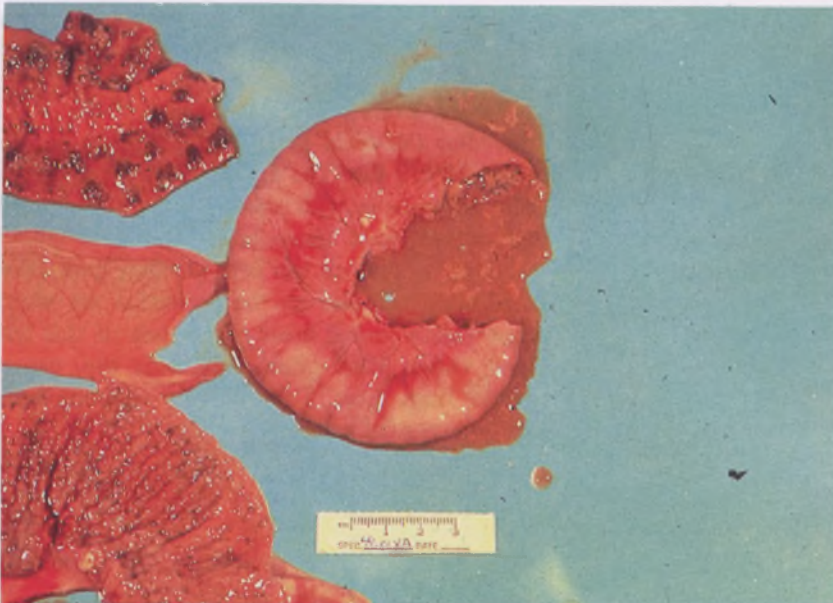

PLATE 644: SUBACUTE NECROTIC BACTERIAL (*SALMONELLA* SPP.) ENTERITIS

The thickened sections of bowel showing Multifocal Mucosal Necrosis in one, and a Diffuse Necrotic Enteritis in another, and the third unopened but showing the typical blood stained content with flecks of necrotic debris and fibrin coming from it, are the result of Subacute Salmonellosis associated with *Salmonella* spp. in this cow. The odor of a Septic Tank was also quite evident. These tissues are from one of several cattle with severe diarrhea prior to death. The lesions would roughly be the same in most species dying with this disease.

Dr. R. Kahrs, Florida, USA

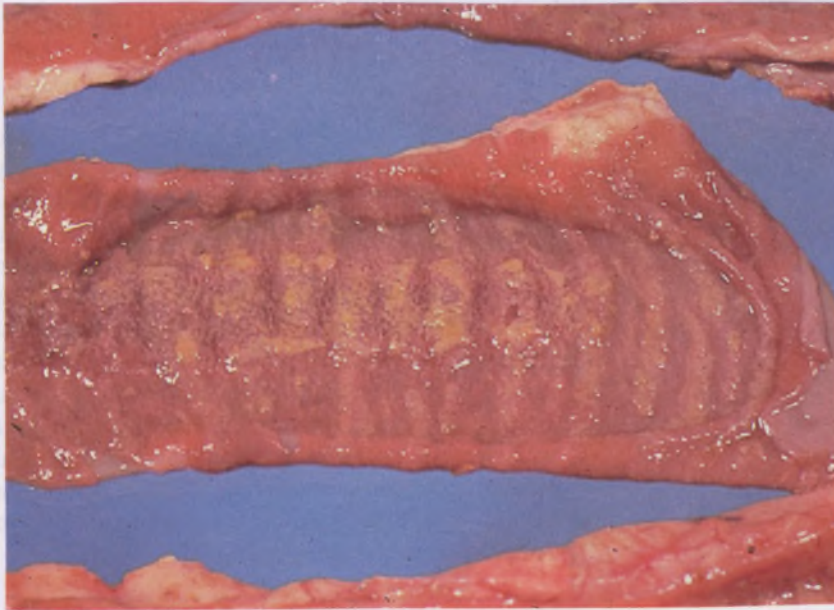


PLATE 645: ACUTE SALMONELLOSIS

The yellow necrotic debris on the mucosal surface of this Peyer's patch in the ileum is caused by *Salmonella* spp.. The cow was one of several to die with protracted diarrhea. The small bowel at necropsy was heavy and contained much fluid, specks of necrotic debris and had a definite Septic Tank Odor.

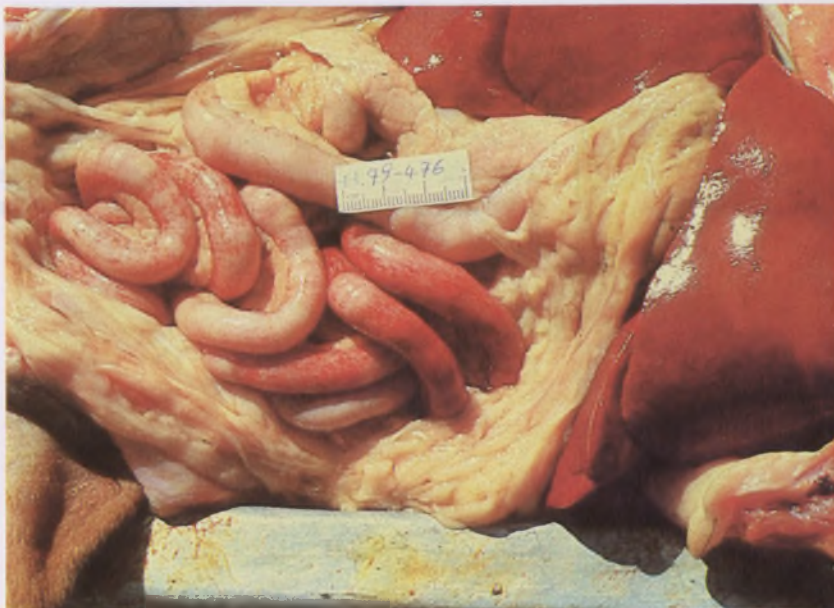
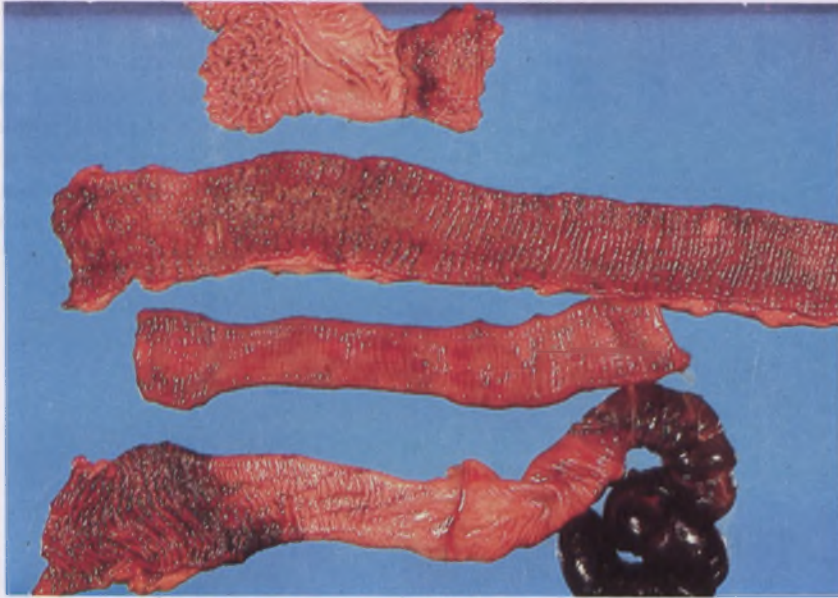
PLATE 646: CANINE PARVOVIRUS DISEASE

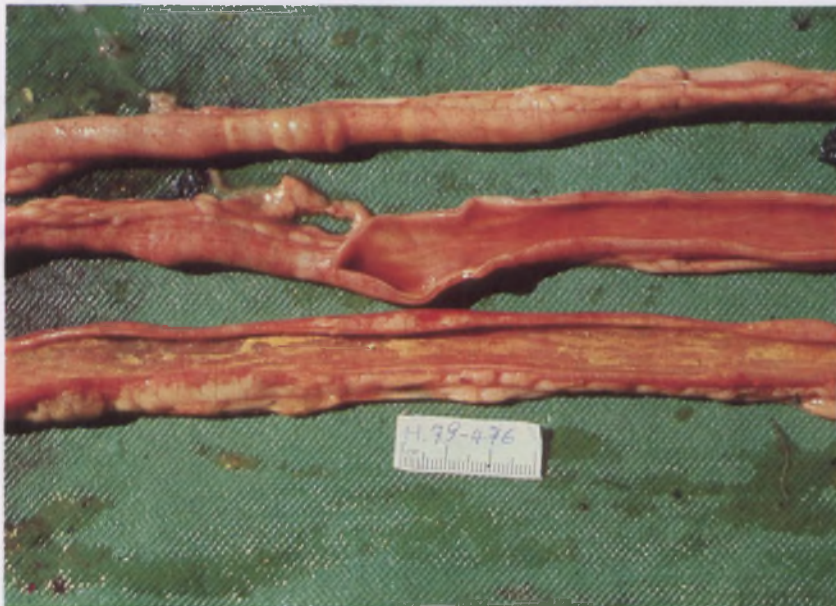The marked hemorrhages and fine granularity on the serosal surface of this dog's intestine are quite diagnostic for Canine Parvovirus Disease. Only in the last few years has this disease become prevalent and devastatingly so. Grossly and histologically it is similar to Feline Panleucopenia, another parvovirus disease.



Dr. B. Cooper, Cornell, USA

PLATE 647: CANINE PARVOVIRUS DISEASE AND INTUSSUSCEPTION

The major portion of this dog's bowel is affected with a severe viral enteritis caused by the relatively new Parvoviral Disease of Dogs (Canine Parvovirus Disease). In addition the distal end of the ileum is noticed as a very dark, red black rounded portion of bowel with some fibrin on its surface. This is an Intussusception caused by the Parvovirus Enteritis. Histologically, Canine Parvovirus Enteritis cannot be distinguished from Feline Panleucopenia, another parvovirus disease. It has dilated crypts with necrotic epithelial debris in them and epithelial loss and epithelial regeneration which appear as bizarre elongated epithelial cells attempting to re-epithelialize the mucosa.



Dr. R. Chu, Taiwan, ROC

PLATE 648: VIRAL (CANINE PARVOVIRUS) ENTERITIS

The thickened, congested bowel with yellow fibrinous debris attached to the mucosa of this dog's intestine is the result of Parvovirus Infection. Out of context, this could also be Panleucopenia in the cat, another parvovirus infection.

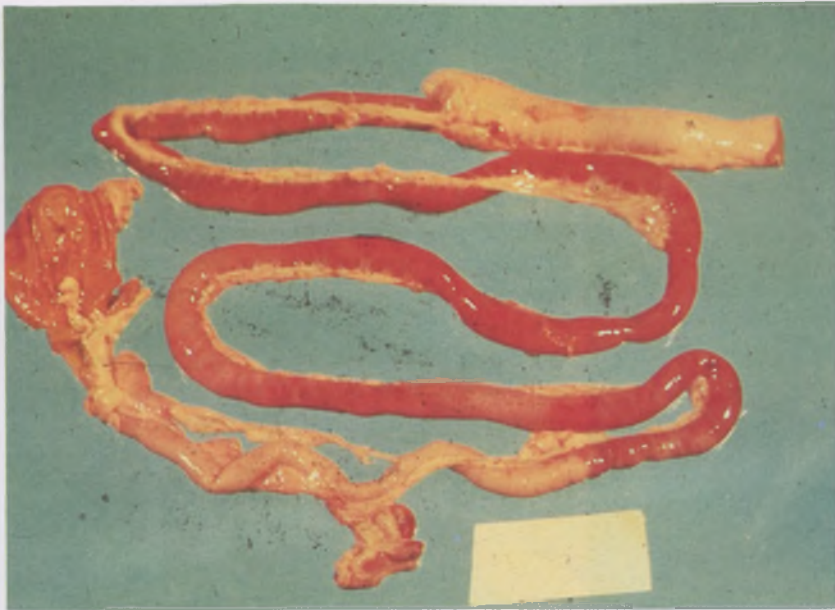


PLATE 649: PANLEUCOPENIA

The stomach and duodenum are essentially normal with the jejunum and ileum being distinctly congested. The bowel is also more flaccid than is normal for cats. The flaccid bowel and the segmental bowel lesion are diagnostic of Panleucopenia in cats. In some cases, it is only the duodenum, the jejunum or the ileum that may be involved. Its segmental nature is quite characteristic. This is a parvovirus disease.

Dr. R. Chu, Taiwan, ROC

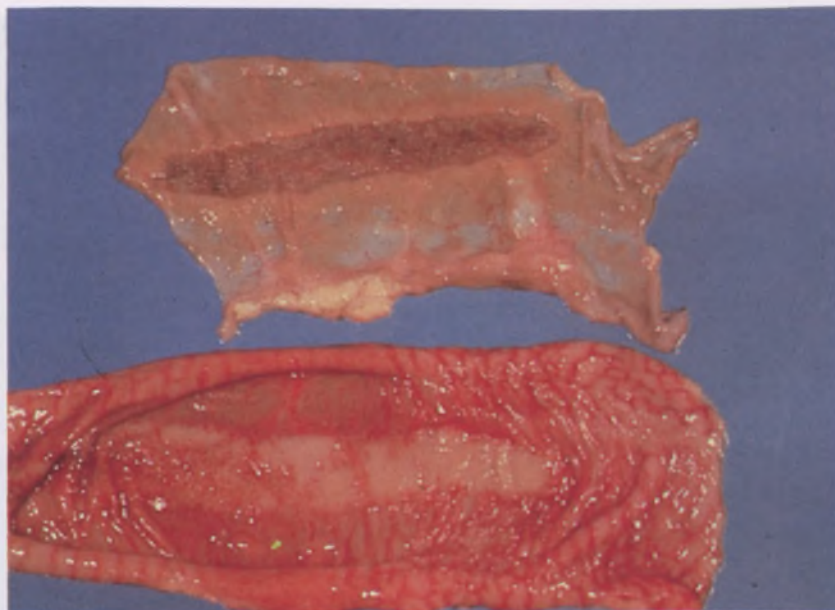


PLATE 650: LYMPHOID NECROSIS OF PEYER'S PATCH AND A NORMAL PEYER'S PATCH

The red bowel with the pale central patch is a normal cow's intestine with a normal Peyer's patch in the center. The other section of bowel is from a cow with Virus Diarrhea and it shows a Peyer's patch which appears finely granular but is definitely sunken below the gut surface. This is due to the marked necrosis and loss of lymphoid tissue seen in some cases of Bovine Virus Diarrhea. A more common lesion of Peyer's patch is necrotic debris attached to the surface.

Dr. L. Roth, Oklahoma, USA

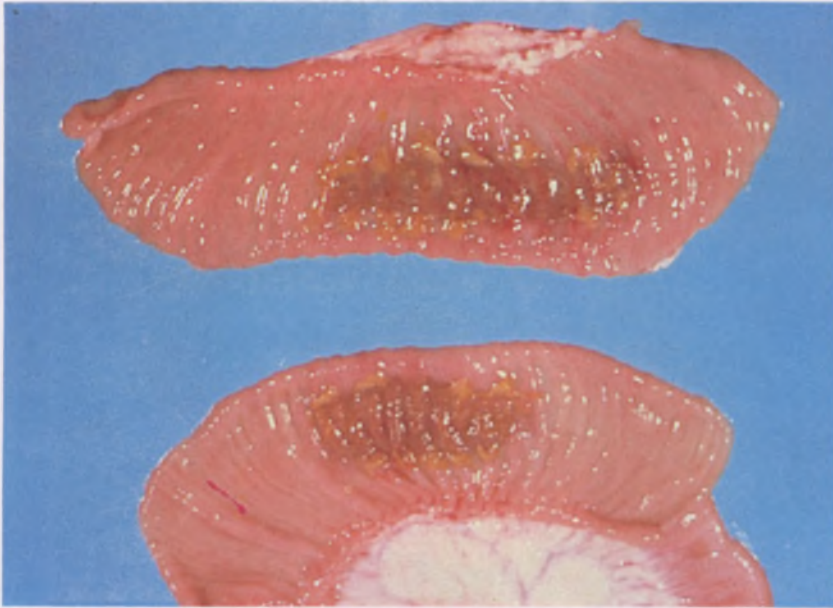

PLATE 651: NECROSIS OF PEYER'S PATCHES

The two Peyer's patches in this cow with Bovine Virus Diarrhea (BVD) show the yellow necrotic debris mostly at its edges and the mottled congested BVD. Most Peyer's patches are located in the lower small intestine primarily the ileum which may have a single patch running its entire length along its anti-mesenteric side. We have seen several case of BVD in which only one Peyer's patch in the duodenum had diagnostic lesions. This is from a 16 weeks old calf which is quite unusual, as cattle this young are not commonly affected by this disease.

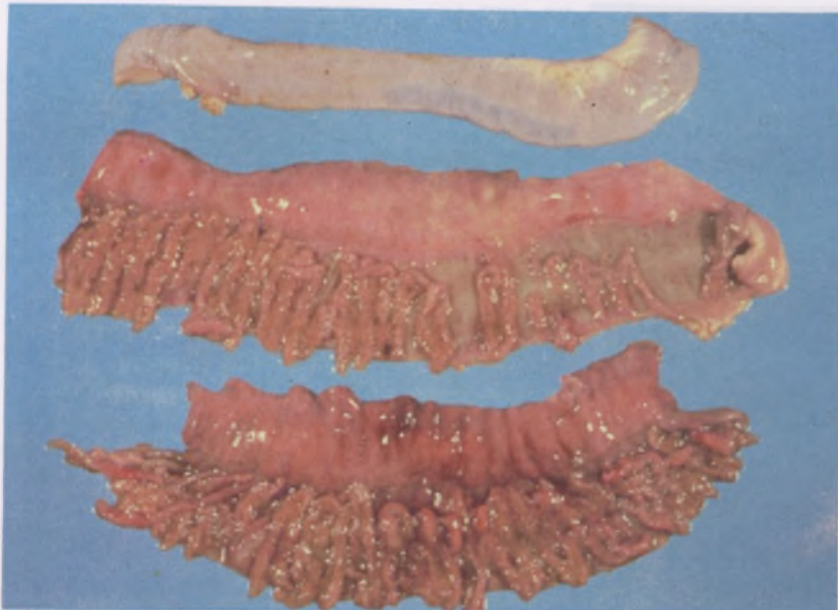

PLATE 652: NECROSIS OF PEYER'S PATCHES

Three segments of a cow's intestine with Bovine Virus Diarrhea (BVD) are shown. All have a Peyer's patch present in them. The two opened segments show the necrotic debris, limited to the Peyer's patches which make up 75% of the mucosal surface in these areas. The unopened segment of bowel shows a darkened Peyer's patch through the serosal and muscle layers. Lesions like this make the diagnosis of BVD quite easy, but they all are not so salient.

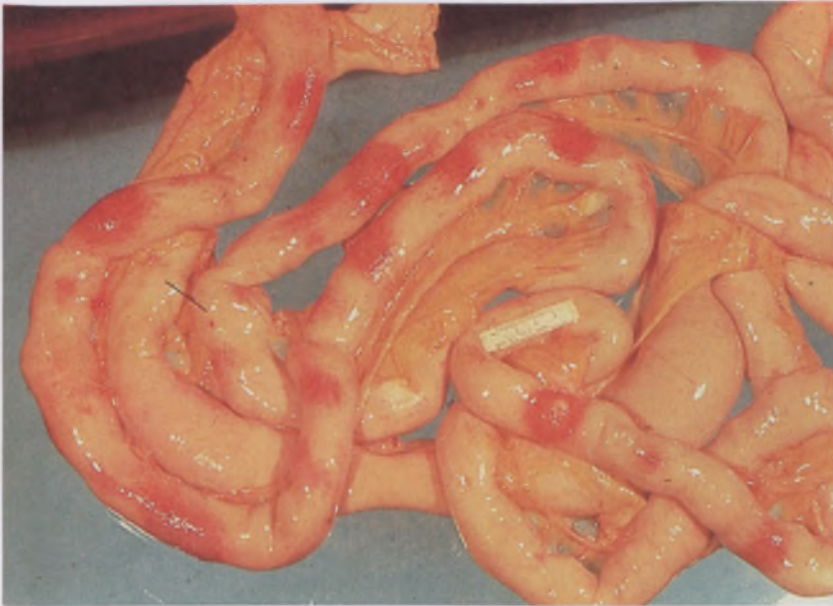


PLATE 653: CHRONIC GRANULOMATOUS ENTERITIS

The entire small intestine is thickened. Scattered throughout the serosa are multiple, fairly discrete, slightly elevated patches of congested serosa. The mucosa is thickened and coarsely granular. Histologically, the thickening of the bowel is due to a marked invasion of the mucosa, to a lesser extent the muscle coats, and these focal areas of the serosa by mononuclear inflammatory cells, mostly monocytes, plasma cells and lymphocytes. This disease of Chronic Granulomatous Enteritis in horses results in diarrhea and, often a protein losing enteropathy. The cause is not known. The cellular response in the bowel causes some to consider that this may be a form of Lymphosarcoma especially in the way the cells invade and penetrate the muscle cells and serosa locally.

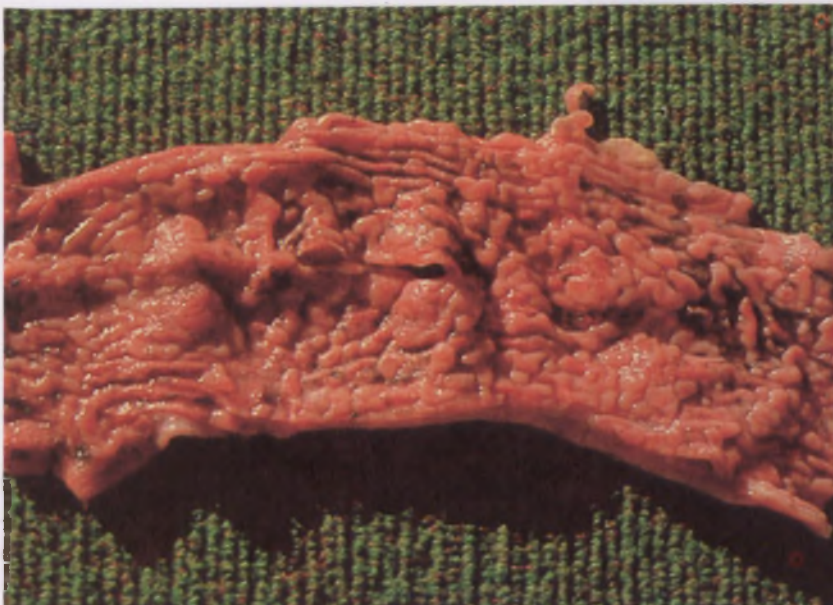


PLATE 654: CHRONIC GRANULOMATOUS ENTERITIS

The marked thickened irregular folds of this mucosa in a horse's small intestine are the result of Chronic Granulomatous Enteritis. Most of these horses have chronic diarrhea. The cause for this disease is not known although acid fast organisms were found in a recently reported case. Histologically, monocytes, plasma cells and lymphoid cells predominate in the inflammatory cell population.

Small Intestine

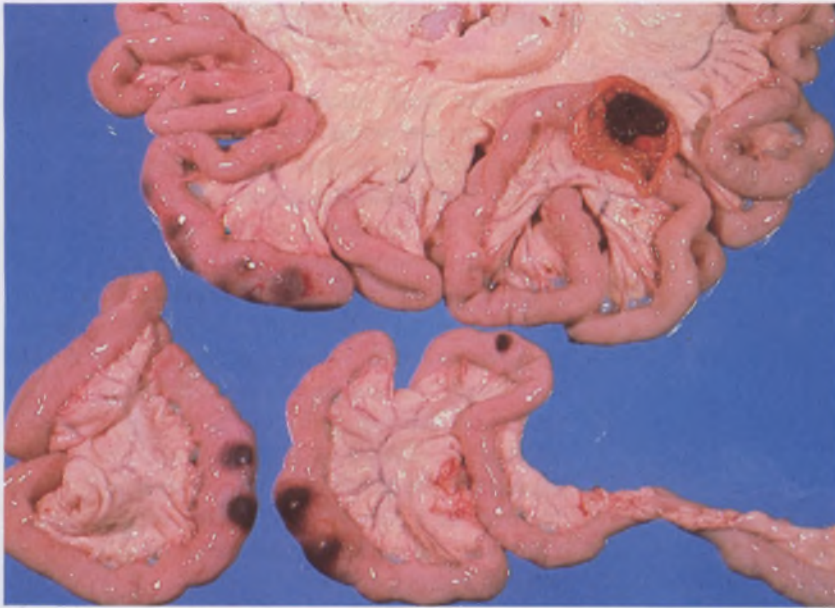

PLATE 655: MYCOTIC ULCERS

The multiple hemorrhagic foci in the small intestine of a cow are classical Mycotic Ulcers. In this case they are secondary to a severe Toxic Rumenitis from overeating but in younger animals they are often associated with excess antibiotic therapy.

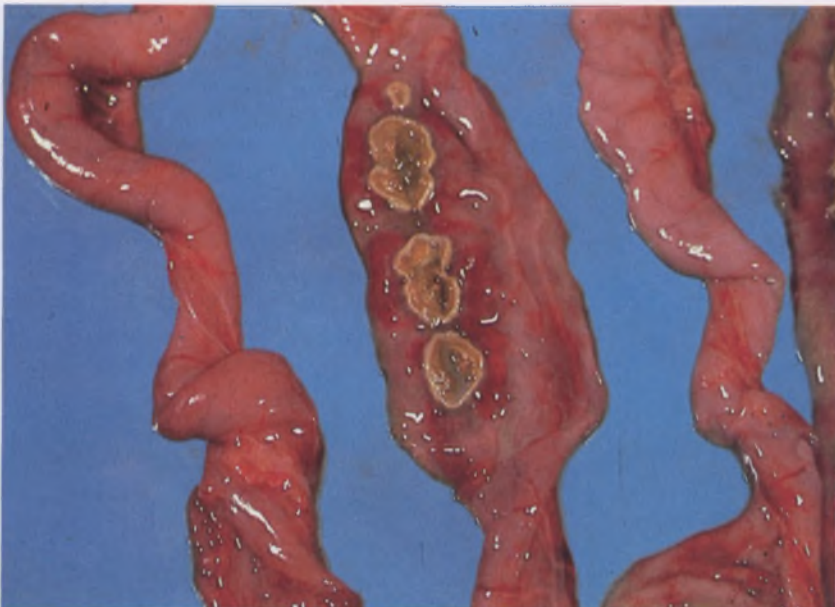


PLATE 656: MYCOTIC ULCERS

The orange, pale bordered plaques on the mucosa of this calf's small intestine are Mycotic Ulcers, caused by *Aspergillus* spp. usually. Most often they are associated with antibiotic use, either for therapy or prevention. They can be seen in any species of animal but usually young ones.

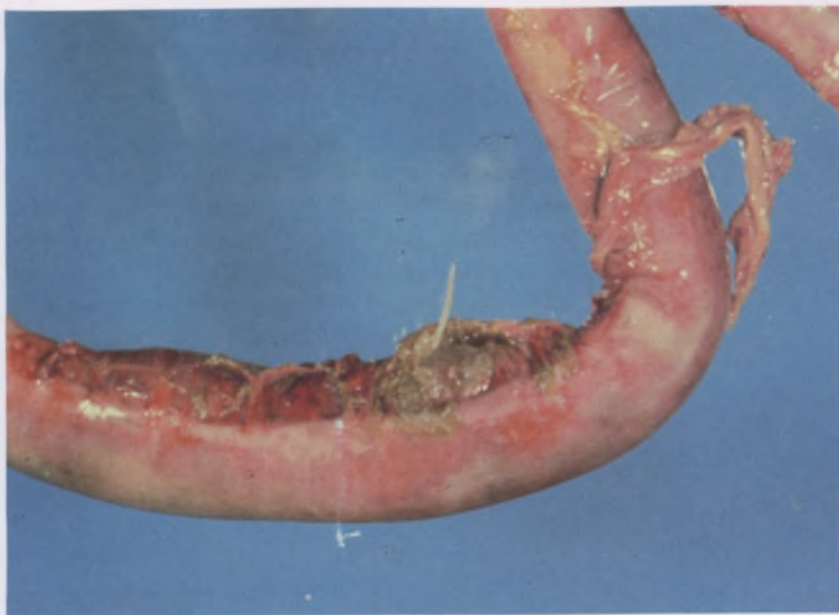

PLATE 657: PERFORATING LINEAR FRICTION ULCER AND LINEAR FOREIGN BODY (*PARASCARIS EQUORUM*)

The horse intestine shown here has a hemorrhagic ulcer along its mesenteric border that has perforated. The causative agent, adult *Parascaris equorum* can be partially seen. This is a Perforating Linear Friction Ulcer caused by the presence of many of these parasites in the lumen which mechanically result in the ulcer. String and other linear foreign bodies can cause the lesion quite easily especially in cats.

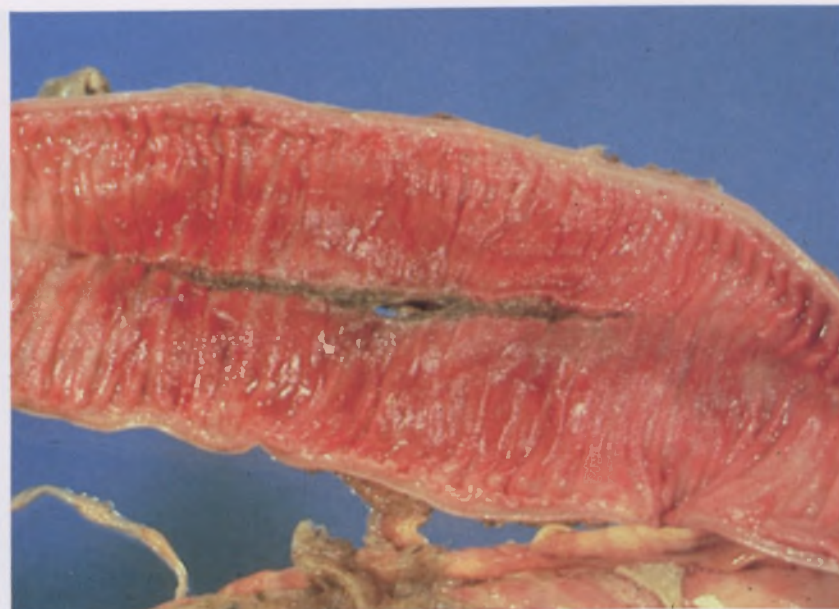
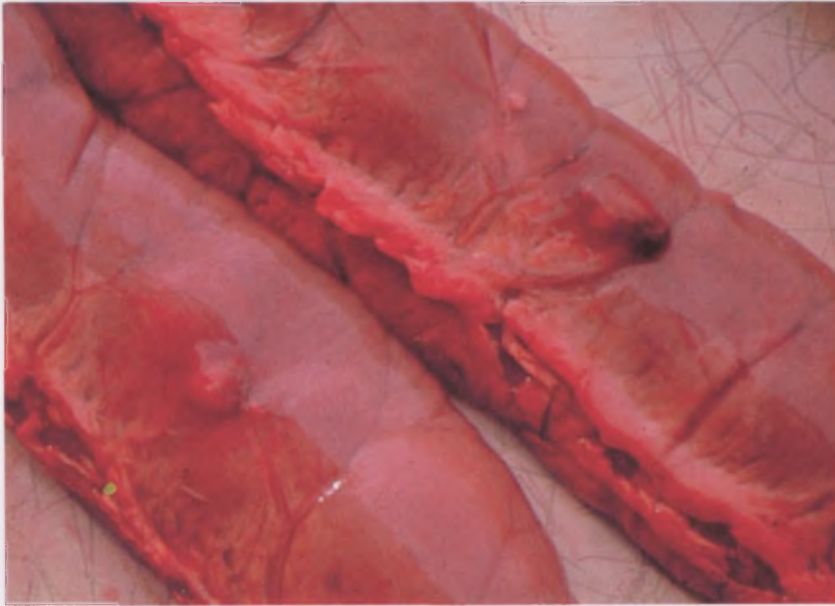


PLATE 658: LINEAR FRICTION ULCER WITH PERFORATION

This is the mucosal surface of the small intestine of a horse showing a Linear Friction Ulcer with a small perforation in its center. These are always located on the mesenteric border of the gut and can be caused by any linear foreign body such as string. In this case, it was due to a mass of ascarids, *Parascaris equorum*. A single ascarid couldn't cause this. Most linear foreign bodies must be anchored for peristalsis to allow the gut to rub on the foreign body. A mass of these parasites while not anchored as such do resist peristalsis else all would be found in the colon and in this way are stationary enough to cause the lesion.



**PLATE 659: NODULAR WORM
(*ESOPHAGOSTOMUM SPP.*)
DISEASE**

The two large, red foci and several smaller paler ones are the result of nodular worm disease in this cow, caused by *Esophagostomum radiatum*. Similar lesions and even more of them are often seen in sheep and swine by other species of *Esophagostomum* spp. They often make focal necrotic areas in lymph nodes as well. In sheep they are so numerous sometimes that one wonders how the bowel functions with such heavy infection.



**PLATE 660: MULTIFOCAL MUCOSAL
PARASITIC HYPERPLASIA
(COCCIDIOSIS)**

The marked granular appearance of the mucosa in this goat is caused by the Mucosal Hyperplasia associated with Coccidiosis in this case *Eimeria arloingi*. As in the biliary epithelium the presence of these protozoal parasites stimulate a marked epithelial hyperplasia. This is an exceptional case as often fatal cases of Coccidiosis may have minimal gross lesions.

Dr. J. Whitlock, Cornell, USA

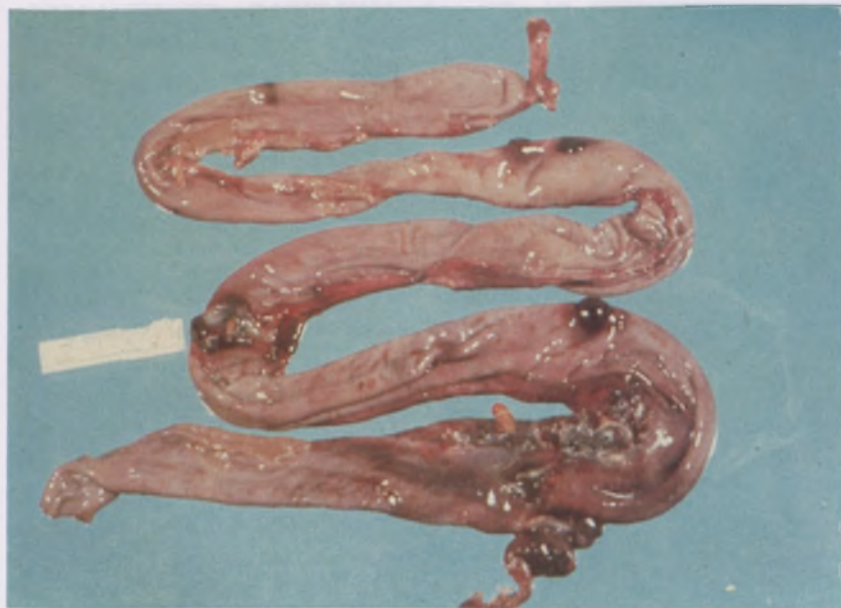

PLATE 661: MULTIFOCAL PERFORATING PARASITIC ULCERS

The multiple bloody foci and perforated ulcers in this horse's intestine are the result of horse bot larvae penetration through the intestinal wall. Normally, the bots are found in the stomach, but when found in aberrant locations such as this, one will usually find that the horse has been given large doses of corticosteroids that in some way interfere with the normal response of the host.

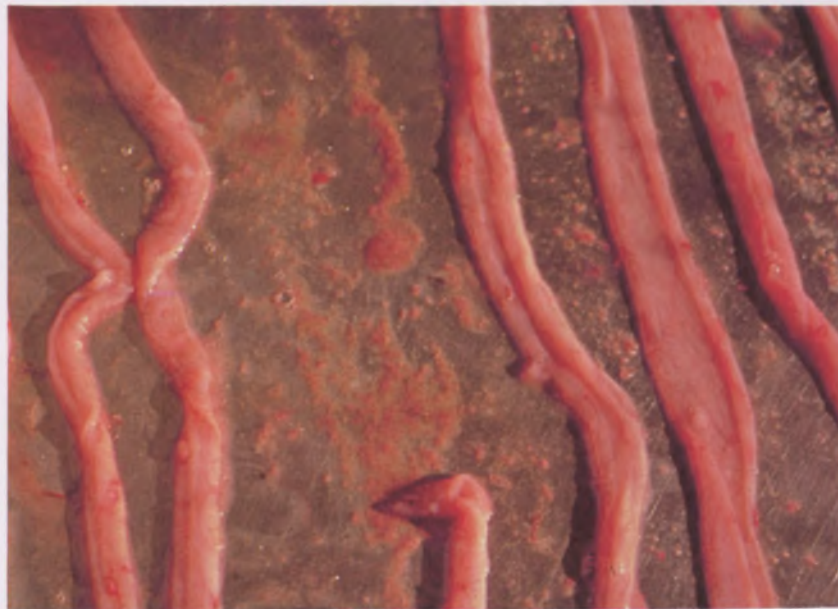
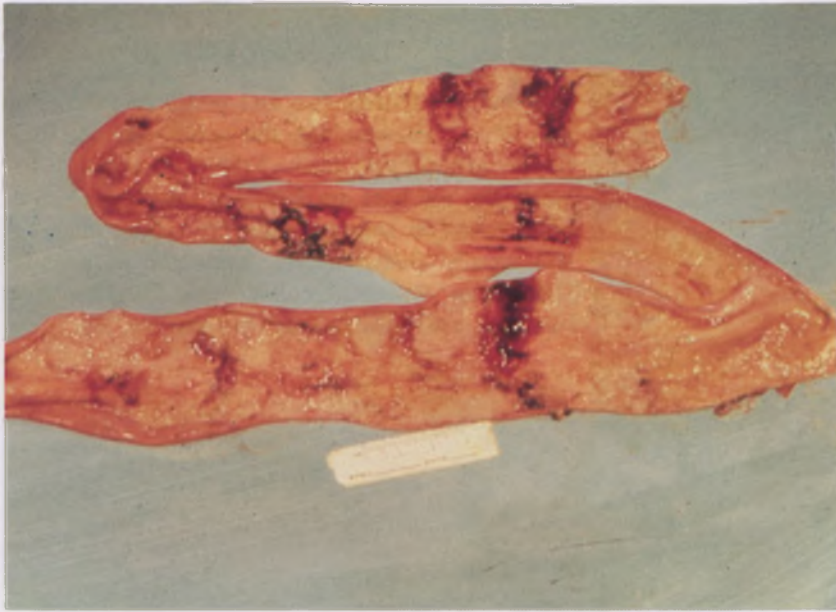


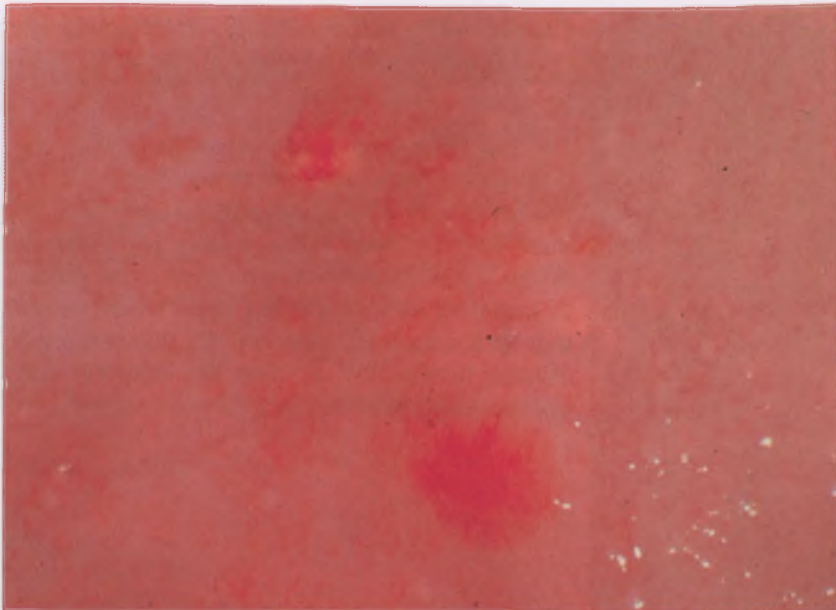
PLATE 662: MIGRATING RUMEN FLUKES (PARAMPHISTOMUM CERV)

This gut came from a debilitated sheep with diarrhea. This is the small bowel and shows the massive number of tiny dots of material that came from the small bowel. These 1-2 mm dots are immature rumen flukes, *Paramphistomum cervi*, in the process of migrating back up the G.I. tract to the rumen. It is in the small intestine like this that they cause damage to the host as they are relatively non-pathogenic in the rumen.



**PLATE 663: MULTIPLE ECCHYMOSES
AND HOOKWORMS
(*ANCYLOSTOMA
CANINUM*)**

The multiple bloody foci, Ecchymoses, scattered in the mucus and debris on the surface of this dog's bowel are caused by multiple Hookworms, *Ancylostoma caninum*. A few of them can be seen in the hemorrhagic areas. The yellow thick material on the surface of the mucosa is just mucus, debris and bile pigment. It is often mistaken for catarrhal enteritis but it can be scraped off easily and it is usually not pathological. There is no inflammation associated with most of it, although in this case there is the incidental hemorrhage associated with the hookworms. The intestinal epithelium continues to produce this material even after death and even more so when in contact with moisture. There are not many other causes of these focal hemorrhages in animals.



**PLATE 664: HOOKWORM ATTACH-
MENT SITES**

The larger red and white foci in the mucosa of this goat's intestine are the focal attachment sites, called Hookworm Hickies in the vernacular, of the hookworm, *Bunostomum trigonocephalum*. Often the worm has an anticoagulant, hirudin, in its saliva to help make blood sucking easier. This allows these sites to continue to bleed for sometime after the worm has moved to another area. This is well noticed in the dog, and the hemorrhagic foci are often described while the parasites themselves are missed by the prosector.

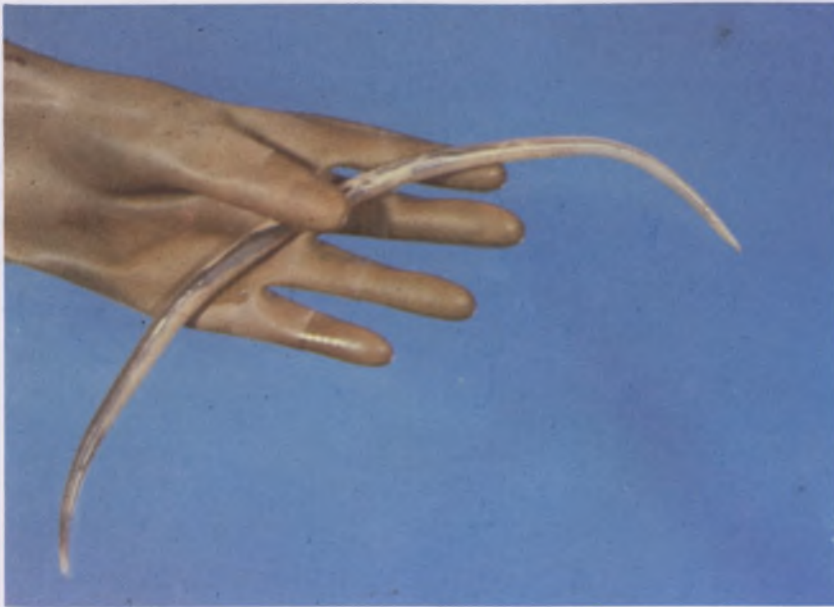

PLATE 665: *PARASCARIS EQUORUM*

This is an adult *Parascaris equorum*, the horse ascarid. It is a large worm as shown in comparison to a hand, and for this reason it probably came from a large horse. It came from an adult Belgian work horse. Everything else being equal, the rough approximation of parasite size is proportional to the host's size.

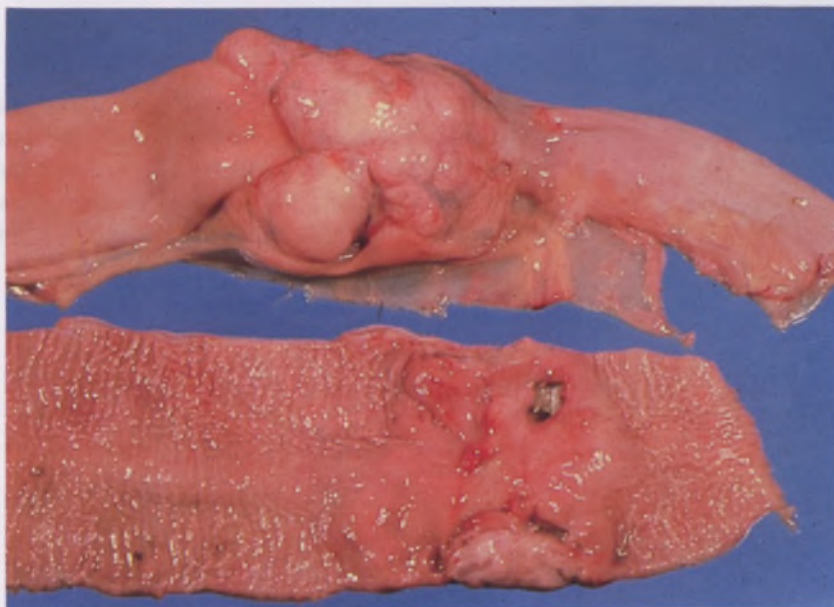
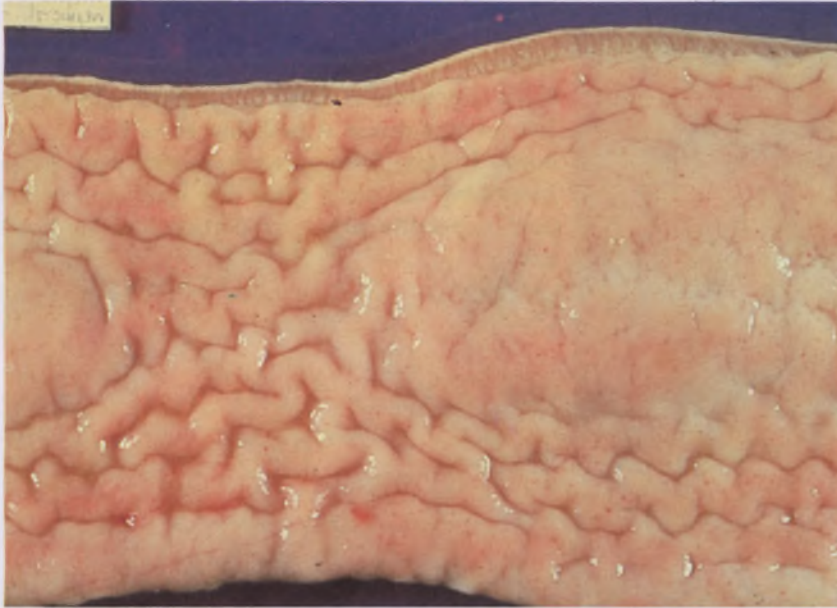


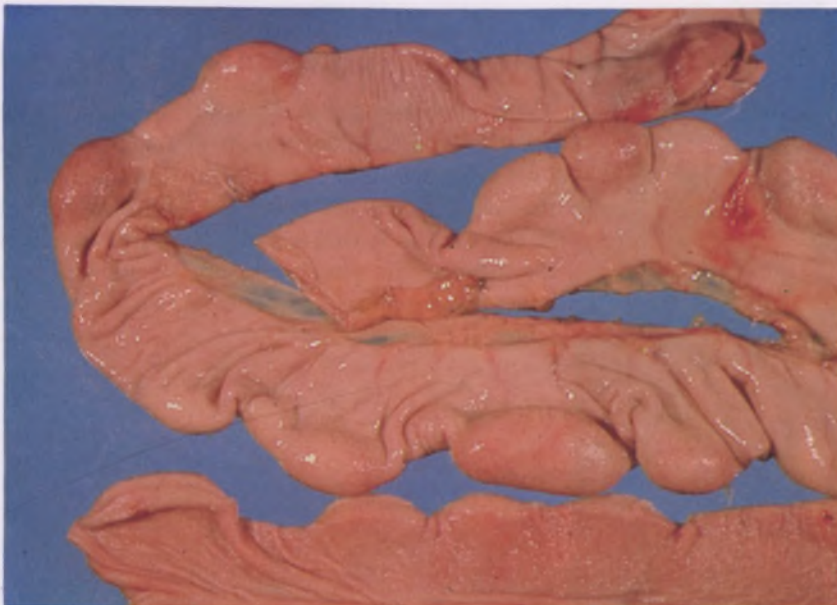PLATE 666: NEOPLASTIC (LYMPHO-SARCOMA) ULCERATION

These two irregular knobby masses in the small intestine of a horse are nodules of Lymphosarcoma. Two crater like ulcers are present in the mucosa of the one segment cut open, and tumor infiltration in the mucosa is well marked. Ulcerated tumors in the intestine are usually carcinomas, not sarcomas, unless the sarcomas happen to be constricting the lumen as this one did.



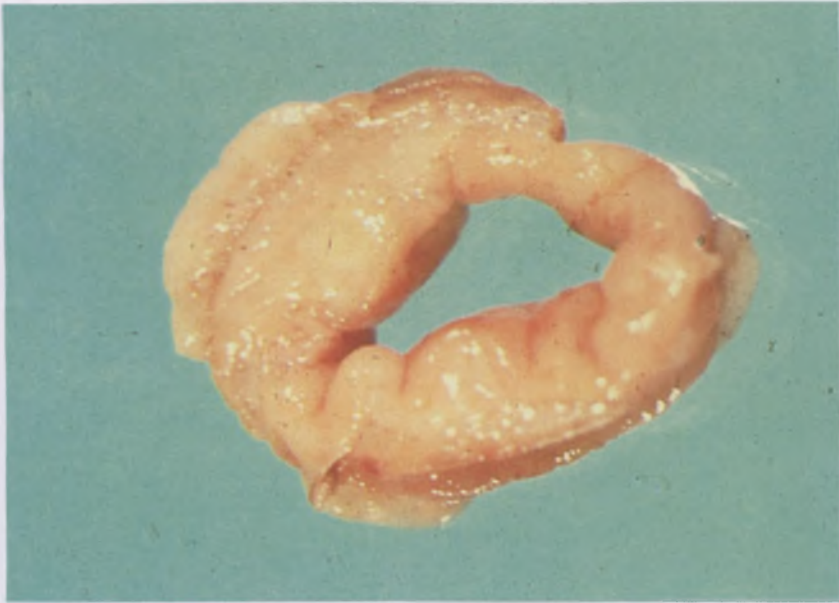**PLATE 667: *INTESTINAL
LYMPHOSARCOMA***

The thickened corrugated mucosa of this horse's intestine and the enlarged smoother areas of Peyer's patches are the result of neoplastic infiltration by lymphoid cells, in this case of Lymphosarcoma. Chronic Granulomatous Enteritis in the horse would look somewhat similar, and histological studies would be needed to be definitive.



**PLATE 668: *INTESTINAL
LYMPHOSARCOMA***

In this case of Lymphosarcoma in a horse, the malignant lymphocytes have formed discrete nodules in the wall, with bulging of the serosa and even a fine granularity of the serosa in these areas, from tumor cell infiltration. The mucosa of the bowel is essentially normal.



Dr. D. C. Doid, New Zealand

**PLATE 669: *INTESTINAL
LYMPHOSARCOMA***

This cross section of a horse's small intestine shows the well marked thickening of the mucosa with malignant lymphoid cells in this case of Lymphosarcoma. Also to be noted is that in the region of a Peyer's patch, the malignant lymphocytes have invaded through the muscle coat to form a definite plaque on the serosa.

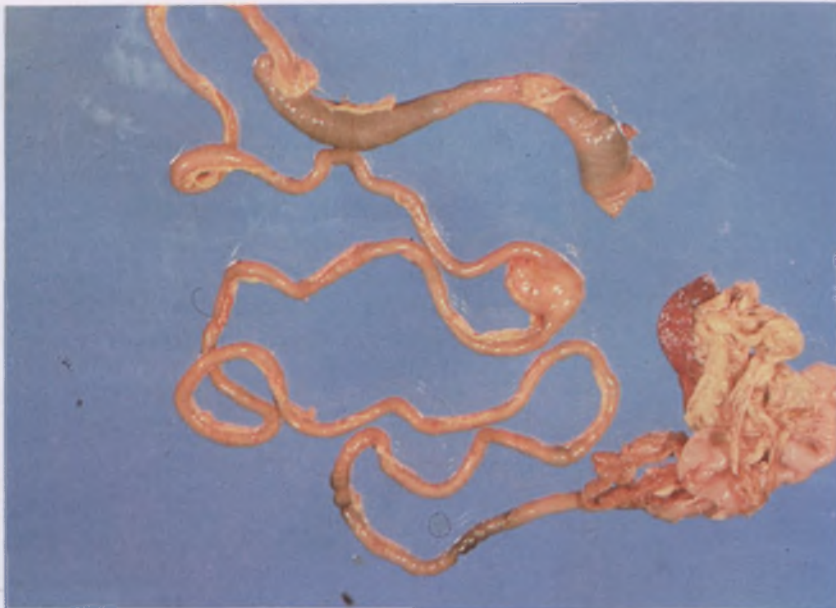

PLATE 670: *MAST CELL TUMOR*

The single large mass in the approximate middle portion of this cat's intestine is a Mast Cell Tumor. Such solitary tumors were once considered to be, almost invariable, Carcinoids, but it is now known that they may be almost any neoplasm including the above, Lymphosarcoma and others. Histological study, often with special stains, is often necessary to be definitive. Mast cell tumors can be benign, especially if on the skin, but when in the mouth or on the scrotum they are often malignant.

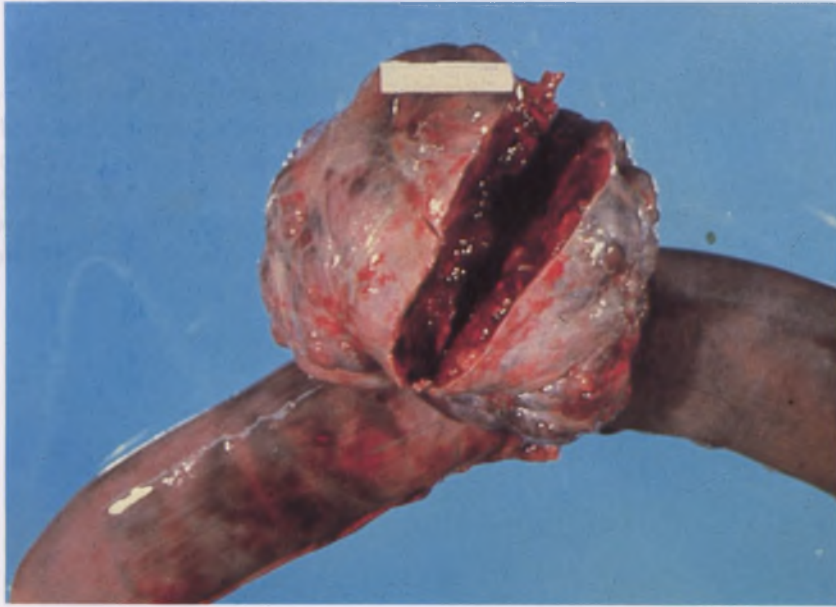
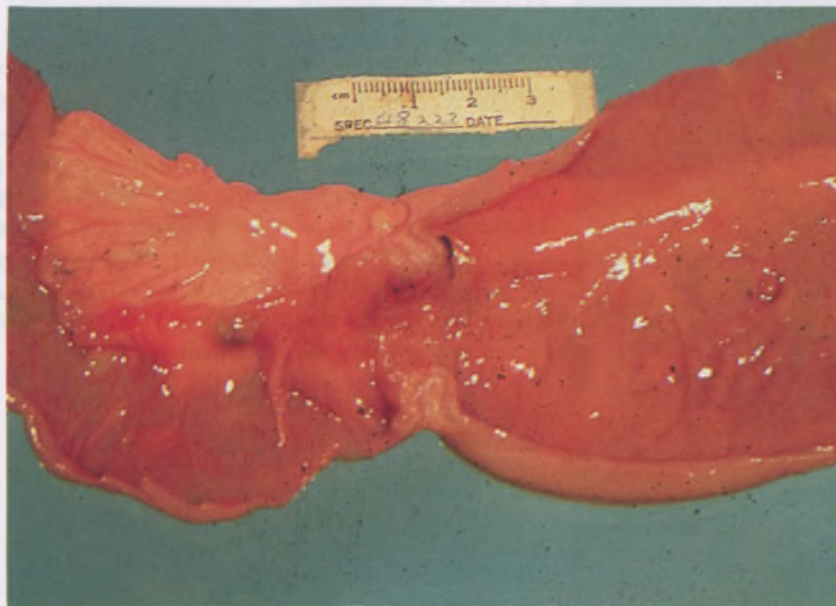


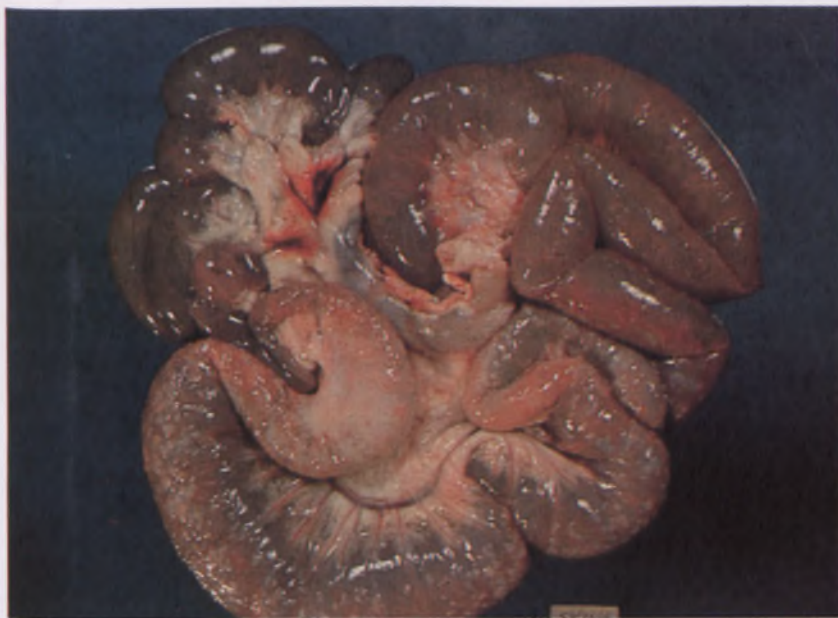PLATE 671: HEMANGIOSARCOMA

The large bloody mass attached to the equally dark small intestine of a horse is a Hemangiosarcoma. It was primary at this site. The gut is dark as a result of strangulation caused by this mass helping to pull the gut around other portions of bowel and mesentery and thus strangulate itself.



**PLATE 672: INTESTINAL
ADENOCARCINOMA AND
ANNULAR CONSTRICTION**

The definite hourglass constriction of the intestine in this sheep without much reaction about it is the result of a Constricting Intestinal Adenocarcinoma. This Annular Constriction is a common result of such a tumor more so than any other tumor. It often necessitates taking several sections of the area for histological proof of the tumor's presence.



Dr. D. C. Dodd, New Zealand

PLATE 673: INTESTINAL ADENOCARCINOMA OF SHEEP

The dilated bowel and the large number of small white foci in the wall of this bowel, almost limited to the antimesenteric border, are due to a massive number of malignant glandular epithelial cells, in this Intestinal Adenocarcinoma of a sheep. The cause of most tumors is not known as yet, but it is of interest that these occur in certain areas and in certain flocks in relatively large numbers, and are rarely seen in other locations or flocks.

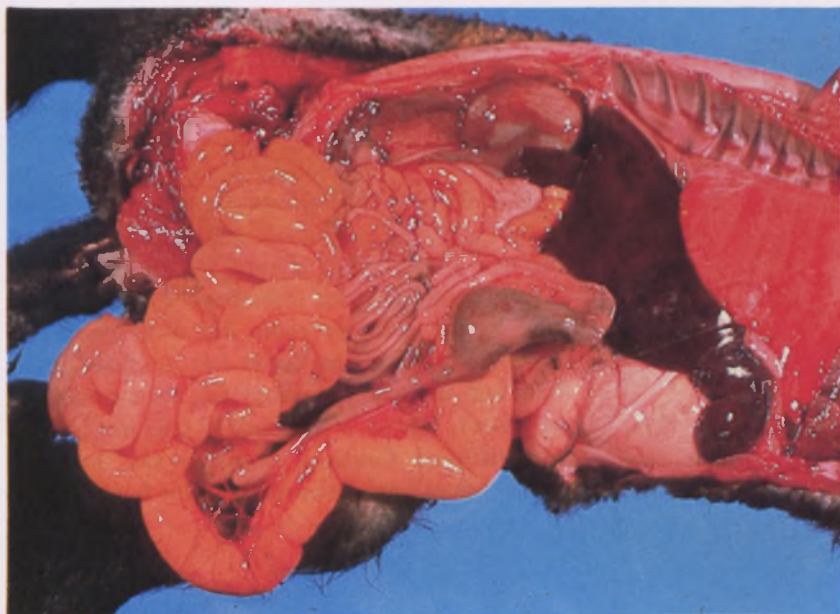
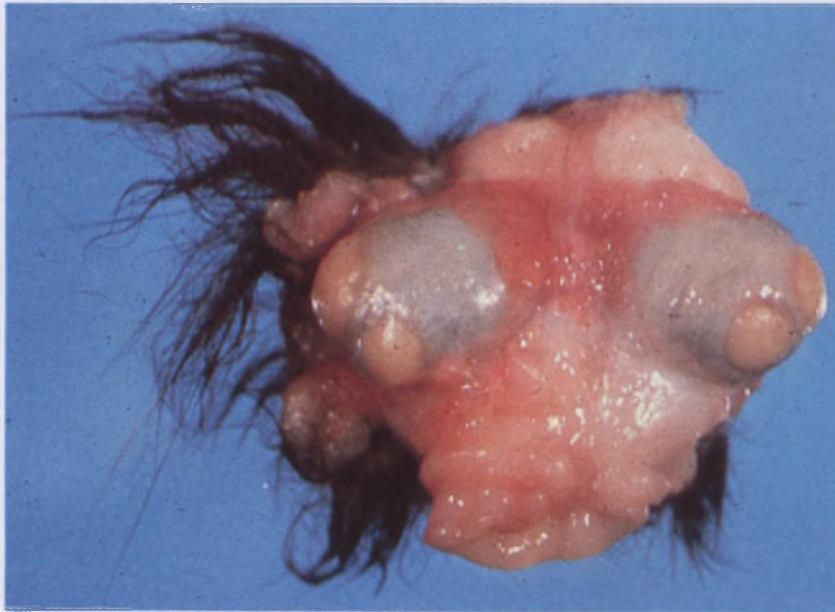

PLATE 674: MECONIUM ILEUS

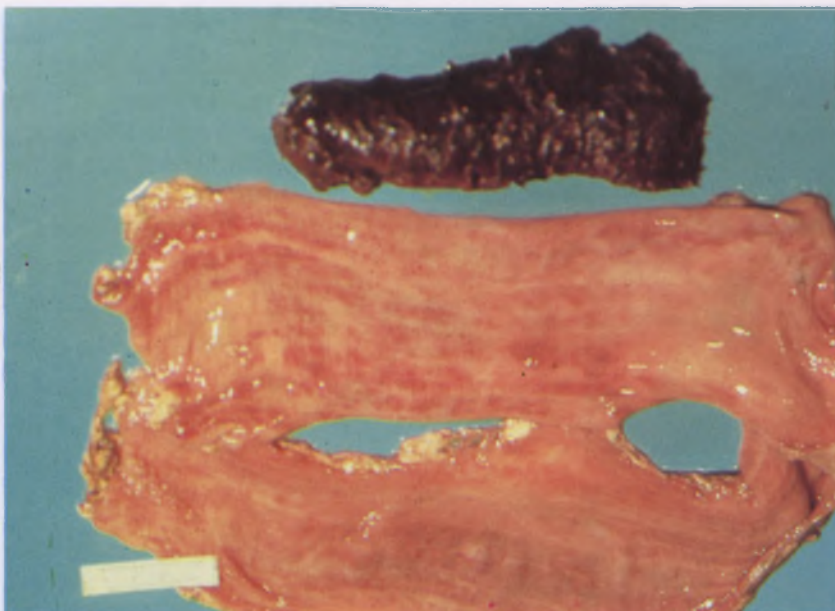
This several days old lamb died as a result of the Meconium Plug causing ileus. This problem is far more common in foals. A specific cause is unknown. The dark meconium plug can be seen just at the ileocecal junction.



**PLATE 675: NORMAL ANAL SACS
AND ANAL SAC GLANDS**

The two blue masses around this cat's anus are the Anal Sacs and on each of these are two tan masses, the Anal Sac Glands. These Anal Sacs may give rise to Squamous Cell Carcinomas (relatively rare in this location) in older animals, while the Anal Sac Glands are rather commonly the site for Anal Sac Gland Adenocarcinomas. Most of these latter tumors metastasize to regional nodes, and can cause a Pseudohyperparathyroidism, with resultant elevations of blood calcium with soft tissue calcification. These normal structures and their related tumors are also seen in other animals.

Dr. D. C. Dodd, New Zealand



**PLATE 676: POST SURGICAL COLONIC
HEMORRHAGE**

The lack of specific lesions in the colon of this dog, plus the large blood clot found there are quite characteristic of a relatively new problem of Post Surgical Colonic Hemorrhage. This is seen in other animals such as cats, cattle and horses. The first case was recognized in a horse which had been on the operating table for several hours. It was taken back to the recovery room but died there with severe anemia and the colon full of blood, both fluid and clotted. No cause for the hemorrhage was found. Edema of the wall as seen in Colitis X or Exhaustion Colitis is not seen and Colitis X does not have frank hemorrhage in the lumen.

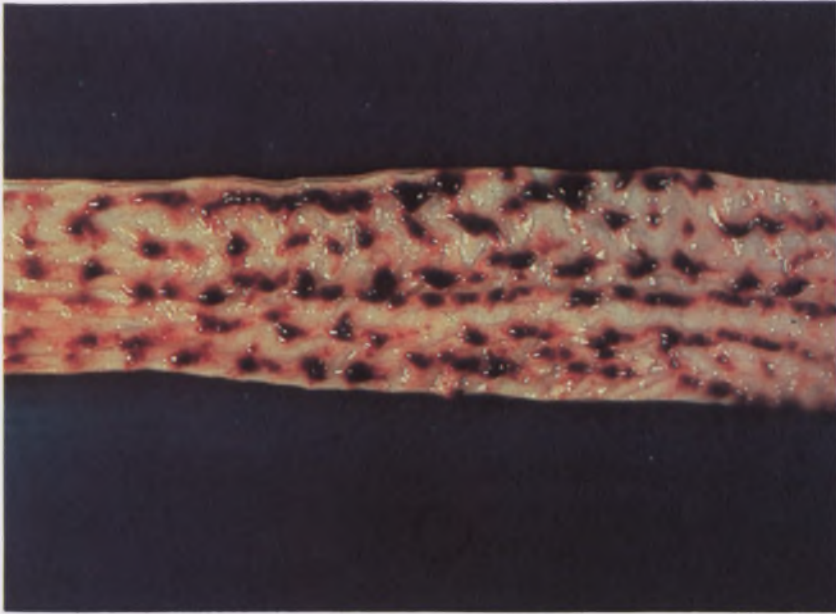

PLATE 677: MUCOSAL TIGER STRIPING OF THE COLON

The severe congestive striping of the colon of this dog is the result of colonic spasm with the trapping of blood in the tips of the mucosal folds. This is a very nonspecific lesion and can be seen in many animals just as a terminal event. It is common enough in some diseases to make the prosector note the finding such as in Rinderpest, but it is really just a functional "lesion". It may be more outstanding under some conditions than others, as in this case of Estrogen Poisoning.

Dr. K. McEntee, Illinois, USA

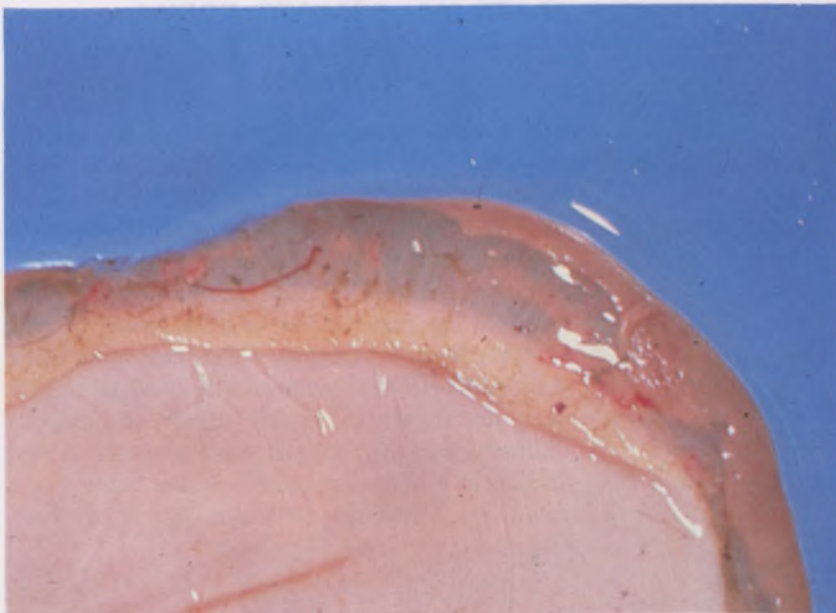


PLATE 678: HYPOPROTEINEMIC EDEMA

This section of horse colon is markedly edematous as the result of protein deficiency. The relative lack of colloid osmotic pressure has allowed the blood serum to stay in the colonic tissues as tissue fluid. The actual reason why it stays in the colon more than other tissues is not known.

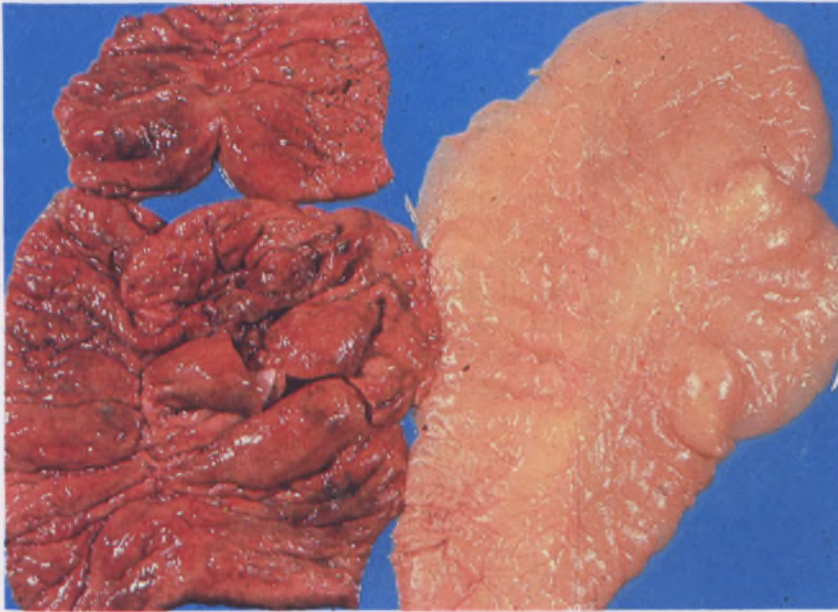
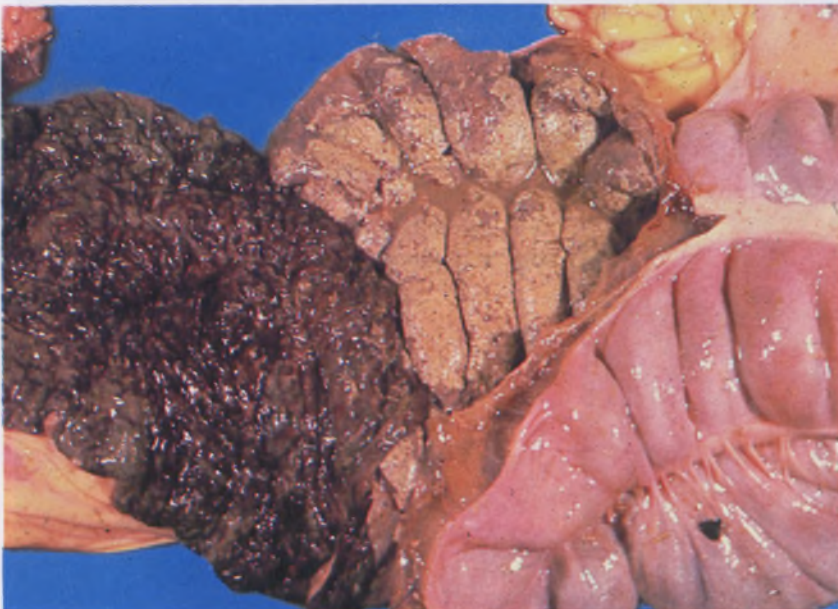


PLATE 679: COLONIC EDEMA

The two horse colon sections shown here are markedly edematous. The pale one is from a horse dying of Hypoproteinemia from chronic hemorrhage and the other is an example of Colitis X or Exhaustion Colitis. Chronic Protein Deficiency could also make the pale form of edema.

Dr. K. McEwen, Illinois, USA



**PLATE 680: COLONIC EDEMA
(COLITIS X, EXHAUSTION
COLITIS)**

The massive Edema of this horse's colon is quite diagnostic for Colitis X or Exhaustion Colitis caused by severe stress, as in heavy prolonged work or shipping. The animals usually but not always have an acute, severe diarrhea after the period of stress, and they die rapidly in a matter of hours. This case also has some surface necrotic debris on part of the edematous mucosa which can cause some confusion with Salmonellosis. Salmonellosis usually does not have the edema which characterizes Colitis X. Recently, research has shown that ascarid antigen in a horse can cause a similar lesion in the colon. Its actual role in Colitis X has not been shown as yet.

Dr. D. Slauson, Cornell

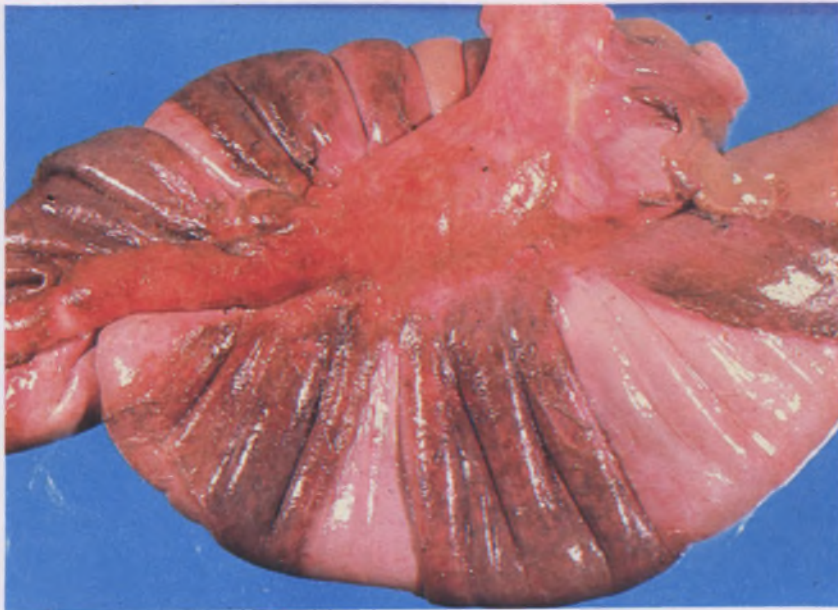
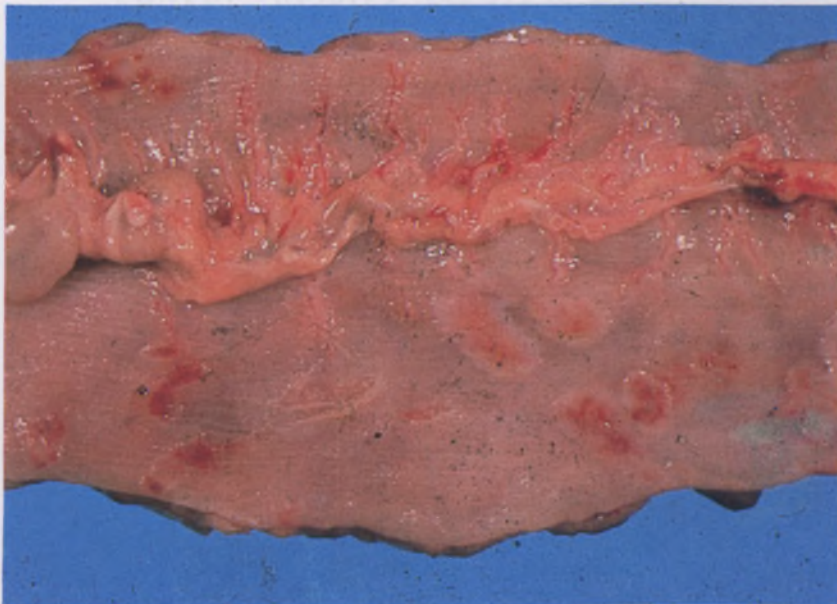
PLATE 681: COLITIS X WITH RUPTURE AND ACUTE PERITONITIS

The massive Edema in the wall of this horse's cecum is part of the diagnostic lesions for Colitis X or Exhaustion Colitis. The edematous bowel had ruptured allowing the marked congestion, fibrin and bits of ingesta seen on the patches of serosa. The unaffected serosal surfaces were those that were infolded and thus protected from the peritonitis. These animals usually die from severe diarrhea, but some may die from the fluid loss into the colon and cecum before diarrhea develops, and an occasional one dies from sequelae, such as this one. The cause is not known, but swine ascarid antigen injected into horses can cause a similar lesion.

Dr. C. Wimberley, Cornell, USA

PLATE 682: BOXER COLITIS (ULCERATIVE COLITIS; GRANULOMATOUS COLITIS)



The serosal surface of this dog's colon show scattered plaques of granulation tissue as a result of Chronic Granulomatous Colitis primarily affecting the mucosa. This disease is usually seen in the boxer breed of dogs but it is also seen in other breeds. Its cause is unknown, but several consider it a bacterial disease somewhat like Whipple's Disease in man. This boxer had a history of severe diarrhea with cachexia. The dog was taken from the owner and housed with a group of experimental beagles for a month, during which time it was fed regular dry dog food. The dog's bowel movements went from 20 to 30 movements of watery stools per day to only 1 or 2 movements per day of relatively solid stools. It had gained weight from 48 lbs. back up to 76 lbs. in the thirty day period. It was returned to the owner and in four days it had lost 15 lbs. and was affected with constant diarrhea. The dog was killed.

Dr. M. Woodside, Pennsylvania, USA

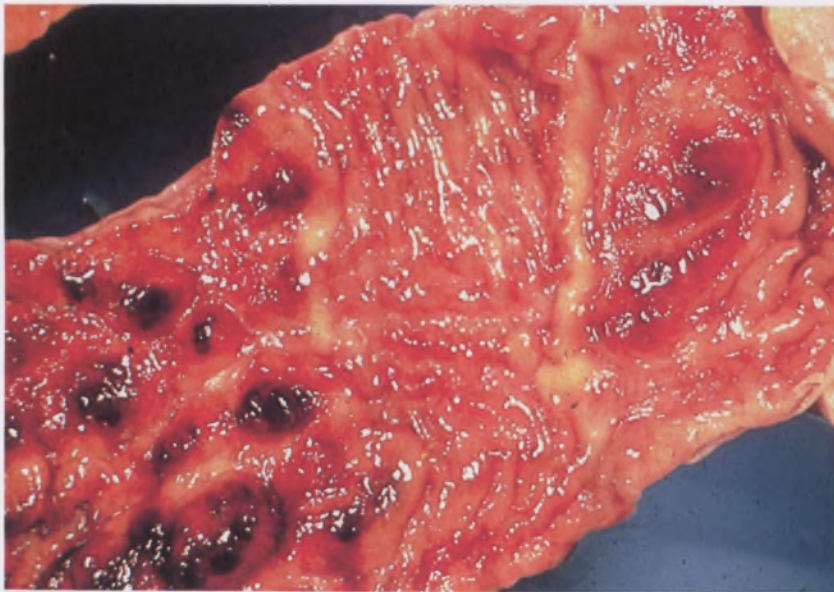


PLATE 683: ULCERATIVE (GRANULOMATOUS) COLITIS OF BOXER DOGS

This is the first portion of colon in a dog showing a normal patch of mucosa among areas of ulceration and hemorrhagic granulation tissue. This case of Granulomatous Colitis or Ulcerative Colitis of Boxer Dogs, is a young boxer that responded well for a while to a change in diet and husbandry but immediately relapsed on being returned to the original environment. Some consider its cause to be infectious, but this has not been proven. It is probably due to stress.

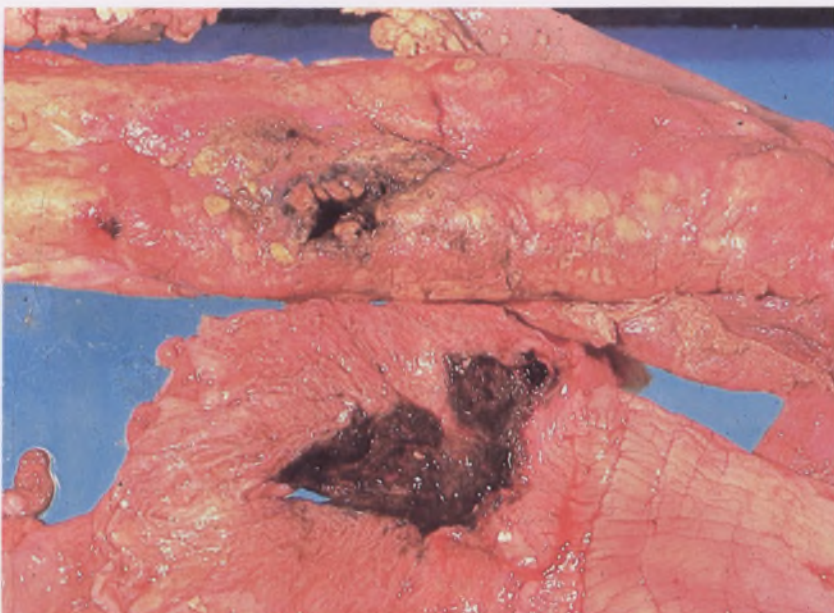


PLATE 684: SADISTIC TRAUMA

The hemorrhagic lesion in the uterus and the hemorrhagic hole in the rectum with some fibrin and ingesta around it are the result of Sadism from a mentally incompetent young man pushing a sharpened steel rod through the vagina, uterus and several portions of bowel. The cow died from Septic Peritonitis.

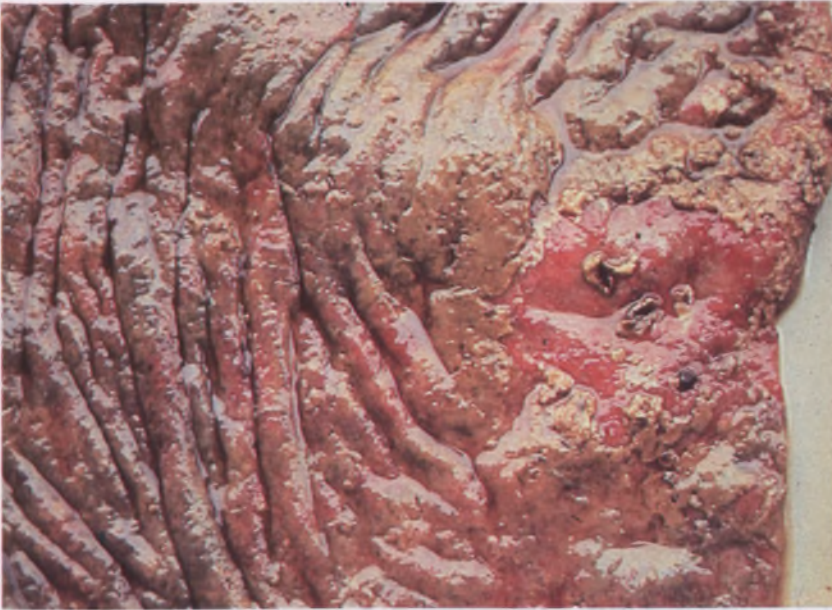


PLATE 685: ACUTE FIBRINONECROTIC COLITIS

The colonic mucosal congestion and superficial necrotic debris, along with a definite septic tank odor, with or without diarrhea, are quite characteristic of Salmonellosis. Appreciable edema of the colon wall is not usually present, which would help distinguish this disease from Colitis X in horses.

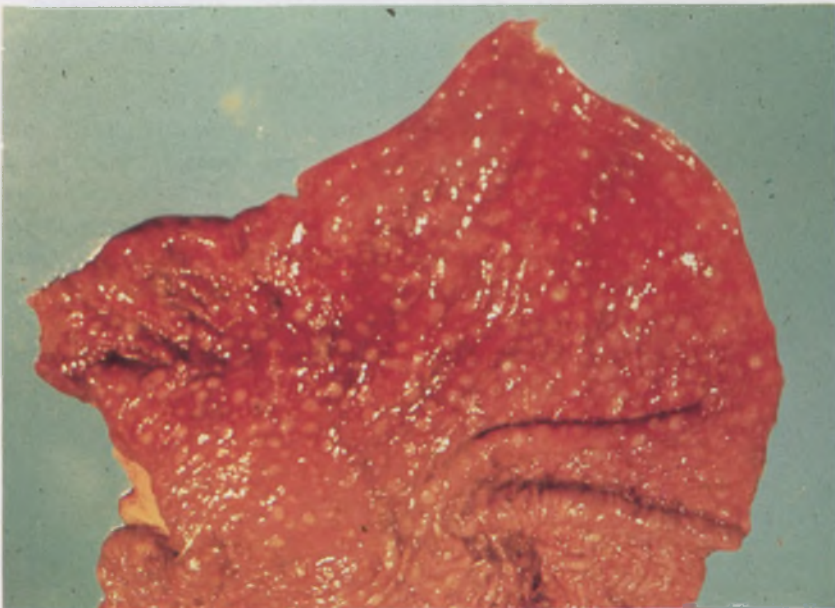
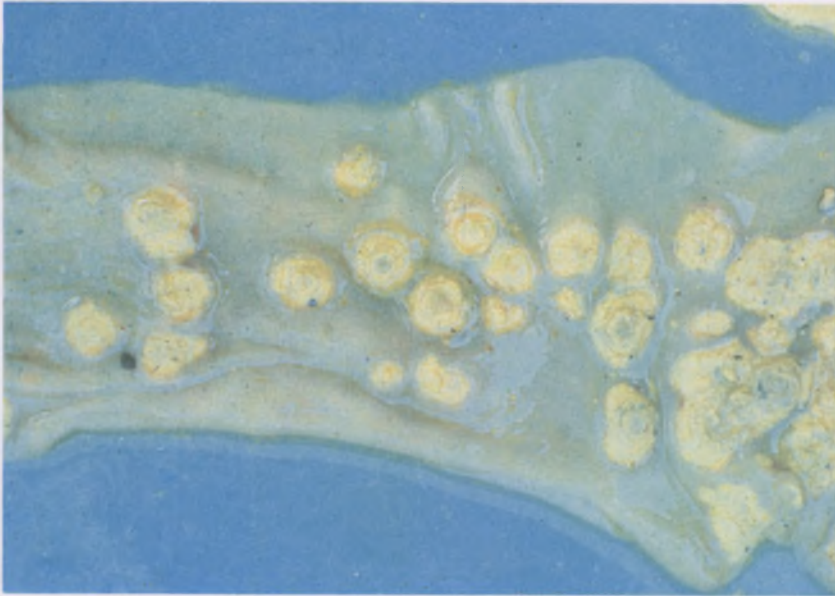


PLATE 686: MULTIFOCAL COLONIC NECROSIS

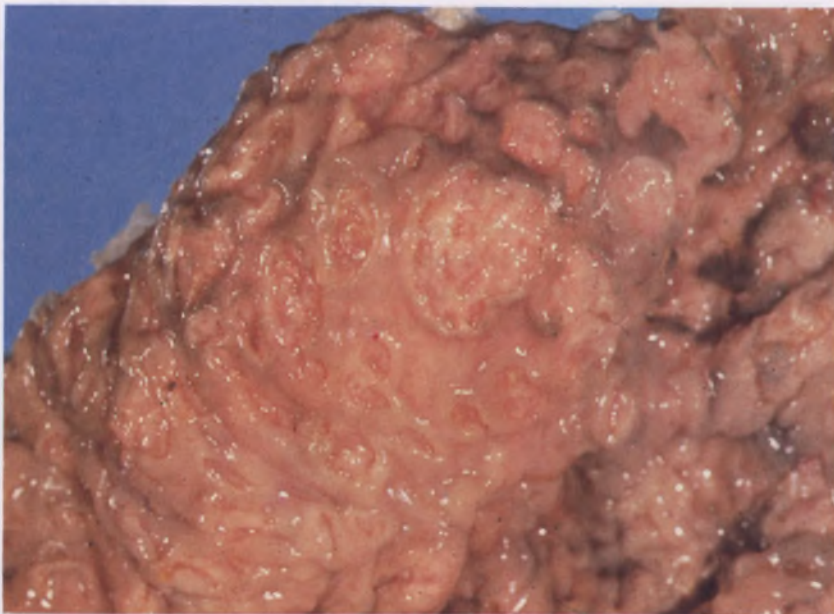
The large numbers of pale necrotic foci in this horse's colon, along with a definite septic tank odor are quite diagnostic for Salmonellosis, caused by *Salmonella* spp. If the horse had been treated, the odor may not always be present. The content of the bowel in many instances may mask this lesion in part, but if it is significant the loose stools will allow these to be seen easily.



Dr. C. I. Liu, Taiwan, ROC

**PLATE 687: BUTTON ULCERS
(MULTIFOCAL NECROTIC COLITIS)**

The multiple yellow plaques in the colonic mucosa of this pig are Button Ulcers caused by *Salmonella* spp.. They are quite commonly found in clinically normal pigs but are also found in swine with Hog Cholera, so much so, that initially they were considered lesions of Hog Cholera.



**PLATE 688: CHRONIC GRANULOMA-
TOUS ULCERATIVE COLITIS**

This colon from a horse shows the multiple Chronic Granulating Ulcers in the mucosa caused by a chronic colonic infection with *Corynebacterium equi* which were isolated in pure culture. Other organisms especially *Salmonella* spp. can also cause a similar lesion. Some think that small strongyle parasites initiate the lesions in the mucosa, which subsequently get infected in a heavily parasitized animal.

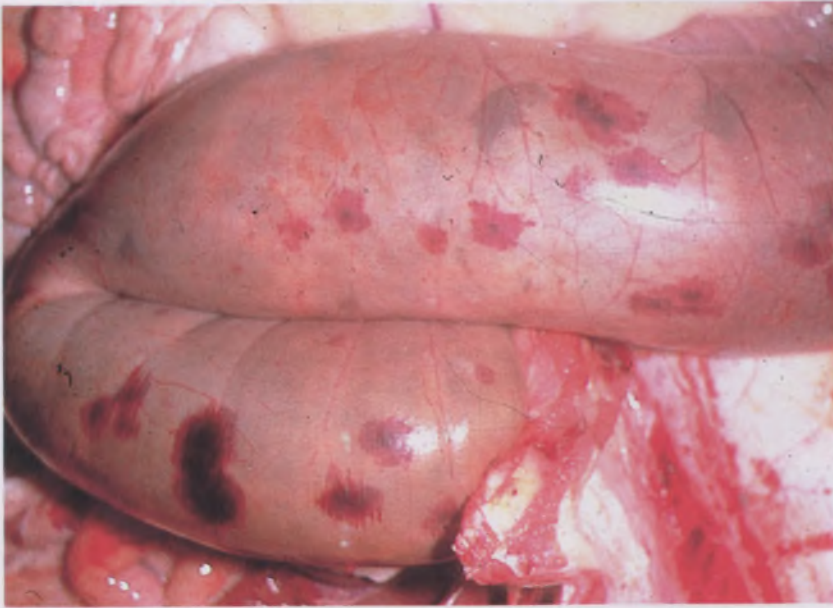


PLATE 689: MULTIFOCAL ECCHYMOSES OF ENTEROTOXEMIA

The multiple splotchy hemorrhages (ecchymoses) in this sheep are quite diagnostic for Enterotoxemia, an Overeating disease caused by *Clostridium perfringens* type D. One would also expect to find excess fluid and fibrin in the heart sac, and in a few cases bilateral encephalomalacia in the brain stem. As this disease is apparently associated with gluconeogenesis, the increased sugar content of the kidneys at death often allows renal autolysis to be more severe and rapid than in most animals that die for other reasons. This accounts for the name Pulp Kidney Disease also given this condition.

Dr. C. Richard, Cornell, USA

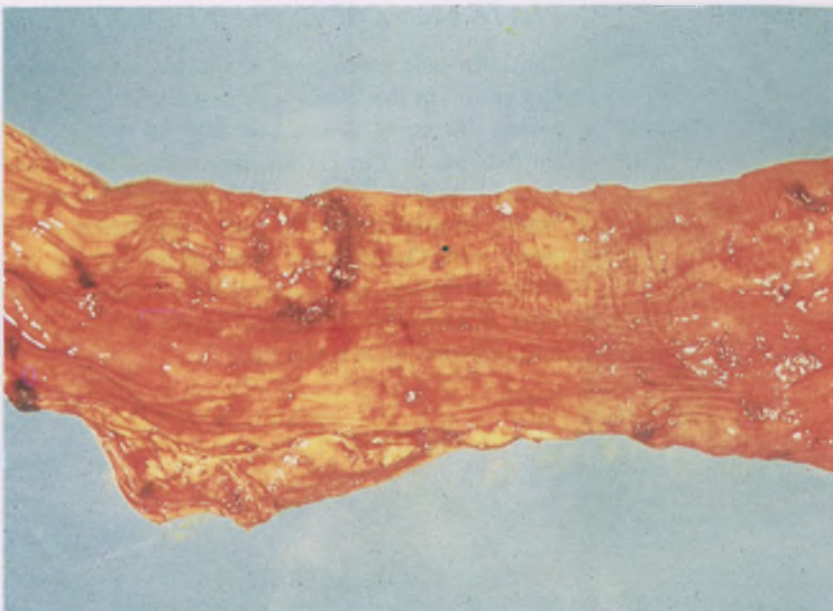
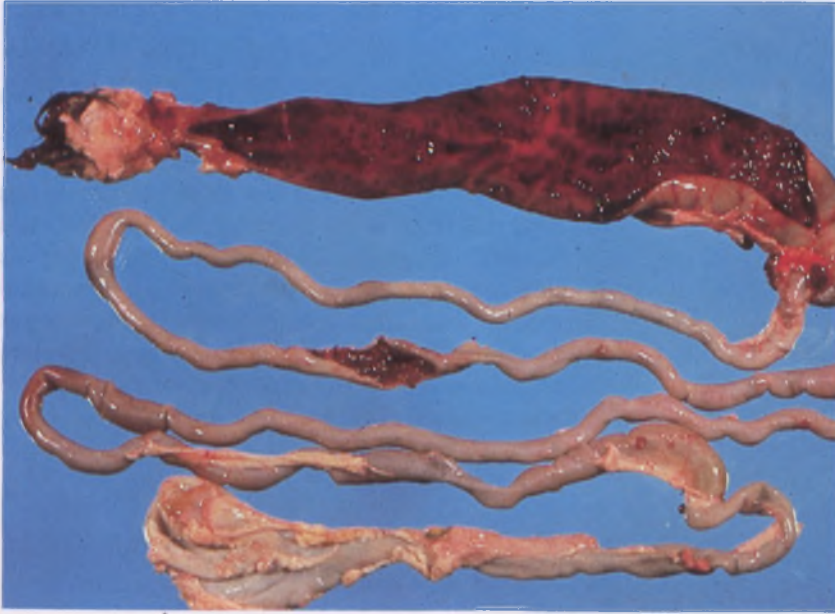


PLATE 690: WINTER DYSENTERY

The bits of blood and fibrin in this cow's colon are all that one usually sees in the very rare fatal case of Winter Dysentery. A large number of cattle in the barn will suddenly have diarrhea in the winter time, they will go off feed and down in milk production but, most will recover in a short period. The cause is suspected to be *Campylobacter* spp..

Dr. G. Campbell, Cornell, USA



**PLATE 691: PANLEUCOPENIA AND
TERMINAL SHOCK LESION
OF THE COLON**

The cat intestine shown here is blue as the result of hemorrhage into the lumen of both the small and large bowel. This is a case of Panleucopenia, a viral disease of cats. The hemorrhage especially of the colon, is seen only sporadically with this disease and may represent a variation in the type of response. One has to consider that the colon lesion may be a Terminal Shock Lesion. This could also be considered the disease called "panleucopenia-like feline leukemia virus (FeLV) disease.

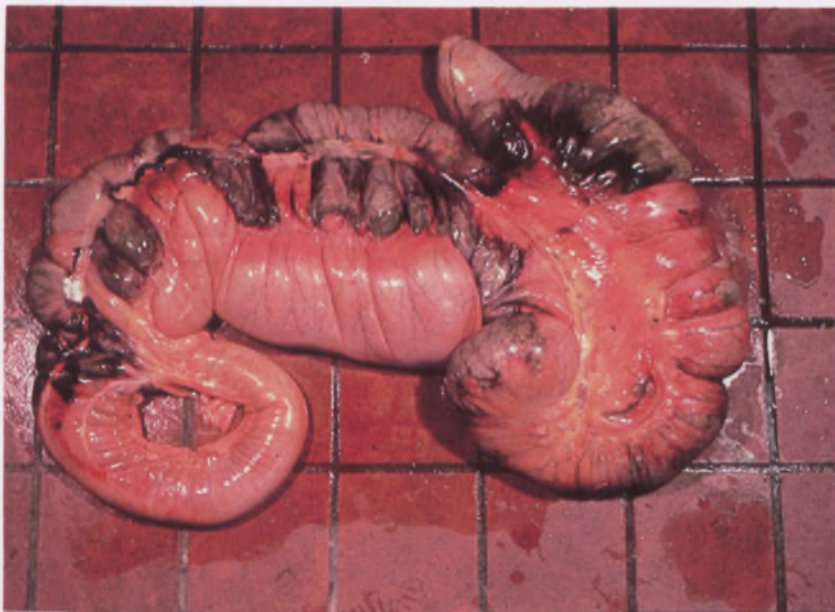

PLATE 692: COLONIC INFARCTION

The large pale green areas of the wall of the colon and cecum in this horse are the result of Infarction, caused by larval *Strongylus vulgaris* arteritis and thrombosis in the cranial mesenteric artery and in the branches closer to the infarcted areas of the bowel. Obstruction in the cranial mesenteric artery alone, even though quite extensive will usually not result in bowel infarction, unless other branches from the caudal mesenteric artery to the same area of bowel are also affected.

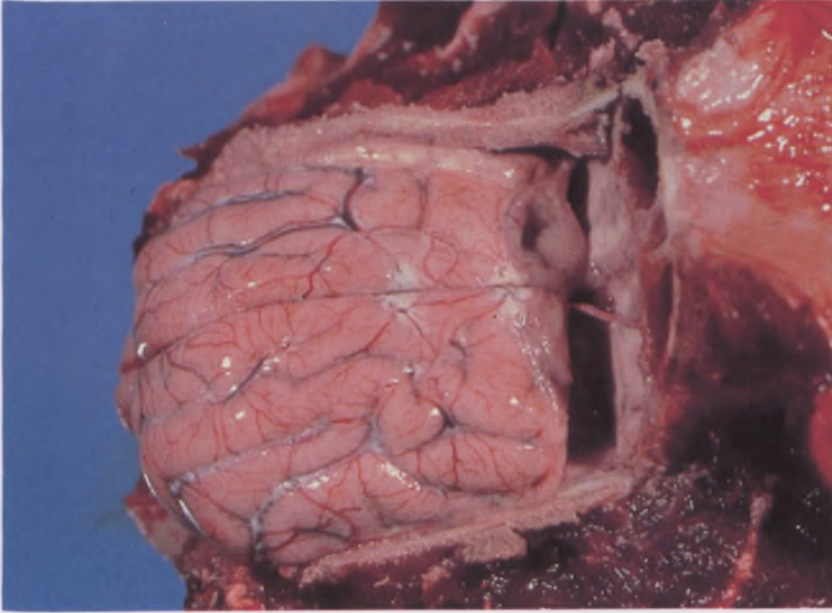


PLATE 693: AGING LIPOID DEPOSITS

The distinct white opaque material scattered in the pia mater over the brain, especially in the sulci are Aging Lipoid Deposits, of no clinical significance. They are seen in other older animals as well. Histologically, they are accumulations of lipid like substances in macrophages without other cellular response. They can be seen in the pia mater all over the brain, not just dorsally, but they are more easily seen there. It is a nonspecific aging change.

Dr. C. Rickard, Cornell, USA

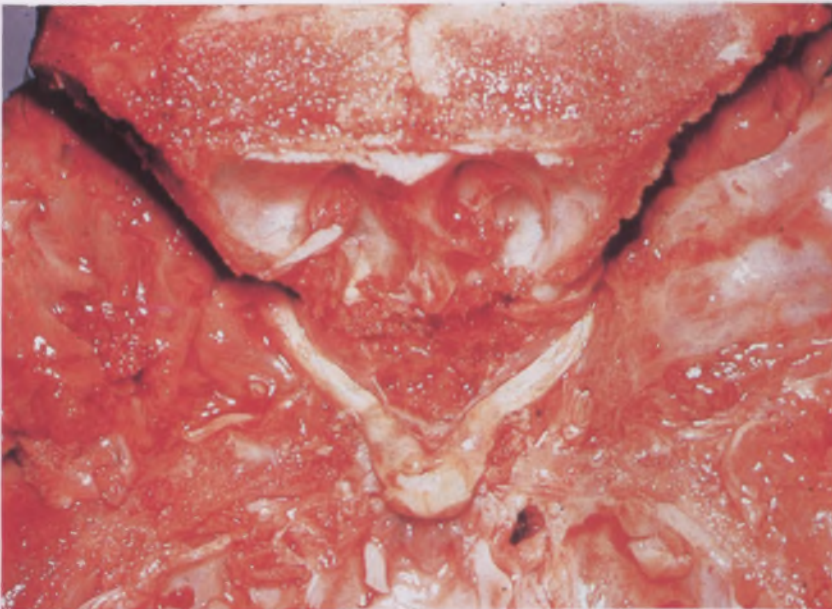
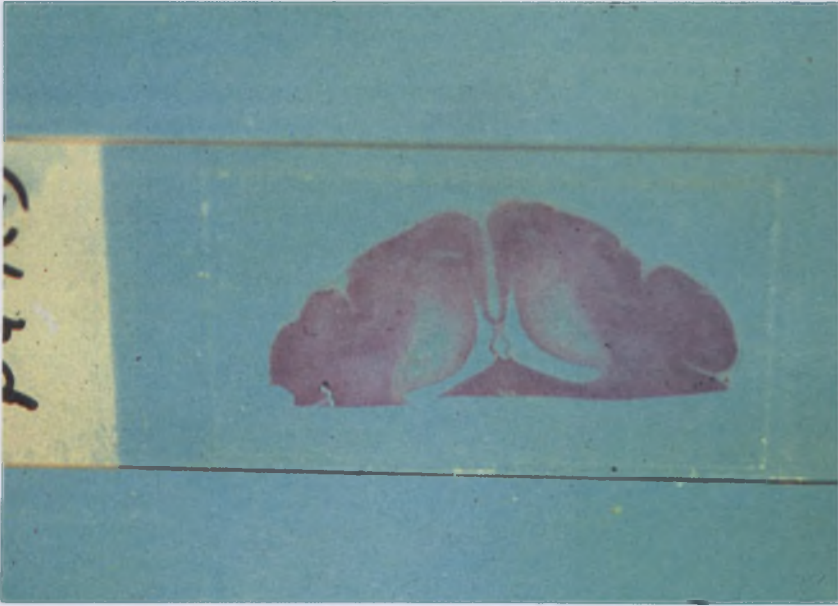

PLATE 694: OPTIC NERVE DEGENERATION

The optic nerves, slightly swollen and discolored as they enter their bony canals, which have been removed, have been damaged as the result of a Vitamin A Deficiency in this calf. The explanation is that the brain keeps growing in young animals but the Vitamin A Deficient bone fails to grow fast enough. This finally results in constriction of the nerves. Night blindness (Nyctalopia) is an early clinical sign.

Dr. R. Panciera, Oklahoma, USA



**PLATE 695: BASAL GANGLIA
ENCEPHALOMALACIA**

This region of a dog's brain shows the definite softening and loss of parenchyma that characterizes Encephalomalacia. This lesion is thought to be due to Thiamine Deficiency in this dog, but was not proven. It can be seen in cases of Cerebral Anoxia in many species, Enterotoxemia in sheep and Thiamine Deficiency in several species.

Dr. A. De Lahunta, Cornell, USA

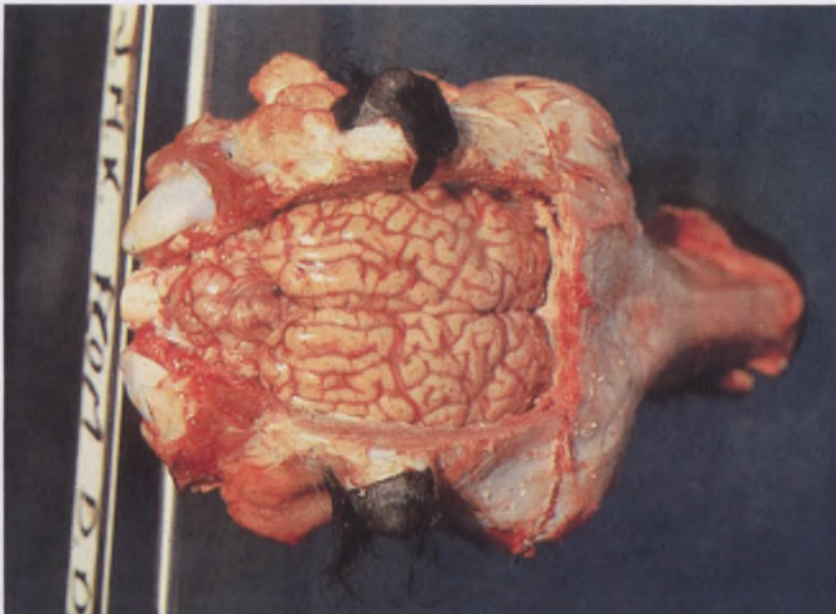


PLATE 696: CONTACT ENCEPHALOMALACIA

The yellow discoloration of several gyri, especially in the caudal portion of the cerebrum in this calf's brain are areas of Contact Encephalomalacia, caused by Thiamine Deficiency in this case of Polioencephalomalacia. Histologically, many Gitter Cells can be found filled with parenchymal debris that gives this yellow orange color. Lead Poisoning can result in a similar lesion. A new technique, to show this lesion better grossly, is the use of an ultraviolet light source that in some cases causes the affected areas to fluoresce.

Dr. R. Seiler, Cornell, USA

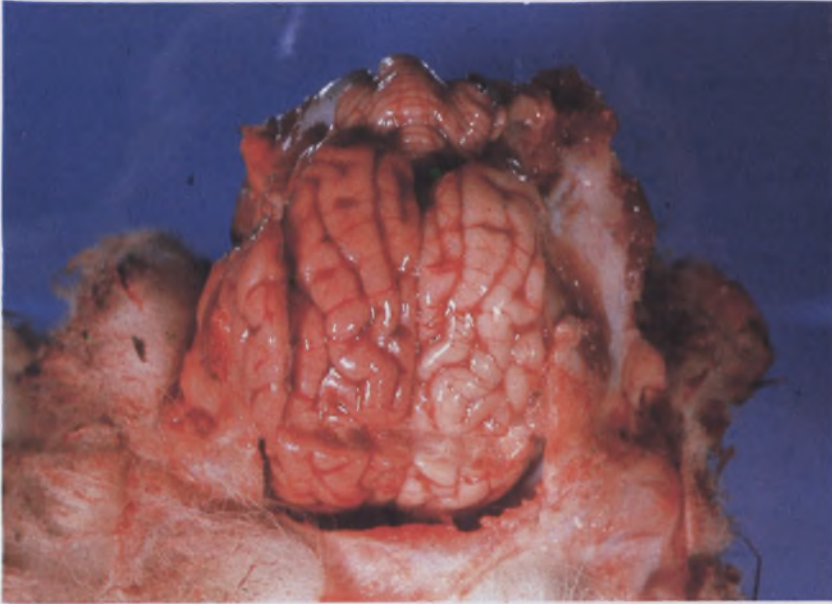


PLATE 697: UNILATERAL INTRACAROTID INJECTION

The distinct red discoloration of the cerebral hemisphere is the result of marked congestion from an Accidental Unilateral Intracarotid Injection of antibiotics. Severe nervous signs developed in this lamb but they were not necessarily fatal. The lamb was slaughtered. This lesion appears mostly in horses. A cross sectional view would be roughly similar.

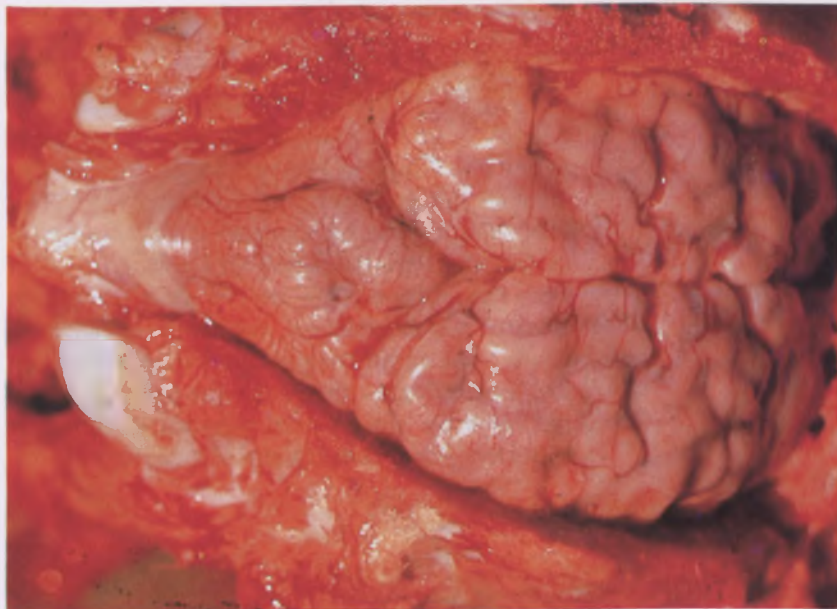


PLATE 698: SUPPURATIVE MENINGITIS WITH CEREBELLAR CONING

The pronounced Coning of the Cerebellum, with fibrin at the tip of the cone over the medulla, is evidence of a Suppurative Meningitis. This caused a swelling of the brain with partial Cerebellar Prolapse through the foramen magnum. Any of the common pathogens could have caused this lesion.

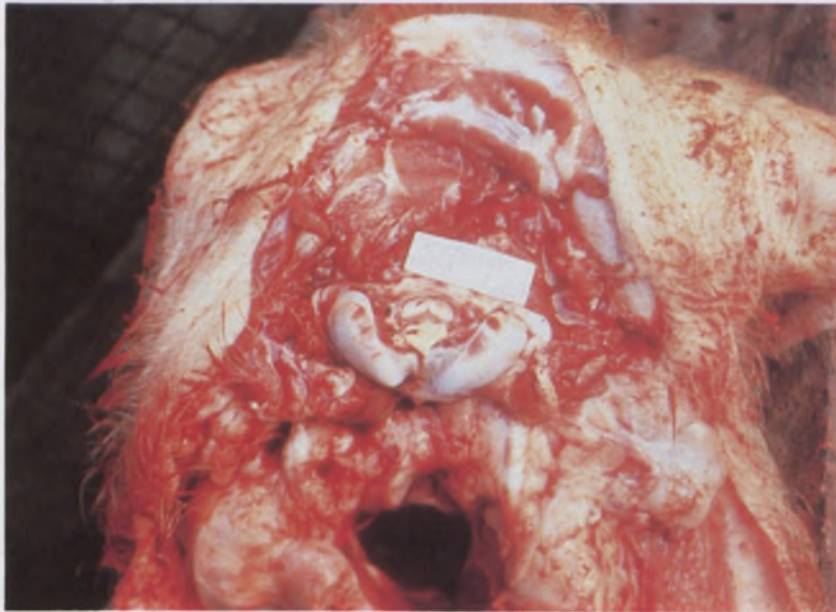


PLATE 699: MENINGEAL ABSCESS

The yellow, tongue shaped mass of material lying on the floor of the skull and pushing the medulla dorsally is a pocket of pus, exposed when the head was removed. Almost any common pathogen can be isolated from such cases. It is the result, in this case, of an ascending infection of the vertebral canal from a wound caused by tail biting.

Dr. R. Chu, Taiwan, ROC

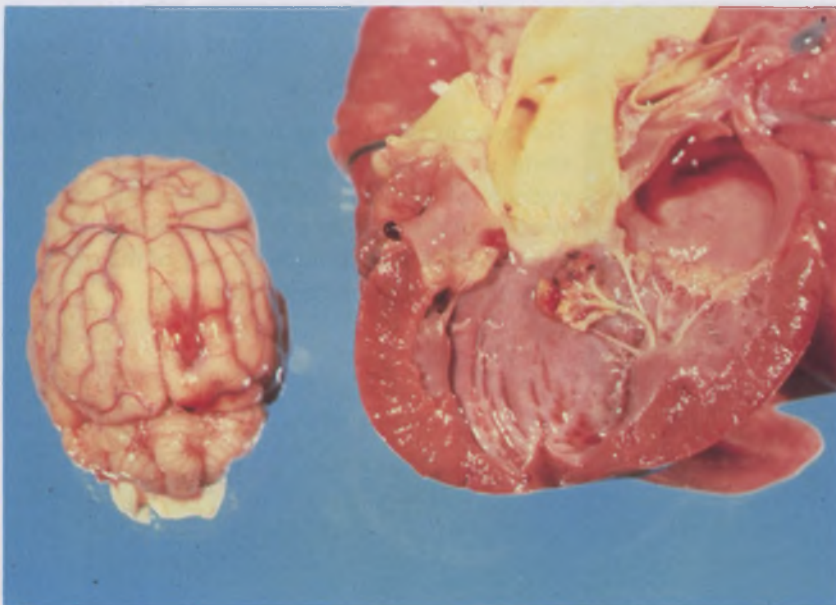
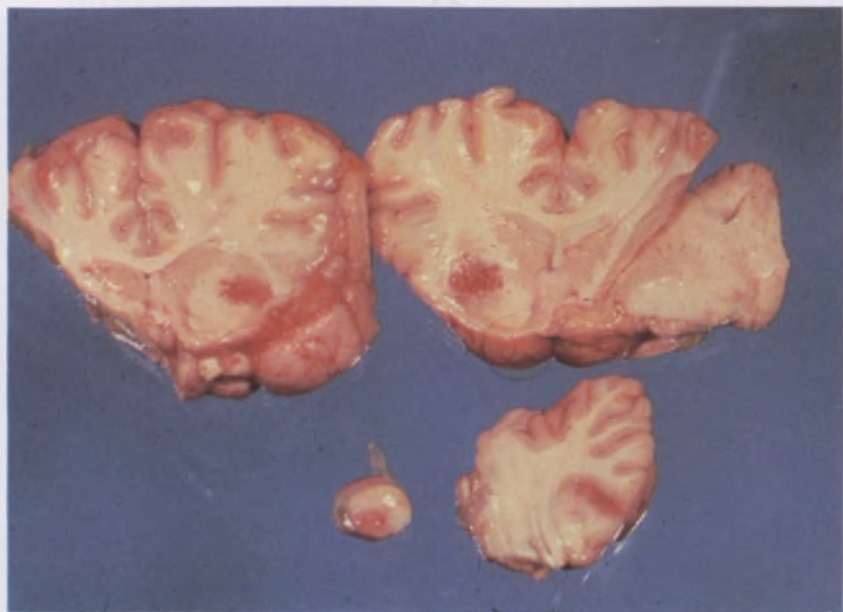


PLATE 700: VEGETATIVE ENDOCARDITIS WITH EMBOLIC ENCEPHALITIS

A dog's heart and brain are shown with the heart having a well marked Bacterial Vegetative Endocarditis on the anterior cusp of the atrioventricular valve. The dog had been treated so the attempts to culture the organism failed. In the caudal half of one cerebral hemisphere are two areas of Embolic Hemorrhagic Encephalitis, the result of pieces of debris breaking off the septic thrombus in the heart and embolizing to the brain. The caudal poles of the cerebrum are the most common locations for such embolization but the reason is not known.

Dr. R. Sailer, Cornell, USA



Dr. M. Wolfe, Cornell, USA

**PLATE 701: ACUTE SUPPURATIVE
ENCEPHALOMYELITIS**

The distinct unilateral, pink focal area in the region of the internal capsule and lenticular nucleus, the one focus in the cerebellum and one in the cervical spinal cord are all areas of Acute Suppurative Encephalomyelitis, caused by *Hemophilus somnus*. Several cases, including this one, have had Acute Focal Laryngitis which was considered to be the portal of entry for the organism.

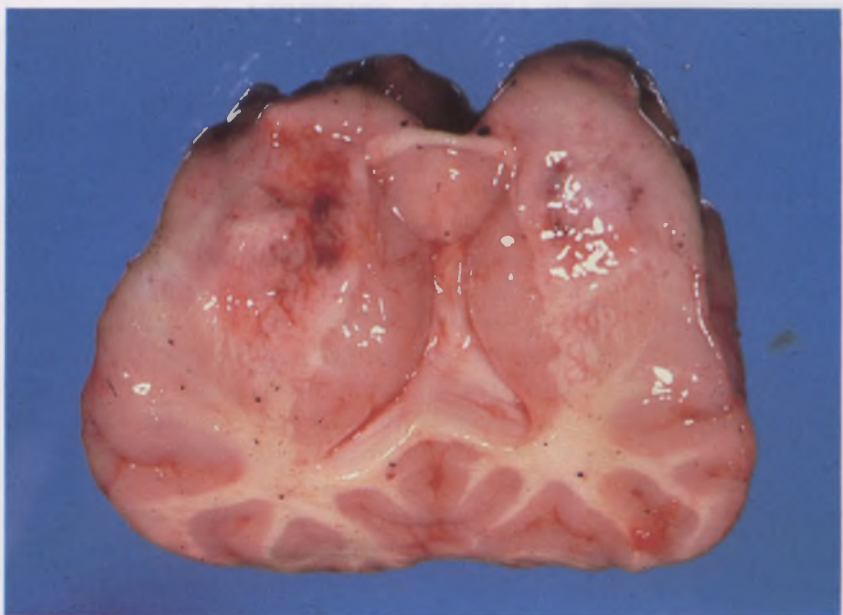


PLATE 702: BILATERAL ENCEPHALOMALACIA

The cross section of this sheep's brain shows the basal ganglia with bilateral, hemorrhagic soft areas of Encephalomalacia associated with the toxin of Enterotoxemia, caused by *Clostridium perfringens* type D. In this case the lenticular nucleus and internal capsule are the areas damaged the most. Fluid and fibrin in the heart sac, along with splotchy hemorrhages in the gut and abdominal walls are more commonly found lesions in the disease. Histologically, this is only a necrotic change without much inflammatory cell response.

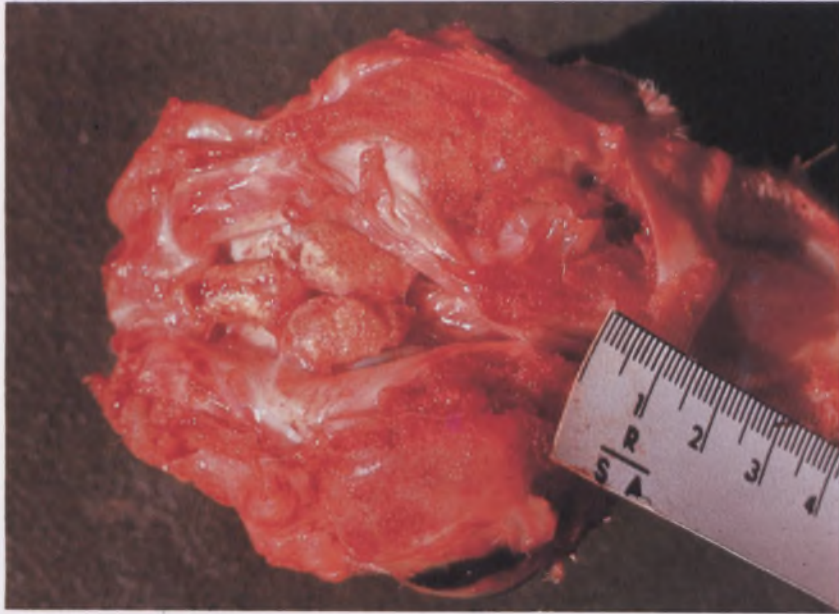


PLATE 703: CEREBRAL ATROPHY AND MINERALIZATION

The entire brain including the cerebral hemispheres and cerebellum, is shrunken and mineralized as a result of Wesselbron's Disease, a virus disease related to Rift Valley Fever. The lung in this case was hypoplastic.

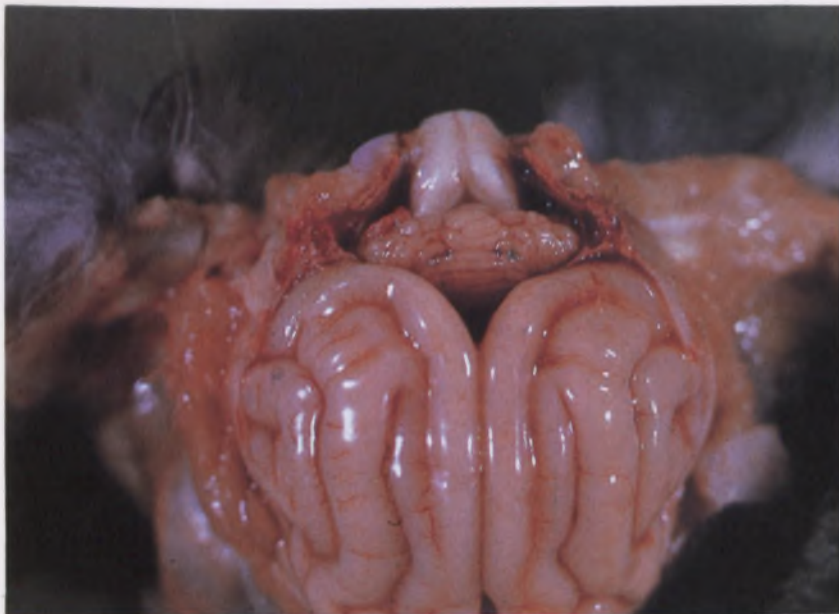


PLATE 704: CEREBELLAR HYPOPLASIA

The undersized cerebellum in this kitten is the result of Panleucopenia, a virus disease in the kitten. The lesion has been known for years as Cerebellar Hypoplasia. It was first thought to be a genetically related hypoplasia however research has shown it to be due to a Parvovirus infection. It is also known as Granuloprival Hypoplasia due to the way it develops. Histologically, the virus damages some areas that subsequently shrink, and at the same time prevents other tissues from growing due to lack of stimulation by the cells that were destroyed. This occurs with other viruses in other species also.

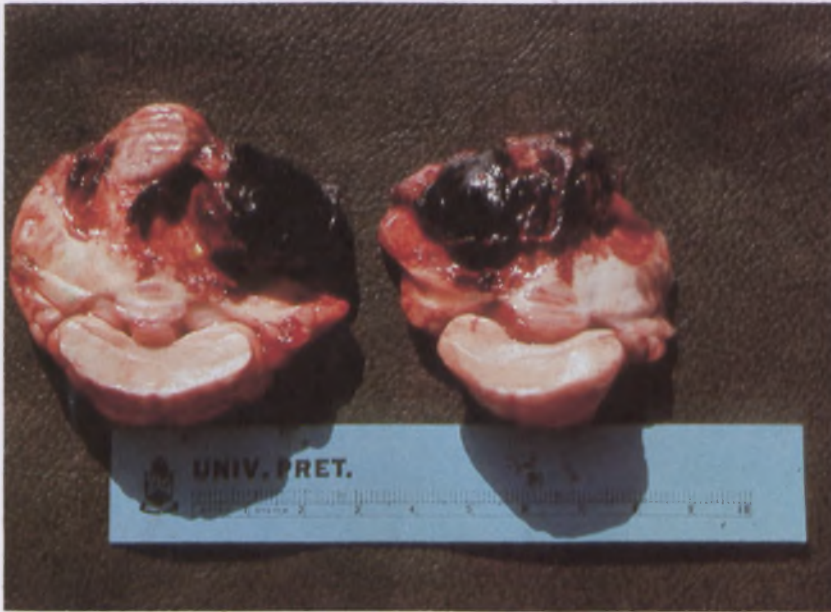


PLATE 705: PROTOZOAL (THEILERIA MUTANS) CEREBELLAR INFARCTION

The large areas of hemorrhage in this cow's cerebellum are the result of Cerebellar Infarction, caused by vascular thrombosis associated with *Theileria mutans*, the protozoan that causes Turning Disease. Impression smears of the edges of the lesion will often reveal the causative organisms in white blood cells in the capillaries. Usually an enlarged spleen is also found.

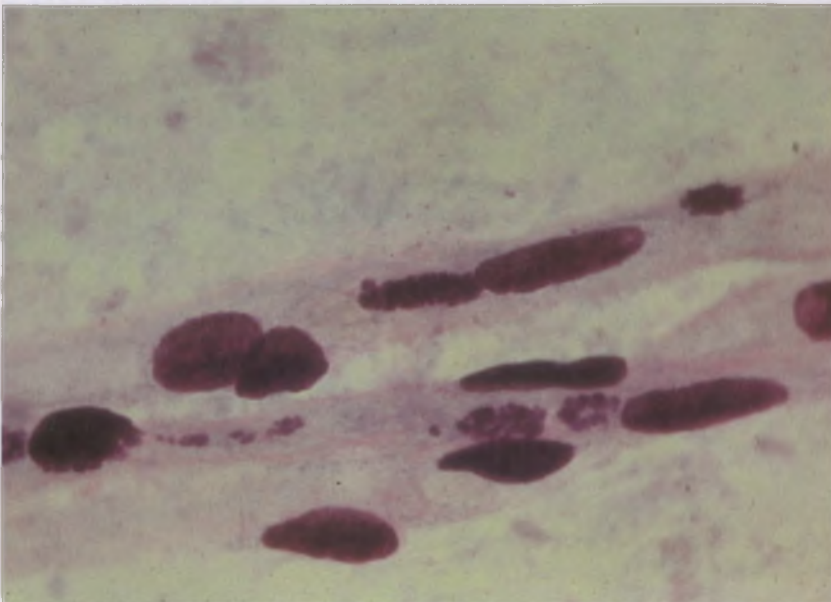
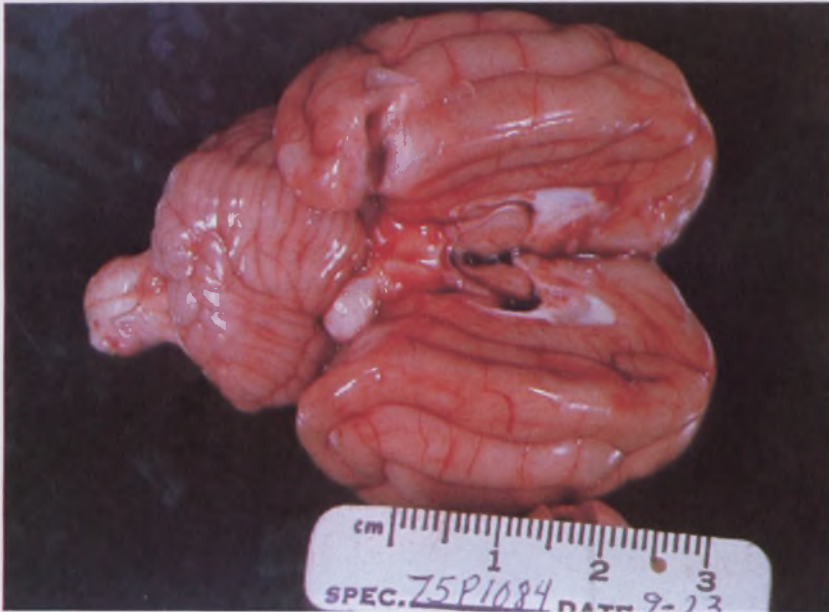

PLATE 706: COWDRIA RUMINANTIUM

This is a smear of the hippocampus from a cow. It is made by squashing a small piece of hippocampus and then periodically lifting it from the slide while spreading it on the slide. The capillaries are stretched with this technique and clumps of *Cowdria ruminantium*, the protozoan that causes Turning Disease, are easily seen near the poles of the endothelial nuclei.



Dr. J. Carlisle, Cornell, USA

**PLATE 707: CEREBRAL MYIASIS
(*CUTEREBRA* SPP.)**

The cat's brain is swollen and congested, and in the longitudinal fissure just cranial to the cerebellum is a larval stage of *Cuterebra* spp.. This form of Myiasis is usually in the skin of rabbits, but many are seen in the skin as lumps in cats and dogs. The adult flies lay their eggs near the burrow openings of rodents and rabbits and inquisitive cats are supposed to become infected in this fashion, but as so many cases are found in nonwandering kittens, still housed in boxes or pens, it is doubtful that egg deposition around burrow openings is the only way parasitism occurs.

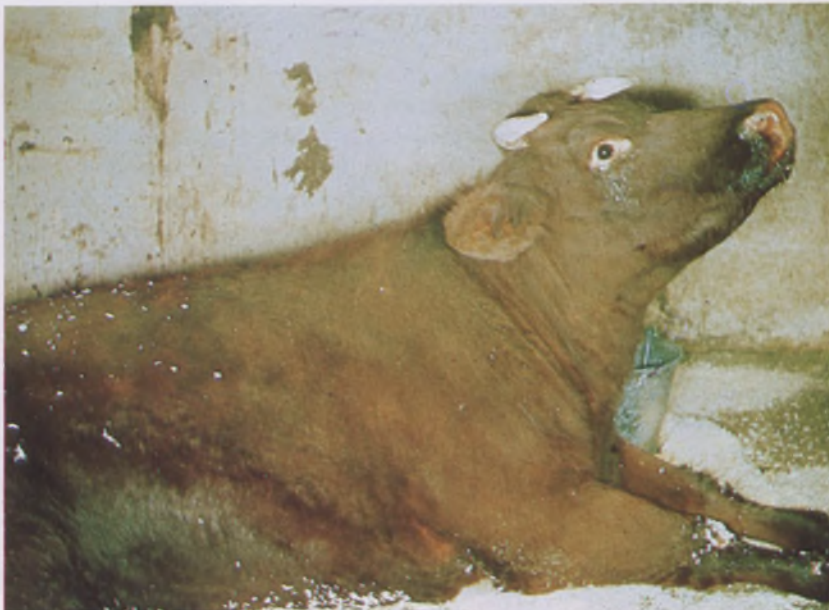

PLATE 708: BRAIN STEM MEDULLOBLASTOMA

This shows a young steer down with opisthotonus and an anthropomorphically apprehensive look to its eyes. This is the result of a brain tumor, more specifically a Medulloblastoma, in the brain stem. Apparently, according to Dr. Kintner of Missouri, this is a not uncommon disease in certain areas of Missouri.

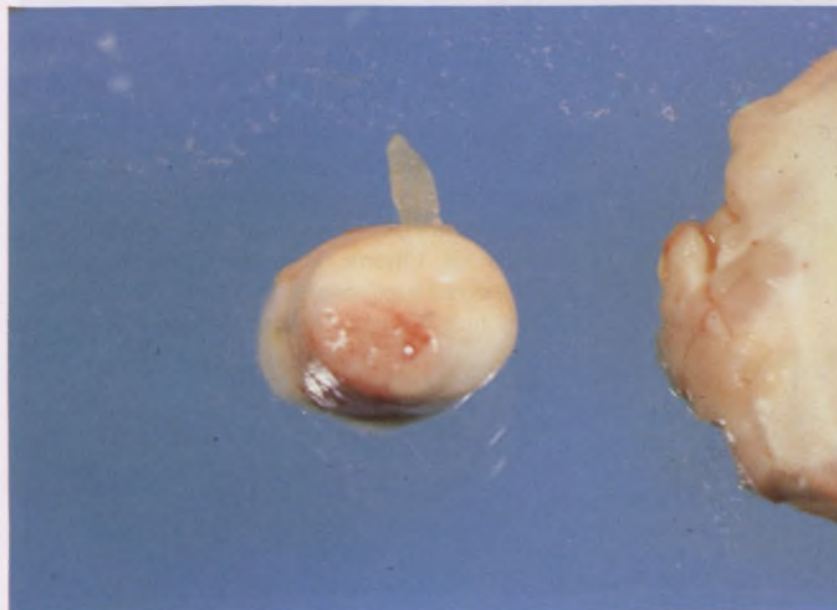Dr. Kintner, Missouri, USA



Dr. C. I. Liu, Taiwan, ROC

PLATE 709: FOREIGN BODY (FISH BONE)

Foreign Bodies such as this fish bone can work themselves to all parts of the body, even to long distances from the actual portal of entry. This fish bone Foreign Body penetrated through the pharyngeal mucosa and up through the soft tissue, to and through the dura mater into the spinal cord at the atlantoccipital joint. This killed the dog.



Dr. M. Wolfe, Cornell, USA

**PLATE 710: ACUTE BACTERIAL
(HEMOPHILUS SOMNUS)
MYELITIS**

The very definite pink quarter section of cervical spinal cord at C1 is a focal area of Acute Bacterial Myelitis, caused by *Hemophilus somnus* (agni) in a cow. A few scattered similar lesions were in the brain. This N.Y. State cow did have nervous signs but as Thromboembolic Meningoencephalitis (TME) is not usually seen in N.Y. State, the lesion was not expected. *H. agni* is usually isolated from TME cases. This cow also had a Suppurative Laryngitis and as several cases of this *Hemophilus* spp. have had the throat lesion, we suspect it may be a likely portal of entry.

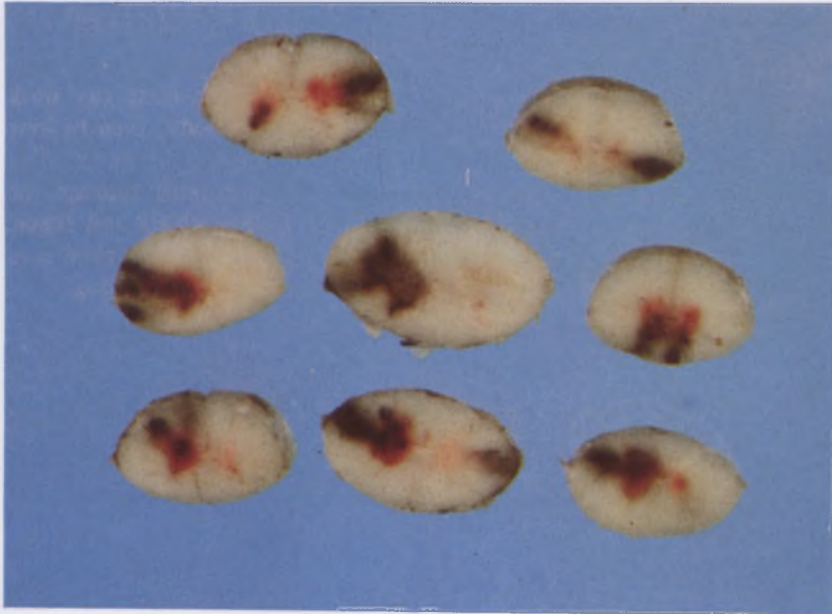
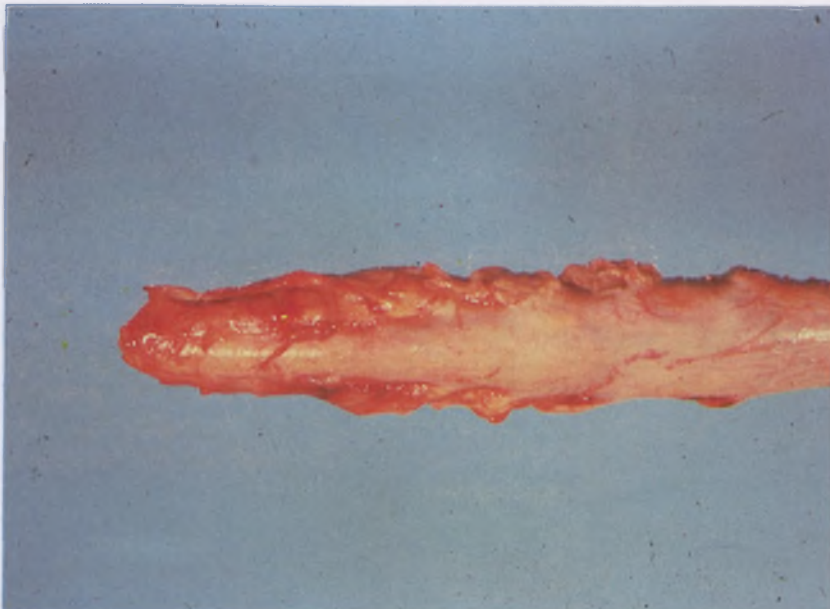


PLATE 711: EQUINE HERPES (RHINO-PNEUMONITIS) MYELITIS

The dark hemorrhagic areas scattered in this partially fixed spinal cord of a horse are hemorrhages associated with Equine Rhinotracheitis Myelitis. This viral disease has a tendency to make lesions along vessels which accounts for the distribution. Protozoal Myelitis is usually more scattered and not as big a lesion as Stenotic Myelopathy associated with Wobblers and usually does not make an easily observed gross lesion. Degenerative Myelopathy, also of older horses, does not usually make an easily observed gross lesion.

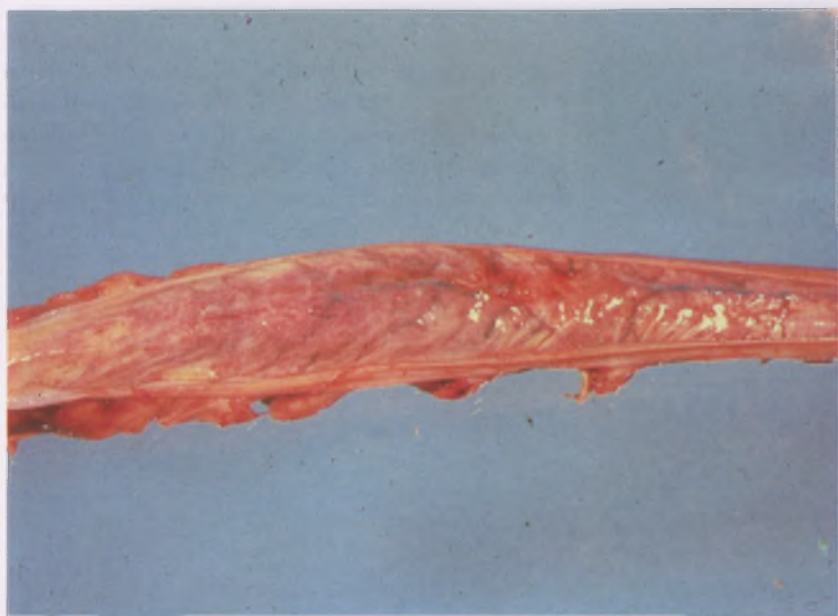
Dr. J. Carlisle, Cornell, USA

PLATE 712: CHRONIC FUNGAL (CRYPTOCOCCUS NEOFORMANS) MENINGITIS



The distal end of this horse's spinal cord (cauda equina) is thickened, red and wet. Several nodules of granulation tissue are present on the dura but the nerves themselves are essentially normal. This example of Chronic Pachymeningitis is due to *Cryptococcus neoformans*. It is to be differentiated from Cauda Equina Neuritis in which the gross lesion is observed as thickening of the nerves themselves.

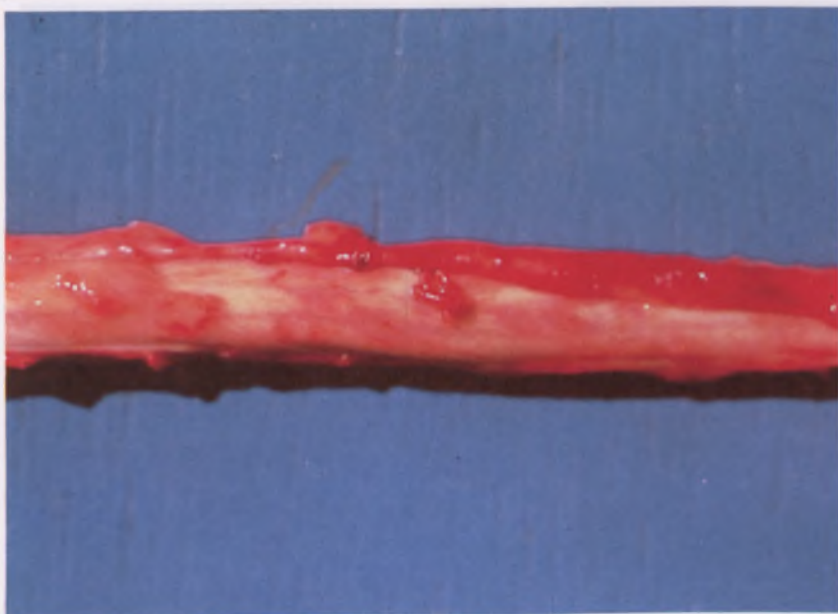
Dr. Kinked, Nevada, USA



**PLATE 713: CHRONIC FUNGAL
(CRYPTOCOCCUS NEOFORMANS)
MENINGITIS**

The thickened dura and arachnoid have been opened to show the edematous, congested, thickened pia mater in this horse's cauda equina. This is the result of Chronic Pachymeningitis caused by *Cryptococcus neoformans*.

Dr. R. Riv, Cornell, USA



**PLATE 714: PARASITIC (SPIROCERCA
LUPI)
PACHYMENINGITIS**

The coiled worm, *Spirocera lupi*, and the several areas of granulation tissue on the dura mater of this section of spinal cord, caused by this worm are rather unusual. The usual location is in association with the aorta and esophagus, or sometimes the rectum. This caused paresis in this dog.

Dr. G. Appel, Kenya

Spinal Cord

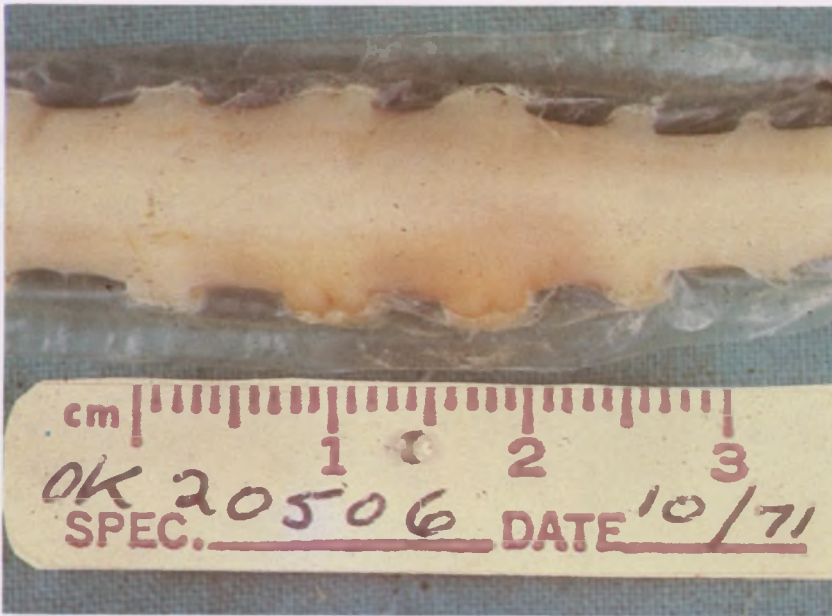

PLATE 715: LYMPHOSARCOMA

The slightly grey, thickened, formalin fixed spinal cord of this cat is diffusely infiltrated with neoplastic lymphoid cells, in this case of Lymphosarcoma. In cattle especially, but also other species such as this cat, the spinal cord may be the only tissue to have the neoplasm.

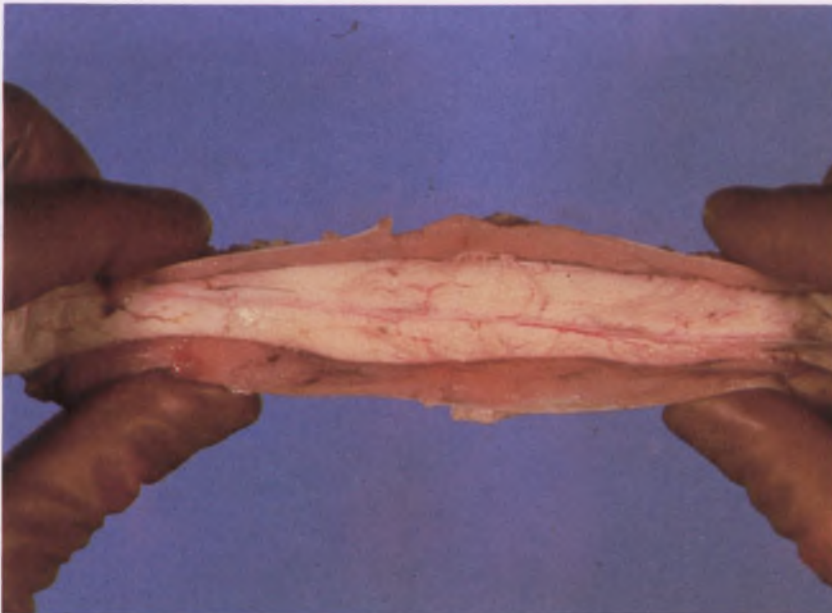


PLATE 716: LYMPHOSARCOMA

The tan tissue, causing the thickening of the meninges around the spinal cord of this cow is due to the massive infiltration by neoplastic lymphocytes, in this case of Lymphosarcoma. In some cases this may be the only area of tumor infiltration in the animal, but usually it is seen in the right atrium, abomasum and uterus as well as lymphoid tissue in general.

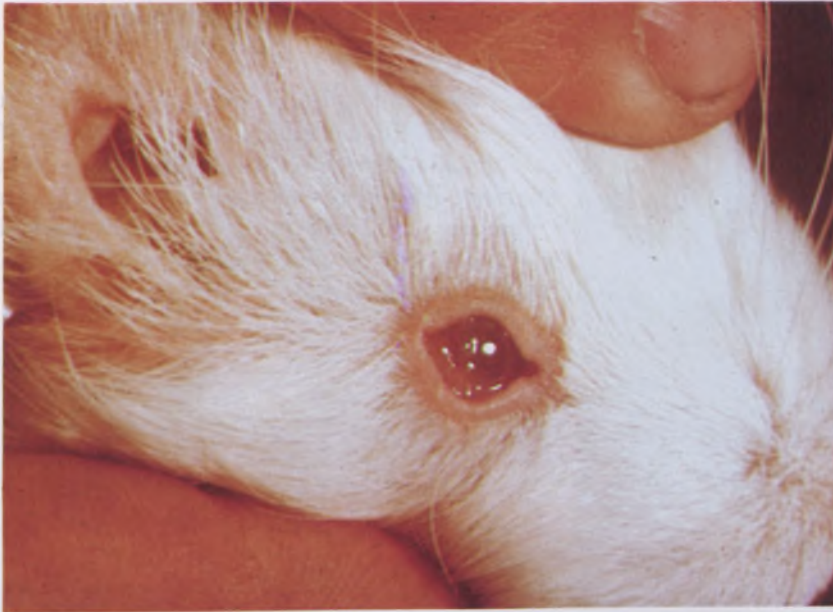

PLATE 717: CHEMOSIS AND HYPHEMA

Only an edematous conjunctiva (Chemosis) and a slight amount of blood (Hyphema) can be seen in this guinea pig's eye. It is the result of surgical trauma. Dr. H. Greene, of the Yale Medical School, had transplanted a tumor from another animal into the anterior chamber of the eye and let it grow. Tumors which are malignant often have the ability for independent growth away from their primary site, while benign tumors do not have this ability. The nonreacting or minimal reacting anterior chamber of an eye is a good transplantation site because it is easy to observe.

Dr. R. Riis, Cornell, USA

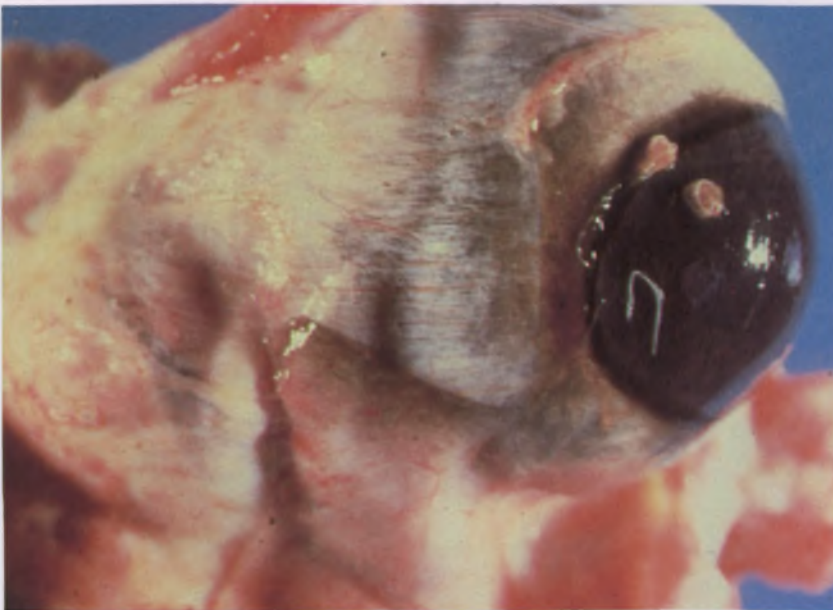
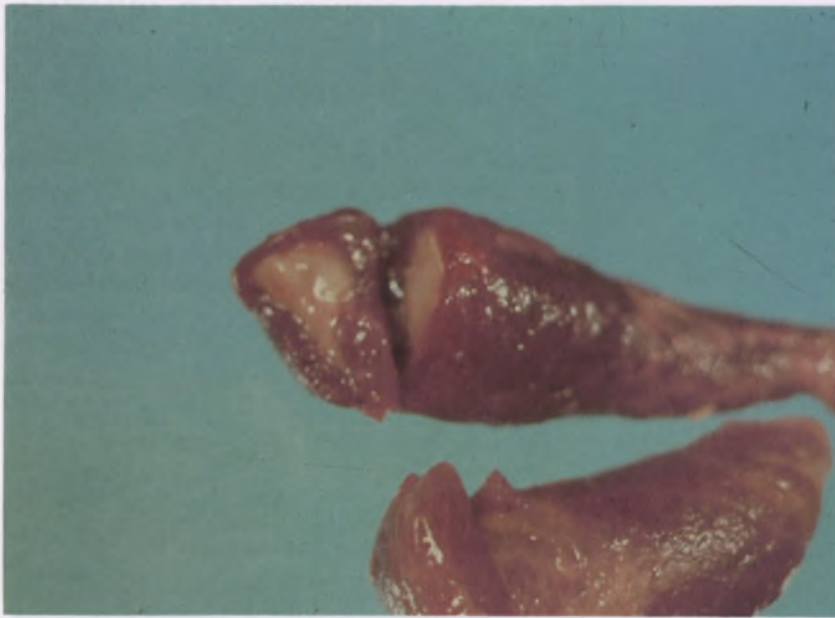

PLATE 718: "EYE WORMS" THELAZIA GULOSA

Five parasites are present on the eye of this cow. Three are free and two are coiled into small balls with debris. These are *Thelazia gulosa*. They are quite common in cattle in New York State but apparently do not cause many clinical problems.

Dr. W. Rebhun, Cornell, USA



Dr. J. Whitlock, Cornell, USA

PLATE 719: ULTIMOBRANCHIAL DUCT CYST OF THE THYROID

The roughly triangular yellow, soft mass in this adult sheep's thyroid gland is a cystic remnant of an ultimobranchial duct. It is filled with squames and other debris. Some of these may be filled with a clear mucoid material and others with inspissated pale debris. One or both thyroids may have these. They are not significant.

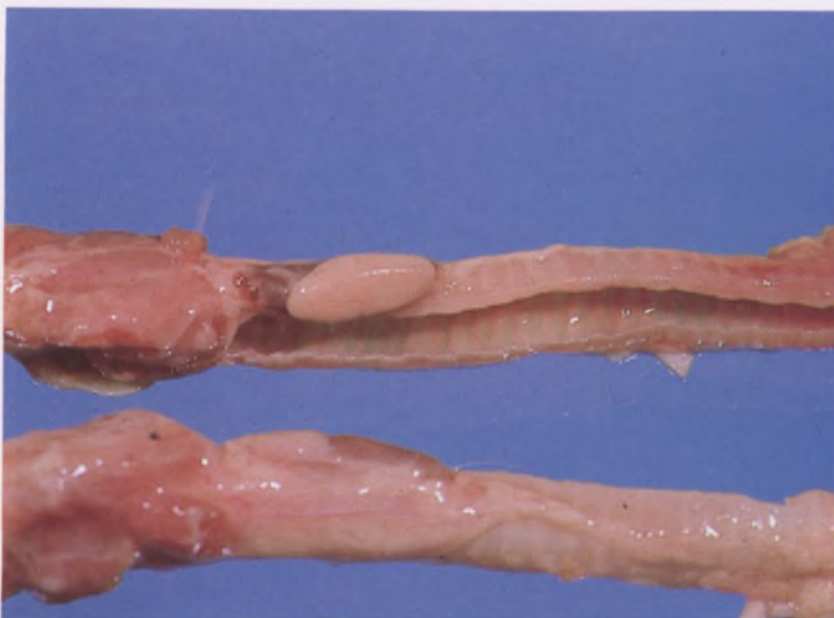


PLATE 720: PARATHYROID HYPOPLASIA

The lighter colored trachea is from a normal cat with a normal sized thyroid and parathyroid. The darker trachea is from a cat with chronic renal failure. Its parathyroid gland is markedly enlarged to over 3 times normal size as a result of its attempt to compensate for part of the induced metabolic upset. This enlargement and other related manifestations such as soft bones are called Secondary Renal Hyperparathyroidism. Parathyroid Hyperplasia without known cause is called Primary Hyperplasia. Primary hyperplasia is quite rare.

Dr. L. Krook, Cornell, USA

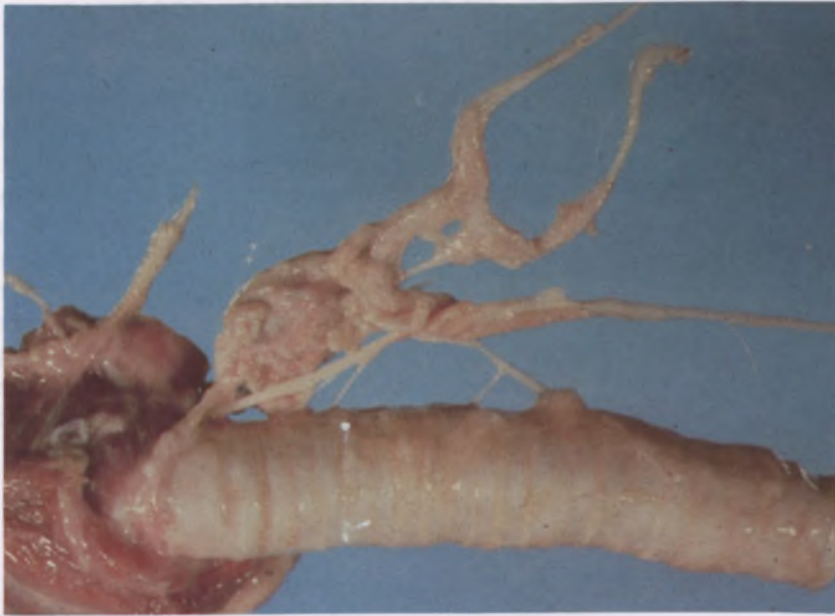

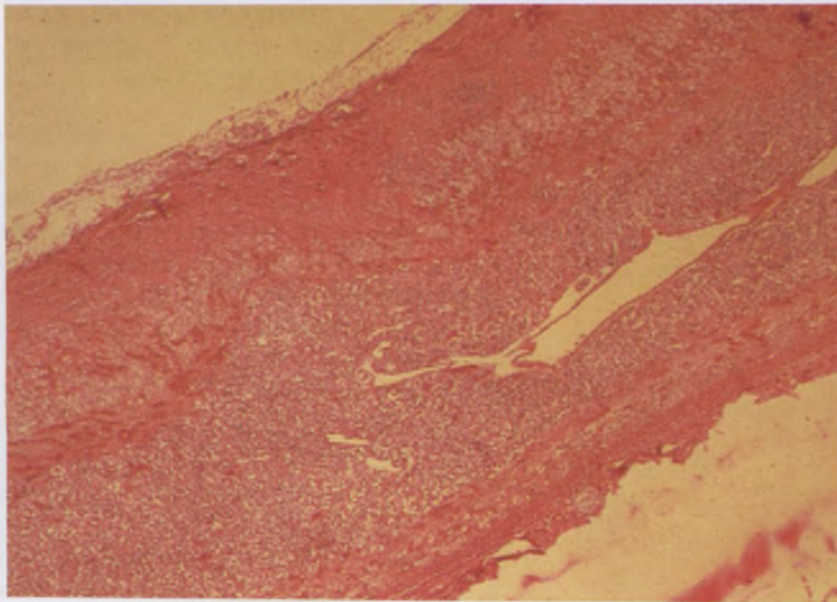
PLATE 721: THYROID ADENOCARCINOMA WITH VASCULAR INVASION

The tangled mass along one side of this dog's trachea is, in reality, a malignant tumor of the thyroid gland which has invaded the vessels of the area. Thyroid adenocarcinomas and adrenal pheochromocytomas are the two most likely tumors to have grossly visible vascular invasion, although many malignant tumors can be observed to invade vessels microscopically.

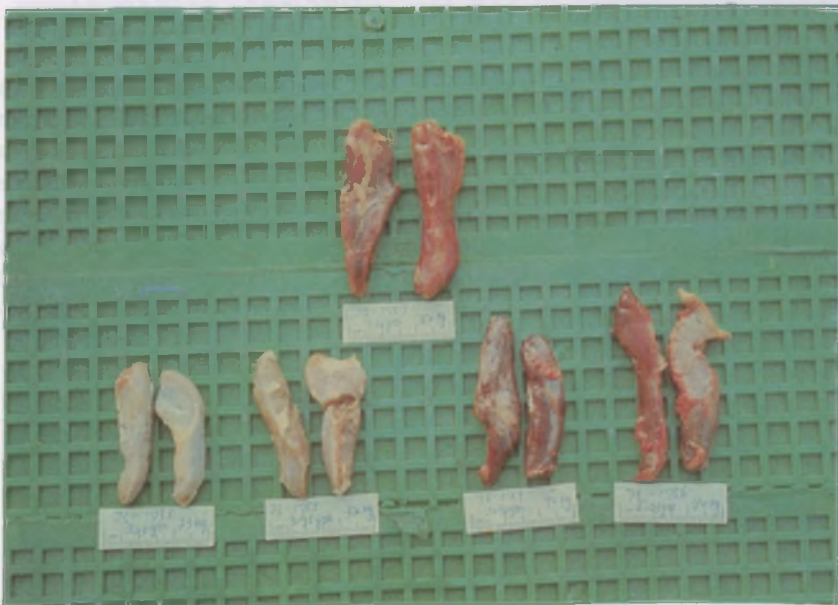

PLATE 722: ADRENAL HYPOPLASIA

The single pair of adrenal came from a 32 kg pig and the adrenals weighed a total of 7.6 g. The two pair of small pale adrenals came from 32 and 33 kg pigs with respective total adrenal weights of 3.93 and 3.95 g. The two darker pair on line with the smaller pale ones came from two 90kg pigs with their adrenals weighing 4.30 and 5.03 g. These last two adrenals are remarkably smaller than the two normal ones above. This apparent hypoplasia of the adrenals is the suspected cause of Porcine Stress Syndrome (PSS). It is hypoplasia and not atrophy as one can apparently find smaller than normal adrenals in many clinically normal pigs before the pigs reach the size when the adrenals are functionally inadequate, and then cause the several manifestations of PSS. We do not have evidence that the adrenals were once of normal size. If this were so then it would be True Atrophy.



Dr. J. Whitlock, Cornell, USA

PLATE 723: ADRENAL CORTICAL ATROPHY

The medulla of this dog's adrenal gland is essentially normal, but the cortex is only about $\frac{1}{4}$ normal size. Only a few vacuolated cortical cells are present, along with a few mononuclear cells in the relatively thickened capsule. This Adrenal Cortical Atrophy is sometimes thought to be the result of an autoimmune phenomenon, as it is with the chicken thyroid, but most of the time it is associated with chemical destruction as a result of dogs being treated for hyperadrenalcorticism. It is often seen as an example of Disuse Atrophy in cases of prolonged therapy with corticosteroids.

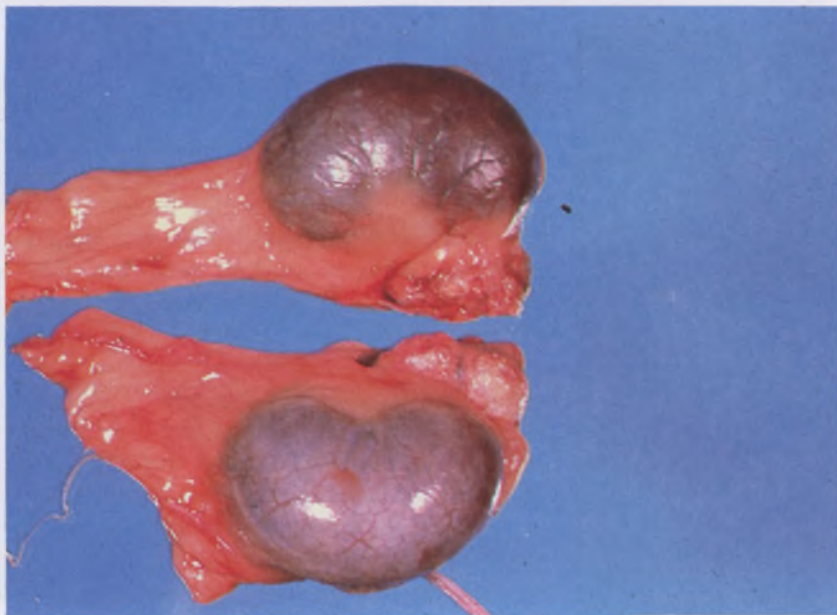
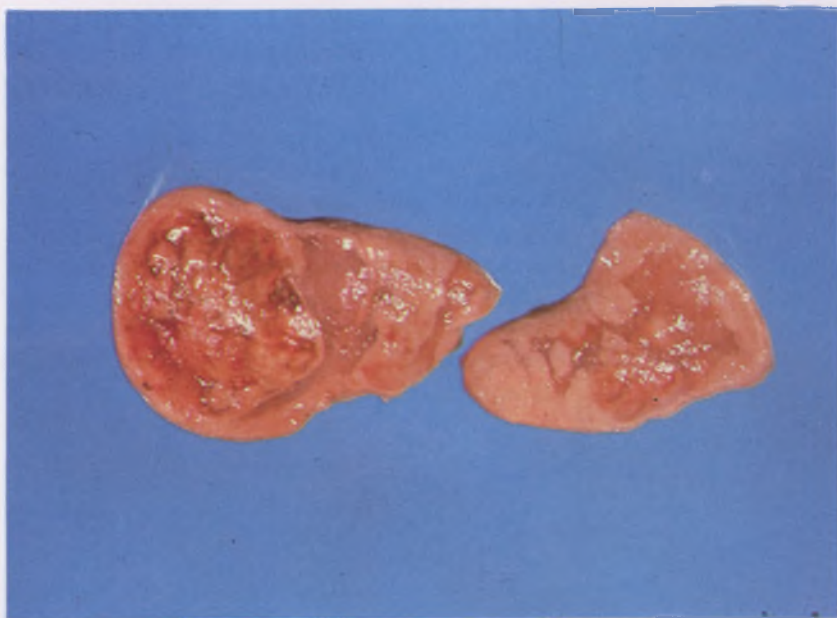
PLATE 724: ADRENAL CORTICAL HYPERPLASIA

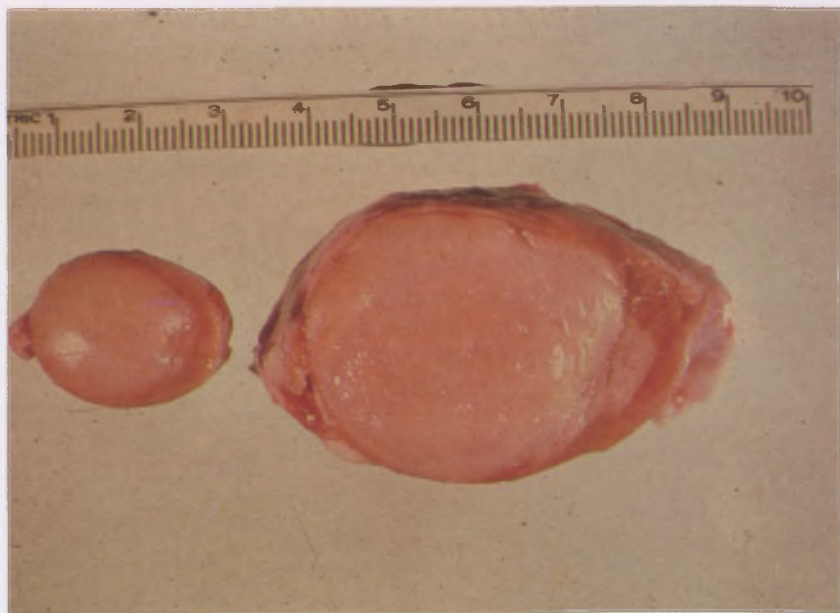
The enlarged finely nodular adrenal glands in this dog are the result of Cortical Hyperplasia. Although many consider that this is mediated through a pituitary gland hyperfunction, there is no evidence to support this. In most cases the dogs, or other animals with this lesion, are clinically normal as are their other endocrine glands. There is no doubt that some are hormonally stimulated, but probably the majority are not.

Dr. G. Cockerell, Cornell, USA



**PLATE 725: ADRENAL CORTICAL
HYPERPLASIA CORTICAL
ADENOMA AND
PHEOCHROMOCYTOMA**

The small adrenal in this dog shows the well marked infolding and pale thickening of the cortex that is Cortical Hyperplasia. The larger adrenal has the same Cortical Hyperplasia plus a discrete nodule making up half the gland. The nodule is slightly bloody and bulges more than the rest of the gland. This is a Cortical Adenoma, a benign tumor of the cortex. Alongside this large Cortical Adenoma is a smaller, grey, shiny mass slightly concave against the adenoma itself. This is a Pheochromocytoma, most of which are usually more tan than grey.



**PLATE 726: ADRENAL
LYMPHOSARCOMA**

The large pale swollen mass in the center of this cow's adrenal gland is a metastatic mass of Lymphosarcoma. A small bit of medulla is present and a small rim of brown cortical tissue surrounds the neoplastic lymphoid mass. Some suggest that the tumor may have metastasized to this site from another area, and others suggest that an oncogenic virus stimulated lymphocytes *in situ*. Lymphoid neoplasia is somewhat like Tuberculosis used to be as it can mimic many diseases by its location and destruction of tissue.

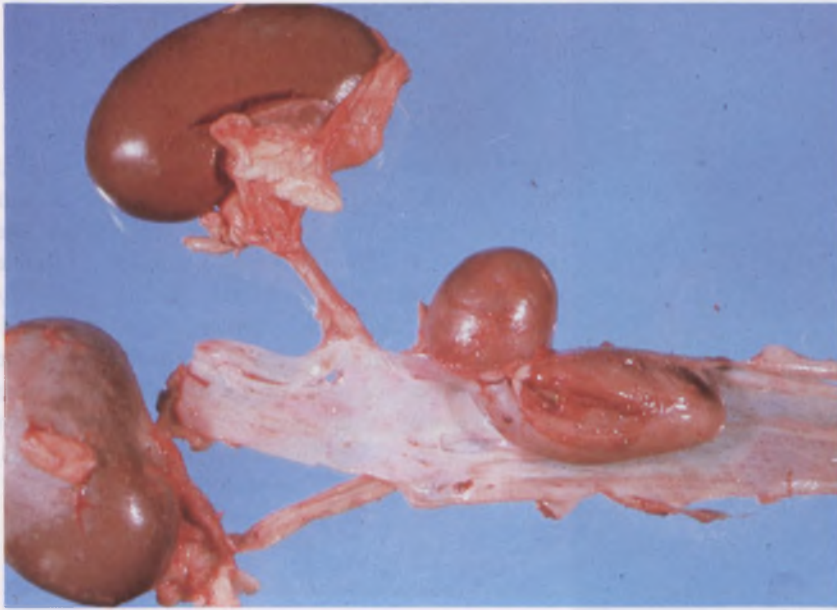


PLATE 727: ADRENAL PHEOCHROMOCYTOMA WITH VASCULAR INVASION

The abdominal vena cava near the kidney of this goat has been opened to show an invasive Pheochromocytoma from the adrenal gland. Pheochromocytomas and Thyroid Adenocarcinomas are the two non-vascular tumors most likely to show this marked propensity for grossly observable vascular invasion. Iodine staining of the fresh tissue often demonstrates the presence of medullary hormones (chromaffin reaction).

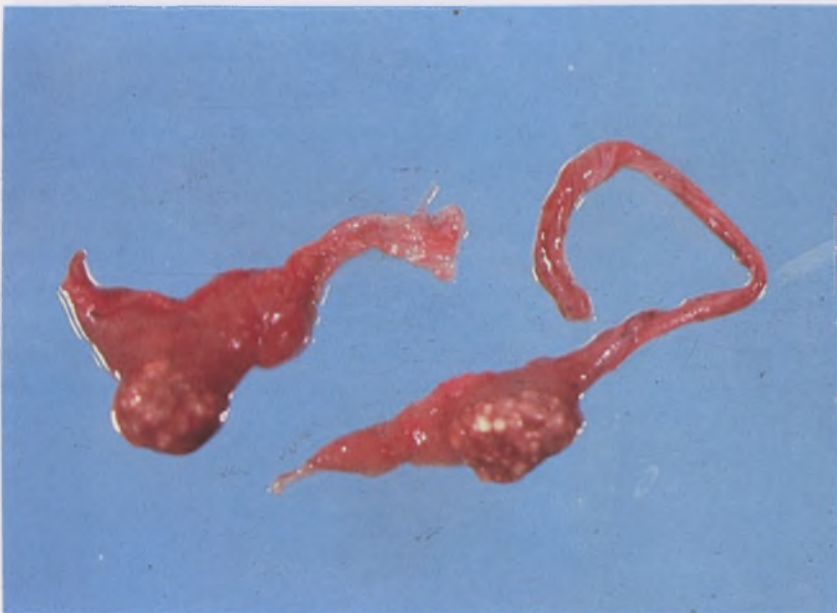


PLATE 728: CHOLESTERINIC GRANULOMAS

The two slightly thickened areas of tissue from a horse attached to a cord of pia mater are the choroid plexi of the lateral ventricles. In each there is a definite white speckled mass. These are granulomatous accumulations of cholesterol and other debris which are called Cholesteatomas. They are not true neoplasms but this older name will probably be around a long time. One text suggests calling them Cholesterinic Granulomas.

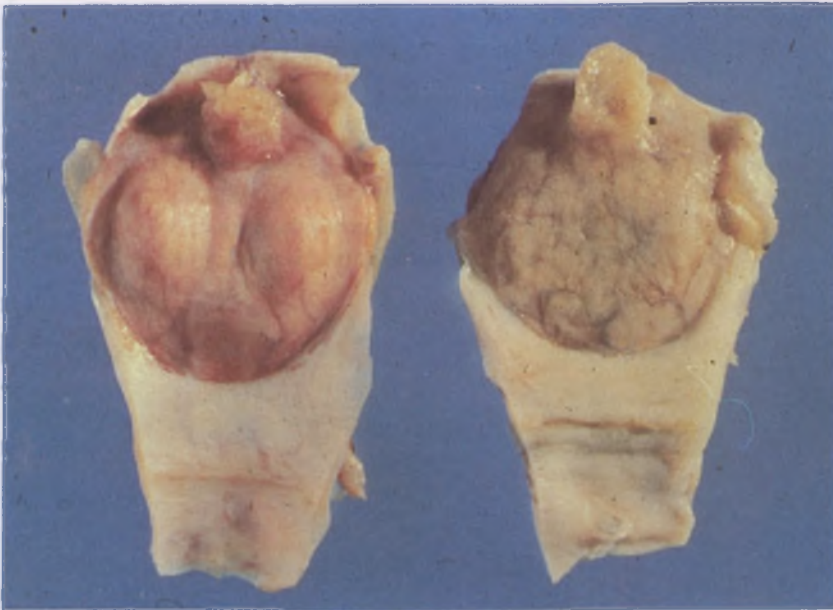

PLATE 729: PITUITARY HYPERPLASIA

The two pituitary glands from horses have been partially fixed in formalin, but that did not damage the lesion which is seen as the bilaterally bulging masses from the dorsal surface of one gland. The other gland is normal. These bulges are caused by Hyperplasia of the Pituitary. It is most often seen in older sheep that die suddenly with Enterotoxemia like signs and lesions. Actually, Pituitary Hyperplasia can be seen in many species but it is difficult to differentiate from benign neoplasia unless it is as symmetrical and outstanding as this one. It occurs in older animals just as tumors do.

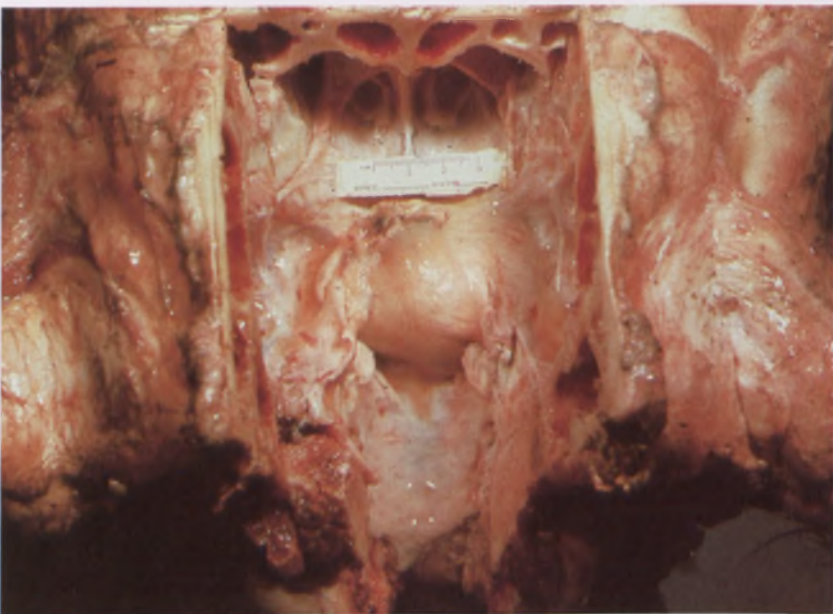


PLATE 730: PITUITARY ABSCESS

The large bulge in the floor of the brain of this cow is caused by an abscess which has replaced the pituitary gland and pushed the diaphragma sellae dorsally. *Corynebacterium pyogenes* is commonly isolated. Surprisingly many of these animals die suddenly without signs. Ear ticks in many countries are thought to be important initiating causes. Sheep, goats and other head butting animals are also prone to this problem, possibly because of vascular damage to the Circle of Willis around the pituitary.

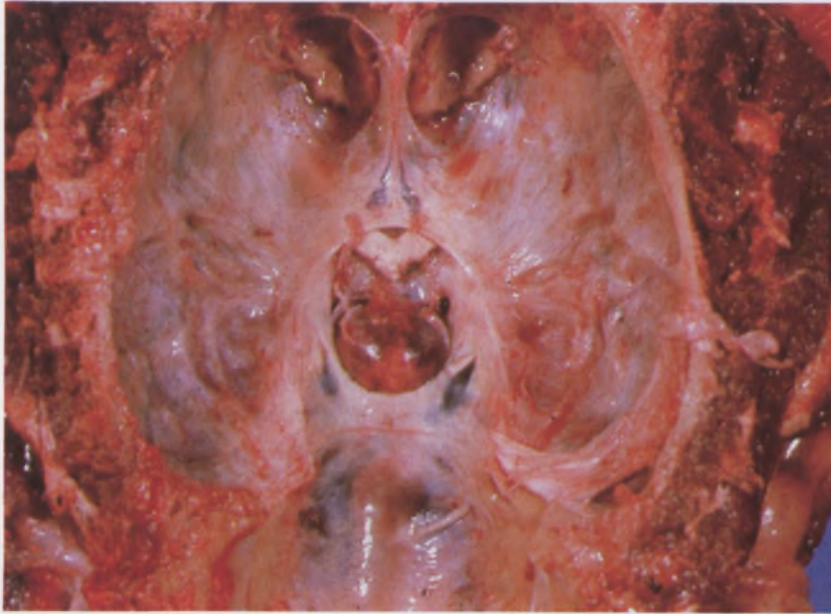

PLATE 731: PITUITARY (CHROMOPHOBE ADENOMA) TUMOR

The large, rounded red mass in this horse pituitary is a Chromophobe Adenoma, probably from the pars intermedia region of the pituitary. It is the most common tumor of the horse pituitary and many are associated with excessively long hair or Hirsutism. A histological evaluation is needed to be definitive.

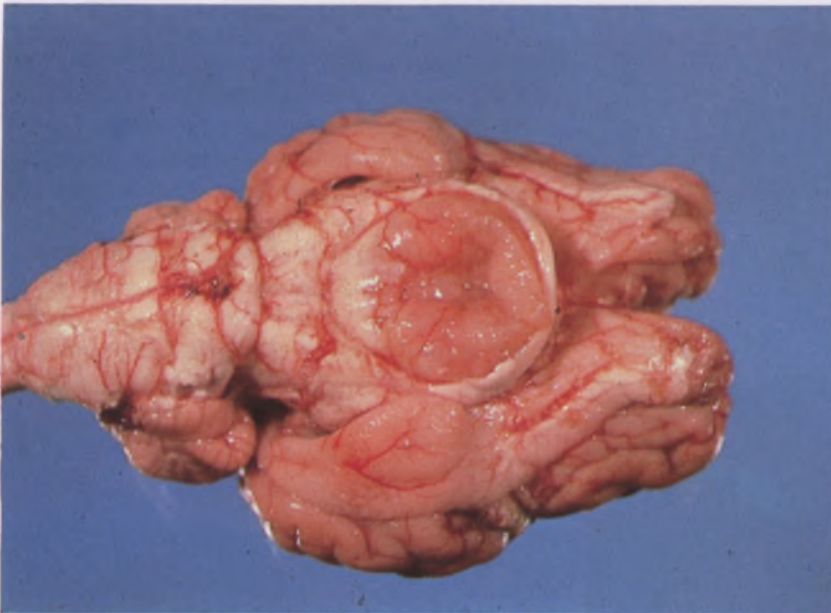


PLATE 732: PITUITARY (LYMPHOSARCOMA) NEOPLASM

The large mass on the floor of this goat's brain has pushed the optic chiasma forward as a pale white band. This mass is a Lymphosarcoma which has replaced the pituitary gland.

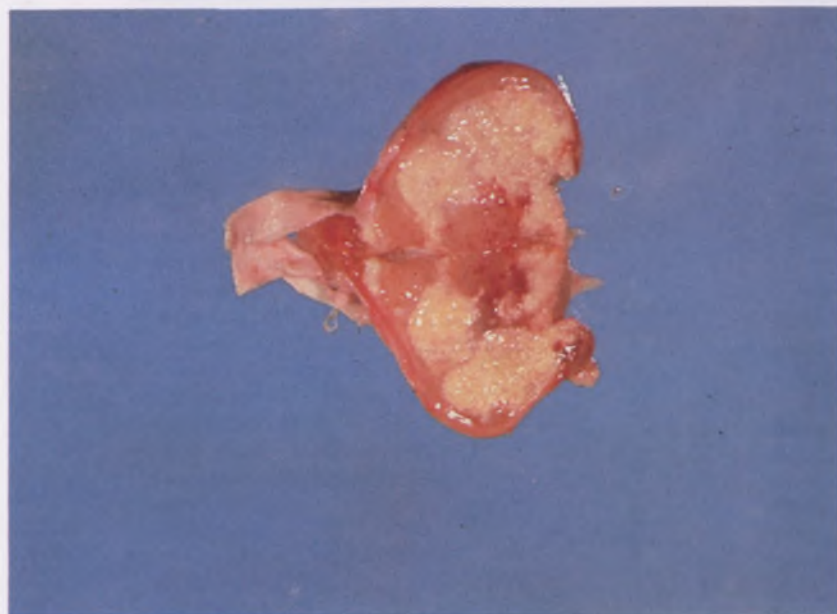


PLATE 733: PITUITARY (LYMPHOSAR-COMA) NEOPLASM

The red, thin rim is all that remains of the pituitary gland of a goat. The rest is pale viable Lymphosarcoma and opaque white mineralized degenerate Lymphosarcoma. Initially, this was considered to be Tuberculosis grossly, but histological study which is always necessary in these cases, proved it to be Lymphosarcoma.

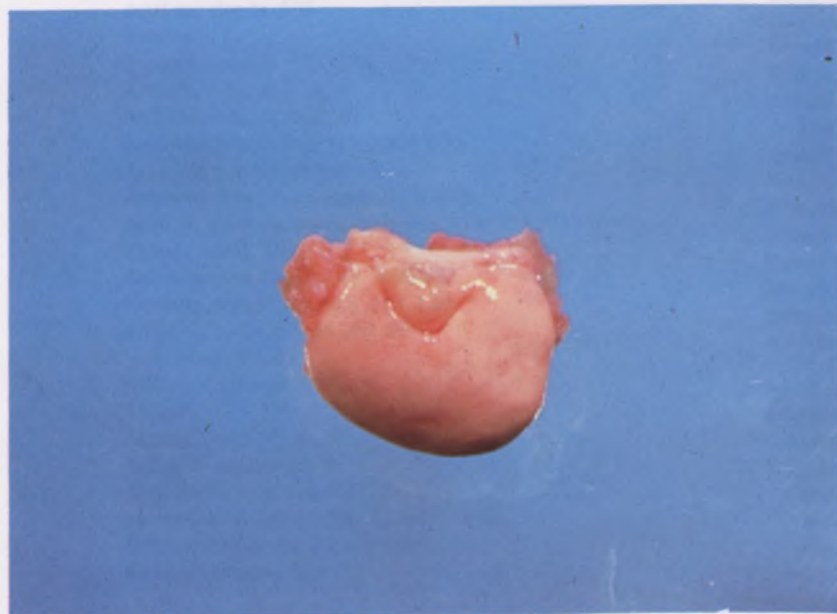


PLATE 734: PITUITARY (LYMPHOSAR-COMA) TUMOR

The entire pituitary has been replaced by a malignant mass, Lymphosarcoma, in this cow. This neoplasm is usually found in the right heart, abomasum, lymph nodes and uterus, but there may only be a solitary tumor often found within the vertebral canal.

- Ablation, gastric mucosa, 574
 Abomasitis, acute, focal 573
 Abomasitis, mycotic, 180
 Abortion, equine viral, 174
 Abortion, vibriotic, 169
 Abscess, endocardial parasitic, 486
 intestine, 640
 kidney, 246, 249
 liver, 172
 meningeal, 689
 mesenteric node, 532, 534
 pituitary, 729
 vena cava, 510, 511
 vertebral, 71, 72
 Acariasis, pulmonary, 425
 Accordion pleated intestine, 624
Actinobacillus equuli, 96, 246, 249, 390, 640
 Adenocarcinoma, intestinal, 672, 673
 metastatic, 137, 138, 139, 140
 nasal, 342
 thyroid, 721
 Adenoma, adrenal cortical, 725
 chromophobe, 731
 gall bladder, 199
 hepatic, 191, 192, 193
 pancreatic, 207, 208
 Adenomatoid reaction, 370, 399
 Adenomatosis, 401, 402
 Adrenomegaly, 20
 Aflatoxin, 161
 African horse sickness, 329
 Aging lipid deposits, 693
 Aleurostrongylus, 431
 Alopecia, 22
 Amyloidosis, renal, 227, 228
 Anal sacs, 675
 Anal sac glands, 675
 Anasarca, 1
 Ancylostomiasis, 663, 664
 Anemia, 120, 363
 Angiomatosis, scrotal, 59
 Annular constriction, intestinal, 672
 Anomalies, gall bladder, 196
 Anomaly, lymphatic vessel, 442, 443
 Aortitis, granulomatous, parasitic, 515, 516
 Aplasia, renal, 209
 Arteriovenous shunt, 445, 446, 447
 Arteritis, verminous, 518, 519, 520
 Arthritis, acute, 94, 95, 96, 99
 chronic, 89, 97
 Arthrosis, traumatic 90, 91
 Ascarids, 189, 190
 Aspergillosis, 290, 656
 Asthenia, cutaneous, 2
 Atelectasis, acquired, 365
 Atelectasis, anesthetic gas machine, 366, 367
 Atherosclerosis, 48, 49, 496, 497
 Atrophic rhinitis, 316
 Atrophy, adrenal cortex, 723
 brain, 703
 circular muscle, intestine, 634
 compression, liver, 154
 disuse of muscle, 105
 exhaustion, intestine, 634
 liver 143, 144, 148
 myocardial, 151
 neurogenic of muscle, 105
 pancreas, 204
 renal, 218
 starvation, 148
 Autoimmune hemolytic anemia, 46
 Autolysis, 143, 144, 145
 renal, 218, 219
 Babesiosis, 46, 276, 527
Bacillus cereus, 288
Bacillus piliformis, 167
 Balbiania, 557
 Barber pole worms, 608
 Barbiturate salts, 344
 Beetles, blister, 16, 17
 Big head, 68
 Bile duct fluke, 198
 Bile duct tapeworm, 182
 Blackleg, 112, 113, 114, 115, 481
 Blastomycosis, 415
 Blistering, 631
 Bloat, frothy, 106
 Bloat line, 106, 545
 Blue bag, 300, 301
 Blue tongue, 555
 Bodies, intimal, 495
 Bone marrow, fatty, 63
 Bone, metaplastic, 11
 Botryomycosis, 302
 Bovine bacillary hemoglobinuria, 162
 Bovine malignant catarrh, 30, 31, 32, 33, 327, 328, 554
 Bovine virus diarrhea, 32, 34, 35, 550, 551, 552, 553, 554,
 598, 650, 651, 652
 Brain/Heart syndrome, 477, 478, 479
 Bronchiolitis obliterans fibrosa, 380, 381
 Bronchiolitis, mucoid 387, 388
 Bronchopneumonia, 390, 398
 Brown dog gut, 621
 Brucella, 306, 307
 Bunostomum, 664
 Bursitis, traumatic, 14
 Cachxia, 8
 Calculi, cholesterol, 153
 gutteral pouch, 325
 renal, 234
 urethral process, 274
 urinary bladder, 275
Campylobacter fetus, 169

- Candidiasis, 558
 Cantharidin, 16, 17, 631
 Caprine leucoencephalomyelitis, 99
 Cardiomyopathy, congestive, 150, 451, 457, 458
 hypertrophic, 451, 459, 460
 neurogenic, 478, 479, 480
 Caseous lymphadenitis, 252, 536
 Cattle grubs, 51
 Celiac disease, 9
 Cellulitis, 116
 Cestrum, 221, 230
 Chemosis, 717
 Choke, esophageal, 546
 Cholangitis, parasitic, 184
 Cholangitis, suppurative, 171
 Cholesteatoma, 728
 Chronic passive congestion, liver, 150, 156
 Cirrhosis, cardiac, 151, 152, 156
 portal, 153, 156
 Claviceps, 18, 19
Clostridium chauvoei, 112, 113, 114, 115, 481
Clostridium hemolyticum, 162, 244
Clostridium perfringens, 111, 218, 595, 641, 702
Clostridium septicum, 112, 116
 Coccidiosis, 660
 Coital exanthema, 289, 308
 Colitis, boxer, 682, 683
 exhaustion, 680, 681
 fibrinopurulent, 685
 granulomatous, 682, 683
 ulcerative, 681, 682
 Colitis X disease, 680, 681
 Colostrum globules, 619
 Compensation, 450
 Compression, spinal cord, 93
 Congestion and edema, passive, liver, 150, 151,
 152, 155, 156
 passive, lung, 418
 pulmonary, 354
 Conjunctivitis, 30
 Coning, cerebellar, 698
 Constriction, annular, intestine, 672
 Contagious ecthyma, 40
 Contamination, bacterial, 145
 Core temperature, 13
Corynebacterium equi, 534, 535
Corynebacterium ovis, 536
Corynebacterium pseudotuberculosis, 252
Corynebacterium pyogenes, 326
Corynebacterium renale, 250
Cowdria ruminantium, 345, 436, 706
 Crostalaria, 22, 377, 378, 379
Cryptococcus neoformans, 712, 713
 Cups, endometrial, 283
 Cuterebra, 707
 Cyst, congenital, renal, 210, 211
 cortical, renal, 216
 endometrial gland, 284
 hepatic, 141
 medullary, renal, 212
 perineal hernial, 107
 prostate, 107
 sinus, mucous, 313, 314
 sinus, ossified, 315
 ultimobranchial duct, 719
 valvular, congenital, 444
 Cysticercosis, 181
 Cystitis, urinary, lymphoid, 277

 Daughter spleens, 522
 Decomposition, postmortem, 143, 144
 Defect, septal, subaortic, 449, 483
 Defect, septal, subaortic, nonpatent, 458
 Deficiency, thiamine, 696
 vitamin A, 694
 vitamin K, 222, 273
 Degeneration, costal cartilage, 86
 epithelial, rumen, 598
 ischemic, of muscle, 104
 muscle, 101, 102, 103, 543
 optic nerve, 694
 Zenker's, 103, 364
 Dehydration salts, 217
 Deposits, aging lipid, 693
 Dermatitis, allergic, 12, 50
 chemical, 15, 20
 mycotic, 47, 48, 49
 penicillin, 12
 viral, 30, 31, 32, 33, 38, 39
Dermatophilus spp. 48
 Dermatosparaxis, 2
Dicrocoelium dentriticum, 184, 187
 Dictyocaulus, 419
 Dilatation, cardiac, 449, 450
 intestine, 636
 lacteals, 620
 lymphatics, subpleural, 351
 poststenotic, pulmonary, 450
Dirofilaria, 418, 428
Dirofilaria immitis, 487
 Disease, Aujeszky's (see pseudorabies)
 bran, 69
 celiac, 9
 colitis X, 680, 681
 hydatid, 73
 Johne's, 9, 637
 myeloproliferative, 266, 528
 navicular, 85
 nodular worm, 659
 parvovirus, 135, 646, 647, 648
 silo filler's, 380, 381
 Theiler's, 148, 175
 turning, 512, 705

- Tyzzer's, 167
 Vit.E/Selenium responsive, 103, 151
 Wesselsbron's, 349, 703
 Whipple's 682, 683
 white muscle, 151, 364, 461, 543
 Disseminated intravascular coagulation, 253
 Distomiasis, 187
 Diverticulum, Meckel's, 618
 propulsion, 632
 Dog sitting position, 71
 Dwarfism, 3, 4
 Dwarf, pituitary, 4
 Dysentery, winter, 690
 Dysplasia, cervical vertebral, 82
 hip, 88
 hoof wall, 6
 Dysplastic, antler, 5
 Dystrophy, nutritional muscular, 461
- Ecchymoses, 663, 688
 Echinococcosis, 73
 Ectopic gut epithelium, 448
 Ectopic pancreatic tissue, 617
 Edema, aortic valve, 452
 colon, 679, 680, 681
 gall bladder, 197
 hindquarters, 106
 hypoproteinemic, 678
 lung, 355
 pitting, 10
 trachea, 329
 Edemamagena, 51
 Eimeria, 660
 Eleaophora, 515
 Emaciation, 8, 9
 Embolism, pulmonary, 428
 Embryonic brain damage, 349
 Emphysema, alveolar, 386
 lung, 398
 urinary bladder, 268, 269
 Encephalitis embolic, 700
 Encephalomalacia, basal ganglia, 695, 702
 contact, 696
 Encephalomyelitis, suppurative, 701
 Endocarditis, vegetative, 13, 700
 vegetative secondary, 483
 Endometrial cups, 283
 Enteritis, granulomatous, 123, 653, 654
 purulent, 643, 644
 Enterotoxemia, 111, 218, 595, 641, 689
 Enzootic hematuria, 280
 Enzootic icterus 231
 Epicauta, 16
 Equine infectious anemia, 405, 537
 Equine viral abortion, 174, 407, 408, 409
 Ergot, 18, 19
- Erosion, enamel, 544
 esophagus, 552, 553
 oral, 554
 Erysipelas, 253
Erysipelas insidiosa, 98
Escherichia coli, 94
 Esophagitis, blister beetle, 548
 Esophogostomiasis, 659
Eurytrema pancreaticum, 198
 Eversion, gastric, 564, 565, 589, 590
 Exostosis, 549
 multiple cartilagenous, 62
 Exsanguination, 296, 571, 572
 Eye worms, 718
- Facial eczema, 160
 Farmer's lung, 414
 Fascioliasis, 184, 185, 186
 Fascioides, 185, 426
 Fat necrosis and sclerosis, 124
 Feline infectious peritonitis, 132, 133, 134, 254
 Feline polyarthritis, 100
 Fescue foot, 21
 Fetallization 370
 Fibropapilloma, urinary bladder, 280
 Fibrosarcoma, nasal, 341
 skin, 58
 Fibrosis, auricular, 464
 capsular, neoplastic related, 139, 195
 focal, lung, 357, 358
 interstitial, pancreas, 206
 interstitial, renal, 229
 lobular, pancreas, 202
 pancreatic, 204
 parasitic, 156
 perilobular, pancreas, 205
 Fibrous tags, lung, 356
 Filaroides, 420, 421, 422
 Flukes blood, 183
 blood portal vein, 513, 514
 liver, 184, 186
 rumen, 662
 Foreign body, intestine 633
 intestine, soft, 634
 linear, 624, 625, 657
 oral, 547
 spinal cord, 709
 Fossae, normal synovial, 83
 Founder, 7
 Founder, road, 7
 Fractures, pathological, 65, 80, 81
 Frostbite, 21
Fusobacterium necrophorum, 165, 172

INDEX

- Gangrene, 18, 19, 21
Gasterophilus, 660
Gasterophilus intestinalis, 606, 607, 609
Gasterophilus nasalis, 609
Gastric eversion into esophagus, 564, 565
Gastric parasitic brood pouch (*D. megastoma*), 610, 611, 612
Gastric parasitic brood pouch (*S. lupi*), 603
Gastritis, hypertrophic, 604
 mycotic, 599, 600
 parasitic, 605
Granularity, serosal, 135
Granulation tissue, capsular, 254
Granulation tissue, exuberant, 43
Granuloma, cholesterinic, 728
 parasitic, aortic, 516
Guttural pouch, calculi, 325
 infection, mycotic, 335
- Hairballs, 562
Hamartoma, hepatic, 142
Heartworms, 418
Heaves, type I, 386
 type II, 387, 388
Hemal nodes, 531
Hemangiosarcoma, heart, 491, 492
 intestinal, 671
 lung, 434
Hematoma, lung, 389
 splenic, 523
 uterus, 297
Hemoglobinuria, 226, 232, 233, 244
Hemomelasma ilei, 123, 124, 125
Hemonchus contortus, 120, 608
Hemophilus, 392, 701, 710
Hemophilus somnus, 593
Hemorrhage, post surgical, colon, 676
 renal, 222, 257
 renal, secondary, 70
 subendocardial, 452
 subserosal, traumatic, 627
 suffusion, 111
 traumatic, heart, 477
 urinary bladder, 273
Hepatitis, bacterial, 165, 166, 167, 168
 mycotic, 179, 180
 parasitic, 181, 188
 protozoal, 177
 viral, 173, 174, 176, 403
Hepatoma, 191, 192, 193
Hepatitis, toxic, hepatitis X, 157, 158, 159, 160, 161
Hernia, diaphragmatic, 109
 perineal, 107
Hemial rings, 127
Histoplasmosis, 416, 417
Hookworms, 663, 664
- Hyaline membrane, 371
Hydropericardium, 436
Hydrothorax, 345
Hygroma, 14
Hyperparathyroidism, nutritional secondary, 68, 69
 renal secondary, 170
Hyperplasia, adrenal cortex, 724, 725
 arterial, 520
 cerebellar, 704
 cystic, gall bladder, 191
 gastric, 566, 568
 intestinal lymphoid tissue, 641
 intestinal mucosa, 660
 parathyroid, 577, 720
 pituitary, 729
 renal, 209
Hypertrophic osteodystrophy, 66, 67
Hypertrophy, arterial, 520
 cardiac, 450
 cardiac, secondary, 450
 gastric, 566, 568
 idiopathic, esophagus, 541
 idiopathic, ileum, 622, 632, 636
 intestine, secondary, 636
Hyphe, 717
Hypoderma, 51
Hypoplasia, adrenal, 722
 cortical, renal, 216
 lung, 349, 703
 pancreas, 200, 201
 renal, 209
- Icterus, 25, 46, 213
Idiopathic hypertrophy, ileum, 622
Ileus, meconium 674
Impaction, abomasal, 586
Implantation foci, tumor, 137, 138
Inclusion bodies, 176, 255
Infarction, auricular, heart, 466
 cerebellum, 705
 colon, 692
 ear, 13
 guttural pouch, mycotic, 335
 liver, 162, 163, 164
 lung, 368
 mammary, 299
 myocardial, 465
 polar, kidney, 223
 pulmonary artery, 505
 renal, 216, 219, 220, 223
 tail, 13
 vertebral, 79
Infectious bovine rhinotracheitis, 32, 330, 398, 596
Infectious canine hepatitis, 46, 135, 176, 255
Injection, intracarotid, 697
Interstitial cell tumor, 311, 312

- Intestinal knotting, 628, 629
 Intestine, accordion pleated, 624
 Intimal bodies, 495
 Intussusception, 623, 636, 647
 Invasion, vascular, 721, 727
 Ipemanol, 375, 376
- Jaagsiekte**, 401, 402
Japanese yew, 28
Jaundice, (see icterus)
Joint mice, 84
- Kidney worm**, 188
Knotting, intestine, 628, 629, 630
- Lantana**, 23, 24, 25, 26
Laryngitis, fibrinonecrotic, 328
 parasitic, 336
 toxic, arsenic, 323
Leiomyoma, 129, 291, 616
Leiomyometaplasia, 621
Leptospirosis, 46
Linear foreign body, 623, 624, 625, 657, 658
Linear friction ulcers, 623, 624, 625, 657, 658
Lipid deposits, aging, 693
Lipidosis, hepatic, 148, 156
 tubular, renal, 216
Lipofuscinosis, intestinal, 621
Lipoma, infiltrating, 54, 117, 118
 pedunculated, 129, 130, 131
Liver, dishrag, 148
 nutmeg, 150, 151
Lymphadenopathy, splenic, 537
Lymphangiectasis, 620
Lymphangitis, necrotizing, 508, 509
Lymphosarcoma, abomasum, 614
 adrenal, 726
 bone, 78, 79
 cardiac, 488
 dermal, 54, 56
 esophagus, 561
 gastric, 615
 intestine, 666, 667, 668, 669
 liver, 156, 194
 lymph node, 538
 mammary gland, 305
 oral, 560
 pericardium, 440
 pituitary, 732, 733, 734
 pleural, 348
 pulmonary, 433
 renal, 216, 260, 261, 262, 263, 264, 265
 spinal cord, 715, 716
 splenic, 528
 subperiosteal, 76, 77
 urinary bladder, 278
 uterus, 292, 293
- Maedi**, 399, 400
Malabsorption, 9
Malignant catarrhal fever (see Bovine Malignant Catarrh)
Malignant Edema, 116
Malnutrition, 8
Maple sugar intestine, 621
Marasmus, 8
Marsh's progressive pneumonia, 399, 400
Mast cell tumor, bone marrow, 74
 intestine, 670
 skin, 60
 urinary bladder, 279
Mastitis, granulomatous, 302
 septic, 298, 300, 301, 304
 staphylococcal, 302, 303
Mastocytosis, 61
Meconium plug, tracheal, 409
Medulloblastoma, brain, 708
Megaesophagus, 493, 540
Melanoma, vertebral, 75
Melanosarcoma, heart, metastatic, 490
 skin, 57
Melanosis, intimal, 441
 pulmonary, 352
 renal, 215
 tracheal, 353
Melia, 29
Meningitis, fungal, 712, 713
 suppurative, 698
Meullerius, 432
Metastrongylus, 429, 430
Metritis, mycotic, 290
 septic, 287, 288
Microfilaria, 52
Migration, ascarids, 189, 190
Mineralization, aortic, 498
 aortic base, 468
 arterial, 499
 brain, 703
 endocardium, 467
 gastric, 575, 576, 577, 578
 pharyngeal, uremic, 317
 pleural, uremic, 346, 347
 pulmonary, 359, 362
 pulmonary artery, 361
 pulmonary, uremic, 360, 361
 renal, 221
 tracheal, 318
 uremic, 500
Motor oil, 27
 mortierla spp, 49
Mucoid bronchiolitis, 387, 388
Mucormycosis, 49, 600

INDEX

- Muellierus, 432
Mycobacterium paratuberculosis, 637, 638, 639
 Mycotic gutteral pouch infection, 335
 Myelitis, bacterial, 710
 herpes, 711
 Myiasis, 609
 Myiasis, cerebral, 707
 Myocardial degeneration, toxic, 470
 Myocarditis, bacterial, 481
 embolic, 482
 toxoplasma, 484
 Myopathy, capture, 469
 exertional, 469
 Myositis, bacterial, 112, 113, 114, 115, 116
- Nasal granuloma, 331, 332
 Necro, 165
 Necrobacillosis, 165
 Necrosis, colon, 686, 687
 epithelial, uremic, 542
 fat nad sclerosis, 121, 122
 fat granulomatous, 126
 fat types, 203
 hepatic 148, 157, 158, 159, 166, 167, 175
 intestine, 644, 645
 lymphoid, ileum, 242
 medullary, renal, 235, 236, 237, 238, 239, 240, 241, 242, 243
 pancreatic, 202
 pancreatic, fat, 203
 Peyer's patch, 650, 651, 652
 pressure, fundus, bladder, 271, 272
 Neonatal isoerythrolysis, 213, 214
 Nephritis, granulomatous, 256, 259
 interstitial, 216
 Neurofibroma, heart, 489
 Neurogenic cardiomyopathy, 478, 479, 480
Nocardia asteroides, 168
 Nodules, friction rub, heart, 463
 Nonpatent subaortic septal defect, 458
 Nutmeg, 150, 155, 156, 457
- Ochratoxin, 229
 Omasitis, caustic, 580
 toxic, 579, 580
 Omphalophlebitis, suppurative, 170
Onchocerca, 52
 Orchitis, brucella, 306, 307
 Orf, 40
 Osteoarthropathy, degenerative, 89
 Osteodystrophic lines, 64
 Osteogenic sarcoma, bone, 80, 81
 lung, 435
 nasal, 340
 Ostertagiosis, 605
 Ostrochondrosis dissicans, 84
- Overeating disease, 579
 Ox warbles, 51
- Pachymeningitis, parasitic, 714
 Pacinian corpuscles, 119
 Panleucopenia, 648, 649, 691, 704
 Papillae, unguiculate, 563
 Papillary acanthosis, 53
 Papilloma, urinary bladder, 280
 Papillomatosis, 44, 45
 Papular stomatitis, 556, 597
Paramphistomum cervi, 662
Parascaris equorum, 657, 658, 665
 Paratuberculosis, 637, 638, 639
 Parvovirus disease, 646, 647, 648
 Pasteurella, 162, 163, 174, 300, 301, 304, 393
 Pathological fractures, 65
 Perforation, gastric ulcer, 592
 uterus, 286
 Periarthritis nodosa, 506, 507
 Pericarditis, fibrinopurulent, 437, 438, 439
 Peritonitis, 132, 133, 134, 136, 592
 Persistent right aortic arch, 493
 Pharyngitis, arsenic, 322
 Pheochromocytoma, 725, 727
 Photosensitization, 23, 24, 25, 26, 160
 Pigment, fluke, 185, 186
Pithomyces chartarum, 160
 Plaques, epithelial, gastric, 607
 epithelial, placenta 281, 282
 hyperkeratotic placental, 281
 peritoneal fibrotic, 128, 149
 Pneumocystosis, 395, 410, 411, 412
 Pneumonia, adenovirus 406
 chronic 395, 397
 enzootic calf, 384, 394
 enzootic sheep, 396
 equine virus abortion, 407, 408, 409
 foreign body, 364
 hemophilus, 392
 herpesvirus, 403, 404
 inhalation, 364
 Marsh's progressive, 399, 400
 mycotic, 413, 415, 416, 417
 parasitic, 422, 423, 424, 425, 426, 427, 428, 429, 430, 431, 432
 proliferative, 369, 370, 371, 372, 373, 374, 375, 376, 377, 378, 379, 382
 proliferative, secondary, 383
 proliferative, secondary, unilateral, 384, 385
 Pneumonitis, post fogging, 419
 Pneumonyssus, 425
 Pododermatitis, chronic, 7
 viral, 34
 Poisoning, aflatoxin, 161
 asphalt, 157, 158, 159
 arsenic 235, 236, 321, 322, 323, 324
 blister beetles, 16, 17, 547
 blue-green algae, 178

- Bracken fern, 280
 cantharidin, 470
 Cestrum, 221
 copper 231
 Crotalaria, 22
 dicoumerol, 110, 111
 ergot, 18, 19
 fertilizer, 15
 Fescue, 21
 Lantana, 23, 24, 25
 lead, 27
 Melia, 29
 nonsteroidal anti-inflammatory, 237, 238, 239, 240, 241, 242, 243

 ochratoxin, 229
 penicillin, 11
 Perilla, 372
 red maple, 233
 sporodesmin, 160
 strychnine, 585
 Taxus, 28
 vetch, 20
 vitamin D, 221, 359, 467
 Polyarthritis, feline, 100
 Polymicrosporon, 413, 414
 Polyp, fibromatous, 291
 nasal, 343
 Porcine stress syndrome (PSS), 101, 102, 721
 Porphyrinosis, congenital, 539
 Portoazygous shunt, 494
 Post fogging pneumonitis, 419
 Post necrotic scarring, 156
 Postpartum hemoglobinuria, 244
 Prepuccitis, mycotic, 309
 Prolapse, cerebellar, 698
 intervertebral disc, 92, 93
 Proliferation, papillary, gastric, 570
 Prolonged gestation, 212
 Pseudohyperparathyroidism, 362, 467, 499
 Pseudohypertrophy, gastric folds, 567
 Pseudomelanosis, 215, 267
 Pseudorabies, 36, 37, 166, 173
 Pulpy kidneys, 218, 219
 Pyelonephritis, chronic, 216
 hemorrhagic, 245, 247, 248, 250, 251

 Queensland itch, 50

 Reaction, adenomatoid, 399, 400
 anaphylactoid, lung, 355
 jet, 449, 462
 parachute, 462
 splash, 449, 462
 Red maple, 233
 Red water, 276
 Regeneratoin, liver, 152, 153, 160

 Rhinitis, fibrinonecrotic, 327
 granulomatous, 331
 purulent, 326
 toxic, arsenic, 321, 322
 Rhinopneumonitis, 711
 Rickets, 65
 Ring, subaortic stenotic, incomplete, 454, 455
 Ring tail, 13
 Roarer, 105
 Rumenitis, bacterial, 593
 mycotic, 179, 180, 581, 601
 toxic, 172, 579, 581, 582, 583
 viral, 596, 597
 Rupture, abdominal muscle, 108
 aortic valve, 472, 473
 atrial, 471, 474
 bladder, urinary, 267, 270
 chordae tendinae, 471
 gastric, 587, 588
 intestine, parturition related, 626
 lung abscess, 168

 Sadism, 684
 uterus, 286
 Salmonellosis, 95, 166, 525, 642, 643, 644, 645, 685, 686, 687, 688
 Sand, bursal, 14
 Sarcoid, 42, 43
 Sarcosporidiosis, 485, 557
 Scarring, postnecrotic, 156
 plumonic, 418
 rumen, 594
 Schistosomiasis, 183, 514
 Sclerosis, neoplastic omental, 139, 140
 Scrapie, 41
 Sequestrum, bone, 549
 Sertoli cell tumor, 312
 Shipping fever of cattle, 393
 Shipping fever of horses, 391
 Shock, terminal, 691
 Shunt, arteriovenous, 445, 446, 447
 portoazygous, 494
 Sinusitis, mycotic, 333
 Site, injection, intracardiac, 456
Spirocerca lupi, 516, 517, 559, 603, 714
 Splenitis, bacterial, 525
 Splenomegaly, 46, 526
 infectious, 524, 527
 neoplastic, 528, 529
 Spondylosis, 87
 Sporotrichum, 47
 Squamous cell carcinoma, gastric, 613
 nasal cavity, 339
 penis, 310
 sinus, 338
 tonsil, 337
 uterus, 294
 Staphylococci, 302, 391, 532
 Starvation, 8
 Stenosis, pulmonic, 450

INDEX

- subaortic, 451, 452, 453
- Stephanuriasis, 188, 258
- Stilesia, 182
- Stomach, normal, 569
- Streptococci, 391, 533, 534
- Strongyloides, 423
- Strongylus, 257, 424, 427, 518, 519, 520, 692
- Strongylus edentatus*, 136
- Suffocation, 546
- Sweet potatoes, 375, 376
- Swine manure, 373, 374
- Swine pox, 38, 39
- Syndrome, fatty liver, 146, 156
 - porcine stress, 101, 102
- Syngamus laryngeus*, 236
- Synovitis, proliferative, 98

- Tamponade, cardiac, 475, 476
- Taxus, 28
- Telangiectasis, 147
- Theileria, 512
- Theileria mutans*, 705
- Thelazia qulosa*, 718
- Thelitis, 35
- Threshold, liver regeneration, 152, 153
- Thromboembolism, 504
- Thrombosis, aortic, 104, 453, 474, 475, 502
 - atrial, 474
 - cerebral vascular, 512
 - esophageal vein, 501
 - glomerular, 253
 - jugular vein, 503
 - mycotic, 602
 - pulmonary artery, 361, 428, 504
 - renal vein, 224, 225
- Thymoma, 530
- Thysanosoma, 182
- Tiger striping, colon, 677
- Torsion, gastric, 589
- Torsion, intestine, 635
 - lung, 368
 - lung, *in utero*, 350
 - uterus, 285
- Toxoplasmosis, 166, 177, 256, 484
- Tracheitis, fibrinonecrotic, 330
 - mycotic, 334
- Tracheobronchitis, parasitic, 420, 421
- Transmissible venereal tumor, 295
- Trauma, colon, sadistic, 684
 - dermal, 36, 37
- laryngeal, 319, 320
 - spleen, 521
 - urinary bladder, 270
 - uterus, 286
- Trichobezoars, 562
- Tularemia, 166
- Tumor, fetal, 142
- Turning disease, 512

- Ulcer, abomasum, 571, 573
 - button, 687
 - caustic, 584
 - dental pad, 555
 - gastric, 574, 591, 592
 - gastric, congenital, 609
 - linear friction, 623, 624, 625
 - mucosal, 550
 - mycotic, 655, 656
 - neoplastic, 666
 - perforating, parasitic, 661
 - rumen, 172, 583, 594
- Unequal expulsion of blood, 521
- Ungiculate papillae, 563
- Uremic frosting, 345, 347

- Vasculitis, mycotic 602
- Vegetative endocarditis, 482, 483
- Verrucous endocardiosis, 462, 471
- Vetch, 20
- Vibrio, 690
- Vibrio fetus*, 169
- Vicia, 20
- Volvulus, intestine, 635

- Warbles (see Grubs)
- Warts, 44
 - interdigital, 45
- Wesselsbron's disease, 703
- White muscle disease, (See Disease)
- Winter dysentery, 690
- Wobbler foal, 82

- Zenker's degeneration, 103

AN ATLAS OF GENERAL PATHOLOGY
VOLUME II

家畜病理學圖譜 (二)

有著作權・不准翻印

著 者 John M. King 李 崇 道
著作權所有人 李 崇 道
發 行 人 同 上
發 行 所 行政院農業發展委員會
中華民國台灣，台北市南海路卅七號
印 刷 所 沈氏藝術印刷股份有限公司
中華民國台灣，台北縣中和市中山路二段421號

中華民國72年3月出版・4000本

定價：台灣區 新台幣1200元
海 外 美 金 40元

