

Development of methodologies and initial testing for a survey of the northeastern United States for the presence of *Angiostrongylus vasorum*

Honors Thesis

Presented to the College of Agriculture and Life Sciences, Department of Animal Science
of Cornell University
in Partial Fulfillment of the Requirements for the
Research Honors Program

by

Ellen Kay Haynes
May 2009

Dr. Dwight Bowman, research advisor

Abstract

Angiostrongylus vasorum is a metastrongyloid parasite that infects the pulmonary arteries and respiratory tract of wild and domestic canids. Foxes serve as a disease reservoir and gastropod intermediate hosts and vertebrate paratenic hosts transmit infection between canids. *A. vasorum* infection is currently considered enzootic in areas of Europe, South America, Africa, and North America, and has become more common in eastern coastal Canada over the past decade. The only reported cases of *A. vasorum* infection in the United States were in a greyhound imported from Ireland and in a dog abandoned in Long Island. Since there is concern that *A. vasorum* may have spread to the United States from Canada, this project aimed to initiate a survey of the northeastern United States for the presence of *A. vasorum*. The heart and lung tissues of 14 foxes from northeastern New Hampshire were examined, but no *A. vasorum* worms were recovered. As a model for *A. vasorum* infection in gastropods, snails were infected with first-stage larvae of *Aelurostrongylus abstrusus* or *Didelphostrongylus* sp, two metastrongyles that also use snails as intermediate hosts. Third-stage *A. abstrusus* larvae were recovered from one successfully infected snail after snail tissue digestion in a pepsin/HCl solution. This project established a working PCR detection methodology, snail infection and digestions protocols, and a library of metastrongyle DNA to be used in testing methods for *A. vasorum* detection.

Keywords: metastrongyles, canid lungworms, epidemiology, parasite detection

Acknowledgments

There are a number of people who have helped me a great deal with my work on this project. First, I would like to express my gratitude to Dr. Dwight Bowman for taking me into his lab and giving me the opportunity to work on a project so well-suited to my interests in veterinary medicine and wildlife. His guidance and support throughout the project, in addition to his wealth of parasitology knowledge and resources, have been greatly appreciated. I would also like to thank Jan Liotta for her help setting up protocols and using the equipment in the lab. I am particularly grateful to Dr. Araceli Lucio-Forster for her assistance obtaining fecal samples for larvae and for editing my thesis, as well as for her general help and support. Thanks also to Misty Pocwierz, who worked with me to set up protocols and accomplish the day-to-day work involved in the project. Finally, I would like to thank Patrick Tate, from the New Hampshire Fish and Game Department, who was instrumental in obtaining the fox carcasses that were tested for *Angiostrongylus vasorum*.

Table of Contents

Introduction.....4

Literature Review.....6

Materials and Methods.....19

Results.....22

Discussion.....24

Works Cited30

Appendix.....33

Introduction

The metastrongyloid parasite *Angiostrongylus vasorum* was first observed in the pulmonary arteries and right side of the heart of a domestic dog in France in 1853 and was characterized as a new species in 1866. This nematode primarily infects wild and domestic canids and uses gastropods as intermediate hosts (Rosen *et al.*, 1970). In the *A. vasorum* lifecycle, canids become infected by consuming intermediate or paratenic hosts that are infected with third-stage larvae (Rosen *et al.*, 1970) and intermediate hosts become infected by consuming first-stage larvae passed in the feces of infected canids (Mahaffey *et al.*, 1981). Canids with *A. vasorum* infection can present with a variety of symptoms, including, but not limited to, extensive hemorrhage and multifocal egg- or larvae-containing granulomas in the lungs (Prestwood *et al.*, 1981), as well as vomiting, depression, weakness, and neurological signs (Bourque *et al.*, 2008).

The global distribution of *A. vasorum* infection has been expanding in the past few decades. Once considered to be enzootic among dogs in France, Ireland, Switzerland, and Uganda, with sporadic cases reported in other parts of the world (Prestwood *et al.*, 1981), it is now considered enzootic in larger areas of Europe, as well as Brazil, Colombia, and Uganda (Bourque *et al.*, 2008). In North America, specifically, *A. vasorum* is well-established and becoming more prevalent in both domestic dogs and wild foxes in the Canadian province of Newfoundland (Conboy, 2004; Jeffery *et al.*, 2004). In the United States, only two cases of *A. vasorum* infection have been reported: one in a Greyhound imported from Ireland (Williams *et al.*, 1985) and the other in a dog abandoned in Long Island (Georgi and Georgi, 1992). Factors such as climate change, movement of mollusk intermediate hosts, and people traveling with their pets have been

speculated to be involved in the spread of this parasite (Traversa and Guglielmini, 2008; Morgan *et al.*, 2005). A concern is that *A. vasorum* may spread to the United States from Canada through imported canids or the movement of mollusks or wild canids from Newfoundland across the St. Lawrence River. The establishment of detection methods and the possible early detection of infection may allow the identification of an existing or new focus of infection, as well as containment and eradication if the parasite is present. Thus, there is currently a need to conduct a survey of the United States to determine whether *A. vasorum* has entered this country.

Such a survey, however, is limited by the ability of existing methods to definitively detect *A. vasorum* in both primary and intermediate hosts. Of the numerous diagnostic methods available, Polymerase Chain Reaction (PCR) for the amplification of the second internal transcribed spacer (ITS-2) sequence of ribosomal (r)DNA has been identified as an effective diagnostic tool for *A. vasorum* infection (Caldeira *et al.*, 2003; Denk *et al.*, 2009; Patterson-Kane *et al.*, 2009). However, the specificity of this PCR protocol is not well-documented.

The work of this project focused on detection of *A. vasorum* in both primary and intermediate hosts. First, primary host species were collected from areas to which *A. vasorum* infection may have spread and tested for *A. vasorum* infection. Second, a model of *A. vasorum* infection of gastropods was established and used to test methods for detecting *A. vasorum* infection in these animals. Finally, other nematodes known to inhabit the lungs of canids or whose lifecycles involve gastropod intermediate hosts were collected and used to compile a DNA library and to test a PCR protocol previously used in diagnosis of *A. vasorum* infection. Thus, the goals of this study were to conduct a

survey of the northeastern United States to determine whether *Angiostrongylus vasorum* is present in this country, to improve detection methods for *A. vasorum* infection in both primary and intermediate hosts, and to test the specificity of an existing PCR protocol for *A. vasorum* detection.

Literature Review

Lifecycle and Morphology of A. vasorum

Angiostrongylus vasorum is a metastrongyloid parasite that infects wild and domestic canids. The nematode was first observed in the pulmonary arteries and right side of the heart of a domestic dog in Toulouse, France in 1853 by Ferres, then described as a new species by Baillet in 1866 (Rosen *et al.*, 1970). Host species commonly infected include the red fox (*Vulpes vulpes*) (Rosen *et al.*, 1970; Morgan *et al.*, 2008), coyote (*Canis latrans*) (Bourque *et al.*, 2005), and domestic dog (*Canis lupus familiaris*) (Williams *et al.*, 1985; Perry *et al.*, 1991; Conboy, 2004; Chapman *et al.*, 2004; Bourque *et al.*, 2008; Denk *et al.*, 2009). In addition to these species, *A. vasorum* infection has occasionally been reported in the crab-eating fox (*Cerdocyon thous*), hoary fox (*Dusicyon vetulus*), wolf (*Canis lupus*), European badger (*Meles meles*), and domestic cat (*Felis catus*) (Jeffery *et al.*, 2004). Recently, a case of *A. vasorum* infection was diagnosed in a captive red panda (*Ailurus fulgens*) in the United Kingdom (Patterson-Kane *et al.*, 2009). In particular, foxes serve as an important infection reservoir (Morgan *et al.*, 2005).

The lifecycle of *A. vasorum* involves canids as primary hosts and infection reservoirs and these animals become infected by consuming infected aquatic or terrestrial mollusks, which serve as intermediate hosts (Rosen *et al.*, 1970). *A. vasorum* has been found to utilize numerous mollusk species as intermediate hosts (Grewal *et al.*, 2003;

Morgan *et al.*, 2005). Species identified so far include the terrestrial slug *Derocera laevae*, which is widespread in Canada and the United States, and the aquatic snail *Biomphalaria pfeifferi*, which has been experimentally infected in the laboratory (Prestwood *et al.*, 1981). *Biomphalaria glabrata*, another aquatic snail, has also been experimentally infected in the laboratory (Barcante *et al.*, 2003). In addition, the common frog (*Rana temporaria*) has been found to be capable of serving as both a paratenic and intermediate host for *A. vasorum* (Bolt *et al.*, 1993). Intermediate hosts become infected with first-stage larvae by eating feces passed by infected canines (Rosen *et al.*, 1970; Mahaffey *et al.*, 1981). In the mollusk, larvae develop to the third stage, which is the stage infective to canids. Canids that consume infected mollusks digest the mollusk tissue, releasing the third-stage larvae. These larvae enter the abdominal wall and molt in the abdominal visceral lymph nodes of the canid host, then migrate through the liver to the heart and pulmonary arteries, where they complete their development into adult worms, mate, and lay eggs (Rosen *et al.*, 1970). Eggs are carried from the pulmonary arteries to the arterioles, where the larvae develop and hatch as first-stage larvae. These larvae enter the alveoli and are subsequently coughed up, swallowed, and expelled in feces (Mahaffey *et al.*, 1981). The cycle continues with mollusk consumption of infected feces. First-stage larvae are typically 0.28-0.31 mm long with the excretory pore at or posterior to the nerve ring and a sharply pointed tail with a distinct notch on the dorsal surface. The adult male has a well-developed bursa and the adult female has a “barber-pole” appearance resulting from the entwining of the reproductive tract and intestine (Rosen *et al.*, 1970).

Clinical Presentation and Treatment

In infected canids, *A. vasorum* adult worms are typically found in the pulmonary arteries (Rosen *et al.*, 1970); in hosts at necropsy, the worms are often found in the right side of the heart, where they have migrated post-mortem when the blood flow into the lungs has ceased (Bowman, personal communication). Experimental infection produces rapid development of pulmonary disease, initial mild interstitial pneumonia followed by extensive hemorrhage, arterial thromboses, periarteritis, and multifocal, coalescing, egg- or larvae-containing granulomas in the lungs (Prestwood *et al.*, 1981). In these cases, radiographic findings include pulmonary congestion with peripheral emphysema, diffuse interstitial lung disease, bronchial thickening, right side of heart and lobar pulmonary artery enlargement, and increased pulmonary density (Mahaffey *et al.*, 1981). Naturally infected dogs commonly present with acute pulmonary embolism or hemorrhagic disorders, among other possible symptoms (Prestwood *et al.*, 1981). Another report indicates that infection is usually asymptomatic or associated with mild, intermittent clinical signs, but animals in later stages of infection may present with coughing, dyspnea, and exercise intolerance, although there is a great deal of variation. Anorexia, stunted growth, weight loss, weakness, depression, vomiting, collapse, lameness, subcutaneous swelling, bleeding disorders, hypercalcemia, disseminated intravascular coagulation, and neurological signs may also be present (Bourque *et al.*, 2008). In some cases, infected dogs have been found to have multifocal lesions and hemorrhage in the brain (Denk *et al.*, 2009). While no drugs have been officially approved for treating dogs with angiostrongylosis, three anthelmintics, fenbendazole, ivermectin, and milbemycin oxime, have been used as effective treatments (Bourque *et al.*, 2002; Conboy, 2004).

Global Distribution and Spread

In 1981, *Angiostrongylus vasorum* infection was considered to be enzootic among dogs in France, Ireland, Switzerland, and Uganda, with sporadic cases reported in Australia, Brazil, Colombia, Germany, Hungary, the former Soviet Union, and the United States (Prestwood *et al.*, 1981). In 2008, it was considered enzootic in larger areas of Europe, including regions of France, southwest England, Ireland, Denmark, Italy, Spain, Germany, Hungary, Finland, Switzerland and Turkey, as well as Brazil, Colombia, and Uganda (Bourque *et al.*, 2008). According to Traversa and Guglielmini (2008), while *A. vasorum* infection was traditionally thought to be prevalent only in well-isolated areas in North America, Southwestern France, the UK, and Denmark, it has spread within the last decade and has now been found in Sweden, Switzerland, Germany, Australia, Greece, and Italy. From these different reports, it is evident that *A. vasorum* infection is not well-defined geographically, but there is a clear trend of range expansion over the past several decades.

In Great Britain, attempts have been made to document the distribution and spread of *A. vasorum* infection. At an animal hospital in south-east England, 23 infected dogs were seen between 1999 and 2003, suggesting it is enzootic in this region (Chapman *et al.*, 2004). Another survey of 546 red foxes in Great Britain from January 2005 to April 2006 found the prevalence of *A. vasorum* to be between 5% and 10%. Furthermore, the distribution of positive animals covered a greater range than expected and suggested that spread into other parts of the country is likely (Morgan *et al.*, 2008).

In North America, *A. vasorum* infection has been established as endemic and is becoming more common in the eastern coastal regions of Canada. The first reported case

of *A. vasorum* infection in Canada was in a red fox in Newfoundland in 1973 (Smith and Threlfall). In 1991, a dog imported from the Cornwall area of England to Alberta, Canada was diagnosed with *A. vasorum* infection, having presented with ocular and nervous disease (Perry *et al.*, 1991). The first reported cases of endemic *A. vasorum* infection in domestic dogs in Canada, and North America, were two dogs from the eastern region of the Avalon Peninsula, in Newfoundland, who had no history of travel outside that region (Bourque *et al.*, 2002). In March 2003, a dead adult female coyote found in the Avalon Peninsula region was diagnosed with *A. vasorum* infection. This was thought to be the first report of *A. vasorum* infection in a coyote from the only endemic area of infection in North America (Bourque *et al.*, 2005).

In a survey of fecal samples from symptomatic dogs in the provinces of Prince Edward Island, Nova Scotia, New Brunswick and Newfoundland, submitted from October 2000 to October 2001, *A. vasorum* infection was diagnosed by the recovery of larvae from 16 of the 202 dogs tested. The only positive samples were among the 67 dogs tested from the Avalon Peninsula of Newfoundland. The 24% infection rate found in this study represented a marked increase from the 4% observed in an unpublished survey from 1997 to 1999, indicating the rapid spread of the parasite (Conboy, 2004). In particular, cases tended to occur in beagles, and it was speculated that this is due to the use of these dogs in hunting, during which they run off the leash and may contact infected slugs in areas inhabited by the natural definitive host, red fox (Conboy, 2004). Paratenic hosts such as frogs may also be involved in spreading infection in these situations, but their relative importance has not been determined (Bolt *et al.*, 1993). Another survey by Jeffery *et al.* (2004) sampled 366 red fox carcasses from six regions of

Newfoundland between 2000 and 2002 for infection with *Angiostrongylus vasorum*. This study found that *A. vasorum* occurred only in southeast Newfoundland, where its prevalence was 56%, and was absent from areas with temperatures below -4°C. Between 2001 and 2003, 7 out of 56 dogs examined from the St. Johns, Newfoundland area were found to be infected with *A. vasorum* (Bourque *et al.*, 2008). In addition to these surveys, canine angiostrongylosis has reportedly been increasingly diagnosed by veterinarians in Eastern Newfoundland since the early 1990s (Bourque *et al.*, 2008), which may be due to greater awareness of the parasite and its clinical presentation, an increase in infection rates, or a combination of these two factors. So far, only two cases of *A. vasorum* infection have been reported in the United States. One was at the Michigan State University in 1985, in a 1-year-old male Greyhound imported from Ireland (Williams *et al.*, 1985). The second case was not a definitive diagnosis, but a first-stage larva from the feces of a dog abandoned in Long Island was identified as likely being *A. vasorum*, as opposed to *Aelurostrongylus abstrusus* (a feline parasite) based on morphology and continual shedding of larvae after confinement (Georgi and Georgi, 1992). However, no survey has been conducted for *A. vasorum* infection in the United States and other cases may not have been reported.

Numerous factors are speculated to be involved in the spread of *A. vasorum* infection. Such factors include climate change, the spread of intermediate host mollusks, increased number and proximity of reservoir hosts, and increased travel of people with their pets. However, data on *A. vasorum* distribution remains fragmentary (Traversa and Guglielmini, 2008), making it difficult to draw strong conclusions about factors affecting the spread of infection. There is anecdotal evidence to support theories about climate

change and intermediate hosts, as outbreaks tend to occur in years that are more mild and wet, when gastropods would be abundant (Conboy, 2004), and, in the Iberian peninsula, *A. vasorum* was more abundant in the mild, damp coastal areas, as compared to the warmer, drier southern interior (Segovia *et al.*, 2004 as cited in Morgan *et al.*, 2005). Furthermore, Jeffery *et al.* (2004) found no infected foxes in areas with temperatures below -4°C . These observations suggest that *A. vasorum* tends to occur in milder climates and with increasing global temperatures, both primary and intermediate hosts may be increasing their ranges into areas that were previously too cold, which, in turn, could increase the range of *A. vasorum*. There is also potential for vacationers' infected dogs to bring *A. vasorum* into previously infection-free areas and establish the parasite in local mollusk and fox populations, and for high population density of foxes in areas where people live to result in transmission to domestic dogs (Morgan *et al.*, 2005). According to Morgan *et al.* (2008), climate change and denser populations of reservoir or intermediate hosts may be involved in the expansion, but such trends are not well-supported. These authors suggest that *A. vasorum* may have additional intermediate hosts, other than mollusks, that are helping it to spread into new areas. Cases of *A. vasorum* infection in previously unaffected areas are often in imported dogs (Perry *et al.*, 1991; Williams *et al.*, 1985; Denk *et al.*, 2009) or dogs that have recently visited areas known to be endemic for *A. vasorum* (Denk *et al.*, 2009), thus such cases may be significant in spreading *A. vasorum* into new regions.

Diagnostic Methods

There are a variety of methods available for identifying *A. vasorum* infection. The most commonly used and widely available methods involve examination of fecal

material. Larvae can be detected in feces using fecal flotation or the more effective Baermann technique, followed by morphological examination for the characteristic tail kink and dorsal spine of the first-stage larvae (Conboy, 2000; Bourque *et al.*, 2002). When using morphology, however, first stage *A. vasorum* larvae must be differentiated from *Crenosoma vulpis*, *Oslerus osleri* or *Filaroides* spp. (Conboy, 2004), among other species. Although the Baermann detection method is considered by some to be the best diagnostic method available, this test is not regularly performed by most veterinarians when doing routine testing of animal feces for the detection of parasitic stages, as it is only able to recover larvae and many, if not most, of the parasites of importance in veterinary medicine are present as eggs or oocysts in feces (Lucio-Forster, personal communication). When this test is requested and used for detection of larvae, it has the disadvantages of being time consuming, requiring experienced microscopists, and being unable to detect infections during the prepatent period or when larvae are not being shed in the feces. The latter is problematic due to the intermittent larval shedding characteristic of *A. vasorum* infection (Traversa and Guglielmini, 2008). Alternative diagnostic methods include bronchoalveolar lavage and tracheal swabs or washes, but these procedures are more risky and invasive and are not as reliable because of the possibilities of prepatent infection, an absence of significant pulmonary tissue involvement, and decreased larval shedding (Chapman *et al.*, 2004). Other methods of diagnosis involve detecting the effects of *A. vasorum* infection on lung and cardiac tissues. Radiographs and, more effectively, computerized axial tomography (CAT) scans, can be used to detect pulmonary lesions. Echocardiography is reliable for detecting pulmonary hypertension, but problems with pulmonary blood flow, although

they can be associated with *A. vasorum* infection, are nonspecific for this condition. Magnetic resonance imaging (MRI) can be used to detect brain and spinal cord hemorrhages that occur in infected dogs (Traversa and Guglielmini, 2008). The fecal and tissue imaging methods described above are not always reliable for diagnosing *A. vasorum* infection, as there is a significant degree of difficulty in specifically detecting this parasite in feces and in differentiating clinical presentation of infection from other cardio-respiratory diseases (Traversa and Guglielmini, 2008). For these reasons, scientists are working toward more sensitive and specific diagnostic methods.

Serological methods have been developed to detect either specific antibodies to *A. vasorum* or worm-produced antigens in the blood of infected animals. One study found a specific antibody response to *A. vasorum* in experimentally infected dogs (Cury *et al.*, 1996). Subsequently, an enzyme-linked immunosorbent assay (ELISA) and a Western Blot (WB) test using crude antigen extracts from adult female worms were used to identify *A. vasorum* infection based on the presence of *A. vasorum*-specific IgG (Cury *et al.*, 2002). Another study developed a sandwich-ELISA using rabbit anti-whole adult worm antiserum to detect circulating antigen of *A. vasorum* infection in the sera of dogs. This test was found to have 100% specificity and 92% sensitivity, as well as a greater rate of detection than fecal methods (Verzberger-Epshtein *et al.*, 2008). De Oliveira Vasconcelos *et al.* (2008) found on the WB test that a crude extract of adult *A. vasorum* worms contained antigens cross-reactive with other parasites, but four proteins from the adult worms were specifically recognized by IgG antibodies from dogs with *A. vasorum* infection. The sensitivity and specificity of these methods indicates their potential for future use in detection of *A. vasorum* infection.

Another line of development in the detection of *A. vasorum* infection is the use of PCR to specifically detect the presence of *A. vasorum* DNA in host tissues. The second internal transcribed spacer (ITS-2) sequence of ribosomal (r)DNA has been widely used to differentiate among species of strongylid nematodes since the interspecific differences in the sequence are greater than the intraspecific differences (Romstad *et al.*, 1998). Caldeira *et al.* (2003) used PCR amplification, combined with restriction fragment length polymorphism (RFLP), to differentiate between larval and adult worms of three *Angiostrongylus* species: *A. costaricensis*, *A. cantonensis*, and *A. vasorum*. This study amplified the ITS-2 sequence of rDNA using the primers NC1 and NC2, as well as the first cytochrome oxidase unit (COI) region of mitochondrial (mt) DNA using the primers LCO and HCO. Denk *et al.* (2009) used PCR followed by sequencing to specifically identify *A. vasorum* infection in lung tissue. This study also used the NC1 and NC2 primers to amplify the ITS-2 sequence of rDNA and, to confirm the results, amplified a 1000 bp fragment of the 28S rRNA gene using the primers NC28-1 and NC12R. Amplified fragments were then sequenced and compared to existing GenBank sequences for *A. vasorum*. Amplification and sequencing of the 18S rRNA gene and the ITS-2 sequence were used by Patterson-Kane *et al.* (2009) to definitively diagnose *A. vasorum* infection in lung tissue. Another study developed a method using PCR-direct sequencing of the small subunit (SSU) ribosomal RNA gene to identify *A. cantonensis*, and found sufficient differences between the sequence of *A. cantonensis* and other angiostrongylid worms to distinctively identify this species. This indicates that molecular methods can be effective in identifying nematodes with similar morphology (Fontanilla and Wade, 2008).

Overall, PCR, followed by sequencing, may be the most definitive method for diagnosing *A. vasorum* infection.

Similarities to Other Worms

In addition to *A. vasorum*, there are numerous other worms that can be found in the respiratory and vascular systems of canids. These include the nematodes *Filaroides (Oslerus) osleri*, *Crenosoma vulpis*, and *Eucoleus (Capillaria) aerophilus*, which are found in the trachea and bronchi; the nematodes *F. hirthei*, *F. milksi*, *Dirofilaria immitis*, and larvae of *D. immitis*, which can be found in the lung parenchyma; the adult nematode *D. immitis*, which inhabits the pulmonary artery, right side of the heart, and venae cavae (Bowman, 2009). These worms are important to recognize, as they can cause some of the same symptoms as *A. vasorum* and may be detected in tests involving lung tissue.

There are also many nematodes that, like *A. vasorum*, use gastropods as intermediate hosts (Bowman, 2009). One study of terrestrial gastropods collected in Central Maine recovered *Parelaphostrongylus tenuis*, *Cosmocercoides dukae*, *Rhabditis* sp., and *Crionema* sp. (Gleich *et al.*, 1977). While *P. tenuis* is a metastrongyloid parasite that infects deer, the latter three parasites listed above are parasites of snails (Bowman, personal communication). *P. tenuis* has also been found in gastropods from Virginia (Rowley *et al.*, 1987) and Pennsylvania (Maze and Johnstone, 1986). *Aelurostrongylus abstrusus* is commonly found to infect cats and uses gastropods as intermediate hosts (Lopez *et al.*, 2005). *Parelaphostrongylus odocoilei* has been found in gastropods from Jasper National Park, Alberta (Samuel *et al.*, 1985). In testing for *A. vasorum* infection in mollusks obtained from areas in which *A. vasorum* may be present, it is important to be

aware of other parasites that may be present in these animals and to use a test that will specifically detect *A. vasorum*.

Several species of *Angiostrongylus* have been reported in the United States. *A. blarini* and *A. michiganensis* were discovered in the United States in the short tailed shrew (*Blarini brevicauda*) and the common shrew (*Sorex cinereus cinereus*), respectively, but were later reassigned to the genus *Stefanskostongylus* (Campbell and Little, 1988). *A. gubernaculatus* has been found in the badger (*Taxidea taxus neglecta*) and skunk (*Mephitis mephitis holzneri*) in California, *A. schmidtii* was found in the pulmonary arteries of the rice rat (*Oryzomys palustris*) in the Gulf Coast region of Florida, and *A. costaricensis* has been found in humans in Central and South America, as well as in the cotton rat (*Sigmodon hispidus*) in Texas (Campbell and Little, 1988). In 2006, *A. costaricensis* was reported in Miami, Florida in two species of non-human primates in captivity, as well as in raccoons and an opossum from the wild. Since the raccoons and opossum were native, these findings indicated that *A. costaricensis* is now endemic in this area (Miller *et al.*, 2006). *A. cantonensis* is speculated to have been transmitted to the United States from China via rats on ships and the first case of *A. cantonensis* infection in the U.S. was found in rats in New Orleans in 1988. Like *A. vasorum*, *A. cantonensis* uses gastropods as intermediate hosts (Campbell and Little, 1988).

Finally, there are metastrongyle nematodes with lifecycles similar to *A. vasorum* that are currently distributed throughout North America. *P. tenuis*, which infects white-tailed deer (*Odocoileus virginianus*) and uses gastropod intermediate hosts, is found in Canada and the eastern United States and infection is spread by the movement of infected

deer (Rawley *et al.*, 1987). *Crenosoma vulpis* infects wild and domestic canids, particularly foxes, and is found in both Canada and the eastern United States, specifically New York (Conboy and Adams, 1995). The similar lifecycles of these two worms to *A. vasorum* and the current geographic distributions of infection across North America suggest that *A. vasorum* infection may occur in animals in the United States, in addition to Canada.

Concerns for Human Health

The possible spread of *A. vasorum* into the United States, while not itself a direct threat to humans, may indicate that zoonotic diseases carried by dogs may be brought into and become established in the United States. *Echinococcus multilocularis*, an intestinal cestode, is the causative agent of Human alveolar echinococcosis, which behaves like a malignant tumor and can cause up to 100% mortality in untreated infected humans. The infection is typically spread through wildlife, including foxes and other wild canids, and the geographic distribution of infection is confined to regions of the northern hemisphere, but it has been reported recently that the range of *E. multilocularis* is expanding, mostly due to the movement of infected foxes (Deplazes and Eckert, 2001). Canine leishmaniasis is another zoonotic disease that can be transmitted from dogs to humans, particularly since dogs serve as the primary infection reservoir for the parasite. Infection with the *Leishmania infantum* parasite causes visceral leishmaniasis in humans (Alvar *et al.*, 2004). There is also concern about *Cochliomyia hominivorax*, commonly called the New World Screw Fly, which is found in the Western Hemisphere and infects flesh wounds in humans and other mammals. Although this fly was eradicated from the United States in 1966, it is still occasionally brought into the country by people and pets

traveling from South America (Alexander, 2006). These diseases pose a significant threat to human health and could be carried by dogs and foxes that enter the United States from other areas. Thus, the movement of dogs from other parts of the world, as may be indicated by the spread of *Angiostrongylus vasorum*, can pose a threat to human health.

Overall, the spread of *A. vasorum* into the United States is a distinct possibility. Studies have shown that *A. vasorum* infection is currently spreading in areas around the world and the proximity of Newfoundland, the endemic focus of *A. vasorum* infection in North America, to the United States raises concern that infection will enter the United States by crossing the St. Lawrence River. The route of spread may be through dogs brought into the United States from other countries, through snails carried on ships, or through another host, since *A. vasorum* is able to infect a variety of species. It is important to monitor potential host populations for this parasite, not only to document the spread of the parasite and attempt to curb the spread of *A. vasorum*, but also to protect against the transmission of other harmful diseases.

Materials and Methods

Detection in Primary Hosts

Fox and coyote carcasses were requested from trappers in New York, New Hampshire, and Maine. Fourteen whole, skinned fox carcasses, including red fox (*Vulpes vulpes*) and grey fox (*Urocyon cinereargenteus*), were collected by trappers during October 2008 from northeast New Hampshire, specifically the Wildlife Management Units B1, C1, and C2 as defined by the New Hampshire Fish and Game Department (see map in Appendix 1). Carcasses were stored in a standard freezer for up to three months, until they were all collected and could be transported to the Cornell University College of

Veterinary Medicine. Then they were thawed in a cold room for several days and, once thawed, the hearts and lungs were removed from the body for dissection. Heart and lung sets were stored overnight in 800mL 0.5% NaCl solution to ensure they were fully defrosted and in an attempt to rehydrate the organs and any parasites present therein. The following day, the pulmonary arteries were dissected according to the procedure outlined by Morgan *et al.* (2008) to look for adult *A. vasorum* worms. Using a dissecting microscope, recovered worms were identified by morphology (Bowman, 2009) and stored in water at -80°C.

Detection in Intermediate Hosts

A colony of land snails (*Rabdotus alternatus*, Carolina Scientific Supply) was established using a husbandry protocol modified from Gray *et al.* (1985). This species of snail was chosen because it was convenient to obtain and the particular species was not significant, as nematodes have been found to be relatively non-specific in their choice of molluscan intermediate host (Grewal *et al.*, 2003). Snails were kept in 1m² plastic aquariums with vermiculite/peat moss substrate and fed lettuce, cabbage, potato, and turnip. Snails were housed in an environmental chamber at 23±2°C with a 12-hour photoperiod. High humidity was maintained by keeping containers of water in the environmental chamber with a circulation fan constantly running. Seven snails were infected with *Aelurostrongylus abstrusus* first-stage larvae isolated from feces of naturally infected cats from the Tompkins County Society for the Prevention of Cruelty to Animals (SPCA) in Ithaca, NY. Three other snails were infected with first-stage larvae of an unidentified species of *Didelphostrongylus* obtained from the feces of an opossum treated at the Cornell University College of Veterinary Medicine Wildlife

Health Center. In both cases, larvae were recovered from feces using the Baermann method. In the infection protocol, snails were fasted for 2-4 days and then individually placed in vials with larvae on a piece of potato or turnip and with no other food available. After one week in these infection vials, snails were marked as potentially infected and returned to the aquariums. After allowing the larvae to develop in the snails for one to two months, snails were removed from their shells, finely minced, and digested in a 0.6% pepsin/0.7% HCl digestion solution at 37°C (Samuel *et al.*, 1985) for about 24 hours with constant shaking. The digest was examined using a dissecting microscope to recover developed third-stage larvae, which were identified by morphology (Bowman, 2009) and frozen in water at -80°C.

Collection of Worms for Nematode DNA Library

Adult *Trogostrongylus subcrenatus* worms were obtained from bronchial arterioles and bronchioles of frozen and subsequently thawed bobcat heart and lung tissues from animals trapped in New York State. Adult *Crenosoma vulpis* worms were recovered from pulmonary arterioles and bronchioles of foxes trapped in New Hampshire during October 2008, as described above. Adult *Dictyocaulus viviparus* worms were obtained from the lung tissue of a cow necropsied at the Cornell University College of Veterinary Medicine. In addition, *Muellerius capillaris* larvae were obtained, using the Baermann method, from the feces of a naturally infected goat whose fecal samples were brought to the Cornell University College of Veterinary Medicine for examination. Digestion of a snail infected with *Aelurostrongylus abstrusus*, according to the procedure outlined above, yielded third-stage larvae of this worm. All recovered worms were stored in water at -80°C. Once the worms were collected, they were ground using

Thomas tissue grinders and DNA was extracted using a QIAamp DNA Mini Kit (Qiagen, Inc., Valencia, CA).

PCR Methodology

The PCR protocol aimed to amplify a fragment of the ITS-2 sequence of rDNA for strongylid nematodes using the primers NC1 (5'- ACG TCT GGT TCA GGG TTG TT-3') and NC2 (5'- TTA GTT TCT TTT CCT CCG CT- 3') (Conole *et al.*, 1999). The protocol used was adapted from Denk *et al.* (2009). Fifty or fifty-two μL of reaction mixture included 5 or 7 μL template DNA solution, respectively, 10 pmol of each primer, 0.4 mM dNTPs, and 2.5 U HotMaster Taq DNA polymerase in 1x PCR HotMaster buffer (5Prime, Inc., Gaithersburg, MD). Amplification was conducted using a thermocycler with the following program: an initial denaturation at 94°C for 2 min, then 40 cycles of 94°C for 1 min, 58°C for 1 min, and 72°C for 1 min, with a final elongation at 72°C for 5 min (Denk *et al.*, 2009). Five μL aliquots of each PCR product were run out by gel electrophoresis stained with ethidium bromide. The expected PCR product for *A. vasorum* using this protocol is a DNA band 600 bp in size (Caldeira *et al.*, 2003; Denk *et al.*, 2009; Patterson-Kane *et al.*, 2009).

Results

Detection in Primary Hosts

In dissecting into the heart and lung tissues of the 14 red and grey foxes collected from New Hampshire, no *A. vasorum* worms were recovered. However, dissection into the bronchioles of one fox's lungs yielded *Crenosoma vulpis* worms (Table I).

Table I. Data obtained from foxes examined for *A. vasorum*.

State collected	Species	Date Collected	Region Collected	Sex	Date Examined	<i>Angiostrongylus vasorum</i>	Other infection?
NH	Fox	10/24/2008	WMU C1/C2	M	1/30/2009	(-)	(-)
NH	Fox	10/29/2008	WMU B1	M	1/30/2009	(-)	(-)
NH	Fox	Unknown	Unknown	M	1/30/2009	(-)	(-)
NH	Fox	10/19/2008	WMU C1/C2	M	1/30/2009	(-)	(-)
NH	Fox	10/25/2008	WMU C1/C2	M	1/30/2009	(-)	(-)
NH	Fox	10/18/2008	WMU C1/C2	F	1/30/2009	(-)	(+) <i>Crenosoma vulpis</i>
NH	Fox	10/20/2008	WMU C1/C2	F	1/30/2009	(-)	(-)
NH	Fox	10/19/2008	WMU C1/C2	M	1/30/2009	(-)	(-)
NH	Fox	10/29/2008	WMU B1	M	1/30/2009	(-)	(-)
NH	Fox	10/30/2008	WMU C2	M	1/30/2009	(-)	(-)
NH	Fox	10/18/2008	WMU C1/C2	M	1/30/2009	(-)	(-)
NH	Fox	10/2008	WMU C1/C2	F	1/30/2009	(-)	(-)
NH	Fox	10/19/2008	WMU C1/C2	M	1/30/2009	(-)	(-)
NH	Fox	6/24/2008	WMU C1/C2	M	1/30/2009	(-)	(-)

Foxes included red fox (*Vulpes vulpes*) and grey fox (*Urocyon cinereargenteus*) collected from New Hampshire (NH). (-) indicates no worms were detected, while (+) indicates worms were detected. No *A. vasorum* were recovered through dissection of the pulmonary arteries, although dissection of the bronchioles in one fox yielded *Crenosoma vulpis*.

Detection in Intermediate Hosts

Seven snails were exposed to *Aelurostrongylus abstrusus* and one was successfully infected, as demonstrated by the recovery of third-stage larvae of this parasite after snail tissue digestion. Three snails were exposed to the *Didelphostrongylus* sp. larvae, but no larvae were recovered from these snails following tissue digestion (Table II).

Table II. Snail infection and digestion data

LARVAL SOURCE	LARVAL TYPE	INFECTION DATE(S)	# SNAILS INFECTED	DIGESTION DATE(S)	# SNAILS DIGESTED	OUTCOME
Cat from SPCA (CPS Case #193994)	<i>Aelurostrongylus abstrusus</i>	11/19/2008	1	1/21/2009	1	11 third-stage larvae recovered
Opossum from Wildlife Health Center	<i>Didelphostrongylus</i> sp.	12/22/2008	3	2/6/2009; 3/4/2009	3	No larvae recovered
Cat from SPCA (Sample #4998C)	<i>Aelurostrongylus abstrusus</i>	2/5/2009; 2/6/2009	6	3/16/2009	4	No larvae recovered

First-stage larvae for infection of *Rabdotus alternatus* snails were obtained from the feces of the source animal using the Baermann method. Dates indicate when infection or digestion of the snails was initiated. Potentially infected snails that died before the period of larval development had passed were not digested.

PCR Methodology

The results of the PCR amplification of the rDNA of the various nematodes obtained for compiling a lungworm DNA library are displayed in Figure 1. The two lanes corresponding to the *Dictyocaulus viviparus* sample (lanes 7 and 8) show bands of approximately 600 bp and the two lanes corresponding to the *Crenosoma vulpis* sample (lanes 9 and 10) show bands of about 550 bp. None of the other lanes show any bands that indicate the presence of amplified DNA.

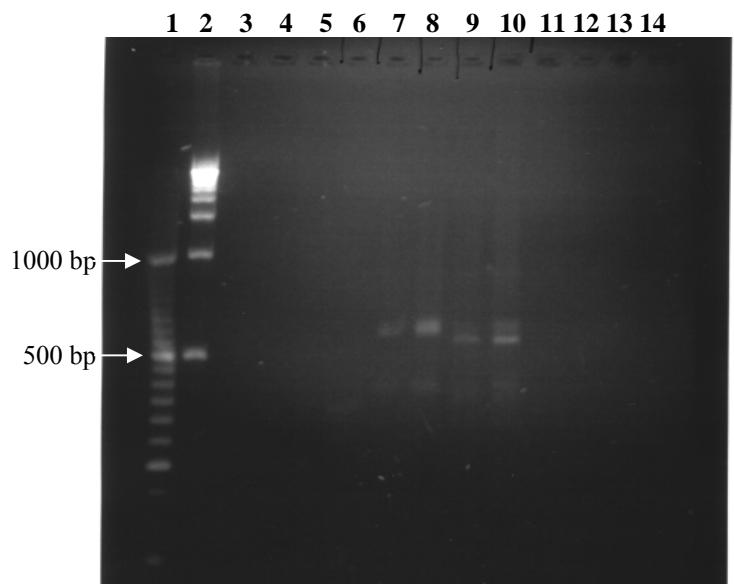


Fig. 1. Gel electrophoresis separation of products of PCR amplification of the ITS-2 sequence of rDNA in several nematodes. Lane 1 contains a 50 bp ladder; lane 2 contains a 500 bp ladder; lane 3 contains the negative control; lanes 4 and 6 correspond to *Muellerius capillaris* with 7 and 5 μ L of DNA, respectively; lanes 7 and 8 correspond to *Dictyocaulus viviparus* with 7 and 5 μ L of DNA, respectively; lanes 9 and 10 correspond to *Crenosoma vulpis* with 7 and 5 μ L of DNA, respectively; lanes 11 and 12 correspond to *Aelurostrongylus abstrusus* with 7 and 5 μ L of DNA, respectively; lanes 13 and 14 correspond to *Trogostrongylus subcrenatus* with 7 and 5 μ L of DNA, respectively. Lane 5 is empty due to a mistake in loading the gel.

Discussion

The results achieved in this project represent the early stages of the survey for *A. vasorum* infection in the United States. In testing primary hosts of *A. vasorum* for infection, no *A. vasorum* worms were recovered. Given the small geographic area from which the tested foxes were collected, it is likely that the lack of detection indicates a

lack of *A. vasorum* infection in this discrete area. However, the small sample size of 14 foxes and the small area from which animals were trapped makes this finding inconclusive in regard to wild canids in the northeastern United States. Surveys of wild canids in Canada for *A. vasorum* infection were conducted with between 56 (Bourque *et al.*, 2008) and 366 animals (Jeffery *et al.* 2004), which represent a much larger proportion of the population of interest. It is also notable that since the fox tissues had been frozen, it was more difficult to dissect into the arterioles of the lungs, and therefore more difficult to recover any *A. vasorum* worms present in these vessels, than would have been the case with fresh tissues. However, freezing was the best way to preserve the carcasses between collection and dissection and during transport from New Hampshire to Cornell University. A significant advantage of using PCR to detect *A. vasorum* in lung tissue would be that it would avoid this problematic dissection step, assuming that freezing would not degrade the DNA of the worm. In a high-quality freezer, DNA would be preserved, but storage in a standard freezer, such as the one used to store the fox carcasses during collection, may cause damage to DNA. Overall, using PCR to test fresh tissue, if logistically possible, would yield the most definitive results.

The snail infection protocol was shown to be effective by the one snail from which third-stage *A. abstrusus* larvae were recovered. The recovery of these larvae indicates that the first-stage larvae successfully penetrated or were consumed by the snail, then developed inside the snail during the time between infection and digestion. The success rate of infection in this experiment, one out of ten snails, is actually not surprising given past studies of gastropod infection with *A. abstrusus*. Lopez *et al.* (2005) infected *Cerutuella virgata*, a terrestrial snail, with *A. abstrusus* first-stage larvae

collected from the feces of naturally infected cats using the Baermann method and found that 65.5% of the first-stage larvae to which the snail was exposed penetrated into the snail foot, but only 4.78% of infecting larvae completed development to the infective third stage. While numbers of infecting larvae were not documented in the current study, these statistics indicate that infection of gastropods is not a guaranteed outcome of exposure to infective larvae. The failure to recover third-stage larvae from potentially infected snails in this study may be explained by a failure of larvae to infect the snails, the death of larvae inside the snails, or a problem with the digestion protocol. The last reason is less likely because larvae were successfully recovered from the first snail infected and the same digestion process was used for all snails. Finally, for the *Didelphostrongylus*, specifically, it is possible that infection was unsuccessful because *Rabdotus alternatus* snails are not suitable intermediate hosts for this nematode.

The presence of bands of amplified DNA on the gel (Fig. 1) suggests that the protocol used successfully amplified the ITS-2 rDNA sequence of *Dictyocaulus viviparus* and *Crenosoma vulpis*. These results are confirmed by the presence of bands at the same location in both lanes corresponding to each worm. The absence of bands in the other lanes indicates a lack of amplified rDNA from the other worms, which is contrary to the expected result. Since the ITS-2 of rDNA is present in all eukaryotes, but differs in size and sequence across species, all the nematodes from which DNA was extracted should have had a fragment of rDNA amplified by this protocol (Chilton, 2004). There are a few possible reasons for the lack of amplified rDNA in some of the lanes. First, the primers may have failed to anneal to the rDNA sequence of interest or the reactants may have failed to carry out the amplification, possibly due to the presence of PCR inhibitors in the

sample. However, these reasons are less likely because all amplifications were conducted with the same reactants and some were successful. A more likely explanation is insufficient quantity and/or quality of DNA in the cases in which amplification failed. DNA was extracted from adult worms of *C. vulpis* and *T. subcrenatus*, but from larvae of *M. capillaris* and *A. abstrusus*. Extraction from larvae would yield a smaller, and possibly insufficient, amount of DNA due to the smaller number of cells in larvae. In the case of *T. subcrenatus*, DNA was extracted from adult worms, but the DNA in the worms may have been degraded during the long-term storage of unknown duration of the bobcat tissues in a standard freezer. While the fox tissues from which the *C. vulpis* were obtained had also been frozen, the collection date was known and they were not frozen for more than four months. The quality of the DNA could have been tested by amplifying a housekeeping gene such as β -actin as a positive control. It is also notable that the lanes containing less DNA had brighter bands, which is contradictory to the expected result of more amplification product in reactions with a larger amount of DNA. This further brings into question the validity of these results. Another problematic aspect of this data is that the amplified fragment from *D. viviparus* appears to be approximately 600 bp long, but the length of the ITS-2 sequence in this species has been reported as 457 bp (Chilton, 2004). This discrepancy could be further investigated through sequencing of this PCR product and comparing it to known GenBank sequences for *D. viviparus*.

Directions for Further Research

Further work is necessary to fully achieve the aims set forth for this project and to definitively conclude whether *A. vasorum* has spread to the United States. First, the PCR protocol investigated needs to be further tested for its specificity for *A. vasorum* by:

obtaining *A. vasorum* DNA and snails known to be infected with *A. vasorum* and testing the protocol with these positive controls, continuing to test possibly cross-reactive nematodes, and sequencing amplified fragments of DNA and comparing them to known GenBank sequences. In addition, a larger number of wild canids should be collected from a wider geographical area than was covered in this study, including Maine, New York, and other areas of New Hampshire, and tested for *A. vasorum* infection through examination of heart and lung tissues and use of PCR. Domestic canids should also be tested for *A. vasorum* infection through analysis of fecal samples using the Baermann method and/or through dissection of heart and lung tissues from deceased dogs, followed by analysis of tissues using PCR. A significant sample size of domestic canids should be tested from a wide geographical area, including Maine, New York, and New Hampshire. Another area of further research should be to collect mollusks from Maine, New York, and New Hampshire and analyze them using PCR to determine if they are infected with *A. vasorum*. It is important to continue work on this study, as its conclusions have significant implications for the health of both canids and humans in the United States.

Overall, this project has been successful in initiating testing of primary host species and in establishing the methodologies for future work surveying the northeast region of the United States for the presence of *A. vasorum*. Sources of carcasses have been identified for future testing of primary hosts and a protocol has been developed for digesting nematodes out of gastropod intermediate hosts that will be useful in testing gastropods collected from the field for *A. vasorum* infection. Finally, this project has established and begun to test a PCR protocol that can be used to definitively determine if

host tissues are infected with *A. vasorum* and, ultimately, whether *A. vasorum* is present in the United States.

Works Cited

- Alexander, J.L., 2006. Screwworms. *J. Am. Vet. Med. Assoc.* 228(3), 357-367.
- Alvar, J., Canavate, C., Molina, R., Moreno, J., Nieto, J., 2004. Canine Leishmaniasis. *Adv. in Parasit.* 57, 1-88.
- Barcante, T.A., Barcante, J.M., Dias, S.R.C., Lima, W., 2003. *Angiostrongylus vasorum* (Baillet, 1866) Kamensky, 1905: emergence of third-stage larvae from infected *Biomphalaria glabrata* snails. *Parasitol. Res.* 91, 471-475.
- Bolt, G., Monrad, J., Frandsen, F., Henriksen, P., Dietz, H.H., 1993. The common frog (*Rana temporaria*) as a potential paratenic and intermediate host for *Angiostrongylus vasorum*. *Parasitol. Res.* 79, 428-430
- Bourque, A., Conboy, G., Miller, L., Whitney, H., Ralhan, S., 2002. *Angiostrongylus vasorum* infection in 2 dogs from Newfoundland. *Can. Vet. J.* 43, 876-879.
- Bourque, A., Whitney, H., Conboy, G., 2005. *Angiostrongylus vasorum* infection in a coyote (*Canis latrans*) from Newfoundland and Labrador, Canada. *J. Wildlife Diseases* 41(4), 816-819.
- Bourque, A.C., Conboy, G., Miller, L.M., Whitney, H., 2008. Pathological findings in dogs naturally infected with *Angiostrongylus vasorum* in Newfoundland and Labrador, Canada. *J. Vet. Diagn. Invest.* 20, 11-20.
- Bowman, D.D., 2009. *Georgi's Parasitology for Veterinarians*, 9th edition. Saunders, St. Louis, pp. 185-191, 323-324.
- Caldeira, R.L., Carvalho, O.S., Mendonça, C., Graeff-Teixeira, C., Silva, M.C.F., Renata, B., Maurer, R., Lima, W.S., Lenzi, H.L., 2003. Molecular differentiation of *Angiostrongylus costaricensis*, *A. cantonensis*, and *A. vasorum* by polymerase chain reaction- restriction fragment length polymorphism. *Mem. Inst. Oswaldo Cruz* 98(8), 1039-1043.
- Campbell, B.G., Little, M.D., 1988. The finding of *Angiostrongylus cantonensis* in rats in New Orleans. *Am. J. Trop. Med. Hyg.* 38(3), 568-570.
- Chapman, P.S., Boag, A.K., Guittian, J., Boswood, A., 2004. *Angiostrongylus vasorum* infection in 23 dogs (1999-2003). *J. Am. Anim. Prac.* 45, 435-440.
- Chilton, N.B., 2004. The use of nuclear ribosomal DNA markers for the identification of bursate nematodes (order Strongylida) and for the diagnosis of infections. *Anim. Health. Res. Rev.* 5(2), 173-187.
- Conboy, G.A., Adams, C., 1995. Treatment of *Crenosoma vulpis* infection in two silver foxes (*Vulpes vulpes*) with ivermectin. *J. Zoo and Wildlife Med.* 26, 597-600.
- Conboy, G.A., 2000. Canine angiostrongylosis (French Heartworm). In: *Companion and Exotic Animal Parasitology*, Bowman, D.D. (Ed.), International Veterinary Information Service (www.ivis.org).
- Conboy, G.A., 2004. *Angiostrongylus vasorum* in dogs in Atlantic Canada and their treatment with milbemycin oxime. *Vet. Rec.* 155, 16-18.
- Conole, J.C., Chilton, N.B., Jarvis, T., Gasser, R.B., 1999. Intraspecific and interspecific variation in the second internal transcribed spacer (ITS-2) sequence for *Metastrongylus* (Nematoda: Metastrongyloidea) detected by high resolution PCR-RFLP. *Int. J. Parasit.* 29, 1935-1940.
- Cury, M.C., Lima, S.K., Vitor, R.W.A., 1996. Enzyme-linked immunosorbent assay (ELISA) for the diagnosis of *Angiostrongylus vasorum* (Baillet 1866) infection in dogs. *Rev. Med. Vet.* 147, 525-530.

- Cury, M.C., Guimaraes, M.P., Lima, W.S., Vitor, R.W.A., 2002. Western blot analysis of the humoral response of dogs experimentally infected with *Angiostrongylus vasorum* (Baillet 1866). *Vet. Parasitol.* 106, 83-87.
- De Oliveira Vasconcelos, V., De Almeida Vitor, R.W., Dos Santos Lima, W., 2008. Identification of stage-specific proteins of *Angiostrongylus vasorum* (Baillet 1866). *Kamensky. Parasitol. Res.* 102, 389-395.
- Denk, D., Matiasek, K., Just, F.T., Hermanns, W., Baiker, K., Herbach, N., Steinberg, T., Fischer, A., 2009. Disseminated angiostrongylosis with fatal cerebral haemorrhages in two dogs in Germany: A clinical case study. *Vet. Parasit.* 160, 100-108.
- Deplazes, P., Eckert, J., 2001. Veterinary aspects of alveolar echinococcosis—a zoonosis of public health significance. *Vet. Parasit.* 198, 65–87.
- Fontanilla, I.K.C., Wade, C.M., 2008. The small subunit (SSU) ribosomal (r) RNA gene as a genetic marker for identifying infective 3rd juvenile stage *Angiostrongylus cantonensis*. *Acta Tropica* 105, 181-186.
- Georgi, J.R., Georgi, M.E., 1992. *Canine Clinical Parasitology*. Lea & Febiger, Philadelphia, USA, pp. 186-188.
- Gleich, J.G., Gilbert, F.F., Kutscha, N.P., 1977. Nematodes in terrestrial gastropods from central Maine. *J. Wildlife Dis.* 13, 43-46.
- Gray, J.B., Kralka, R.A., Samuel, W.M., 1985. Rearing of eight species of terrestrial gastropods (order Sylommatophora) under laboratory conditions. *Can. J. Zoo.* 63, 2474-2476.
- Grewal, P.S., Grewal, S.K., Tan, L., Adams, B.J., 2003. Parasitism of mulloscs by nematodes: Types of associations and evolutionary trends. *J. Nematology* 35(2), 146-156.
- Jeffery, R.A., Lankester, M.W., McGrath, M.J., Whitney, H.G., 2004. *Angiostrongylus vasorum* and *Crenosoma vulpis* in red foxes (*Vulpes vulpes*) in Newfoundland, Canada. *Can. J. Zool.* 82, 66-74.
- Lopez, C., Panadero, R., Paz, A., Sanchez-Andrade, R., Diaz, P., Diez-Banos, P., Morrondo, P., 2005. Larval development of *Aelurostrongylus abstrusus* (Nematoda, Angiostrongylidae) in experimentally infected *Cerनुella* (*Cerनुella*) *virgata* (Mollusca, Helicidae). *Parasitol. Res.* 95, 13-16.
- Mahaffey, M.B., Lesonsky, J.M., Prestwood, A.K., Mahaffey, E.A., Lewis, R.E., 1981. Experimental Canine Angiostrongylosis: II. Radiographic manifestations. *J. Am. Anim. Hosp. Assoc.* 17, 499-502.
- Maze, R.J., Johnstone, C., 1986. Gastropod intermediate hosts of the meningeal worm *Parelaphostrongylus tenuis* in Pennsylvania: observations on their ecology. *Can. J. Zool.* 64, 185-188.
- Miller, C.L., Kinsella, J.M., Garner, M.M., Evans, S., Gullett, P.A., Schmidt, R.E., 2006. Endemic infections of *Parastrongylus* (= *Angiostrongylus*) *costaricensis* in two species of nonhuman primates, raccoons and an opossum from Miami, Florida. *J. Parasit.* 92(2), 406-408.
- Morgan, E.R., Shaw, S.E., Brennan, S.F., De Waal, T.D., Jones, B.R., Mulcahy, G., 2005. *Angiostrongylus vasorum*: a real heartbreaker. *Trends in Parasit.* 21(2), 49-51.

- Morgan, E.R., Tomlinson, A., Hunter, S., Nicholas, T., Roberts, E., Fox, M.T., Taylor, M.A., 2008. *Angiostrongylus vasorum* and *Eucoleus aerophilus* in foxes (*Vulpes vulpes*) in Great Britain. *Vet. Parasit.* 154, 48-57.
- Patterson-Kane, J.C., Gibbons, L.M., Jefferies, R., Morgan, E.R., Wenzlow, N., Redrobe, S.P., 2009. Pneumonia from *Angiostrongylus vasorum* infection in a red panda (*Ailurus fulgens fulgens*). *J. Vet. Diagn. Invest.* 21, 270-273.
- Perry, A.W., Hertling, R., Kennedy, M.J., 1991. Angiostrongylosis with disseminated larval infection associated with signs of ocular and nervous disease in an imported dog. *Can. Vet. J.* 32, 430-431.
- Prestwood, A.K., Greene, C.E., Mahaffey, E.A., Burgess, D.E., 1981. Experimental canine angiostrongylosis: I. Pathologic manifestations. *J. Am. Anim. Hosp. Assoc.* 17, 491-497.
- Rawley, M.A., Loker, E.S., Pagels, J.F., Montali, R.J., 1987. Terrestrial gastropod hosts of *Parelaphostrongylus tenuis* at the National Zoological Park's Conservation and Research Center, Virginia. *J. Parasit.* 73(6), 1084-1089.
- Romstad, A., Gasser, R.B., Nansen, P., Polderman, A.M., Chilton, N.B., 1998. *Necator americanus* (Nematoda: Ancylostomatidae) from Africa and Malaysia have different ITS2 rDNA sequences. *Int. J. Parasit.* 28, 611-615.
- Rosen, L., Ash, L.R., Wallace G.D., 1970. Life history of the canine lungworm *Angiostrongylus vasorum* (Baillet), *Am. J. Vet. Res.* 31, 131-143.
- Samuel, W.M., Platt, T.R., Knispel-Krause, S.M., 1985. Gastropod intermediate hosts and transmissions of *Parelaphostrongylus odocoilei*, a muscle-inhabiting nematode of mule deer, *Odocoileus h. hemionus*, in Jasper National Park, Alberta. *Can. J. Zool.* 63, 928-932.
- Smith, F.R., Threlfall, W., 1973. Helminths of some mammals from Newfoundland. *Am. Midl. Nat.* 90, 215-218.
- Traversa, D., Guglielmini, C., 2008. Feline aelurostrongylosis and canine angiostrongylosis: A challenging diagnosis for two emerging verminous pneumonia infections. *Vet. Parasit.* 157, 163-174.
- Verzberger-Epshtein, I., Markham, R.J.F., Sheppard, J.A., Stryhn, H., Whitney, H., Conboy, G.A., 2008. Serologic detection of *Angiostrongylus vasorum* infection in dogs. *Vet. Parasit.* 151, 53-60.
- Williams, J.F., Lindemann, B., Padgett, G.A., Smith, O.L., 1985. Angiostrongylosis in a Greyhound. *JAVMA* 186(10), 1101-1103.

Appendix 1: Map of New Hampshire Wildlife Management Units
Available online at http://www.wildlife.state.nh.us/Hunting/WMU_maps/wmu_8x11.pdf

NH Fish & Game Department DEER AND TURKEY MANAGEMENT UNITS

