


Vet Med
Vol. 5, 1986

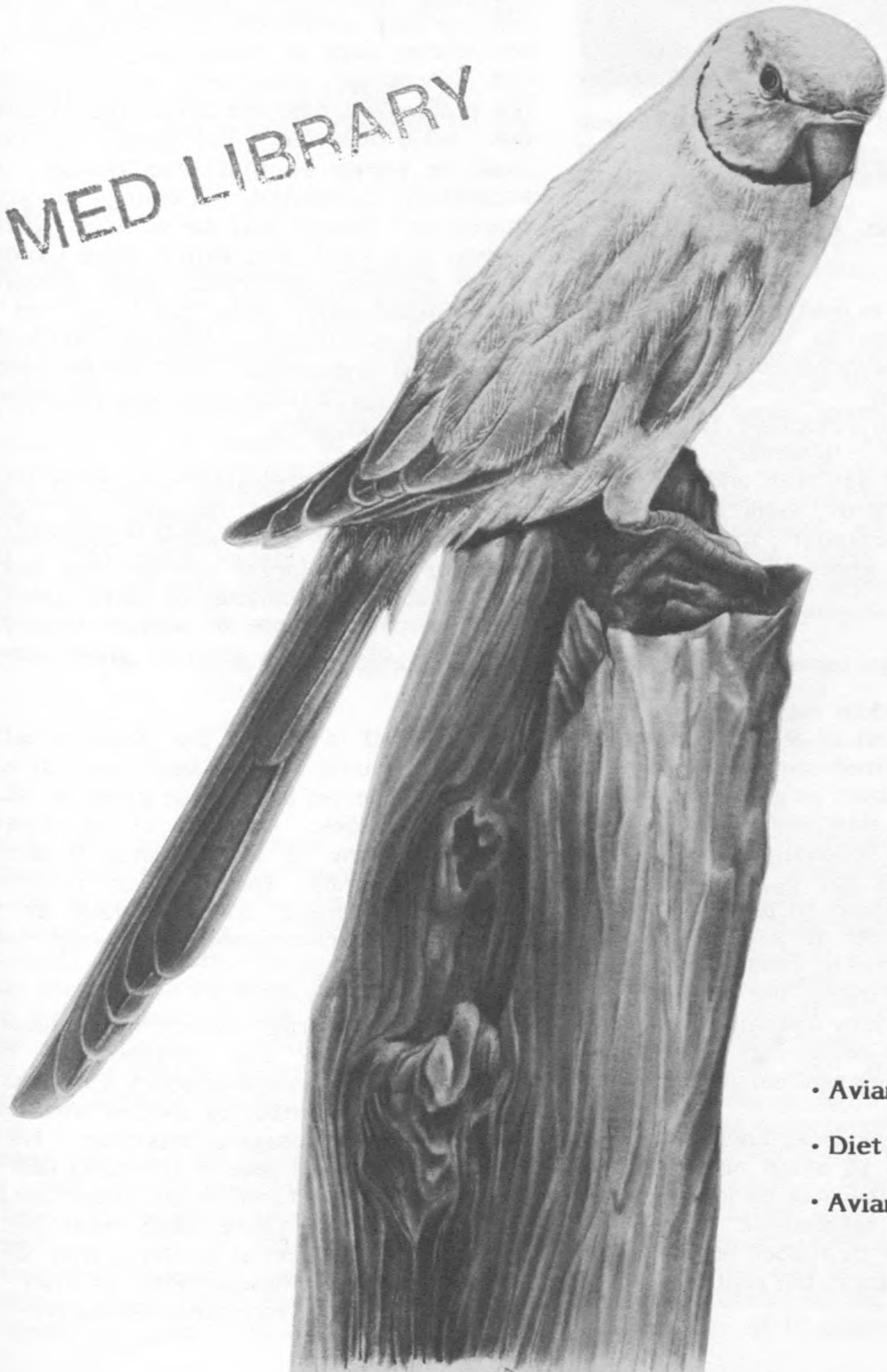

AVIAN ROUNDS


LIBRARY
IOWA STATE UNIVERSITY
AUG 5 1986
of Science and Technology

New York State College of Veterinary Medicine • Cornell University

ET MED LIBRARY



- Avian Anesthesia pg. 2
- Diet & Calcium pg. 7
- Avian Tuberculosis pg. 10



AVIAN ANESTHESIA

By Kathy Linn, COR. '84

Because of differences in mammalian and avian anatomy and physiology as well as relative unfamiliarity with idiosyncrasies of the many species which may be encountered, veterinarians are often reluctant to attempt anesthesia of birds. However, with the increasing popularity of pet birds and the rising interest in wild bird medicine, many veterinarians will encounter the need to anesthetize - locally or generally - one or more birds.

LOCAL ANESTHESIA

Local anesthesia is seldom used on birds for a number of reasons. First of all, the cutaneous sensation in birds is limited compared to that of mammals, and thus minor surgical procedures such as the suturing of skin lacerations seem to cause them little pain. Secondly, although local anesthesia may deaden any pain a patient is perceiving, it does nothing to protect it from stress. It is often safer to avoid the stress factor as much as possible by rendering the bird in hand unconscious. Finally, the small size of many avian patients makes overdosage of local anesthetic agents --producing depression, ataxia and death -- a very real danger.

There are two forms of local anesthesia that have some application to avian medicine. A few drops of proparicaine may be instilled into the eyes for certain ophthalmic procedures; lidocaine ointment may be rubbed onto exposed mucous membranes to aid in the replacement of prolapsed cloacas.

INJECTABLE ANESTHETICS

Injectable anesthetics require little equipment and are very convenient for many of the short procedures, such as radiography, wound repair and laparoscopy, commonly done in birds. A few problems attend the use of agents given by this route, however. The weight of the bird must be known so that drug dosage can be accurately calculated. Coming up with an appropriate dosage may be difficult when the patient is a small bird with a large tumor -- a rather common occurrence with budgerigars. Most importantly, once the drug has been injected it is difficult to control the depth and duration of anesthesia. This makes injectable anesthetics less desirable for long procedures or critically ill patients.

Many of the **barbiturates** have been tried on birds with varying degrees of success. Ultrashort-acting barbiturates have been used on some of the larger species and found to provide about ten minutes of useful anesthesia. The approximate dose of sodium thiamylal is 0.2 ml/kg of a 2.5% solution given slowly to effect.

Pentobarbital is one of the more versatile of the barbiturates; it has been used in a wide number of species and can be given by IM, IV or even oral routes. Duration of the anesthesia induced by any of these routes is about 30 minutes in most species, but recovery is generally prolonged and may take up to 12 hours. The recommended IM dosage for this drug is 50 mg/kg.

A combination drug containing pentobarbital, chloral hydrate and magnesium sulfate (Equithesin, by Jensen-Salsbury Co.) has been used in a large number of species with relative success. The IV dosage of this drug is 1.0 to 1.5 ml/kg while the IM dose is 2.5 ml/kg (2.0 ml/kg in obese and debilitated birds). Induction by the more common IM route takes from 10 to 35 minutes and duration of action is from 25 to 90 minutes. Some muscle necrosis may occur when this drug is given intramuscularly.



In general, although barbiturates can be used successfully, their relatively narrow margin of safety and prolonged recovery periods make them less desirable than some of the other agents available.

(Metomidate and CT 1341 are also used for avian anesthesia, but are not available in the U.S.)

Ketamine

Of the injectable anesthetics available in this country, ketamine is the most widely used. Given intramuscularly it takes from 3-5 minutes to produce anesthesia of approximately 10-30 minutes duration. Its recovery period is longer than that of CT 1341, as birds take from 30 minutes to 5 hours to stand after administration of ketamine. Dosages vary considerably from species to species, but in general dosage is inversely proportional to body weight. The most widely cited IM dosage scheme is the following proposed by Boever and Wright:

Body weight (grams)	IM dosage, mg/g	IM dosage mg/kg
100	0.1-0.2	100-200
250-500	0.05-0.1	50-100
500-3000	0.02-0.1	20-100
3000	0.02-0.05	20-50


In using this table it may be helpful to remember that the average budgerigar weighs 30 g., the average pigeon weighs 300g., and red tailed hawks and great horned owls tend to weigh about a kilogram. Large raptors seem to do best when given between 25 and 50 mg/kg. In the avian clinic of the New York State College of Veterinary Medicine, 30-40 mg/kg IM has worked well to anesthetize raptors for radiography and laparoscopy.

Ketamine can also be given intravenously to larger birds, rapidly inducing anesthesia which lasts from 15 minutes to several hours. It may be combined with IV diazepam to smooth induction and recovery and enhance muscle relaxation; when this is done the usual dosage of ketamine is 30-40 mg/kg and

diazepam dosage is 1.0-1.15 mg/kg. As with the IM route there is substantial variation in the amount of anesthetic required by different species. Owls appear to be especially sensitive to ketamine; it is suggested that the optimal IV dose for them is 25 mg/kg with the exception of the barred owl, which does best when given a dose of only 10 mg/kg. It is important to inject the ketamine slowly and to give the drug in divided doses separated by a few minutes if the total amount given is more than 50 mg. Too much ketamine too quickly given IV can result in apnea or even cardiac arrest.

Ketamine dosage by either route can be repeated if necessary. The duration of anesthesia as well as the recovery time is dose-dependent: birds given heavier doses take longer to wake up. Depth of anesthesia also appears to be somewhat dependent on dose, the lower dosages (10 mg/kg) being considered good only for restraint while higher ones are appropriate for minor surgical procedures. However, analgesia appears to be incomplete at even the highest dosages.

When ketamine is administered properly it has little effect on respiration, but heart rate does tend to decrease. Its effect on arterial blood gases and acid-base status is minimal. There are several problems attendant with the use of ketamine. The questionable degree of analgesia attained has already been mentioned; this may limit its usefulness for major surgical procedures. As well, the recovery period can be rather long in some situations. Excessive salivation has been reported, although this does not seem to occur as consistently as it does with metomidate. Most workers have found muscle relaxation under ketamine to be poor, with tremors and wing flapping quite common; recoveries can also be quite violent. This can be a real problem during orthopedic procedures. The addition of IV diazepam to the anesthetic



protocol appears to alleviate this somewhat. Finally, although ketamine is generally considered to be a safe anesthetic agents for birds, its therapeutic index (at least in chickens) is only 4.85, making accurate dosage critical. It is possible to overdose birds if they have a higher than average amount of body fat.

When giving any of the injectable anesthetics, it is important to put the drug in the right place to assure proper absorption and minimize mechanical damage to the patient. Intramuscular injections are best given in the caudal two-thirds of the pectoral muscles. If the needle is angled in toward the keel there is little danger of injecting anesthetic into the body cavity. Intravenous injections are most frequently given in the branch of the brachial vein that passes over the elbow on the ventral surface of the wing. This area is devoid of feathers and it is easy to see the needle within the lumen of the vein, making aspiration of blood as unnecessary as it is difficult. For both IM and IV injections a 26 gauge needle should be used. Once venipuncture has been performed, it is often necessary to keep pressure on the site for up to five minutes to prevent hematoma formation; otherwise a small bird could lose a significant portion of its blood volume.

INHALATION ANESTHESIA

Inhalation anesthesia is the method of choice for lengthy or involved procedures because it can be maintained for as long as necessary and the depth of anesthesia can be controlled. Because recovery from some of the inhalation anesthetic agents is quite rapid this is also a desirable method of anesthetizing patients for short procedures as well. The following agents are in fairly common use:

Ether is administered most frequently by open drop face mask technique. Induction and recovery are very rapid -- both occur within minutes. Unfortunately, ether is very explosive, which precludes the use of electrocautery. It is also very difficult to

control depth of anesthesia with this drug, especially when an open drop method is used. Because of these problems, ether has largely (and wisely) been replaced as an anesthetic by some of the newer volatile agents.

When used by itself **nitrous oxide** is incapable of producing anesthesia in birds: even a 90% concentration fails to anesthetize chickens. It has been used in combination with halothane and methoxyflurane to speed induction (it is unclear whether or not this actually occurs) and to decrease the concentration of the other anesthetic agent necessary to induce and maintain anesthesia. Usually the amount of halothane or methoxyflurane can be reduced by 1/4 to 1/3 when nitrous oxide is added to the gas mixture. It is recommended that nitrous oxide make up 50 to 70% of the total gas flow to be effective. The phenomenon of diffusion hypoxia is assumed to occur if ample oxygen is not given at the end of the anesthetic period, but this has never been demonstrated.

Methoxyflurane can be administered by open drop technique or through a standard anesthetic apparatus with a vaporizer. It is thought to produce a more stable plane of anesthesia than halothane, but induction and recovery take rather longer when methoxyflurane is used. Larger birds often take from 45 minutes to one hour to stand following surgery. Generally a 3-4% concentration is required to induce anesthesia; this takes from 4 to 15 minutes in most birds. Anesthesia can usually be maintained at 1.5-2% concentrations.

Halothane must be administered through an anesthetic system using a vaporizer, because concentrations delivered to the bird by open drop face mask can get lethally high. Induction usually takes from 2-4 minutes and requires anesthetic concentrations of around 2% for small birds and 2.5-3% for larger ones. Concentrations required for maintenance vary between 0.5 and 1.5%. Recovery usually takes from 3 to 5 minutes. Bradycardia, hypotension and hypothermia often occur in birds under halothane anesthesia. This is reported to



rapidly resolve once the anesthetic is turned off; nevertheless, it may be of considerable concern during a surgical procedure.

The administration of **isoflurane** to birds has been used successfully here at the New York State College of Veterinary Medicine in a variety of avian species. Induction with isoflurane is rapid; usually one to two minutes at a concentration of 3% renders a bird ready for intubation. A concentration of about 1.5% is required for maintenance of anesthesia. Recovery from this anesthetic is almost immediate; most birds are standing within five minutes. We have noticed a decrease in the heart rate of most birds undergoing isoflurane anesthesia, but this is usually not as marked as that which has been reported for halothane; usually heart rate only decreases 20 to 40 beats per minute. The birds do become hypothermic during anesthesia; blood pressure has not been monitored. All in all, isoflurane is a promising anesthetic agent for birds and deserves attention.


Compared to that of mammals the avian lung has a much higher surface to volume ratio and a thinner blood-air barrier, making it more efficient at gas exchange. This may account for the more rapid induction times seen in avian anesthesia as well as the sudden and dramatic changes in anesthetic depth that frequently occur in response to minimal changes in anesthetic concentration or respiratory rate. However, birds have about the same total volume of gas in their respiratory systems (proportional to body size) that mammals do. This means that birds have much less functional residual capacity in their parabronchi than mammals have in their alveoli; blood oxygenation can only occur if a constant flow of gas is maintained in the parabronchi. Apnea, therefore, results in death much more quickly in birds. Some researchers feel that the large amount of gas stored in the air sacs makes birds relatively inefficient at eliminating inhaled anesthetics. They suggest that oxygen be continued for a while after the anesthetics are turned off to aid the birds while they are

clearing their air sacs of residual anesthetic gases.

Birds appear to be especially sensitive to carbon dioxide concentrations in inspired air. They even possess CO₂-sensitive pulmonary receptors which play a role in regulating respiratory frequency. Respiration is vastly reduced in the absence of CO₂. In fact, when pure oxygen is instilled into the air sacs birds will become apneic. Perhaps systems which allow some CO₂ to be rebreathed would be desirable in avian anesthesia.



Ed Spindel '84 anesthetizes a bald eagle using a gas anesthetic machine. Dr. Spindel continues to pursue his interest in exotic and avian medicine at his veterinary practice in Liverpool, New York.



AVIAN ROUNDS

The most commonly encountered problem in avian anesthesia is that of hypothermia. Being small, birds have a high surface-to-volume ratio which predisposes them to heat loss when they are not moving. Normal body temperature is usually between 105 and 112° F but it may drop up to 18° during halothane anesthesia. All birds undergoing anesthesia should be kept on heating pads throughout surgery and the recovery period and should never be restrained directly on a metal surface. The metal acts as an efficient heat sink and promotes rapid hypothermia. Small birds may be kept warm by placing them on warm bags of intravenous fluids or even surgical gloves filled with warm water and knotted. Alcohol scrubs prior to surgery should be avoided. Hypothermia can be compounded by hypoglycemia, which is common in debilitated birds. It is important not to fast birds (except for those at least a kilogram in size) prior to surgery, as fasting for even a few hours may produce hypoglycemia. If a candidate for surgery is found to be hypoglycemic, administration of 5% dextrose solution IV or SQ will help it maintain its body temperature.

An unusual sequela to anesthesia that has been noted in two raptors at the New York State College of Veterinary Medicine has been a marked decrease in the intraocular pressure of one eye following anesthesia. In both cases it was the "down eye" that was affected. This problem has resolved within hours on both occasions and its cause remains hidden.

Avian anesthesia has its attendant frustrations, but it can also be rewarding. With the application of a few basic principles, and a little common sense, it is not difficult to do.

Abstracted from an article by Kathy Linn, DVM and Robin Glead, MRCVS, DACVA, in **Principles and Practice of Veterinary Anesthesia**. Editor, C.E. Short. Williams & Wilkins, Baltimore, M.D. 1987 (In press).



Brad Taylor '86, holds a young bald eagle in the Avian Clinic of the New York State College of Veterinary Medicine, Cornell.


AVIAN ROUNDS

Avian Rounds is published semi-annually by the New York State College of Veterinary Medicine at Cornell. Articles, ideas for articles and photos are contributed by students, alumni, and friends of the College. Submissions are welcome and all articles are reviewed by our editorial board.

AVIAN ROUNDS EDITORIAL BOARD

Lloyd A. Dillingham, DVM
David L. Graham, DVM
Christopher Murphy, DVM
Joanne Paul Murphy, DVM
Shelby Riddle, DVM

Correspondence may be addressed to **Karen Redmond, Editor**, Avian Rounds, Schurman Hall, New York State College of Veterinary Medicine, Cornell University, Ithaca, New York 14853. Telephone: 607/253-3740.



THE EFFECTS OF DIET AND CALCIUM ON PET BIRD HEALTH

Richard Blomquist COR. '85

Diseases directly and indirectly caused by dietary deficiency are common in captive birds. Particularly common is chronic calcium deficiency since its dietary requirements are greater than those for any other mineral. Calcium is needed for mineralization of the skeleton, reproduction of the egg shell, normal neuromuscular function, blood clotting, glandular secretion, membrane integrity, and regulation of certain enzyme systems.

About 98% of a bird's total body calcium exists in bone. Bone formation is an ongoing process controlled by serum calcium levels through the action of three hormones: parathormone, calcitonin and the active metabolite of vitamin D.


All air-breathing vertebrates have parathyroid glands and the stimulus for these glands to secrete parathormone is the lowering of plasma calcium levels. Calcitonin is secreted by specialized cells called the ultimobranchial glands and works to lower serum calcium by retardation of bone resorption. Recent extensive investigations into the metabolites of vitamin D and their actions have led to the suggestion that vitamin D should not be considered a vitamin *per se* but as a steroid hormone. Vitamin D₃ is either consumed in the diet or it is formed in the skin under the influence of ultraviolet light. Vitamin D also acts in concert with parathormone to control bone resorption.

Avian species have developed a peculiar facet of bone metabolism to deal with the enormous drain of body calcium during egg production. The shell gland of the fowl's oviduct is capable of secreting approximately 5 grams of calcium carbonate in 20 hours. Calcium is rapidly removed from the blood during this process. A unique aspect of avian physiology is the existence of skeletal calcium in normal

structural bone as well as in cyclicly produced non-structural bone tissue in medullary cavities. This "medullary bone" only exists in females one to two weeks prior to and during reproduction. Calcium stored in medullary bone is an asset during egg shell production for it is capable of being formed and resorbed much more quickly than any other form of bone.

The metabolism of calcium is intricately linked with that of phosphorus and vitamin D. Therefore, it is necessary that appropriate amounts of all these nutrients be included in the diet. To date (1984) there has been no scientific determination of the nutrient requirements of any avian species except domestic fowl. This is evident in the range of "optimal" dietary compositions quoted in the literature. These recommendations are based on diets which have been empirically shown to prevent overt nutritional disorders and to support reproduction in various groups of captive avian species in zoos, aviaries and other collections.

Calcium and phosphorus exist in the body in a 2:1 ratio. The optimal ratio in the diet should be between 1:1 and 4:1 or higher, depending on species, age and reproductive status. Most dietary errors involve insufficient calcium, excess phosphorus, or both. Carnivorous birds are commonly fed unsupplemented meat diets with calcium/phosphorus ratios ranging from 1:5 to 1:37. Since soluble calcium and phosphorus ions are in equilibrium with various forms of insoluble calcium phosphate, an excess of phosphate ions ties up the calcium ions present in the ingesta as insoluble calcium phosphate. Phosphorus continues to be absorbed causing a hyperphosphatemia which, by mass law, results in hypocalcemia. In addition, excessive oily dietary supplements (e.g. cod liver oil) or oil-bearing seeds (e.g. peanut and sunflower used as a large proportion of most psittacine diets) lead to an excess of unabsorbed long-chain fatty acids which combine with dietary calcium to form insoluble calcium soaps. These fatty acids can also reduce absorption of fat soluble vitamins, including vitamin D₃. Finally, most commonly used avian



Dr. David G.
with a patient

diets contain absolute levels of calcium which are much too low. The diet of mature non-breeding birds should contain about 1% calcium. Young, growing birds or reproductively active birds should be fed a diet with approximately 2.5% calcium. Carnivorous birds are commonly fed diets ranging from 0.01-0.4% calcium. Seed-eating birds' diets range from 0.05-0.17% calcium. Even insectivorous birds are not free from deficiencies, as they might be expected to be since they consume the entire organism; the insect's chitinous exoskeleton is devoid of calcium. Mealworms, a commonly-offered item, contain 0.03-0.26% calcium.


Birds that receive exposure to ultraviolet irradiation have no dietary requirement for vitamin D. In addition to the formation of D₃ in the skin, it has been suggested that the oily secretion of the uropygial gland is also converted to D₃ by sunlight and that the bird consumes this vitamin D while preening. However, the majority of pet birds are housed indoors and ordinary window glass filters out most ultraviolet light.

It follows that a dietary source of vitamin D₃ is required by the majority of captive birds. In plants, vitamin D occurs only in sundried foliage and is completely lacking in seeds. This vitamin D, of plant origin, is vitamin D₂ and cannot be utilized by birds. Therefore, diets composed mainly of seed and/or fresh vegetation are deficient in vitamin D₃. Since vitamin D₃ is required for calcium absorption, hypocalcemia was noted after 2 weeks even on a diet containing adequate (1%) calcium but devoid of vitamin D₃.

Metabolic bone disease is a general term which has been applied to several conditions that develop as a result of dietary deficiencies of calcium or vitamin D, or from an improper calcium-to-phosphorus ratio in the diet. These conditions include rickets, and its adult counterpart, osteomalacia, and nutritional secondary hyperparathyroidism. A calcium deficient state can also lead to reproductive failure. Vitamin D deficiency may cause soft-shelled eggs, which can cause a bird to become egg bound.

The primary treatment and the prevention of all the above disorders is correction of the diet. The use of a commercial pelleted or kibbled non-seed diet is a convenient way to supply adequate amounts of essential nutrients. Carnivorous birds will thrive on Zupreem Bird of Prey Diet[®]. Commercial diets for seed-eating birds that have been used with success include: Purina Gamebird Layena, and nutritionally complete dry dog food, New World monkey chow, or various new pelleted products for more specific bird groups marketed by the Lafeber Company, Bird Life[®], Blair's Products, or Ziegler Brothers.

The introduction of a commercial non-seed diet may be met with resistance by the bird because affected birds may have become habituated to deleterious food items. Mixing the old diet with the new, and slowly withdrawing the prior diet is suggested. Sudden replacement of the previous diet with a new one can, in some cases, result in death by starvation. One research trial implementing the immediate withdrawal technique reported canaries



accepted at once but budgerigars refused for up to 48 hours before adapting well.

A commercial diet may not always be a viable option. Many well-meaning owners and caretakers will want to provide a more "natural" diet. In these cases, one should encourage as varied a diet as possible and insist upon proper supplementation.

Free-choice calcium supplementation with cuttlebone, commercially prepared mineral blocks, or oyster shells has been a successful means of preventing deficiency disorders in many species of pet birds. Determining what amounts are being ingested or if a borderline deficiency exists is near impossible, but millions of pet birds have thrived with free-choice calcium available. Arnold et al. showed that free-choice cuttlebone prevented NSH in the parakeet. (See following article).

Many commercial calcium supplements are manufactured for both humans and pets. These can be used to supplement the diet if it can be disguised in a food item or is palatable enough to be taken voluntarily. Sprinkling a powdered supplement over a seed diet is a common practice that should be discouraged since most of the supplement will be discarded with the seed hulls. A new product, Avimin^R, is a liquid mineral supplement for birds which may be added to the drinking water. Multivitamin preparations containing vitamin D₃ rather than D₂ are to be recommended since birds can not adequately use D₂. Parenteral use of a vitamin D₃ supplement may be necessary in severely deficient animals. Frequent and direct exposure to sunlight or use of ultraviolet fluorescent lamps will assure vitamin D₃ activity in all species.

This article was condensed from Dr. Blomquist's senior seminar, "The Effects of Diet and Serum Calcium Homeostatic Mechanisms on Pet Bird Health".

Condensed from: **"Nutritional Secondary Hyperparathyroidism in the Parakeet",**

Stephen A. Arnold, Malcolm A. Kram, Harold F. Hintz, Howard Evans and Lennart Krook. 1973. *Cornell Veterinarian*, 64: 37-46.

The effects of low dietary calcium and/or dietary phosphorus excess with resulting nutritional secondary hyperparathyroidism (NSH) are well recognized in mammals. The condition has, however, received little attention in caged birds. In caged birds fed sunflower seeds, peanuts, and whole oats, all of which have a low calcium and a high phosphorus content, parathyroid hyperplasia and bone lesions, primarily osteolysis, were recorded. Osteolysis defines a deep-seated resorption of bone tissue, centered around the activity of mature osteocytes.

Four parakeets, five weeks of age, were fed free choice of commercial birdseed and demineralized water. Two of the birds were also given free access to cuttlebone. The birdseed contained 0.01 percent calcium and 0.37 percent phosphorus. The cuttlebone contained 81 percent ash, 34.6 percent calcium and 0.04 percent phosphorus on a dry matter basis. The feeding experiment lasted for 7 weeks. No clinical signs were observed in any birds during the 7-week feeding period. At necropsy, the parathyroids of non-supplemented birds were markedly enlarged. Histologically, bones of nonsupplemented birds showed all the criteria of enhanced osteolysis.

The present study showed that a low calcium - high phosphorus diet does indeed produce NSH in caged birds, as is the situation in mammals. Feeding of birdseed alone, with a very unfavorable calcium to phosphorus ratio, is totally inadequate.



A CASE REPORT:

AVIAN TUBERCULOSIS IN A GREEN-CHEEKED AMAZON PARROT

By Shelby Riddle COR. '86

THE HISTORY: Lobo, a nine-year-old male Green-cheeked Amazon parrot (*Amazona viridigenalis*), was admitted to the Teaching Hospital of the New York State College of Veterinary Medicine as an emergency case. The owners had recently noticed weight loss and voice change with an occasional respiratory wheeze. The parrot's history showed that he had been obtained by the present owner from a private individual, but had spent some time as a display bird at the SPCA. Lobo had also escaped from his owners six years ago and spent three days in the woods before recapture. In the same household with the parrot were two budgerigars that died unexpectedly and were found to be emaciated. For a time he'd been housed with a Mitred conure (*Aratinga mitrata*), but was removed when he received a bite wound on the leg from the conure. Lobo's diet consisted of sunflower seeds, corn, red peppers, peanuts, and apples with no greens or vitamin or mineral supplementation.

PHYSICAL EXAMINATION: On physical examination, the bird was noted to be very thin with an empty crop and a weight of 331 grams. The feathers were ruffled and the tail feathers were bent or missing. The right naris was plugged with a brown material and he was wheezing. Both legs were swollen and there was bleeding at the site of the previous bite wound. Examination of the droppings revealed that the urates were increased in volume and the stool was soft. Despite his empty crop and emaciation, reportedly the bird had been eating well up to the time of presentation, and ate well in the hospital. He was treated with amoxicillin trihydrate and tube fed a canned dog food slurry.

DIAGNOSTIC TESTS & RESULTS: Blood was collected by venipuncture and revealed a mild degree of anemia and normal total solids (4.9 gm/dl). The total white blood cell (WBC) count was 19,900 with 82% heterophils and 15% lymphocytes. The leukocytosis with heterophilia was considered to be the result of response to inflammation. A blood sample submitted for serum chemistry, including electrolytes and liver and kidney function tests yielded, in general, results within the normal range.

Using physical restraint, a ventrodorsal whole body radiograph was taken. The radiograph revealed a cranially displaced gizzard with the possibility of left liver lobe enlargement, loss of definition to the lateral surface of the thoracic air sacs, especially on the left side, and increased soft tissue volume around the legs, with irregularity to the skin contour.

Cloacal swabs were submitted for chlamydial isolation, and feces for flotation, as well as culture and sensitivity for acid-fast staining. The fecal flotation was negative for parasites. Fecal culture yielded a few colonies of *Klebsiella pneumoniae* and *Bacillus* sp.. Clumps of small acid-fast organisms were identified with Ziehl-Neelsen staining of a fecal smear. Due to the presence of such a large number of acid-fast staining organisms, the presumptive diagnosis was avian tuberculosis and the bird was euthanized at the owner's request. Confirmation of the etiologic agent *M. avium* requires bacteriologic isolation and typing and is pending at the National Services Veterinary Laboratory in Ames, Iowa.



NECROPSY FINDINGS: Gross necropsy and microscopic findings suggested a diagnosis of tuberculosis, with the large number of organisms visualized suggestive of Mycobacterium avium. There were multiple tan to cream-colored, well circumscribed and smoothly encapsulated nodules attached to the body wall, liver, kidney, mesentery, and ventriculus. There was a pronounced grey-tan nodular to diffuse thickening of the duodenal and upper jejunal wall. In the lungs there were focally extensive regions of interstitial calcinosis as well as numerous interstitial microgranulomas composed of plump macrophages which contained acid-fast organisms. While the leg swelling had been clinically interpreted as edema, the swelling was actually a manifestation of diffuse granulomatous inflammation of the dermis and subcutis due to acid-fast organism infiltration. The radiographic appearance of an apparently enlarged left liver lobe was determined to be the result of cranial displacement of the liver due to duodenal involvement with enlargement. Based on these lesions, it was difficult to determine the primary site of infection.

DISCUSSION: Mycobacterium avium is a ubiquitous organism which can survive for years in the environment. About 150 cases of human infection with M. avium have been recorded worldwide, with most cases characterized by lymphadenitis or pulmonary tuberculosis. This is not a large number of cases considering the degree of exposure of humans to infected chickens, swine, wild birds and other species, but it is still a disease which must be treated with respect as a potential zoonosis.

Parrots can become infected with M. avium, M. tuberculosis, and M. bovis; other avian species are reportedly susceptible in nature only to M. avium. Parrots are more susceptible to the mammalian forms and relatively resistant to M. avium. The usual route of entry is the digestive tract, with repeated ingestion of mycobacterial organisms resulting in a primary intestinal tract infection with subsequent spread via the lymphatics to other organs and sites throughout the body.

Avian tuberculosis is a slowly progressive and insidious disease and should be suspected in a psittacine bird with chronic wasting, recurrent diarrhea, anemia, and dullness or loss of plumage, or when nodular lesions are seen in visceral organs via laparoscopy or at necropsy. However, small nodules or minute grayish areas of necrosis also may be caused by other infections such as pseudotuberculosis, E. coli infections, fowl typhoid, parasitic invasions, or by neoplastic diseases.

In general, it is difficult to diagnose this disease antemortem due to inconsistent laboratory findings. Clinical signs are variable, with some birds having diarrhea and others having signs related to osteomyelitis or to involvement of a variety of other organs, including the brain and eye. In examination of infected captive exotic birds the most consistently observed clinical signs associated with avian tuberculosis were muscular atrophy and severe weight loss, evidenced by the prominence of the keel. At this advanced stage, death of the birds was imminent.

A definitive diagnosis of tuberculosis requires that the acid-fast bacilli be isolated and identified from exudates, body discharges or from lesions. Specimens must be treated to kill contaminants and, if mailed, should be placed in a saturated solution of sodium borate to minimize growth of contaminants. Most TB tests used in poultry, including the intradermal tuberculin test and a whole blood agglutination test, are less reliable when used in captive avian species. Numerous false-negative results were reported in limited trials involving an antigen derived from M. avium serotype I in a whole-blood agglutination test. The suspect birds were found later to have the disease, making the usefulness of this test questionable. Finally, due to the high number of false negative results in acid-fast stains of cloacal and tracheal smears, they are of value only in confirming, not denying, a diagnosis.

Radiographic identification of avian tuberculosis lesions is difficult because, unlike mammalian TB lesions, those of birds have not



been shown to mineralize. As there are no standard methods for identifying tuberculosis infection in exotic species, newly acquired birds should be isolated and contact avoided with starlings, sparrows, blackbirds, chickens and pigeons as they can be reservoirs of infection.

Unfortunately, in pet birds the source of infection is not always apparent, as in the case of a 42-year-old parrot, diagnosed as having avian tuberculosis. The parrot was owned by the same family for 38 years and the family had no history of TB and no reaction to subsequent TB tests. While M. avium is the main cause of

tuberculosis in birds and a frequent cause in swine, it is responsible for only a small percentage of cases of tuberculosis in man. The group of people most often affected are those considered to have compromised host defenses before the onset of infection. In considering the importance of a definitive diagnosis of tuberculosis in a pet bird, it must be emphasized that parrots are the only birds reported to be susceptible to the human Mycobacterium tuberculosis organisms, and the apparent sharp decline of parrot tuberculosis in Europe in the past may be associated with control of the human disease.

AVIAN ROUNDS

The New York State College of Veterinary Medicine
Cornell University
Ithaca, New York 14853

Nonprofit Org.
U.S. Postage
PAID
Cornell
University

VETERINARY MEDICINE LIBRARY
% SALLY PETERSON
IOWA STATE UNIVERSITY
AMES, IA 50010